IntechOpen

A Textbook of Advanced Oral and Maxillofacial Surgery

Edited by Mohammad Hosein Kalantar Motamedi

A TEXTBOOK OF ADVANCED ORAL AND MAXILLOFACIAL SURGERY

Edited by

Mohammad Hosein Kalantar Motamedi

A Textbook of Advanced Oral and Maxillofacial Surgery
http://dx.doi.org/10.5772/3316
Edited by Mohammad Hosein Kalantar Motamedi

Contributors

Mazen Ahmad Almasri, Piotr Malara, Jeong Keun Lee, Yong Seok Cho, Amrish Bhagol, Virendra Singh, Ruchi Singhal, Petr Schütz, Hussein Hassan Hamed Ibrahim, Orrett Ogle, Levon Nikoyan, Francesco Arcuri, Livia Stellin, Alessandro Gatti, Matteo Brucoli, Mariangela Giarda, Arnaldo Benech, Matteo Nicolotti, Amila Brkic, Banu Gürkan-Köseoğlu, Hülya Koçak-Berberoğlu, Çetin Kasapoğlu, Vanja Vucicevic Boras, Mohammad Hosein Kalantar Motamedi, Jan Rustemeyer, Miroslav Andric, Bozidar Brkovic, Milan Jurisic, Vladimir Jurisic, Jelena Milašin, Hajime Shudou, Maiolino Thomaz Fonseca Oliveira, Flaviana Soares Rocha, Jonas Dantas Batista, Sylvio Luiz Costa De Moraes, Darceny Zanetta-Barbosa, Dragana Gabrić Pandurić, Irina Filipović Zore, Mato Sušić, Ivona Bago, Davor Katanec, Aleksandar Milenović, Mehmet Cemal Akay, Kazuma Fujimura, Faris Fočo, Hany Emam, Mark Stevens, Ali Hassani, Sarang Saadat, Petia Pechalova, Elena Poriazova, Nikolai Pavlov, Angel Georgiev Bakardjiev, Farzin Sarkarat, Roozbeh Kahali, Behanm Bohluli, Shahram Nazerani, Koroush Taheri Talesh, Taghi Azizi, Hossein Behnia, Azita Tehranchi, Golnaz Morad, Sertac Aktop, Onur Gonul, Tülin Satılmış, Hasan Garip, Kamil Göker, Farshid Kavandi, Fina Navi, Tarek El-Bialy, Adel Alhadlaq

© **The Editor(s) and the Author(s) 2013**
The moral rights of the and the author(s) have been asserted.
All rights to the book as a whole are reserved by INTECH. The book as a whole (compilation) cannot be reproduced, distributed or used for commercial or non-commercial purposes without INTECH's written permission.
Enquiries concerning the use of the book should be directed to INTECH rights and permissions department (permissions@intechopen.com).
Violations are liable to prosecution under the governing Copyright Law.

Individual chapters of this publication are distributed under the terms of the Creative Commons Attribution 3.0 Unported License which permits commercial use, distribution and reproduction of the individual chapters, provided the original author(s) and source publication are appropriately acknowledged. If so indicated, certain images may not be included under the Creative Commons license. In such cases users will need to obtain permission from the license holder to reproduce the material. More details and guidelines concerning content reuse and adaptation can be foundat http://www.intechopen.com/copyright-policy.html.

Notice

Statements and opinions expressed in the chapters are these of the individual contributors and not necessarily those of the editors or publisher. No responsibility is accepted for the accuracy of information contained in the published chapters. The publisher assumes no responsibility for any damage or injury to persons or property arising out of the use of any materials, instructions, methods or ideas contained in the book.

First published in Croatia, 2013 by INTECH d.o.o.
eBook (PDF) Published by IN TECH d.o.o.
Place and year of publication of eBook (PDF): Rijeka, 2019.
IntechOpen is the global imprint of IN TECH d.o.o.
Printed in Croatia

Legal deposit, Croatia: National and University Library in Zagreb

Additional hard and PDF copies can be obtained from orders@intechopen.com

A Textbook of Advanced Oral and Maxillofacial Surgery
Edited by Mohammad Hosein Kalantar Motamedi

p. cm.

ISBN 978-953-51-1146-7

eBook (PDF) ISBN 978-953-51-7166-9

We are IntechOpen, the world's leading publisher of Open Access books

Built by scientists, for scientists

4,100+
Open access books available

116,000+
International authors and editors

120M+
Downloads

Our authors are among the

151
Countries delivered to

Top 1%
most cited scientists

12.2%
Contributors from top 500 universities

WEB OF SCIENCE™

Selection of our books indexed in the Book Citation Index in Web of Science™ Core Collection (BKCI)

Interested in publishing with us?
Contact book.department@intechopen.com

Numbers displayed above are based on latest data collected.
For more information visit www.intechopen.com

Meet the editor

Dr. Mohammad Hosein Kalantar Motamedi is Professor of Oral and Maxillofacial Surgery at BMSU Trauma Research Center and Azad University, Tehran. He graduated from Pennington High (Pennington, Virginia, USA) and then went to the University of Houston (Texas, USA). His doctorates was from Tehran University, postgraduate degree from Shahid Beheshti University and fellowship certification from Basel University (Switzerland). He has published 18 textbooks, 124 papers indexed in PubMed (h-index = 13). He has supervised 55 doctorate dissertations, is Editor-in-Chief of "Trauma Monthly", Associate Editor of "BMC Oral Health", "BMC Research Notes"(UK), "Dental Hypotheses", "Open Journal of Stomatology" and is CE faculty of "Dentistry Today" (USA). He is listed in Marquis "Who's Who in the World" and "Who's Who in Medicine and Healthcare".

Contents

Preface XIII

Section 1 Surgery of Impacted Teeth: Complications and Concepts 1

Chapter 1 **Complications Following Surgery of Impacted Teeth and Their Management 3**
Çetin Kasapoğlu, Amila Brkić, Banu Gürkan-Köseoğlu and Hülya Koçak-Berberoğlu

Chapter 2 **New Concepts in Impacted Third Molar Surgery 27**
Mohammad Hosein Kalantar Motamedi and Farshid Kavandi

Section 2 Oral and Maxillofacial Infections: Diagnosis and Management 45

Chapter 3 **Odontogenic Infections 47**
Onur Gonul, Sertac Aktop, Tulin Satilmis, Hasan Garip and Kamil Goker

Chapter 4 **Non-Odontogenic Oral and Maxillofacial Infections 67**
Petr Schütz and Hussein Hassan Hamed Ibrahim

Section 3 Oral and Maxillofacial Pathologies: Diagnosis and Management 127

Chapter 5 **Diagnosis and Management of Common Oral and Maxillofacial Lesions 129**
Taghi Azizi

Section 4 Large and Agressive Maxillofacial Cysts: Trends in Management 189

Chapter 6 **Treatment of Large Cysts of the Mandible with Autografts of Cancellous Bone from the Tibia 191**
Piotr Malara

Chapter 7 **Keratocystic Odontogenic Tumors – Clinical and Molecular Features 209**
Miroslav Andrić, Božidar Brković, Vladimir Jurišić, Milan Jurišić and Jelena Milašin

Chapter 8 **Marsupialization of Keratocystic Odontogenic Tumors of the Mandible: Longitudinal Image Analysis of Tumor Size via 3D Visualized CT Scans 241**
Hajime Shudou, Masanori Sasaki, Takahiro Yamashiro, Shizuo Tsunomachi, Yasuharu Takenoshita, Yasutaka Kubota, Tomohiro Ninomiya, Toshiyuki Kawazu and Yoshihide Mori

Section 5 Considerations in Radiotherapy and Chemotherapy: Current Treatment Guidelines 255

Chapter 9 **Radiation and Chemotherapy in Oral and Maxillofacial Surgery 257**
Orett E. Ogle and Levon Nikoyan

Chapter 10 **Bisphosphonate-Related Osteonecrosis of the Jaws – Diagnosis and Management 279**
Petia F. Pechalova, Elena G. Poriazova, Nikolai V. Pavlov and Angel G. Bakardjiev

Section 6 Oral and Maxillofacial Vascular Anomalies: Diagnosis and Treatment 301

Chapter 11 **Vascular Anomalies of the Maxillofacial Region: Diagnosis and Management 303**
Faris Fočo and Amila Brkić

Section 7 Laser Applications in Oral and Maxillofacial Surgery 325

Chapter 12 **Applications of Low Level Laser Therapy 327**
Vanja Vučićević Boras, Danica Vidović Juras, Ana Andabak Rogulj, Dragana Gabrić Pandurić, Željko Verzak and Vlaho Brailo

Chapter 13 **Application of Diode Laser in Oral and Maxillofacial Surgery 341**
Dragana Gabrić Pandurić, Ivona Bago, Irina Filipović Zore, Mato Sušić, Davor Katanec, Aleksandar Milenović and Vanja Vučićević Boras

Section 8 Maxillofacial Fractures: Diagnosis and Management 383

Chapter 14 **Management of Mandibular Fractures 385**
Amrish Bhagol, Virendra Singh and Ruchi Singhal

Chapter 15 **Management of Midfacial Fractures 415**
Sertac Aktop, Onur Gonul, Tulin Satilmis, Hasan Garip and Kamil Goker

Section 9 Advanced Maxillofacial Distraction Osteogenesis: State-of-the-Art 447

Chapter 16 **Distraction Osteogenesis 449**
Hossein Behnia, Azita Tehranchi and Golnaz Morad

Section 10 Advanced Oral and Maxillofacial Reconstruction 479

Chapter 17 **Reconstruction of Mandibular Defects 481**
Maiolino Thomaz Fonseca Oliveira, Flaviana Soares Rocha, Jonas Dantas Batista, Sylvio Luiz Costa de Moraes and Darceny Zanetta-Barbosa

Chapter 18 **Microsurgical Reconstruction of Maxillary Defects 501**
Shahram Nazerani

Chapter 19 **Maxillofacial Reconstruction of Ballistic Injuries 531**
Mohammad Hosein Kalantar Motamedi, Seyed Hossein Mortazavi, Hossein Behnia, Masoud Yaghmaei, Abbas Khodayari, Fahimeh Akhlaghi, Mohammad Ghasem Shams and Rashid Zargar Marandi

Chapter 20 **Cleft Lip and Palate Surgery 559**
Koroush Taheri Talesh and Mohammad Hosein Kalantar Motamedi

Chapter 21 **The Cosmetic Considerations in Facial Defect Reconstruction 573**
Mazen Almasri

Chapter 22 **Current Advances in Mandibular Condyle Reconstruction 593**
Tarek El-Bialy and Adel Alhadlaq

Section 11 Advanced Oral and Maxillofacial Rehabilitation and Implantology 615

Chapter 23 **Concepts in Bone Reconstruction for Implant Rehabilitation 617**
Hany A. Emam and Mark R. Stevens

Chapter 24 **Outfracture Osteotomy Sinus Graft: A Modified Technique Convenient for Maxillary Sinus Lifting 641**
Jeong Keun Lee and Yong Seok Cho

Chapter 25 **Inferior Alveolar Nerve Transpositioning for Implant Placement 659**
Ali Hassani, Mohammad Hosein Kalantar Motamedi and Sarang Saadat

Section 12 Orthognathic Surgery of Maxillofacial Deformities 695

Chapter 26 **Basic and Advanced Operative Techniques in Orthognathic Surgery 697**
F. Arcuri, M. Giarda, L. Stellin, A. Gatti, M. Nicolotti, M. Brucoli, A. Benech and P. Boffano

Chapter 27 **Rigid Fixation of Intraoral Vertico-Sagittal Ramus Osteotomy for Mandibular Prognathism 719**
Kazuma Fujimura and Kazuhisa Bessho

Chapter 28 **Soft-tissue Response in Orthognathic Surgery Patients Treated by Bimaxillary Osteotomy – Cephalometry Compared with 2-D Photogrammetry 725**
Jan Rustemeyer

Chapter 29 **Corticotomy and Miniplate Anchorage for Treating Severe Anterior Open-Bite: Current Clinical Applications 741**
Mehmet Cemal Akay

Section 13 Esthetic Oral and Maxillofacial Surgery 761

Chapter 30 **Office – Based Facial Cosmetic Procedures 763**
Farzin Sarkarat, Behnam Bohluli and Roozbeh Kahali

Chapter 31 **Facial Sculpturing by Fat Grafting 813**
Behnam Bohluli, Mehran Aghagoli, Farzin Sarkarat, Mansour Malekzadeh and Nima Moharamnejad

Section 14 Temporomandibular Joint Disorders and Facial Pain 829

Chapter 32 **Diagnosis and Management of Temporomandibular Disorders 831**
Fina Navi, Mohammad Hosein Kalantar Motamedi, Koroush Taheri Talesh, Esshagh Lasemi and Zahra Nematollahi

Preface

Oral and maxillofacial surgery is used to correct a wide spectrum of diseases, injuries, defects and deformities of the mouth, head, neck, face and jaws. It is an internationally recognized surgical specialty rapidly changing hand-in-hand with evolving advancements in technology. Oral and maxillofacial surgeons care for patients with impacted wisdom teeth, facial pain, and misaligned jaws. They treat accident victims with facial injuries, place dental implants and do bone transplants; they also care for patients with oral cancer, cysts, jaws lesions as well as cosmetic deformities of the face.

New texts are needed to keep practitioners up-to-date. A great number of textbooks have been written over the years aiming to introduce students and residents to the basics of oral and maxillofacial surgery. This book presents information relevant to advanced oral and maxillofacial surgical procedures, concepts and techniques. It targets residents, specialists and fellows engaged in practice of this dynamic specialty. For brevity therefore, the basic topics are not presented here as they are well covered in most textbooks; chapters on asepsis, infection control, surgical armamentarium, simple and complicated exodontia, antibiotic therapy, apicectomy ... are thus, not mentioned in this text. Instead, up-to-date coverage of complex, technique-oriented procedures performed by experienced specialists are presented. This book provides surgical information that will hopefully be helpful to clinicians in developing a correct and systematic approach to patient diagnosis and current management.

To this end, 14 sections on surgical complications of impactions, diagnosis and treatment of oral and maxillofacial infections, oral and maxillofacial pathological lesions, reconstruction of oral and maxillofacial defects, cleft lip and palate, and ballistic injuries, distraction osteogenesis, radiotherapy and chemotherapy, orthognathic surgery as well as oral and maxillofacial cosmetic procedures have been written by 93 international specialists from 18 countries. The text is comprised of 32 chapters focusing on advanced procedures of interest to practicing oral and maxillofacial surgeons; this book may help build a foundation of core knowledge that will guide and stimulate further research and advancements in this constantly changing field. Additionally, access to this knowledge is simple because readers may download the entire book online for free; saving paper and thus saving trees.

The preparation of this book was a difficult undertaking as it required a collaborative effort. This would not have been possible without the cooperation and contribution of national and international peers and colleagues whom I personally contacted and individually invited. It may be interesting to note here, that just recently when incidentally searching my “sent-emails” list, I found to my astonishment that I had written over 700 separate individualized email invitations (not bulk mail) over the past year to renowned specialists world-wide calling for chapters; I had no idea that I had sent that many emails. This book is the result and

the culmination of efforts of those colleagues who kindly responded to my email despite their busy schedule, commitments and academic obligations; thus I would like to take the opportunity to thank each and every one of them for accepting my invitation and contributing chapters in their field of expertise. Their assiduous, unyielding and relentless efforts in this cause and their generosity in sharing their knowledge on a global scale motivated me to complete this project. I know well that they had to sacrifice their free time to work on this book; a number of authors pulled-out half-way through the project. Preparing a book chapter is not like submitting an article. It is much more difficult. Only one who has authored a book can fully appreciate just how hard a task it is to compile and complete. But however arduous, time-taking and pain-staking a task, it had its merits. It compelled me to seek the assistance of my peers, friends and colleagues and thus provided me the honor, privilege and opportunity to work with out-standing researchers from across the globe including the USA, Canada, KSA, Poland, Turkey, Serbia, S. Korea, Kuwait, Brazil, Bosnia, Croatia, Japan, Bulgaria, Germany, Egypt, India, Italy and Iran. I hereby express my gratitude and sincere appreciation to each and every one of them. I would also like to thank : Ms. Ana Nikolic Head of Acquisitions for this project and the publishing managers Mr. Vedran Greblo, Ms. Martina Blecic, Mr. Dejan Grgur and Ms. Ana Pantar for their kind help throughout the past 12 months, and my mother Zakie my supporter, my father Mohammad Reza MD, FACS my mentor, and my wife Maryam who patiently put up with me during the lengthy hours while I sat in front of the computer monitor day-in and day-out typing-away, sending emails and editing book chapters. I hope it was worth it all.

Mohammad Hosein Kalantar Motamedi, DDS
Professor of Oral and Maxillofacial Surgery, Trauma Research Center,
Baqiyatallah University of Medical Sciences,
Tehran, Iran

Section 1

Surgery of Impacted Teeth: Complications and Concepts

Chapter 1

Complications Following Surgery of Impacted Teeth and Their Management

Çetin Kasapoğlu, Amila Brkić,
Banu Gürkan-Köseoğlu and
Hülya Koçak-Berberoğlu

Additional information is available at the end of the chapter

http://dx.doi.org/10.5772/53400

1. Introduction

One of the most performed procedures in the specialty of oral and maxillofacial surgery is removal of impacted teeth, especially third molars. Impaction is defined as failure of teeth to erupt into the dental arch within the expected time [1,2]. The reasons for tooth impaction include several factors subdivided into a local and general factors such as position and size of adjacent teeth, dense overlying bone, excessive soft tissue or a genetic abnormality including abnormal eruption path, dental arch length and space in which to erupt [1-3]. Clinically and radiographically, there are two types of impactions namely complete and partial. Complete impaction means that the tooth is covered by bone and mucosa and is prevented from erupting into a normal functional position; partial impaction means that the tooth is partially visible or in communication with oral cavity, but it has failed to erupt fully into a normal position [1]. The most common impacted teeeth are mandibular and maxillary third molars, followed by the maxillary canines and mandibular premolars. New data suggests that 72,2% of the world population has at least one impacted tooth (usually lower third molar) [3,4]. From the last 40 years, the incidence of impacted teeth has grown through different populations, due to living habits such as soft food diet and lower intensity of the use of the masticatory apparatus [3]. Only a few decades earlier, Inuits and Latin American Indians were described as populations with no impacted teeth [1]. Some authors suggest that race and gender have an influence on occurrence of impactions; thus, the impactions are more common in Caucasians than in Negroes; and females are more predisposed to this phenomenon than males. The age of the patients also play an important role in impacted teeth occurrence. Patients between 20 and 30 years of age are the most frequently affected with symptomatic impactions [4-7]. As age

INTECH
open science | open minds

© 2013 Kasapoğlu et al.; licensee InTech. This is a paper distributed under the terms of the Creative Commons Attribution License (http://creativecommons.org/licenses/by/3.0), which permits unrestricted use, distribution, and reproduction in any medium, provided the original work is properly cited.

increases, the phenomenon of impaction is reduced and after the age of 50 it is in a range from 6-14% [4,8]. Although in many cases, removal of impacted teeth can be easily performed, using just an elevator and forceps, occurrence of potential complications, causing distress to both the patient and the surgeon, should not be neglected. Clinical conditions such as position and relationship of the impacted tooth to adjacent teeth and anatomic structures such as the maxillary sinus, blood vessels, nerves, and anatomic spaces play an important role in development of complications [9]. However, despite surgical skills and expertise, some of the complications are iatrogenic origin, thus knowledge of their potential development might be helpful in their prevention. The aim of this chapter is to describe and discuss the most common and predictable complications related to the surgical removal of impacted teeth.

2. Complications associated with surgery of impacted teeth

Complications associated with impacted teeth removals are not irrelevant and their development is conditioned by local and general factors including tooth position, age and health status of the patient, knowledge and experience of the surgeon and surgical equipment. Because of osteoporotic or sclerotic bones, dental ankylosis, use of various drugs for coagulation, osteoporosis etc., which are more common seen at the older patients, the complication results associated with removal of impacted teeth might be more serious comparing with the same complications at younger patients. Generally speaking the complications related to removal of impacted teeth might be subdivided into a two groups:

Complications during surgery of impacted teeth and complications after surgery [9].

2.1. Complications during surgery of impacted teeth

Complications during the impacted teeth surgery are the most common and expected complications. They might be subdivided into seven groups:

1. Complications associated with impacted or adjacent tooth, 2. Soft tissue complications,3. Nerve injuries,4. Bone complications, 5. Maxillary sinus complications,6. Complications associated with surgical equipment, 7. Swallowing and aspiration [9].

2.1.1. Complications associated with the impacted or adjacent tooth

Caries is mentioned as one of the common pathological features associated with partially impacted third molars [10-12]. Mesioangular and horizontal positions of third molars are also responsible for development of distal cervical caries on the second molar, which are difficult to be restore without extraction of the impacted tooth. In many cases even use of lower force by an elevator or forceps, the fracture of the impacted tooth crown or fracture of the adjacent tooth or its restoration may be expected (Fig. 1) [13].

Variability in root shape and number may lead to fracture of the impacted tooth or roots. In cases when a small portion of the fractured root is in close relation to the maxillary antrum or mandibular canal and there is possibility of its displacement to these anatomic spaces, the

http://dx.doi.org/10.5772/53400

Figure 1. Control panoramic radiograph during lower left third molar surgery shows a fracture of the tooth.

fragment should not be removed [9]; provided that the fragments are not associated with pathologic lesions such as periapical lesions, cysts or tumors, and do not produce any clinical symptoms, in which case they should be removed [14]. Displacement of the adjacent tooth is common (deciduous tooth or permanent tooth bud) [1,9]. It may occur in cases when the impacted and neighboring permanent teeth are in close contact. It is also seen in cases of deep palatally- impacted maxillary canines and adjacent lateral incisors, lower third and adjacent second molars or mesiodens and adjacent central incisors. Displacement is mostly the result of uncontrolled force during extraction, although the loss of supporting bone during surgery may be influential [9]. In case of this complication, the treatment modality would be to place the displaced tooth in its previous position and immobilize it for three to four weeks. Fixation often can be obtained using additional sutures placed laterally across the occlusal surface, thereby holding the tooth in place. Use of other means of fixation, including dental wires, arch bars, and composite splints, has also been effective [15]. The patient should be given a soft diet.

2.1.1.1. Displacement of lower third molars

During surgery of impacted teeth, especially in cases of third molars, accidental displacements into the lingual, submandibular, pterygomandibular, infratemporal and maxillary sinus spaces may be seen. Lower third molars are more commonly displaced to one of anatomic spaces than other impacted teeth. Reasons for this complication may be of anatomic nature, angulation of the tooth, dehiscence in lingual cortical plate, excessive or uncontrolled force, lack of experience of the surgeon, or inadequate clinical and radiographic examinations [16,17]. Distolingual angulated lower third molars are the most prone to be displaced, comparing with other positions (Figs. 2,3) [18].

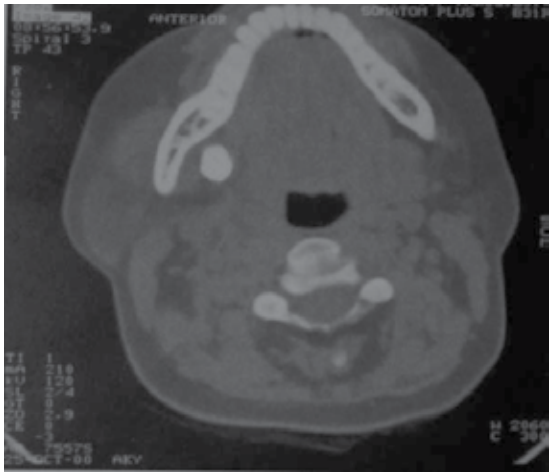

Figure 2. Axial CT scan shows the displaced lower right third molar in the sublingual space.

Figure 3. Coronal CT scan of the same patient shows the position of the displaced tooth.

The lingual plate is thin and easy to perforate ; these are the most important factors for displacement of lingually positioned lower third molars into the sublingual and submandibular spaces [16]. Placement of a retractor or finger lingually may prevent this mishap. Although in some cases displaced teeth might be asymptomatic [14], persistent pain and swallowing of adjacent anatomic spaces or trismus are the most common symptoms that may insue [9]. Surgical approach to displaced teeth may be achieved by intraoral incision only, but sometimes it may be necessary to do a combined intraoral and extraoral approach with a submandibular

http://dx.doi.org/10.5772/53400

incision in the neck [9,14,16]. A modified approach for removing fragments displaced lingually is to osteotomize the lingual plate and then approach the fragments [9].

The second most common location for displaced lower third molars is the pterygomandibular space [9]. The displaced tooth or fragments may lodge near the inferior attachment of the medial pterygoid muscle, which is difficult to diagnose without computed tomography(CT). Clinical symptoms include trismus and swelling on the lingual aspect of the mandibular angle [20]. Removal of displaced teeth is usually by intraoral approach, except in cases of deeply positioned teeth, when an extraoral approach is necessary [20].

Although rarely seen, lower third molars might be displaced into the lateral pharyngeal space [17-19]. Clinical symptoms usually include significant swelling and edema in the neck and cheek region including the retromolar region. In diagnosis of a displaced tooth or its fragment, panoramic, lateral, posteroanterior, occlusal radiographs and CT images can be useful [18]. If the fragment is displaced near the tonsils, tonsillectomy may have to be considered to remove the fragment [17].

2.1.1.2. Displacement of upper third molars

Removal of impacted maxillary third molars is a simple and easy procedure. Although rarely reported, displacement of either a root fragment, the crown, or the entire tooth into the infratemporal fossa and maxillary sinus space may occur [21-27]. Several factors that may predispose to tooth displacement into the infratemporal fossa including: Incorrect extraction technique, distolingual angulated tooth, decreased visibility during surgical removal or limited bone distal to the third molar [21]. To prevent a displacement of the tooth into the infratemporal fossa, use of a distal retractor is recommended. Displacement is usually through the periosteum adjacent to the lateral pterygoid plate and inferior to the lateral pterygoid muscle; the tooth may lodge between the zygomatic arch and lateral pterygoid plate [22]. It is difficult to be determined clinically without a new panoramic x-ray and CT scans. Clinical symptoms of a displaced tooth into the infratemporal fossa may vary from asymptomatic to symptomatic with swelling, pain, limitation of mandibular motion or even trismus, if fibrosis is present [23]. Some authors are in opinion that displaced teeth can migrate downwards into the oral cavity, allowing an easy surgical removal [21,23,24]. However, Gulbrandsen et al. [26] does not share this opinion because of fibrosis and anatomic boundaries of the infratemporal space. Therapeutic approaches to displaced teeth into the infratemporal fossa may include coronal, Gillies, Caldwell-Luc or resection of the coronoid process [21-27]. Some authors prefer to postpone the retrieval surgery for two weeks based until fibrous tissue formation immobilizes the tooth and the possibility that inferior displacement of the tooth may occur [25]. This delay also avoids the possible displacement of the tooth deeper to the skull base if an early retrieval attempt is performed [25]. The second most common displacement location of maxillary third molars is the maxillary antrum. It is important to note that the occurrence of this complication is in a close relation with excessive apical force during use of elevators and incorrect surgical technique [9]. Also deeply positioned upper third molars without formed roots are prone to this. Especially when the roots of the maxillary third molar are only half formed and the tooth is located in a more inferior position (Figs. 4-6).

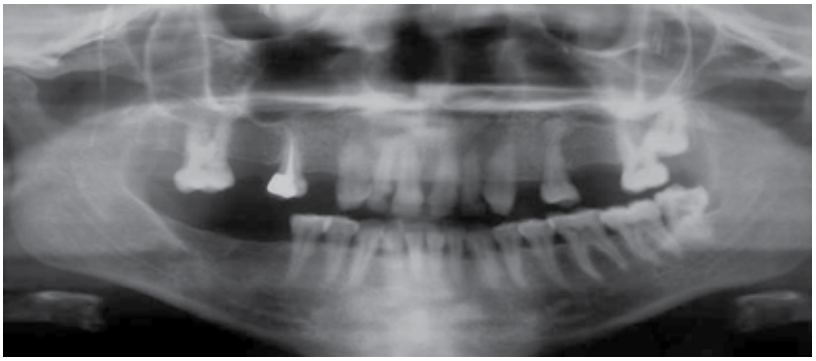

Figure 4. Preoperative panoramic radiograph shows impacted upper left third molar.

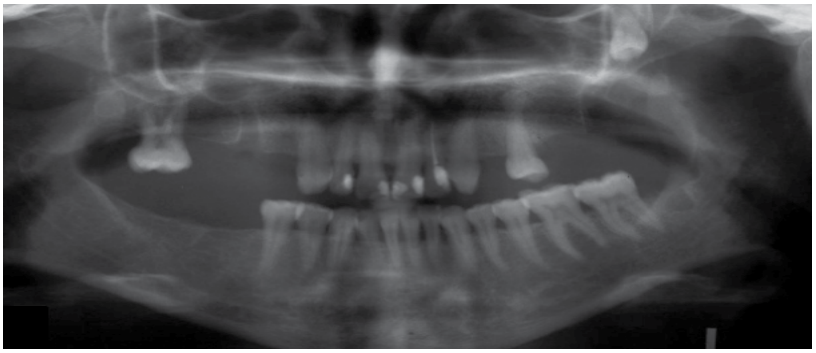

Figure 5. Control panoramic radiograph from the same patient, shows displacement of the tooth into the infratemporal space.

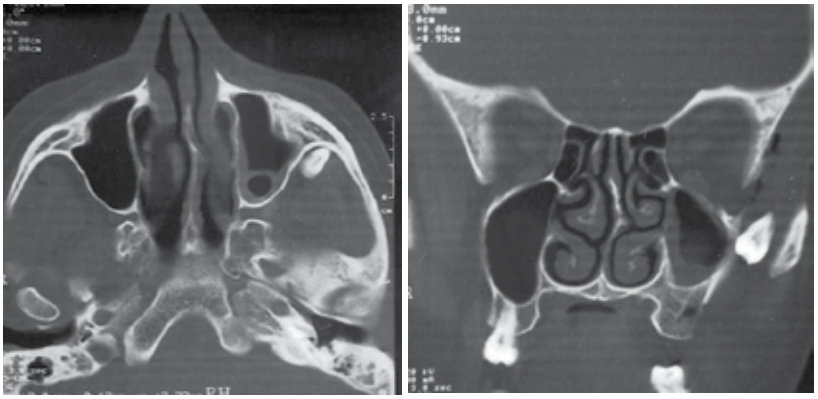

Figure 6. Axial CT (left) and coronal CT scan (right) shows the position of the displaced tooth in the infratemporal space.

http://dx.doi.org/10.5772/53400

The presence of a tooth, as a foreign body, inside the sinus may lead to complications such as infection, and thus its surgical removal is strongly recommended [15,27]. The management of removal foreign bodies from the maxillary sinus space includes a several methods such as Caldwell-Luc procedure and transnasal maxillary sinus surgery [27]. Access to the maxillary sinus is achieved through the nose via the ostium. The foreign body is captured and removed using an urological retrieval basket through the endoscopic working channel port. The advent of endoscopic techniques has made it the preferred choice, especially for patients with chronic sinusitis. In contrast to the endoscopic technique, which involves accessing the maxillary sinus via the nose, the Caldwell-Luc procedure involves gaining access to the maxillary sinus by a fenestration of the anterior lateral wall of the maxillary sinus or canine fossa.

One of the rare displacements of deeply and buccaly positioned maxillary third molars is into Bichat's fat pad. Incorrect use of the elevator may lead to a fracture of the buccal bone, which consists mostly of trabecular bone with a thin cortical layer, and push the tooth into the buccal space. The risk increases if the bone height buccal and/or distal to the molar is inadequate [28].

Impacted upper canines, or mesiodens, if deeply positioned, may be displaced into the nasal cavity during surgery [9].

Teeth and their fragments are not the only objects displaced into anatomic spaces. In the literature accidental displacement of a high-speed handpiece bur during third molar surgery has been described [29]. One of the reasons for this is attributed to improper excessive use of force during the surgery.

2.1.2. Soft tissue complications

Soft tissue complications during surgery of impacted teeth involves several injuries such as injuries of the neighbouring soft tissues including Bichat's fat pad, hemorrhage and hematoma formation or surgical emphysema [9].

Buccal fat also known as Bichat's fat pad is one of several encapsulated fat masses in the cheek located on both sides of the face between the buccinator muscle and the masseter, the zygomaticus major, and the zygomaticus minor [30]. Injury of the buccal fat pad is mostly the result of deep incision performed during upper third molar surgery (Fig. 7).

Hemorrhage is a common complication during and after surgery, and can be of either local or systemic nature. Systemic conditions include hemophilia A or B, von Willebrand's disease etc., thus good anamnesis is important in approach to maximize the patient's ability to form a stable clot [9,31]. Hemorrhage complicating third molar surgery has ranged from 0.2% to 5.8% [31]. It is of note that impacted mandibular third molars show a higher risk of hemorrhage compared to maxillary third molars [31,32]. Tooth position and inclination including patient age are important factors in development of this complication; thus deeply positioned and distoangular or horizontally- positioned lower third molars show a higher risk of hemorrhage. In the upper jaw high vertically- positioned third molars are most often implicated [33]. Old patients are more prone to this complication [32,33].

Figure 7. Prolapse of Bichat's fat pad during upper third molar surgery.

A hematoma is defined as a collection of blood in a virtual space. The size and spread of a hematoma depends on its vascular origin (capillary, venous or arterial) and the tissue into which it is bleeding (muscle, fat or interstitia) [33]. It stops expanding when the pressure of the pooling blood exceeds the vascular pressure of the bleeding site. However, in some cases hemorrhage and hematoma formation can occur into deeper spaces without immediate signs or symptoms. This complication often occurs during injection of local anesthesia without aspiration in the buccal vestibule [33]. In management of hematoma antibiotic therapy and follow up for next 2-5 days may be necessary [9].

Iatrogenic surgical subcutaneous emphysema another complication of third molar surgery occurs when an air-driven high-speed turbine is used for tooth sectioning; air is forced into the soft tissue through the reflected flap and invades the adjacent tissues [9,34]. Flap size for exposure of impacted tooth and bone may also play a role in subcutaneous emphysema development. For these reasons, a low-speed straight handpiece with copious sterile saline irrigation should be used during osteotomy and tooth separation. Clinical signs are local swelling, tenting of the skin and crepitation on palpation immediately after tooth sectioning. However, in some cases the symptoms develop after the surgery making the differential diagnosis of emphysema difficult. It is important to mentioned that air may pass through the masticatory space into the parapharyngeal and retropharyngeal areas, penetrating into the mediastinum [34].

2.1.3. Nerve injuries

Nerve injuries are mostly associated with removal of mandibular impacted teeth (third molars and premolars). The inferior alveolar nerve (IAN), lingual and mental nerves are the most prone to injury during anesthesia and surgical procedures [35-38]. However, available literature describes a case of facial nerve injury during upper third molar surgery [39].

Nerves can be damaged by traumatic, compressive or toxic injuries, which usually result in neuropraxia; however traumatic anatomic breakdown of the nerve may occur leading to

axonotmesis or neurotmesis. Neuropraxia is defined as physiological damage to the myelin sheath after transcient ischemia or metabolic disturbance characterized by transient impossibility to transmit action potentials. Whenever the causative factor is removed, the damage of the Schwann cells and the impairment of the myelin sheath can heal completely [40]. Axonotemesis is antomic breakdown in the axon without cutting the nerve trunk. It may be seen even in cases where the irritating factor (for example displaced rooth fragment near inferior alveolar nerve) is not removed. Complete breakdown of axons is defined as neurotmesis. Axonotmesis and neurotmesis can lead to subsequent paresthesia which may almost never resolve [40]. Neurosensory dysfunctions associated with nerve injuries includes anesthesia or numbness (loss of sensation, because of damage to a nerve or receptor), paresthesia (abnormal touch sensation, such as burning, prickling or formication, often in the absence of an external stimulus), dysesthesia or hypoesthesia. The incidence of temporary neurosensory disturbances after third molar surgery is more than 20% in the first 24 hours postoperatively and range from 0.3% to 5.3 % after six months [41]. The nerve damage depends of several factors such as type of anesthetic, state of eruption, depth of impaction, patient age, experience of the surgeon and type of lingual flap retraction [38,41]. Some studies suggest that the patient's age increases the risk of inferior alveolar nerve damage, but only in the presence of other preoperative risk factors such as the anatomic relation between the third molar roots and the mandibular canal [36,37]. Radiographically, diversion of the canal, darkening of the roots and interruptions of the“ white lines“ are indicative signs of close relation of third molars with the inferior alveolar canal [37]. Clinical symptoms of lingual nerve damage can vary from drooling, tongue biting, a burning sensation of the tongue, burns on the tongue from hot food and drinks, pain, change in speech pattern and change in taste perception of foods and drinks [38].

Lingual nerve damage is mostly seen when a lingual flap is reflected during third molar surgery; and because of this, placement of a lingual retractor such as Howarth's, Ward's, Maede's, Howell's or Rowe's retractor on the lingual bone subperiosteally is strongly recommended [35,38]. The lingual nerve can be within 1mm of the bone –essentially in the periosteum-on the lingual or distal aspect of the third molar [38].

In cases of maxillary third molar surgery, facial nerve paralysis may develop after local dental block anesthesia or even after tooth extraction [9,39]. Although the mechanism of development after dental procedures is unknown, there are three explanations of its occurrence such as: Direct trauma to the nerve from the needle, intraneural hematoma formation or compression and local anesthetic toxicity. However, a blast of air into the tissue with dissection through the fascial spaces mayalso cause facial nerve paralysis. Thus, forced air while cleaning an extraction site should not be used [39].

2.1.4. Bone complications

Bone complications associated with surgery of impacted teeth include mandibular or maxillary fractures, mostly associated with position of the impacted tooth or improper excessive use of force during the surgery. In some cases this complication must be predicted (Fig. 8).

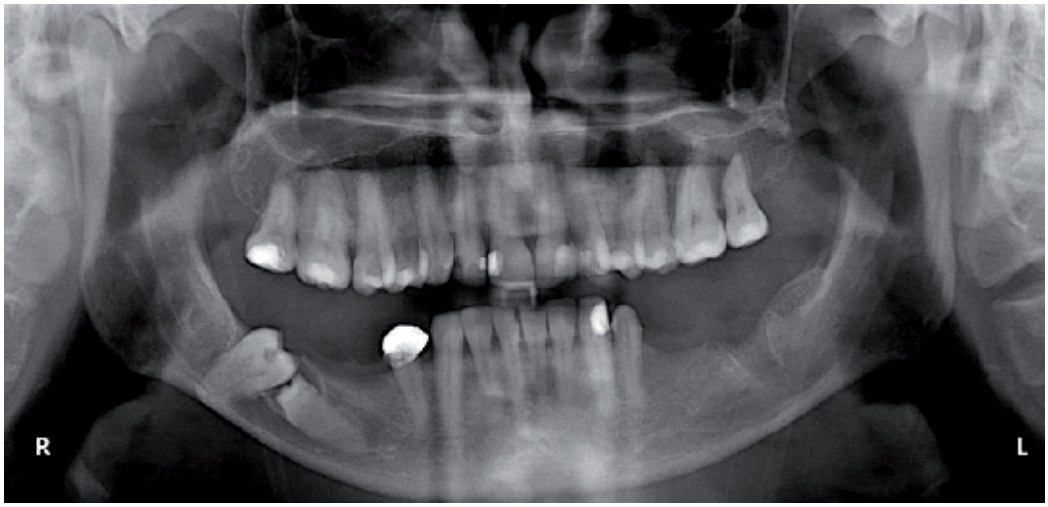

Figure 8. Panoramic radiograph shows deeply positioned lower right impacted teeth.

2.1.4.1. Mandibular fracture

One of the commonly seen complications associated with impacted lower wisdom teeth is the fracture of the mandibular angle. Angle fractures were the subjects of many studies in which the fracture risks and therapeutic approaches were evaluated [42-47]. Oikarinen and Malmström in their study, evaluating 1248 maxillofacial fractures, found that 17 % of the cases were the fractures of the mandibular angle [42]. Fractures may result from high force impact or stress and certain medical conditions that weaken the bones (osteoporosis, osteogenesis imperfecta, bone cysts and tumours etc.). Factors that play an important role in the angle fractures are the patient age, atrophic and sclerotic mandible, tooth position, dental ankylosis, abnormality of the number, shape and size of the roots, and presence of odontogenic lesions [9, 46].

Impacted teeth also play an important role, leading to weakness of the angular bone and mandibular fracture [9]. A study by Schön et al. have shown 43% of fractures were found in the mandibular angle, and in these fractures, 97% were associated with the presence of third mandibular molars [47].

Fractures develop during and after third molar surgery. The study of Wagner et al. [44] evaluated mandibular fractures following third molar removals and the results showed that 14 out of 17 fractures occurred postoperatively. Although in many cases no fracture was visible on radiographs during the primary investigation, a cracking noise reported later by the patient was the most important indication of a fracture. The authors also concluded that food chewing might play an important role in postoperatively fractures with suggestions for soft diet for up to 4 weeks after the operation [44]. The same authors also presented a case of mandibular fracture associated with osteomyelitis following third molar surgery [44]. In many cases depending on impacted tooth position and angulation ostectomy must be performed. This leads to weakening of the bone, mandating use of the less force by elevators and forceps for

http://dx.doi.org/10.5772/53400

removal of impacted teeth. An animal study by Reitzik et al. showed that less force is necessary to fracture mandibles with impacted third molars than mandibles with erupted third molars concluding that they significantly weaken the mandible (Figs. 9,10) [45].

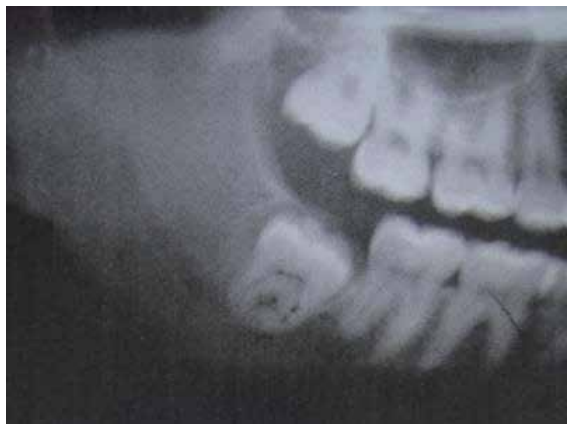

Figure 9. Preoperative radiograph of impacted lower right wisdom tooth.

Figure 10. Postoperative radiograph of the same patient shows a mandibible fracture in the area of the extracted tooth.

The risk of the angle fractures is higher if the presence of bone sclerosis, atrophy or dental ankylosis is noted; bone sclerosis increases with age, thus a lower incidence of fracture is seen in the younger patients. Wagner et al. state that the mandible angle fractures were mostly seen in the male patients at the mean age of forty [44].

2.1.4.2. Fractures of the maxillary tuberosity

Fracture of the maxillary tuberosity is complication associated with extraction of upper molars. There is an opinion that that a maxillary tuberosity is more predisposed to fracture, if the maxillary sinus has enlarged between the teeth and into the tuberosity creating thin bony walls [9]. Dental anomalies of the maxillary molars may also be contributory including; tooth fusion, tooth isolation, over eruption, ankylosis, hypercementosis, chronic periapical infection and roots which are widely divergent [9, 48]. This complications is rarely seen in cases of unerupted wisdom teeth, because it usually develops during extraction of first and second erupted molars.

Clinical signs and diagnosis of the maxillary tuberosity fractures include crunch or loud crack of bone breaking, sudden loosening of the tooth and bone together, with segment still attached to soft tissue and observable opening into the maxillary sinus (visible hole or "hollow" sound when suctioning the socket). Mobility of fracture fragments will confirm the maxillary tuberosity fracture, which will be diagnosed by radiographs [9]. However, in some cases the fracture may be asymptomatic, thus diagnosis is delayed. The patient may complain of sharp pain at the time of fracture, reflux of fluids from mouth to nose, sinus stuffiness, or presence of overt sinusitis. Management of maxillary tuberosity fracture include a few steps; the procedure of extraction must be stopped before inadvertent laceration of the soft tissue occurs. In cases of small fractures without sinus perforation, dissection of the fractured segment (including the tooth with small bony fragments) from gingiva and periosteum should be done and sutured. If sinus perforation (less than 3 to 4 mm) occurs, dissection of the segment and closure of the socket primarily and use of gelatin sponges (Gelfoam® sponge) to obturate the opening is recommended (Figs. 11,12) [9,48,49].

Figure 11. Panoramic radiograph of the patient after extraction of upper left first molar

http://dx.doi.org/10.5772/53400

Figure 12. Intraoral view of the same patient with fractured maxillary tuberosity.

In cases of a large bony fragment, it is recommended that the extraction be abandoned and surgical removal of the tooth be performed at a later date using root sectioning. The clinician that the dentist tries to detach the fractured tuberosity from the roots, or that the dentist stabilizes the mobile part(s) of the bone by means of a fixation technique for 4–6 weeks; after union surgical removal without the use of a forceps is done [49]. However, if the large segment includes multiple teeth, stabilization for 6 to 8 weeks by wiring to the adjacent teeth, allowing the segment to heal and then returning for the extraction in a more controlled fashion should be performed. Large bone fragments usually means large oro-antral communication (4 mm or greater). Its management may require more specialized procedures such as the mobilization of local flaps, autogenous or allogenic bone, or use of synthetic materials. The patient must be under antibiotics and decongestants therapy, following instructions such as avoiding nose blowing, smoking, etc., so the oro-antral communication does not reopen [9]. Consequences of maxillary tuberosity fractures include oro-antral fistula formation, sinusitis and poorer retention for eventual prostheses. Every patient undergoing maxillary molar extraction should be advised of the possibility of tuberosity fracture.

2.1.5. Maxillary sinus complications

Extraction of impacted maxillary teeth may lead to development of maxillary sinusitis and chronic oroantral fistula formation, if an oroantral communication is present. The size of the communication and the preoperative sinus status are important factors [15]. Incidence of perforating Schneiderin membrane during third molar surgery is not low. In a multicentric study Rothamel et al., reported a 13% rate mostly associated with intraoperative fracture of the root, higher degree of impaction and higher age of the patient [50]. Due to fact that many oral and maxillofacial surgeons in cases of diagnosed sinus mucosa perforations use a buccal sliding mucoperiostal flap to close the oroantral comunication, the incidence of oroantral fistula is not very high. Some authors suggest that the incidence is 0,06% [33].

2.1.6. Complications associated with surgical equipment

Complications associated with surgical equipment are mostly the result of metal fracturing because of effects of heat, torsion etc. Torsional strength and flexibility of the instruments, making them more prone to fracture under torsional stress. Improper excessive use of force during the surgery, may also lead to breaks. In cases of the instrument fracture, fragments should be immediately removed.

2.1.7. Swallowing and aspiration

Swallowing or aspiration of the extracted tooth or its fragments may be encountered. The incidence is around 0.004% [51] and sometimes it may be associated with the dental practitioner's lack of experience. The study of Obinata et al. [51] have showed that accidental ingestion was more common in dentists with careers shorter than 5 years. Accidental swallowing usually does not cause any clinical signs or symptoms thus most of the foreign objects are passed after passage through the gastrointestinal tract without complications within 7-10 days. [51,52]. However, if the patient develops symptoms of perforation, such as pain, vomiting, tenderness or abdominal guarding, and if objects remain lodged longer than 2 weeks, surgical intervention is required [51]. Ingested objects might be diagnosed by X-ray of the esophagus, the stomach and the intestine.

Comparing with swallowing, aspiration during tooth extraction is rarely seen and there is an opinion that the cough reflex is responsible for it. Right main-stem bronchus, due to fact that is more wider, shorter, and more vertical than the left main bronchus, is the most common location of aspirated foreign bodies. In cases of aspiration the patient should be immediately referred to a pulmonologist for identification and potential removal of the foreign body. If a foreign object is lost into the oropharynx, the patient should be placed in a reclining position, and encouraged to cough vigorously to secure the airway [51]. The Heimlich maneuver for relieve the laryngeal obstruction may be required. Symptoms such as choking, inspiratory stridor, and labored breathing are signs of airway obstruction [53].

For accurate diagnosis and to avoid unnecessary complications such as recurrent pneumonia, lung abscess, bronchiectasis and hemoptysis, a chest X-ray is necessary. It is important to note that elderly patients may show impairment of sensory and motor nerve responses, which could result in deterioration or dysfunction of the gag/cough reflex [51].

2.2. Complications after the impacted teeth surgery

Pain, swelling, trismus, hemorrhage and dry socket are the most common symptoms following removal of impacted teeth [15,54-58]. Morbidity increases with age of the patient, position and location of the tooth (for example, deeper impactions are more prone to develop complications), and duration of the surgical procedure [55]. Sequelae of the surgery have a direct effect on the quality of the patients life [56]. Sex of the patient may have also an influence on the complication development; a female patient due to the small size of their jaws, limited surgical field, hormonal status and more dense bone may make the surgery more difficult and traumatic [57,58].

http://dx.doi.org/10.5772/53400

2.2.1. Pain

Pain usually begins after the anesthesia from the procedure wears off and reaches peak levels 6 to 12 hours postoperatively [54,58]. It is usually moderate and of short duration for the first 24-48 hours [56]. Pathophysiology of pain may be explained by facts that following tissue injury or inflammation, there is a sequential release of mediators from mast cells, the vasculature and other cells. Histamine and serotonin appear first, followed shortly after by bradykinin and later prostaglandins. Bradykinin has been shown to produce pain in man when given intradermally, intraarterially or intraperitoneally and the hyperalgesia associated with prostaglandin is also due to its potentiation of Bradykinin [58,59].

For management use of different analgesics, including paracetamol and nonsteroidal antiinflammatory drugs, either alone or in combination with steroids and narcotics is necessary [54,56]. Many studies evaluated an influence of surgical techniques,closure techniques, use of drugs such as analgesics, corticosteroids, and antibiotics and laser application on pain intensity and duration.Some authors reported a correlation between operation time duration and analgesic use over the first 48 hours post surgery [58,60,61]. The longer duration of the surgery leads a longer tissue injury. In this way more mediators are released and therefore could be a reflection of the severity of pain, swelling and trismus [58]. In cases of secondary wound healing, the incidence of pain is lower, compared with primary wound healing [62-66].

2.2.2. Swelling and surgical edema

The swelling or surgical edema usually reaches a maximum level 2 to 3 days postoperatively and should subside by 4 days and resolve by 7 days [54]. Bello et al. [58] reported that risk of swelling might be associated with increasing age of the patient, while results of Akadiri et al. [62] showed that sex, weight, and body surface area are significant determinants of facial swelling. Mucoperiosteal flap designs may play also an important role in postoperative surgical edema development, thus those flaps which ensure a secondary healing, because of wound drainage, lead to lower incidence of swelling [63-66].

Patient comfort and postoperative swelling limitation may decrease by preoperative use of systemic corticosteroids and ice, postoperatively. Markiewicz et al. [67] showed that preoperative administration of corticosteroids produces a mild to moderate reduction in edema and improvement in range of motion after third molar surgery.

The role of the assistant during an operation should not be neglected in our opinion, thus, if the cheek or soft tissue retractors are manipulated with brute force, a transient barrier of normal lymph drainage may be breached causing unnecessary swelling.

2.2.3. Trismus

Trismus or difficulty opening the mouth, is often the result of surgical trauma and is secondary to masticatory muscle inflammation following lower third molar surgery. The patient may feel jaw stiffness with difficulty to brush, talk, or eat normally. The most common injured muscle is the medial pterygoid muscle, and reasons for its injury might include several factors such

as injury caused by a needle, swelling, hematoma, and inflammation. If the mouth stays open for too long, trismus may be expected [9]. So, its development is correlated with operation time [58,60,61]. In most cases, the trismus is temporary. Preoperative use of steroids may be helpful in reduction of trismus [54,57]. Postoperatively, patient mouth opening exercises should be performed leading to the preoperative level of function. Also, use of muscle relaxants such as chlorzoxazone (Parafon Forte tablets) is helpful in trismus management [58].

2.2.4. Infection (alveolar osteitis / alveolitis / dry socket, osteomyelitis)

Postoperative inflammatory conditions, including surgical site infections, abscess, alveolar osteitis or even osteomyelitis are complications after surgical removal of impacted teeth, with an estimated frequency of 1% to 30% [54]. Host bacteria within the operative sites, tooth position, operation procedure, surgical equipment and medical status of the patient are just some of many risk factors associated with these complications. One of important factor is flap design, especially in case of lower third molars. Although opinions are controversial, some authors [64] state that the modified triangular flap and primary wound healing leads to higher risk of the alveolar osteitis. Kirk et al. [66] felt alveolar osteitis was more common in cases of envelope flap and secondary wound healing. Alveolar osteitis or dry socket is complication characterized by postoperative pain in and around the extraction site, which increases in severity at any time between 1 and 3 days after the extraction accompanied by a partially or totally disintegrated blood clot within the alveolar socket with or without halitosis [67]. In some cases a blood clot fails to form in the socket. Bacteria and their products are mostly responsible for fibrinolysis of the blood clot, thus numerous studies examined influence of different antibacterial agents on dry socket development [68-71]. Results of the studies showed that pre- and postoperative rinsing the mouth with chlorhexidine [68-70] and application of chlorhexidine gel into the alveolus [71] may lead to decreasing incidence of dry socket. Metin et al.[70] concluded that the postoperative use of chlorhexidine is more effective.

Osteomyelitis, following surgery of impacted teeth is rarely seen.The disease is characterized by accumulation of an inflammatory exudate in the bony medullary cavity and beneath the periosteum, causing compression of the central (sinusoidal) and peripheral blood supply to the bone. Necrotic tissue promotes the proliferation of bacteria, which, without appropriate intervention, will result in incomplete healing and progression of disease [72]. Osteomyelitis is mostly associated with trauma (fracture related) and dentoalveolar infection [73]. However, it seems that atypic position of tooth may also play a role in osteomyelitis development [74]. Schoen et al. [73], state surgical extraction of impacted third molars in acute inflammation phase, may contribute to expansion of the abscess formation, thus, predisposing to osteomyelitis occurence. As we have mentioned before, fractures (mandibular and maxillary), may lead to osteomyelitis.

2.2.5. Bone or soft tissue hemorrhage

Postoperative bleeding is a risk in all surgical procedures including impacted teeth surgery. It can result from one or more causes. It is important to mention that in many cases intraoperative

http://dx.doi.org/10.5772/53400

bleeding may lead to postoperative bleeding and the risk of hemorrhage is lower in cases of primary wound healing by hermetically suturing the socket [63,75].

2.2.6. Delayed healing and wound dehiscence

Extraction of impacted teeth involves the manipulation of both soft and hard tissues, thus approach to the teeth means that a mucoperiosteal flap be created and osteotomy be performed. After extraction of the teeth the flap is usually placed in its previous position and sutured.This is primary wound healing. However, design of the flap may play an important role in wound healing [63-66,76,77]. Impacted lower third molars are the most common subjects of different studies including wound healing and flap designs. Different designs for the raising mucoperiosteal flaps to expose impacted lower third molars were presented by various authors, but the most common used designs are modified triangle flaps and the envelope / sulcular flap [65,66,76,77]. Clinical practitioners and authors are in opinion that modified triangle flaps give better results, being significantly less likely to develop dehiscence and thus secondary healing of the wound [63-66,76,77]. Jakse et al. [77] showed that the conventional sulcular flap design has a nearly 6-times higher risk of rupture of the primary wound closure than the modified triangular flap. Secondary healing might be responsible for longer periods of discomfort, continuous pain and possibly increased incidence of alveolar osteitis along with the loss of gingival attachment distal to the second molar [66]. However, secondary healing has some advantages such as reduction of swelling, pain and trismus after the surgery [63-66]. It is worth mention that every type of mucoperiosteal flap in the area of alveolar process that exposes the alveolar bone to the buccal cavity, may induce bone resorption, because of growing activity of osteoclasts [65].

3. Conclusion

The occurrence of the any complication mentioned in this chapter should be stated to the patient. In cases of the swallowing or aspiration of the extracted tooth patients must be referred immediately to an emergency department. Due to the fact that many of the mentioned complications may be of iatrogenic origin, the surgeon must be prepared for the mishaps and know how to manage them.

Author details

Çetin Kasapoğlu[2], Amila Brkić[1], Banu Gürkan-Köseoğlu[2] and Hülya Koçak-Berberoğlu[2]

1 Department of Oral Surgery, Faculty of Dentistry, Sarajevo University, Sarajevo, Bosnia and Herzegovina

2 Department of Oral and Maxillofacial Surgery, Faculty of Dentistry, Istanbul University, Istanbul, Turkey

References

[1] Jojić, B. & Perović, J.V.(1990). Oralna hirurgija (4th edition), Naučna knjiga, Beograd.

[2] Hupp, J.R, Ellis III, E. & Tucker, M.R.(2008) Contemporary oral and maxillofacial surgery (5th edition), Mosby Elsevier, St. Louis, Missouri.

[3] Alling C.C, Helfrick J.F & Alling R.D. (1993). Impacted Teeth. W.B. Saunders. Philadelphia.

[4] Ahlqwist, M. & Gröndahl, H.G.(1991). Prevalence of impacted teeth and associated pathology in middle- aged and older Swedish women. Community Dent Oral Epidemiol. Vol 19, No 2. pp. 116-119.

[5] Brown LH, Berkman S, Cohen D, Kaplan AL, Rosenberg M. A radiological study of the frequency and distribution of impacted teeth. J Dent Assoc S Afr. 1982 Sep;37(9):627-30.

[6] Knutsson, K., Brehmer, B., Lysell, L. & Rohlin, M. (1996). Pathoses associated with mandibular third molars subjected to removal. Oral Surg Oral Med Oral Pathol Oral Radiol and Endod. Vol 82, No 1. pp.10-7.

[7] Sasano, T., Kuribara, N., Iikubo, M., Yoshida A, et al. (2003). Influence of an angular position and degree of impaction of third molars on development of symptoms: Long term follow-up under good oral hygiene condition. Tohoku Journal of Experimental Medicine. Vol 200, No 2. pp.75-83.

[8] Gisakis, I.G, Palamidakis, F.D., Farmakis E.T.R, Kamberos, G. & Kamberos, S.(2011). Prevalence of impacted teeth in a Greek population. Journal of Investigative and Clinical Dentistry Vol 2, No2. pp.102–109.

[9] Kasapoğlu Ç, Gürkan-Köseoğlu B, Koçak-Berberoğlu H (2005). Gömük diŞler.Nobel ilaÇ. Istanbul

[10] Bataineh, A.B., Albashaireh, Z.S. & Hazza'a, A.M.(2002). The surgical removal of mandibular third molars: a study in decision making. Quintessence Int. Vol 33, No 8. pp. 613-617.

[11] Lysell, L. & Rohlin, M.(1998). A study of indications used for removal of the mandibular third molar. Int J Oral Maxillofac Surg. Vol 17, No 3. pp.161-164.

[12] Punwutikorn, J., Waikakul, A. & Ochareon, P.(1999). Symptoms of unerupted mandibular third molars. Oral Surg Oral Med Oral Pathol Oral Radiol Endod. Vol 87, No 3. pp.305-310.

[13] Ming-Yu Li (2012).Contemporary approach to Dental Caries.InTech, Croatia.

[14] Aznar-Arasa L, Figueiredo R, Gay-Escoda C. Iatrogenic displacement of lower third molar roots into the sublingual space: report of 6 cases. J Oral Maxillofac Surg. 2012 Feb;70(2):e107-15.

[15] Susarla SM, Blaeser BF, Magalnick D,Third molar surgery and associated complications. Oral Maxillofacial Surg Clin N Am 15 (2003) 177–186.

[16] Nusrath MA, Banks RJ. Unrecognised displacement of mandibular molar root into the submandibular space. Br Dent J. 2010 Sep 25;209(6):279-80.

[17] Esen E, Aydoğan LB, Akçali MC. Accidental displacement of an impacted mandibular third molar into the lateral pharyngeal space. J Oral Maxillofac Surg. 2000 Jan;58(1): 96-7.

[18] Ortakoğlu K, Okcu KM, Karasu HA, Günaydin Y. Accidental Displacement of Impacted Third Molar into Lateral Pharyngeal Space. Turk J Med Sci 32 (2002) 431-433.

[19] Ertas U, Yaruz MS, Tozoğlu S. Accidental third molar displacement into the lateral pharyngeal space. J Oral Maxillofac Surg. 2002 Oct;60(10):1217.

[20] Tumuluri V, Punnia-Moorthy A. Displacement of a mandibular third molar root fragment into the pterygomandibular space. Australian Dental Journal 2002; 47(1): 68-71.

[21] Patel M, Down K. Accidental displacement of impacted maxillary third molars. Br Dent J. 1994;177:57-9.

[22] Oberman M, Horowitz I, Ramon Y. Accidental displacement of impacted maxillary third molars. Int J Oral Maxillofac Surg.1986;15:756-8.

[23] Sverzut CE, Trivellato AE, Sverzut AT, de Matos FP, Kato RB. Removal of a maxillary third molar accidentally displaced into the infratemporal fossa via intraoral approach under local anesthesia: report of a case. J Oral Maxillofac Surg. 2009;67:1316-20.

[24] Dimitrakopoulos I, Papadaki M. Displacement of a maxillary third molar into the infratemporal fossa: case report. Quintessence Int. 2007;38:607-10.

[25] Gómez-Oliveira G, Arribas-García I, Alvarez-Flores M, Gregoire-Ferriol J, Martínez-Gimeno C. Delayed removal of a maxillary third molar from the infratemporal fossa. Med Oral Patol Oral Cir Bucal. 2010 May 1;15(3):e509-11.

[26] Gulbrandsen SR, Jackson IT, Turlington EG. Recovery of a maxillary third molar from the infratemporal space via a hemicoronal approach. J Oral Maxillofac Surg. 1987;45:279-82.

[27] Sverzut CE, Trivellato AE, Lopes LMF, Ferraz EP, Sverzut AT. Accidental Displacement of Impacted Maxillary Third Molar: A Case Report. Braz Dent J (2005) 16(2): 167-170.

[28] Kocaelli H, Balcioglu HA, Erdem TL. Displacement of a maxillary third molar into the buccal space: anatomical implications apropos of a case. Int J Oral Maxillofac Surg. 2011 Jun;40(6):650-3.

[29] Yalcin S, Aktas I, Emes Y, Atalay B. Accidental displacement of a high-speed handpiece bur during mandibular third molar surgery: a case report. Oral Surg Oral Med Oral Pathol Oral Radiol Endod 2008;105:e29-e31.

[30] Zhang Yan YP, Qi KM, Wang JQ, Liu, ZF. Anatomical structure of the buccal fat pad and its clinical adaptations". Plastic and reconstructive surgery 2002;109 (7): 2509–18; discussion 2519–20.

[31] Bouloux GF, Steed MB, Perciaccante VJ. Complications of third molar surgery. Oral Maxillofac Surg Clin North Am. 2007 Feb;19(1):117-28.

[32] Jensen S. Hemorrhage after oral surgery. An analysis of 103 cases. Oral Surg Oral Med Oral Pathol. 1974 Jan;37(1):2-16.

[33] Moghadam HG, Caminiti MF. Life-threatening hemorrhage after extraction of third molars:case report and management protocol. J Can Dent Assoc. 2002 Dec;68(11):670-4.

[34] Romeo U, Galanakis A,Lerario F, Daniele GM, Tenore G, Palaia G. Subcutaneous Emphysema During Third Molar Surgery: A Case Report. Braz Dent J.2011; 22(1): 83-86.

[35] Blackburn CW, Bramley PA. Lingual nerve damage associated with the removal of lower third molars.Br Dent J 1989;167:103-7.

[36] Valmaseda-Castellon E, Berini-Aytes L, Gay-Escoda C. Inferior alveolar nerve damage after lower third molar surgical extraction: a prospective study of 1117 surgical extractions. Oral Surg Oral Med Oral Pathol Oral Radiol Endod 2001; 92:377.

[37] Sanmarti-Garcia G, Valmaseda-Castellon E, Gay-Escoda C. Does computed tomography prevent inferior alveolar nerve injuries caused by lower third molar removal? J Oral Maxillofac Surg 2012 Jan;70(1):5-11.

[38] Pichler JW, Beirne OR. Lingual flap retraction and prevention of lingual nerve damage associated with third molar surgery: a systematic review of the literature. Oral Surg Oral Med Oral Pathol Oral Radiol Endod. 2001 Apr;91(4):395-401.

[39] Cakarer S, Can T, Cankaya B, Erdem MA, Yazici S, Ayintap E, Özden AV, Keskin C. Peripheral facial nerve paralysis after upper third molar extraction. J Craniofac Surg. 2010 Nov;21(6):1825-7.

[40] Giuliani M, Lajolo C, Deli G, Silveri C. Inferior alveolar nerve paresthesia caused by endodontic pathosis: a case report and review of the literature. Oral Surg Oral Med Oral Pathol Oral Radiol Endod. 2001 Dec;92(6):670-4.

[41] de Beukelaer JG, Smeele LE, van Ginkel FC. Is short term neurosensory testing after removal of mandibular third molars efficacious? Oral Surg Oral Med Oral Pathol Oral Radiol Endod. 1998 Apr;85(4):366-70.

[42] Oikarinen VJ, Malmström M. Jaw fractures. Suom Hammaslaak Toim. 1969;65(1): 95-111.

[43] Wagner KW, Otten JE, Schoen R, Schmelzeisen R. Pathological mandibular fractures following third molar removal. Int J Oral Maxillofac Surg. 2005 Oct;34(7):722-6.

[44] Wagner KW, Schoen R, Wongchuensoontorn C, Schmelzeisen R. Complicated late mandibular fracture following third molar removal. Quintessence Int. 2007 Jan;38(1): 63-5.

[45] Reitzik M, Lownie JF, Cleaton-jones P, Austin J. Experimental fractures of monkey mandibles. Int J Oral Surg. 1978 Apr;7(2):100-3.

[46] Cankaya AB, Erdem MA, Cakarer S, Cifter M, Oral CK. Iatrogenic mandibular fracture associated with third molar removal. Int J Med Sci. 2011;8(7):547-53.

[47] 47. Schön R, Roveda SIL, Carter B. Mandibular fractures in Townsville, Australia: incidence, aetiology and treatment using the 2.0 AO/ASIF miniplate system. British Journal of Oral and Maxillofacial Surgery 2001; 39: 145-8.

[48] Shah N, Bridgman JB. An extraction complicated by lateral and medial pterygoid tethering of a fractured maxillarytuberosity. Br Dent J. 2005;198(9):543-4.

[49] Bruno Ramos Chrcanovic, Belini Freire-Maia. Considerations of maxillary tuberosity fractures during extraction of upper molars: a literature review. Dental Traumatology. 2011; 27(5); 393-398.

[50] Rothamel D, Wahl G, d'Hoedt B, Nentwig GH, Schwarz F, Becker J. Incidence and predictive factors for perforation of the maxillary antrum in operations to remove upper wisdom teeth: prospective multicentre study. Br J Oral Maxillofac Surg. 2007 Jul; 45(5):387-91.

[51] Obinata K, Satoh T, Towfik AM, Nakamura M. An investigation of accidental ingestion during dental procedures. J Oral Sci. 2011 Dec;53(4):495-500.

[52] Hisanaga R, Hagita K, Nojima K, Katakura A, Morinaga K, Ichinohe T, Konomi R, Takahashi T, Takano N, Inoue T (2010) Survey of accidental ingestion and aspiration at Tokyo Dental College Chiba Hospital. Bull Tokyo Dent Coll 51, 95-101.

[53] Milton TM, Hearing SD, Ireland AJ (2001) Ingested foreign bodies associated with orthodontic treatment: report of three cases and review of ingestion/ aspiration incident management. Br Dent J 190, 592-596.

[54] Susarla SM, Sharaf B, Dodson TB. Do antibiotics reduce the frequency of surgical site infections after impacted mandibular third molar surgery? Oral Maxillofac Surg Clin North Am. 2011 Nov;23(4):541-6.

[55] Baqain ZH, Karaky AA, Sawair F, Khraisat A, Duaibis R, Rajab LD. Frequency estimates and risk factors for postoperative morbidity after third molar removal: a prospective cohort study. J Oral Maxillofac Surg. 2008 Nov;66(11):2276-83.

[56] Osunde OD, Adebola RA, Omeje UK. Management of inflammatory complications in third molar surgery: a review of the literature. Afr Health Sci. 2011 Sep;11(3):530-7.

[57] Malkawi Z, Al-Omiri MK, Khraisat A. Risk indicators of postoperative complications following surgical extraction of lower third molars. Med Princ Pract. 2011;20(4):321-5.

[58] Bello SA, Adeyemo WL, Bamgbose BO, Obi EV, Adeyinka AA. Effect of age, impaction types and operative time on inflammatory tissue reactions following lowerthird molar surgery. Head Face Med. 2011 Apr 28;7:8.

[59] Cotran RS, Kumar V, Collins T. Robbins Pathologic basis of disease. 6. W.B. Sanders Company, Philadephia; 1999. pp. 50–87.

[60] Pederson A. Inter-relationship of complaints after removal of impacted third molars. Int J Oral Maxillofac Surg. 1985;14:241–247.

[61] Garcia GA, Sampedro FH, Rey JH, Torreira MG. Trismus and pain after removal of impacted lower third molars. J Oral Maxillofac Surg. 1997;55:1223–1226.

[62] Akadiri OA, Okoje VN, Arotiba JT. Identification of risk factors for short-term morbidity in third molar surgery. Odontostomatol Trop. 2008 Dec;31(124):5-10.

[63] Khande K, Saluja H, Mahindra U. Primary and secondary closure of the surgical wound after removal of impacted mandibular third molars. J Maxillofac Oral Surg. 2011 Jun; 10(2):112-7.

[64] Koyuncu BO, Cetingül E. Short-term clinical outcomes of two different flap techniques in impacted mandibular third molar surgery. Oral Surg Oral Med Oral Pathol Oral Radiol. 2012 Aug 23. [Epub ahead of print]

[65] Karaca I, Simşek S, Uğar D, Bozkaya S. Review of flap design influence on the health of the periodontium after mandibular third molar surgery. Oral Surg Oral Med Oral Pathol Oral Radiol Endod. 2007 Jul;104(1):18-23.

[66] Kirk DG, Liston PN, Tong DC, Love RM. Influence of two different flap designs on incidence of pain, swelling, trismus, and alveolar osteitis in the week following third molar surgery. Oral Surg Oral Med Oral Pathol Oral Radiol Endod. 2007 Jul;104(1):e1-6.

[67] Markiewicz MR, Brady MF, Ding EL, Dodson TB. Corticosteroids reduce postoperative morbidity after third molar surgery: a systematic review and meta-analysis. J Oral Maxillofac Surg. 2008 Sep;66(9):1881-94.

[68] Alpaslan GH, Yamalik MK. The effects of chlorzoxazone on postoperative trismus following lower third molar surgery. Ankara Univ Hekim Fak Derg. 1988 Sep;15(1): 29-33.

[69] Blum IR. Contemporary views on dry socket (alveolar osteitis). A clinical appraisal of the standardization, etiopathogenesis and management: a critical review. Int J Oral Maxillofac Surg. 2002;31:309–317.

[70] Sridhar V, Wali GG, Shyla HN. Evaluation of the perioperative use of 0.2% chlorhexidine gluconate for the prevention of alveolar osteitis after the extraction of impacted mandibular third molars: a clinical study. J Maxillofac Oral Surg. 2011 Jun;10(2):101-11.

[71] Larsen PE. The effect of a chlorhexidine rinse on the incidence of alveolar osteitis following the surgical removal of impacted mandibular third molars. J Oral Maxillofac Surg. 1991 Sep;49(9):932-7.

[72] Metin M, Tek M, Sener I. Comparison of two chlorhexidine rinse protocols on the incidence of alveolar osteitis following the surgical removal of impacted third molars. J Contemp Dent Pract. 2006 May 1;7(2):79-86.

[73] Babar A, Ibrahim MW, Baig NJ, Shah I, Amin E. Efficacy of intra-alveolar chlorhexidine gel in reducing frequency of alveolar osteitis in mandibular third molar surgery. J Coll Physicians Surg Pak. 2012 Feb;22(2):91-4.

[74] Humber CC, Albilia JB, Rittenberg B. Chronic osteomyelitis following an uncomplicated dental extraction. J Can Dent Assoc. 2011;77:b98.

[75] Schoen R, Suarez-Cunqueiro MM, Metzger MC, Schmelzeisen R. Osteomyelitis of the mandible following third molar surgery: a regrettable consequence in a healthy patient. Quintessence Int. 2009 May;40(5):351-4.

[76] Lambade P, Lambade D, Dolas RS, Virani N. Ectopic mandibular third molar leading to osteomyelitis of condyle: a case report with literature review. Oral Maxillofac Surg. 2012 Jul 31. [Epub ahead of print]

[77] Carrasco-Labra A, Brignardello-Petersen R, Yanine N, Araya I, Guyatt G. Secondary versus primary closure techniques for the prevention of postoperative complications following removal of impacted mandibular third molars: a systematic review and meta-analysis of randomized controlled trials. J Oral Maxillofac Surg. 2012 Aug; 70(8):e441-57.

[78] Rosa AL, Carneiro MG, Lavrador MA, Novaes AB Jr. Influence of flap design on periodontal healing of second molars after extraction of impacted mandibular third molars. Oral Surg Oral Med Oral Pathol Oral Radiol Endod. 2002 Apr;93(4):404-7.

[79] Jakse N, Bankaoglu V, Wimmer G, Eskici A, Pertl C. Primary wound healing after lower third molar surgery: evaluation of 2 different flap designs. Oral Surg Oral Med Oral Pathol Oral Radiol Endod. 2002 Jan;93(1):7-12.

Chapter 2

New Concepts in Impacted Third Molar Surgery

Mohammad Hosein Kalantar Motamedi and Farshid Kavandi

Additional information is available at the end of the chapter

http://dx.doi.org/10.5772/54648

1. Introduction

Surgery for removal of impacted third molar surgeries may be associated with several postoperative complications; these complications are more common in the mandible than in the maxilla; they may include bleeding, dry socket, nerve injury, delayed healing, periodontal pocketing, and infection. Many are preventable.[1] All third molars need not be removed independent of disease findings and patients need not unnecessarily have to accept adverse consequences associated with the surgery risks and discomforts in the absence of pain, radiographic findings of pathology, and or marked clinical evidence of disease. However, when surgery is indicated several new concepts and techniques presented in this chapter can prevent and or manage some of the common postoperative sequel of impacted third molar surgery.[1,2]

2. Assessments for removal of impacted third molars

2.1. Arch-space tooth-size discrepancy

The most significant variable associated with eruption seems to be the retromolar space available for the tooth. [3] The accuracy of prediction has improved remarkably, with the highest values being 97%. Thus, when there is no space available for eruption the tooth should be removed (Fig.1).

2.2. Other factors for preventive removal

The Finnish Current Care guideline indicates three distinct groups of teeth for preventive removal: horizontal teeth, root ends growing close to the nerve, and partially erupted vertical teeth. On average, this preventive group comprises 25% of lower 3rd molars. Thus, instead of

INTECH
open science | open minds

© 2013 Motamedi and Kavandi; licensee InTech. This is a paper distributed under the terms of the Creative Commons Attribution License (http://creativecommons.org/licenses/by/3.0), which permits unrestricted use, distribution, and reproduction in any medium, provided the original work is properly cited.

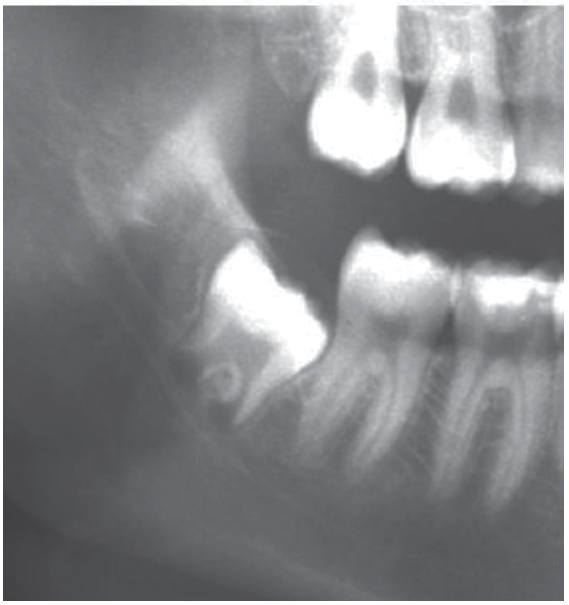

Figure 1. Lack of space for eruption of impacted lower 3rd molar.

removing all third molars preventively, actually, it is necessary to remove only one fourth of third molars. The remaining may be treated later according to signs and symptoms. [3] Dental caries, tooth displacement and pathology are obvious indications for removal of third molars (Fig.2).

2.3. Presurgical assessment

Surgical procedures should be planned and executed according to scientific evidence. Estimating possible difficulty in the removal of third molars is a constant challenge for surgeons. [4] There is a highly significant correlation between the level of difficulty for surgical removal of lower third molars (predicted by the anatomic variables) and postoperative inflammatory complications.[5]

2.3.1. Weight

Surgical difficulty in overweight patients is attributed to the herniation of the cheek intraorally making retraction difficult. [4]

2.3.2. Depth of impaction

The results of Tong Lim et al showed that the depth of impaction of the maxillary wisdom tooth serves as a factor for greater possibility of an oroantral perforation.; a deeper impaction requires a larger amount of bone removal to deliver the third molar and, hence, is more likely to cause damage to the sinus lining during the operative procedure. A cone-beam computed

http://dx.doi.org/10.5772/54648

Figure 2. Carious lesion of the 2nd molar and pulpal exposure caused by impacted lower 3rd molar.

tomogram may be a better method to measure the proximity of the roots of the maxillary third molar to the sinus floor.[6]

2.3.3. Pathological processes

Complications are inevitable when the tooth is associated with a pathological process and must be removed. In these cases, bone resorption reduces the degree of difficulty; unless the pathology is an associated odontoma or cementoblastoma etc. [7] Complications occur in nearly half of the cases with associated pericoronitis which includes alveolitis, infection, etc.

2.3.4. Orientation of the impaction

Deviation from the vertical alignment of the tooth increases surgical difficulty. Greater difficulty occurs in cases classified as C3 category (Pell and Gregory classification). [4]

2.3.5. Root morphology and number of roots

Root morphology and number of roots are significantly associated with difficulty. Limited root development (tooth germ) allows rotation of the tooth around its axis, commonly requiring sectioning and time-consuming surgery of more than 30 minutes. Teeth with complete and divergent roots also prove more difficult to remove. Such teeth are often treated with sectioning before any mobility is attained because the fragmentation reduces the retention areas and facilitates removal with greater preservation of the adjacent bone and anatomical structures.[4]

2.3.6. Proximity of the alveolar nerve

The relation between the mandibular canal and tooth roots should be considered during extractions. However, radiographic images do not provide the necessary reliability.

The hypothesis is that when the white line of the mandibular canal is absent or indistinct where the canal intersects the tooth root, or divergence of the canal or darkening of the root at that location the mandibular canal is possibly entrapped.[8] Cone beam CT is indicated.

2.3.7. Proximity between the second and third molars

Closeness and proximity between the second and third molars makes surgery more difficult. The space between the distal surface of the second molar and mesial surface of the third molar and the periodontal ligament space was significantly associated with surgical difficulty. Contact of the root of the second molar and the crown of the impacted third molar require sectioning and special surgical technique.[1,2,4]

2.3.8. Angulation of the third molar

According to Chang, the greater the angulation of the third molar, the more difficult it is to remove and to maintain oral hygiene. During a multivariate logistical regression analysis, angulation was continually an important factor. Tooth angulation can be a precise indicator for the prophylactic removal of partially erupted mandibular third molars. The partially erupted third molar is also a predisposing factor to food impaction and in the development of distal caries on the mandibular second molar as well (Fig. 3). [6]

Figure 3. Angulated impacted lower 3rd molar causing carious lesion of the 2nd molar and predisposing to food impaction and periodontal pocket formation.

2.3.9. Existing periodontal pocket

There is evidence that supports removing third molars when at least 1 pocket depth of at least 4mm is measured in the third molar region in young adults around an asymptomatic third

molar, or distal of an adjacent second molar because of an association with a decreased odds of periodontal disease progressing over time in teeth more anterior in the mouth. The removal of mandibular third molars appears to significantly improve the periodontal status on the distal root of second molars, positively affecting overall periodontal health.[2] Although the prevention of progression of periodontal disease, or the elimination of periodontal disease is often given as justification for third molar removal. Nevertheless, there are occasions when removal of third molars can either create or exacerbate periodontal problems on the distal aspect of the lower second molar.[9] The most important predictor of the final bone level behind the second molar was the bone level on the distal aspect of the second molar on completion of removal of the third molar [9]; when there is no distal septum bone formation may be hampered.

2.3.10. Preoperative NSAIDS and analgesic agents

Studies evaluating the preoperative administration of NSAIDs and pain in oral surgery have been published. The beneficial effects of the preoperative administration of piroxicam, ketorolac, meloxicam, parecoxib and dexamethasone with rofecoxib have been documented. Some authors found a lower consumption of rescue analgesics and a delay in the onset of pain when the NSAIDs were administered before the surgical procedure. [10]

The maximum plasma peak (MMP) after the administration of 400 mg of ibuprofen occurs after 32 min. It is also known that the maximum concentrations of prostaglandins around damaged tissues are obtained approximately 1 h after injury. Another important aspect that has to be taken into account is to obtain MMP of the NSAIDs before the local anesthetic wears off. This is an important consideration and seems to support the use of long-lasting anesthetics to increase the residual analgesic effect.[10]

2.3.11. Radiographic evaluations

More attention should be given to optimize the use of CBCT to cover difficult cases that may give rise to complications.[11,12] Although CT scan is the gold standard to disclose a close relation between the lower third molar roots and the mandibular canal, for several reasons, including cost and radiation dose, it is not usually the first radiographic technique of choice. IAN injury after third molar extraction is normally caused by close anatomic proximity or by the surgical technique. If the cause of injury is the anatomic relation, then CT would be useful only for diagnostic purposes, i.e. to warn the patient of an increased risk with a higher positive predictive value than with panoramic radiography alone. However, the value and accuracy of this prediction is questionable, because if the cause of the injury is the surgical technique, then CT would help to minimize the risk of IAN injury only if it changed the way the surgeon operates, e.g. planning tooth sectioning if the IAN has a course between the roots or minimizing buccal ostectomy if the IAN has a buccal position close to the crown of the third molar impaction.[13]

2.3.12. Age

According to a number of authors, age is the most consistent factor in the determination of surgical difficulty, considering the differences in bone density associated with age. Moreover, the increase in age is associated with complete root formation, which may be related to the higher rate of complications among patients over 25 years of age compared with younger patients. Bone density of the tooth has been described as important indicator for the prediction of surgical difficulty. Studies indicate that as one becomes older, third molars become more difficult to remove, may take longer to remove, and may result in an increased risk for complications associated with removal. The age of 25 years appears in many studies to be a critical time after which complications increase more rapidly. There are no studies indicating a decrease in complications with increasing age. It also appears that recovery from complications is more prolonged and is less predictable and less complete with increasing age. As such, many clinicians recommend removal of 3rd molars in young adults. [14]

2.3.13. Temporomandibular joint problems

Removal of third molars can cause or exacerbate pre-existing temporomandibular joint disorders (TMD), particularly internal derangements of the tmj. The relationship, however, is indirect because third molars are often removed in an age group of patients where internal derangements of the TMJ are relatively common. One study of 60 third molar referrals showed that 13% of patients having third molars removed had pre-existing TMJ dysfunction. A prospective case-control study involving 72 patients showed that, on examination of patients with TMJ dysfunction, there is either no increase or a statistically insignificantly higher instance of TMJ dysfunction in those who have undergone third molar removal versus those who have not. A case-control study involving 2217 patients with a history of third molar removal and 2217 subjects without third molar removal also showed an insignificant increase of TMJ symptoms in those with a history of third molar removal. Therefore it appears that third molar removal is not a significant factor in the initiation or exacerbation of TMJ problems. However, a longitudinal study of 34491,15-year-old patients followed up for 5 years indicated that 23% of all TMJ dysfunction in this group might be due to third molar removal[15] Excessive mouth opening especially for a long period of time and use of excessive force upon extraction and failure to support the jaw may predispose to TMD.

2.3.14. Nerve involvement

Case studies have shown that the inferior alveolar nerve may be involved after third molar removal in anywhere from 0.5% to 5% of lower third molar removals. In many cases this can be predicted preoperatively from panoramic radiographs and, more recently, from cone beam computed tomography scanning, showing the relationship of the inferior alveolar nerve to the roots of the lower third molars. Lingual nerve involvement associated with third molar removal occurs less frequently but may be more problematic for patients. Estimates of the incidence of lingual nerve involvement from case series show an incidence of between 0.2% and 2% of lower third molar removals.[9]

Narrowing of the IAN canal increases the risk for postoperative IAN impairment. This information is new to the literature and the evidence is strong.

The absence of cancellous bone between the nerve and the tooth, in other words, direct contact between the 2 structures, is another independent factor.

Thus IAN position has a close association with the 2 independent predictors of injury, namely direct contact and narrowing of the IAN canal.[15]

Fully developed roots increase the risk for postoperative nerve impairment. This was expected because fully developed roots are likely to have closer contact to the IAN bundle. This is another argument for early removal of wisdom teeth.[15]

Patients meeting any of the known criteria:

Diversion of the IAN canal,

Darkening of the root where the IAN canal crosses the root, and

Interruption of the white line bordering the IAN canal where it crosses the root, may benefit from CBCT or 3D imaging. Moreover, the legal demand for more detailed information on the incidence of potential complications is met and automatically documented by the imaging study.[15]

Kim showed that age, impaction depth, and the 5 radiographic superimposition signs—darkening of the roots, deflection of the roots, narrowing of the roots, dark and bifid apex of the roots, and narrowing of the canal—were significantly associated with neurosensory deficits of the IAN after mandibular third molar extraction (Fig. 4).[16]

Doucet showed that removing mandibular third molars at the time of the BSSO procedure will minimize postoperative neurosensory disturbance of the IAN by decreasing its entrapment and manipulation. [17]

2.3.15. Coronectomy as an option

Coronectomy was developed as a relatively new preventive method to decrease the prevalence of IAN injury compared with the conventional total removal of the lower third molar. The crown of the impacted lower third molar is often the cause of the food impaction, dental caries, or pericoronitis that troubles the patients. By removing the crown and leaving the root(s) behind, the problems are solved and the risk of an IAN deficit is obviated.[18]

Coronectomy is performed when contact between the mandibular third molar apex and the inferior alveolar nerve is suspected. The efficacy of coronectomy compared with conventional tooth extraction has been recognized in recent years. The absence of transmission images indicative of periapical lesions and the presence of bone covering more than 99.2% of the retained roots showed a safe postoperative course at the 1- year follow-up after coronectomy. [19] It is stated that retained roots after coronectomy in the lower third molars produce no complications in terms of infection, pain, or the development of pathologies within the first 3 years. Root eruption can occur in a very small percentage of patients and may require reoperation to remove the root.[18]

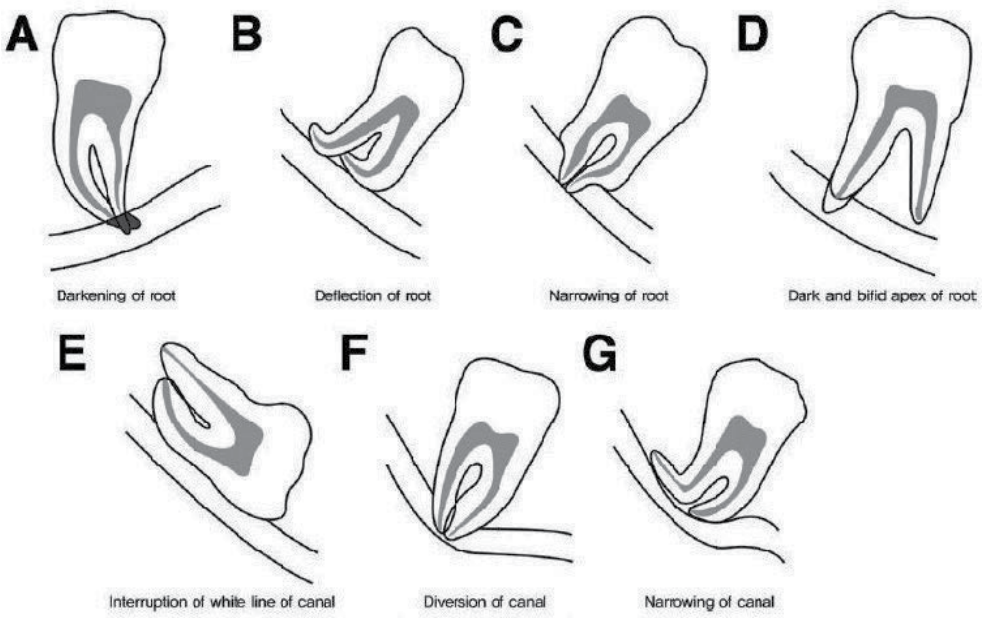

Figure 4. Signs significantly associated with neurosensory deficits of the IAN after mandibular third molar extraction.

In the rare event if after coronectomy, the retained roots erupt into the oral cavity and become infected. In such cases, it is appropriate to extract the retained roots after they move away from the mandibular canal (Fig. 5.).

2.3.16. Sinus communication

This is a complication encountered with upper 3rd molars; most communications close spontaneously without surgery. Chiapasco in a retrospective study of complications of 500 impacted maxillary third molars, reported that a sinus communication was seen in 0.8% ; none required surgery. A prospective cohort study of 684 patients indicated a sinus communication in 13% of patients following 3rd molar surgery. Another prospective cohort study of 389 upper third molar extractions showed a sinus perforation rate of 5.1%, with female patients, older patients, and more complicated extractions having a higher incidence.[9]

2.3.17. Flap design

Baqain showed probing depth was significantly greater with envelope flaps in the early postoperative period [20]

Erdogan et al. demonstrated a lower pain score. Alveolar osteitis was not reported in either group, whereas a previous randomized, prospective split mouth study demonstrated a higher

http://dx.doi.org/10.5772/54648

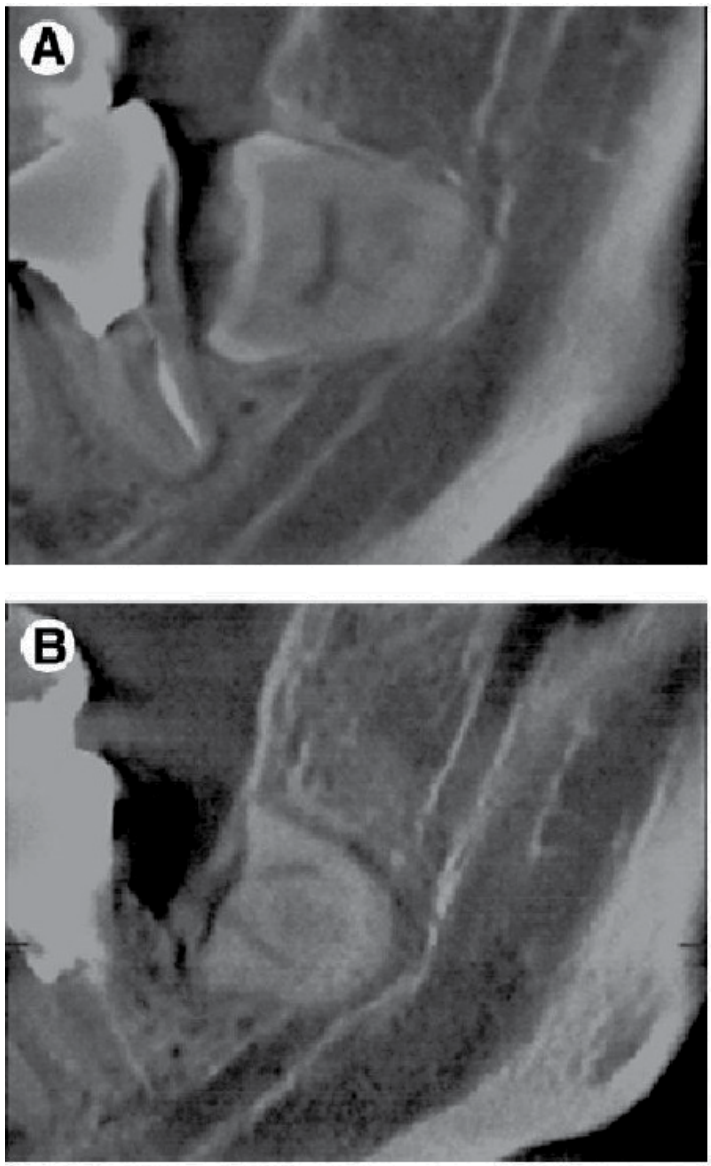

Figure 5. A. Coronectomy of an impacted 3rd molar with nerve involvement. B. One year later shows bone formation as well as root migration.

incidence of alveolar osteitis in the envelope flap group, even though the difference was not statistically significant.[20]This was also documented by Haraji.[21]

Chaves et al. in their study on young subjects with good oral hygiene showed that flap design, envelope or three cornered flaps, had no influence on periodontal health postoperatively; both caused shallow pocket depth. [20]

2.3.18. Periodontal defect

Periodontal defects have been a frequent occurrence postoperatively at the distal aspect of the mandibular second molar after the removal of impacted third molars. Among several studies, it was shown that 43.3% of the cases result in probing depths of 7mm or greater 2 years after removal of the third molar.[22]

Pocket formation behind the second molar after surgical removal of an impacted mandibular third molar is an occasional postoperative complication that cannot always be

Prevented (especially when present preoperatively). This complication may necessitate further surgical intervention to eliminate the pocket or to regenerate bone. Such interventions are fraught with difficulty and limited success.

However, in some cases that have fully bone-impacted third molar there is no clinical or radiographic evidence of a pocket distal to mandibular second molar even though the crown of the impacted tooth is in close contact with the distal root of the second molar. Since there is no distoproximal bone below the alveolar crest behind the second molar. Removal of this overlying alveolar crestal bone (to remove the impaction) may cause a deep bone defect distal to the second molar extending down to the base of the extraction socket. Thus, the alveolar crest must be preserved (Fig. 6).

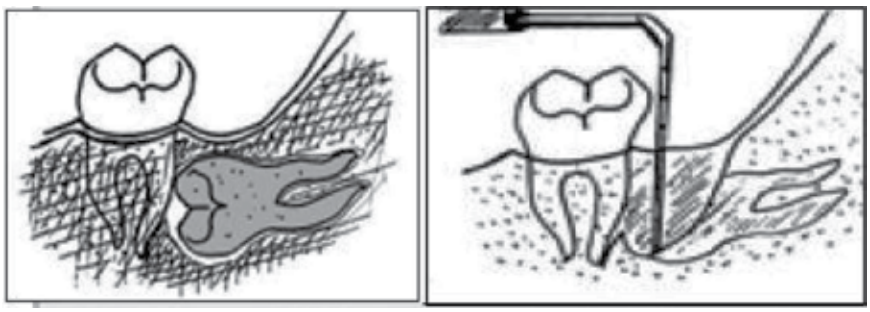

Figure 6. A. Fully bone impacted lower 3rd molar (crown to root impaction) with no pocket preoperatively. B. Resulting pocket if the crestal bone is removed to take out the impaction.

In 1999, Motamedi popularized a technique to prevent this occurrence in such cases and coined the term "buccal window".

Technique. After-full thickness mucoperiosteal flap reflection and bone exposure, bone removal is started in the lateral cortex 2 to 3 mm below the bony crest using an electric surgical handpiece and a round surgical bur. An oval "window" of buccal bone is removed over the lateral aspect of the crown of the impacted wisdom tooth. The anterior part of the buccal window should be no closer than 1 to 2 mm from the distal root of the second molar (to prevent iatrogenic root damage). After the crown and cervical part of the impacted tooth and the upper third of its roots have been exposed, the tooth is sectioned vertically at the cementoenamel junction using a rose or fissure bur; the gap created in this way should be sufficient to

http://dx.doi.org/10.5772/54648

accommodate movement of the sectioned crown. However, to prevent damage to the lingual or the alveolar nerve, the tooth is not sectioned completely. A straight elevator is placed in the groove to separate the crown from its roots. The crown is then sectioned horizontally and delivered buccally through the window (in pieces) using a hemostat. Next, the roots are sectioned at the bifurcation and removed. After removal of the dental follicle, the flap is sutured in place.[1,2 23] This technique ensures that no postoperative pocket is formed.

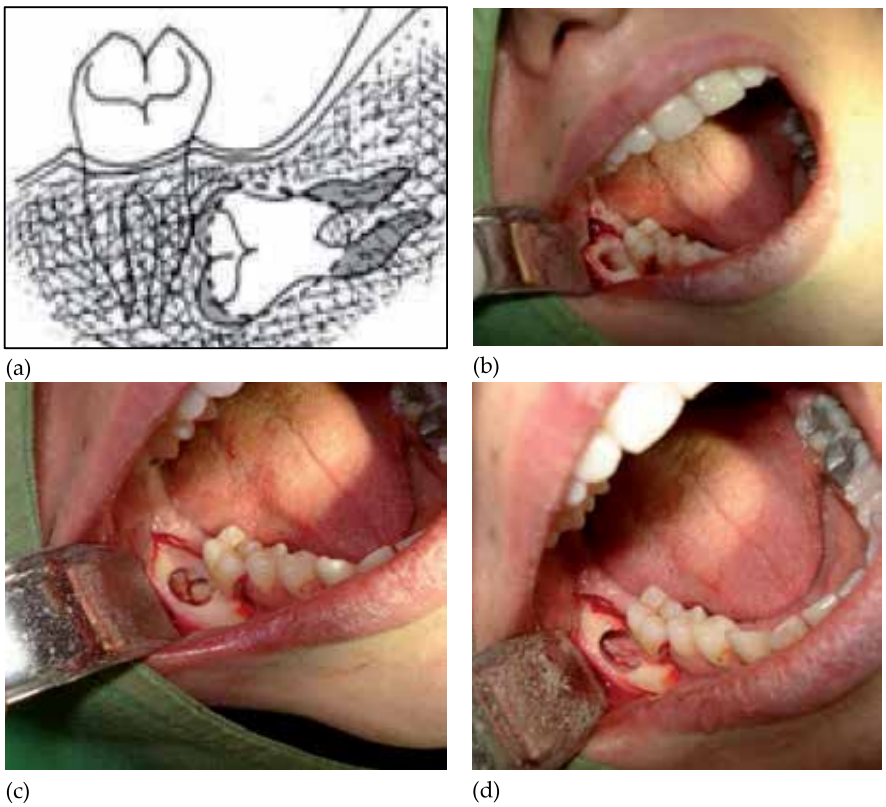

Figure 7. A. An oval "window" of buccal bone is removed over the lateral aspect of the crown of the impacted wisdom tooth. The anterior part of the buccal window should be no closer than 1 to 2 mm from the distal root of the second molar (to prevent iatrogenic root damage). B. A buccal window has been created over the crown of the impaction. C. After the crown and cervical part of the impacted tooth and the upper third of its roots have been exposed, the tooth is sectioned vertically at the cementoenamel junction using a rose or fissure bur; the gap created in this way should be sufficient to accommodate movement of the sectioned crown. D. The tooth has been removed and the crest preserved.

2.4. Damage to the gingiva

Iatrogenic gingival damage is more apt to occur in young adolescents with tooth-sized arch-length discrepancies who have been referred for removal of impacted mandibular third molars for orthodontics. In these patients, the mandibular arches are often underdeveloped, and the

surgeon often finds the second molar only partially erupted. The distal part of this tooth is often adjacent to the anterior border of the ascending ramus with almost no distobuccal collar of keratinized gingival clinically evident. The mandibular third molar is often incompletely formed and impacted in the ramus with no retromolar pad. Only a thin band of keratinized gingival (often less than 1 mm in width) may be noticeable on the buccal aspect of the lower 2nd molar tooth. In such cases, flap reflection and removal of the impacted mandibular third molar occasionally lead to destruction of what little attached gingiva was present before surgery. Disruption of the gingival attachments of the second molar and destruction of the fragile attached gingival collar will cause an immediate loss in vestibular depth because of the pull of the buccinator muscle insertions on the flap. This often prevents cervical reattachment of the gingiva to the second molar, hindering healing of the remaining nonkeratinized gingiva, which leads to plaque retention, inflammation, and pocket formation, requiring periodontal therapy secondarily.[24]

Current techniques to regenerate or graft keratinized gingiva in the distobuccal region of the mandible are fraught with difficulty. The anatomy of the posterior mandible with the closeness of the external oblique ridge to the cervix of the second molar and the shallow sometimes nonexistent, buccal vestibule in this area make preparation of a bed for grafting very difficult. Additionally, after the mucoperiosteum has been reflected, the buccinator muscle insertions pull upward on the flap, preventing stabilization of free grafts.[24] In 2000 Motamedi presented the "lingual flap" technique to restore attached gingiva around second molar.

Technique. When the width of attached gingiva on the lingual aspect of the second molar is adequate, a posteriorly based finger flap of keratinized gingiva can be mobilized and used to increase or restore keratinized gingiva on the buccal and distal aspects of the tooth. The submarginal incision on the buccal aspect facilitates stabilization of the finger-flap and prevents displacement via the buccinator. By using a submarginal incision on the lingual aspect and remaining within the confines of the lingual attached gingiva, regeneration of the donor site is ensured. Periodontal dressing is placed (**Fig. 8**.).

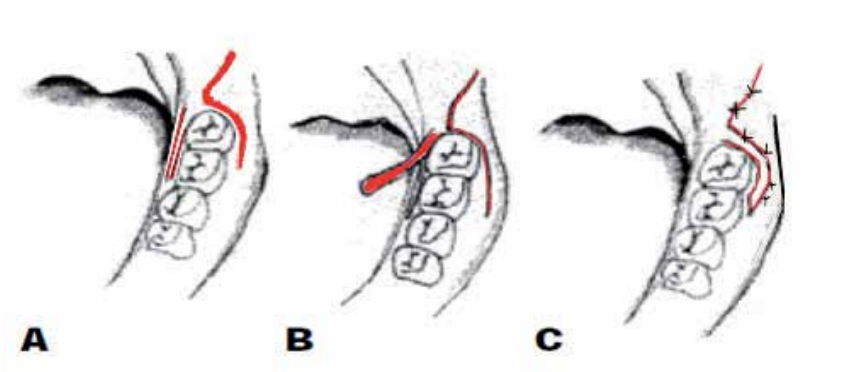

Figure 8. A. Finger flap incision on lingual side within the attached gingiva. Triangular flap on buccal side. Impacted 3rd molar has been removed. B. Flap raised on a pedicle. C. Flap transpositioned into the buccal flap incision.

http://dx.doi.org/10.5772/54648

Because of lingual retromolar anatomy, the surgeon must take into consideration the proximity of the lingual nerve to the third molar region. Damage to this nerve with its intimate relationship with the chorda tympani may result in loss of taste and lingual salivary gland secretion, in addition to loss of sensation in the anterior two-thirds of the tongue on the affected side. By averaging data from several recent studies, the mean vertical distance of the nerve from the distolingual alveolar crest in the region of the mandibular third molar was found to be about 4.45 mm, and the average horizontal distance of the nerve to the lingual cortex was 2.18 mm. But, in 10% to 15% of the cases,the nerve was reported at or above the lingual cortical crest in the most distal region of the third molar tooth.

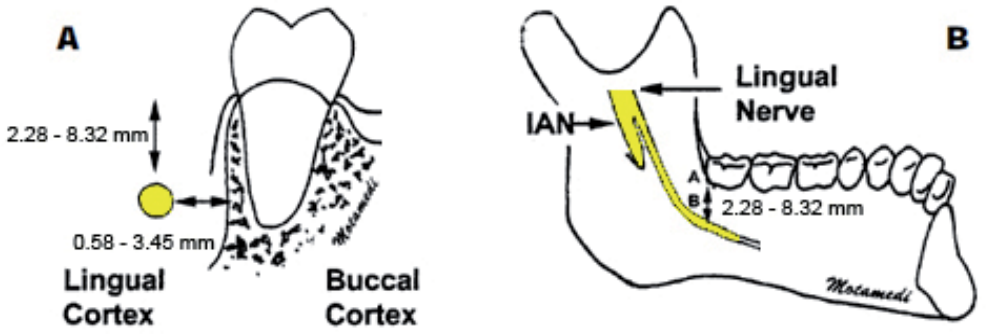

Figure 9. A. Distance of the lingual nerve to the lingual cortex. B. Distance of the lingual nerve to the lingual crest in the distolingual area of the 3rd molar.

However, in this technique, lingual damage is unlikely for 3 reasons. First, because the technique is executed anterior to the third molar socket while the course of the lingual nerve pursues a steep descending medial course into the tongue from the distal part of the third molar crest forward; thus nerve damage during lingual flap mobilization is unlikely anterior to this point. Second, the incisions used in mobilization of the lingual finger flap go back no farther than the distal aspect of the second molar and remain within the confines of the lingual attached gingiva; therefore, lingual nerve damage during the procedure is improbable because the nerve does not enter the attached gingiva. Third, the surgeon may opt to bring in a supraperiosteal lingual flap, which does not carry the risk of damaging the lingual nerve (Fig. 10).[24]

2.5. Double impactions

Simultaneously impacted mandibular second and third molars in adolescent patients with arch space deficiency, although relatively uncommon, may be encountered in clinical practice. The decision of which tooth to save and which to extract may be difficult. If the second molar is to be extracted—aside from the difficulty of the procedure to surgically remove the tooth from under the third molar while not displacing the third molar tooth bud—the orthodontic point of view presents the problem of waiting for mandibular third molar eruption to occur (18 years of age and above) and then bringing the mandibular third molar tooth forward and

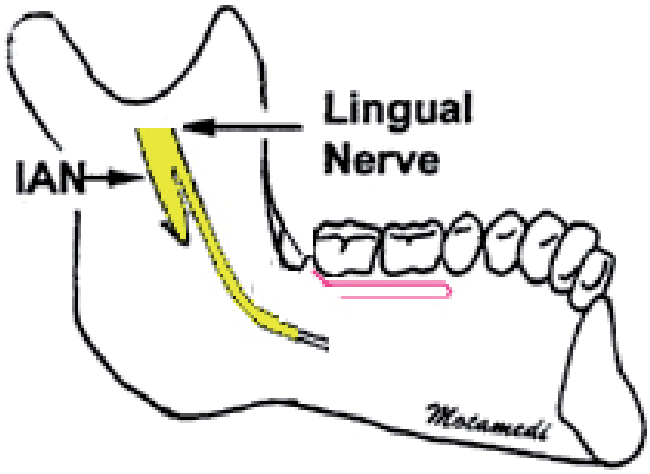

Figure 10. Finger flap incision on lingual side within the attached gingiva. Impacted 3rd molar has been removed.

upright into occlusion with the upper second molar. During this waiting period, we may encounter extrusion or supraeruption of the upper second molar, which has no opposing tooth. This will then be difficult to manage. In addition, the tooth anatomy of the third molar may not conform to the opposing maxillary second molar. [25]

From the surgical standpoint, removal of the impacted mandibular third molar is easier, but exposure and apical repositioning of the gingiva of the second molar for orthodontic bracketing is problematic because of the external oblique ridge and shallow vestibule in the posterior part of the jaw. Disruption of the gingival attachments and flap reflection of the attached gingiva to remove the third molar will cause an immediate loss in vestibular depth due to the upward pull of the buccinator muscle insertions on the flap. This prevents cervical reattachment of the gingiva to the second molar, preventing exposure of the second molar and precluding orthodontic bracket bonding. Current techniques to apically reposition the gingiva in the distobuccal region of the mandible are fraught with difficulty. The anatomy of the posterior mandible—with the closeness of the external oblique ridge to the cervix of the second molar—and the shallow, sometimes nonexistent, buccal vestibule in this area make flap stabilization difficult. Motamedi suggested a technique to anchoring the mucoperiosteal flap to the cortical bone in a manner that is effective in exposing the crown of the second mandibular molar and to prepare it for bracket bonding.[25]

Technique. After extraction of the impacted third molar, the buccal and crestal bone covering the second mandibular molar is removed. Then, a hole is drilled through the buccal cortex of the extracted third molar just distal to the impacted second molar. Next, a 3-0 silk or polyglactin suture is passed through the superior part of the flap and then through the buccal cortex and tied securely to anchor down the flap apically below the crown of the second molar. The crown of the second molar should now be exposed sufficiently for bracket bonding; orthodontic treatment is usually started 7 to 10 days postoperatively (**Fig. 11**).[25]

http://dx.doi.org/10.5772/54648

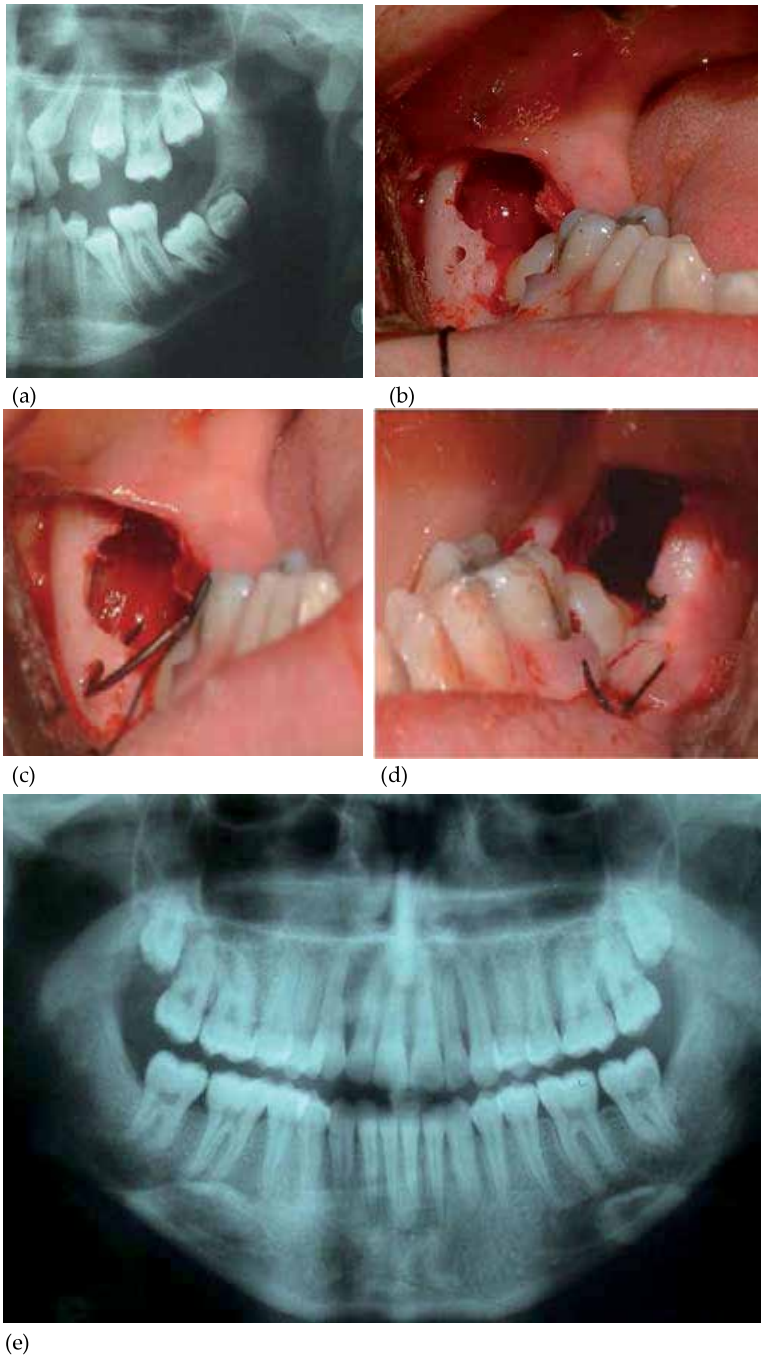

Figure 11. A. Radiograph of a double impaction in the mandible in a 13 year-old boy. B. The 32rd molar has been removed. A hole is drilled in the buccal cortex. C. 3-0 silk suture is passed through the superior part of the flap and then through the buccal cortex. D. the flap is tied down. E. Radiograph 2.5 years post-treatment.

3. Conclusion

Surgery for removal of impacted third molar surgeries may be associated with several postoperative complications; these complications are best prevented. However, the surgeon should be prepared to manage them should they occur. All third molars need not be removed independent of disease findings and patients need not unnecessarily have to accept adverse consequences associated with the surgery risks and discomforts in the absence of pain, radiographic findings of pathology, and or marked clinical evidence of disease. However, when surgery is indicated several new concepts and techniques presented in this chapter can prevent and or manage some of the common postoperative sequel of impacted third molar surgery.[1,2] The techniques presented herein are not for the novice.

Author details

Mohammad Hosein Kalantar Motamedi[1*] and Farshid Kavandi[1]

*Address all correspondence to: motamedical@lycos.com; farshid_kavandi@yahoo.com

1 Trauma Research Center, Baqiyatallah Medical Sciences University, Tehran, Iran

Oral and Maxillofacial Surgeon, Bouali Hospital, Tehran, Iran

References

[1] Motamedi MH. Concepts to consider during surgery to remove impacted third molars. Dent Today. 2007 Oct;26(10):136, 138-41; quiz 141, 129.

[2] Motamedi MH. Preventing periodontal pocket formation after removal of an impacted mandibular third molar. J Am Dent Assoc. 1999 Oct;130(10):1482-4.

[3] Ventä I. How often do asymptomatic, disease-free third molars need to be removed? J Oral Maxillofac Surg. 2012 Sep;70(9 Suppl 1):S41-7.

[4] Carvalho RW, do Egito Vasconcelos BC. Assessment of factors associated with surgical difficulty during removal of impacted lower third molars. J Oral Maxillofac Surg. 2011 Nov;69(11):2714-21. Epub 2011 Jul 12.

[5] Freudlsperger C, Deiss T, Bodem J, Engel M, Hoffmann J. Influence of lower third molar anatomic position on postoperative inflammatory complications.J Oral Maxillofac Surg. 2012 Jun;70(6):1280-5. Epub 2012 Feb 4.

[6] Lim AA, Wong CW, Allen JC Jr. Maxillary third molar: patterns of impaction and their relation to oroantral perforation. J Oral Maxillofac Surg. 2012 May;70(5):1035-9. Epub 2012 Apr 10.

[7] Motamedi MH. Removal of a complex odontoma associated with an impacted third molar. Dent Today. 2008 Apr;27(4):76, 78-9; quiz 79, 68.

[8] Motamedi MH. Impacted lower third molar and the inferior alveolar nerve. OralSurg Oral Med Oral Pathol Oral Radiol Endod. 1999 Jan;87(1):3-4.

[9] Pogrel MA. What are the risks of operative intervention? J Oral Maxillofac Surg. 2012 Sep;70(9 Suppl 1):S33-6. Epub 2012 Jun 16.

[10] Aznar-Arasa L, Harutunian K, Figueiredo R, Valmaseda-Castellón E, Gay-Escoda C. Effect of preoperative ibuprofen on pain and swelling after lower third molar removal: a randomized controlled trial. Int J Oral Maxillofac Surg. 2012 Aug;41(8):1005-9. Epub 2012 Apr 20.

[11] Suomalainen A, Apajalahti S, Vehmas T, Ventä I. Availability of CBCT and iatrogenic alveolar nerve injuries. Acta Odontol Scand. 2012 Feb 9. Pages1129-1130

[12] Guerrero ME, Nackaerts O, Beinsberger J, Horner K, Schoenaers J, Jacobs R; SEDENTEXCT Project Consortium. Inferior alveolar nerve sensory disturbance after impacted mandibular third molar evaluation using cone beam computed tomography and panoramic radiography: a pilot study. J Oral Maxillofac Surg. 2012 Oct;70(10): 2264-70. doi: 10.1016/j.joms.2012.04.015. Epub 2012 Jun 16.

[13] Sanmartí-Garcia G, Valmaseda-Castellón E, Gay-Escoda C. Does computed tomography prevent inferior alveolar nerve injuries caused by lower third molar removal?J Oral Maxillofac Surg. 2012 Jan;70(1):5-11. Epub 2011 Jul 27.

[14] Pogrel MA.What is the effect of timing of removal on the incidence and severity of complications? J Oral Maxillofac Surg. 2012 Sep;70(9 Suppl 1):S37-40. Epub 2012 Jun 16.

[15] Eyrich G, Seifert B, Matthews F, Matthiessen U, Heusser CK, Kruse AL, Obwegeser JA, Lübbers HT. 3-Dimensional imaging for lower third molars: is there an implication for surgical removal?J Oral Maxillofac Surg. 2011 Jul;69(7):1867-72. Epub 2011 Mar 21.

[16] Kim JW, Cha IH, Kim SJ, Kim MR. Which Risk Factors Are Associated With Neurosensory Deficits of Inferior Alveolar Nerve After Mandibular Third Molar Extraction? J Oral Maxillofac Surg. 2012 Aug 15. [Epub ahead of print]

[17] Doucet JC, Morrison AD, Davis BR, Robertson CG, Goodday R, Precious DS. Concomitant removal of mandibular third molars during sagittal split osteotomy minimizes neurosensory dysfunction. J Oral Maxillofac Surg. 2012 Sep;70(9):2153-63. Epub 2011 Nov 12.

[18] Leung YY, Cheung LK. Coronectomy of the lower third molar is safe within the first 3 years. J Oral Maxillofac Surg. 2012 Jul;70(7):1515-22. Epub 2012 Apr 10.

[19] Goto S, Kurita K, Kuroiwa Y, Hatano Y, Kohara K, Izumi M, Ariji E. Clinical and dental computed tomographic evaluation 1 year after coronectomy. J Oral Maxillofac Surg. 2012 May;70(5):1023-9. Epub 2011 Dec 30.

[20] Baqain ZH, Al-Shafii A, Hamdan AA, Sawair FA. Flap design and mandibular third molar surgery: a split mouth randomized clinical study. Int J Oral Maxillofac Surg. 2012 Aug;41(8):1020-4. Epub 2012 Mar 15.

[21] Haraji A, Motamedi MH, Rezvani F. Can flap design influence the incidence of alveolar osteitis following removal of impacted mandibular third molars? Gen Dent. 2010 Sep-Oct;58(5):e187-9. PubMed PMID: 20829150.

[22] Hassan KS, Marei HF, Alagl AS. Does grafting of third molar extraction sockets enhance periodontal measures in 30- to 35-year old patients? J Oral Maxillofac Surg. 2012 Apr;70(4):757-64. Epub 2011 Dec 16.

[23] Motamedi MH. Can an impacted mandibular third molar be removed in a way that prevents subsequent formation of a periodontal pocket behind the second molar? J Can Dent Assoc. 2006 Jul-Aug;72(6):532-3.

[24] Motamedi MH. A technique to manage gingival complications of third molar surgery. Oral Surg Oral Med Oral Pathol Oral Radiol Endod. 2000 Aug;90(2):140-3.

[25] Motamedi MH, Shafeie HA. Technique to manage simultaneously impacted mandibular second and third molars in adolescent patients. Oral Surg Oral MedOral Pathol Oral Radiol Endod. 2007 Apr;103(4):464-6. Epub 2006 Oct 16.

Section 2

Oral and Maxillofacial Infections: Diagnosis and Management

Chapter 3

Odontogenic Infections

Onur Gonul, Sertac Aktop, Tulin Satilmis,
Hasan Garip and Kamil Goker

Additional information is available at the end of the chapter

http://dx.doi.org/10.5772/54645

1. Introduction

The incidence, severity, morbidity, and mortality of odontogenic infections have declined dramatically over the years. This reduction in mortality was not due to the first use of penicillin in the treatment of these infections. Rather, it was due to application of the principles of the initial establishment of airway security, followed by early and aggressive surgical drainage of all anatomical spaces affected by cellulitis or abscesses. Since then, with the use of antibiotics and advanced medical supportive care, mortality associated with Ludwig's angina has been further reduced, to 4% [1].

Determination of the severity of infection, evaluation of host defences, surgical management, medical support, administration of antibiotics, and frequent evaluations of the patient are the mainstays of the management of odontogenic infections. Three major factors must be considered when determining the severity of an infection of the head and neck: anatomical location, rate of progression, and airway compromise.

The host response to a severe infection can place a severe physiological load on the body. Fever can increase sensible and insensible fluid losses and caloric requirements. A prolonged fever may cause dehydration, which can, in turn, decrease cardiovascular reserves and deplete glycogen stores, shifting the metabolism to a catabolic state [2].

The surgeon should also be aware that elderly individuals are not able to respond to high fevers, as is often seen in children. Thus, an elevated temperature in a patient of advanced age is not only a sign of a particularly severe infection, but also an omen of decreased cardiovascular and metabolic reserve, due to the demands placed on the elderly patient's physiology [3].

INTECH
open science | open minds

© 2013 Gonul et al.; licensee InTech. This is a paper distributed under the terms of the Creative Commons Attribution License (http://creativecommons.org/licenses/by/3.0), which permits unrestricted use, distribution, and reproduction in any medium, provided the original work is properly cited.

White blood cell count at admission has been reported to be a significant predictor of the length of hospital stay. Thus, evaluation of leukocytosis is important in determining the severity of infection, as well as in estimating the length of hospital stay.

The physiological stress of a serious infection can also disrupt previously well-established control of systemic diseases, such as diabetes, hypertension, and renal disease. The increased cardiac and respiratory demands of a severe infection may deplete scarce physiological reserves in a patient with chronic obstructive pulmonary disease or atherosclerotic heart disease, for example. Thus, an otherwise mild or moderate infection may be a significant threat to a patient with pre-existing systemic disease, and the surgeon should be careful to evaluate and manage concurrent systemic diseases in conjunction with direct management of the infection.

2. Microbiology of dental infections

Recent reports have confirmed that oral/dental infections are polymicrobial, including facultative anaerobes, such as viridans-group streptococci and the *Streptococcus anginosus* group, with predominantly strict anaerobes, such as anaerobic cocci, *Prevotella* and *Fusobacterium* species. The use of sophisticated non-culture methods has identified a wider range of organisms, such as *Treponema* species and anaerobic Gram-positive rods such as *Bulleidia extructa*, *Cryptobacterium curtum*, and *Mogibacterium timidum* [4].

3. Anatomical Spread of Infection

Bone, muscle, aponeurosis or fascia, neurovascular bundles, and skin can all act as barriers to the spread of infection. However, no tissue barrier or boundary is so restrictive or confining to universally prevent spread of infection into contiguous anatomical spaces[4,5]. [Figures: 1,2]

3.1. Upper lip

Infection at the base of the upper lip typically originates from the upper anterior teeth. It spreads to the orbicularis muscle, from the labial sulcus between the levator labii superioris muscle and the levator angularis oris muscle.

3.2. Canine fossa

Spread of infection to the canine fossa usually originates from maxillary canine or upper premolar teeth, often presenting above the buccinator muscle attachment. These swellings obliterate the nasolabial fold. This space is in close proximity to the lower eyelids, and therefore early management is essential to avoid circumorbital infection. There is a risk of spread cranially, via the external angular vein, which may then become thrombosed.

http://dx.doi.org/10.5772/54645

Figure 1. Severe infection of several fascial spaces.

Figure 2. Submental view.

3.3. Buccal space

The attachment of the buccinator muscle to the base of the alveolar process can control the spread of infection in the region of the mandibular and maxillary molars. An infection spreads intraorally, superficial to the buccinator muscle, in front of the anterior border of the masseter muscle. Thus, the clinical manifestations of infection in this space are characterized by swelling confined to the cheek. However, infection may spread superiorly, towards the temporal space, inferiorly, to the submandibular space, or posteriorly, into the masseteric space. In some cases, infection may spread to the surface of the skin, leading to fistula formation

3.4. Palate

The palate is usually involved in infections originating from the maxillary lateral incisor or the palatal roots of the posterior teeth. The infection spreads from the apices of these teeth, perforating the palatal alveolar bone, and pus accumulates below the palatal mucoperiosteum.

It is important to be aware that although the lateral incisor is the most common source of palatal abscess, though most still present labially.

3.5. Pterygomandibular space

Infection in this space is manifested by trismus, due to the involvement of the pterygoid muscles. This space is bounded medially by the medial pterygoid muscle and laterally by the medial surface of the mandible, anteriorly by the pterygomandibular raphe, and posteriorly by the deep lobe of the parotid gland. The lateral pterygoid muscle forms the roof of this space.

3.6. Submasseteric space

The most common source of infection in this space is from lower third molar pericoronitis. This space is bound medially by the masseter muscle and laterally by the outer surface of the ramus of the mandible. It is in direct communication with the lateral pharyngeal space posteriorly. The temporalis muscle divides the superior part of this space into two portions, the superficial temporal space, which is bounded by temporalis muscle medially, and the deep temporal space, with the temporalis muscle laterally and the periosteum of the temporal bone medially. Severe trismus due to spasm of the masseter muscle is a characteristic feature of involvement of this fascial space.

3.7. Infratemporal space

Extension of infection from maxillary molars can pass into this space. Infection may also spread from the pterygomandibular, parotid, or lateral pharyngeal region to the infratemporal space. The patient then complains of pain, particularly with mouth opening, some dysphagia, and difficulty with lateral mandibular movements. This space is located behind the zygomatic bone posterior to the maxilla and medial to the insertion of the medial pterygoid muscle. The infratemporal space is bounded superiorly by the greater wing of the sphenoid and is in close proximity to the inferior orbital fissure, with a possible risk of spread of infection to the orbit.

3.8. Parotid space

Involvement of this space may be an extension of infection in the middle ear or the mastoid region. Infection in the masseteric or the lateral pharyngeal space may also spread to the parotid region. Thus, the most characteristic feature of involvement of this space is swelling of the parotid gland region, below the ear lobe. This space contains several important structures that may be affected by infections. These include the 7th cranial nerve, the auriculotemporal nerve, the facial vein, the parotid lymph node, and, more deeply, the external carotid with its branches.

3.9. Submandibular space

This space is located below the mylohyoid muscle, medial to the ramus and the body of the mandible. It is bounded anteriorly by the attachments of the anterior belly of the digastric muscle and posteriorly by the posterior belly of digastric muscle and the stylomandibular

ligament. Infection from the posterior mandibular teeth may pass lingually, below the attachment of the mylohyoid muscle, into this space. Clinically, swelling of the submandibular regions tends to obliterate the angle of the mandible, causing pain and redness of the skin overlying this region. Dysphagia is also usually a marked symptom.

3.10. Submental space

This space lies between the two anterior bellies of the digastric muscle. Anteriorly and laterally this space is bounded by the body of the mandible. It is contained, superficially, by the platysma muscle and, deeply and superiorly, by the mylohyoid muscle. Infection of this space usually arises from mandibular anterior teeth, where the infection perforates the lingual cortex; swelling of the submental region is a characteristic clinical feature. The skin over the swelling is stretched and hardened, and the patient experiences considerable pain and difficulty with swallowing. The infection may progress buccally, causing swelling in the labial sulcus and over the chin.

3.11. Sublingual space

Infection spreads into this space as the result of perforation of the lingual cortex, above the attachment of the mylohyoid muscle. This space is bounded superiorly by the mucous membranes and inferiorly by the mylohyoid muscle. The genioglossus and geniohyoid muscles form the medial boundary. Laterally, this space is bounded by the lingual surface of the mandible. Infection in this space will raise the floor of the mouth and displace the tongue, medially and posteriorly. Such tongue displacement may compromise the airway and immediate intervention may be required. Dysphagia and difficulty with speech are also common.

3.12. Pharyngeal space

This space is located on the lateral side of the neck, bounded medially by the superior constrictor muscle of the pharynx and posterolaterally by the parotid space. Infection in this space may originate from mandibular molars or third molar pericoronal suppuration. This could also be a site of spread of infection from the parotid space or fascial space around the body of the mandible. The lateral pharyngeal space contains the carotid sheath, glossopharyngeal nerve, accessory nerve, and the hypoglossal nerve, as well as the sympathetic trunk. Thus, spread of infection into this space carries a significant danger of spreading into a descending neck infection and involvement of the mediastinum. Clinically, stiffness of the neck, swelling of the lateral wall of the pharynx, medial displacement of the tonsils, dysphagia, and trismus are among the characteristic clinical features of involvement of this space.

3.13. Retropharyngeal space

This space is located between the posterior wall of the pharynx and the prevertebral fascia. This space is in direct communication with the base of the skull, superiorly, and the media-

stinum, inferiorly. It has the same characteristic clinical features as infection of the lateral pharyngeal space and carries a significant complication risk of a descending neck infection.

4. Evaluation of patients with dentofacial infections

Patients with dentofacial infections may present with various signs and symptoms, ranging from less important to extremely serious. Quick assessment of the patient's situation is essential as the first step of therapy. If the patient shows central nervous system changes, airway compromise, or toxification, then immediate hospitalization, aggressive medical treatment, and surgical intervention may be necessary. Basic principles of patient evaluation must be followed. A complete patient history, physical examination, laboratory investigation, radiological investigation, and accurate and appropriate interpretation of findings must be made. Following these basic principles provides the best chance of accurate diagnosis and treatment [6,7].

4.1. History taking

History taking helps in obtaining information regarding the origin, extent, location, and potential threat of the problem. History taking can be defined briefly as determining the present situation of the patient, previous hospitalization history of the patient, previous trauma in the region, recurrent infections, and history of recent swelling and/or airway compromise.

4.2. Physical examination

Examination of the thorax, abdomen, extremities, cardiovascular system, recording of vital signs, and body temperature assessment are essential as part of the general patient evaluation. Next, the skin of the face, head, and neck, swellings, injuries, and areas of tenderness over maxillary and frontal sinuses, sinus tracts, fistula formation, enlargement of underlying bony structures, salivary glands, and lymph nodes must be examined. A comprehensive extraoral examination includes inspection of the skin of the face, head, and neck, and of any swelling, injuries, fixation of skin, sinus, or fistula formation. Palpation of the size of any swelling, tenderness, local temperature, fluctuation, enlargement or tenderness over maxillary and frontal sinuses, sinus tracts, fistula formation, enlargement and tenderness of underlying bony structure, salivary glands, and lymph nodes is also important. A comprehensive intraoral examination includes measurement of inter-incisal openings for the assessment of trismus, examination of the teeth, any localized fistula or swelling, sites of tooth extraction, percussion findings, heat and cold testing, electrical pulp testing, visualization of opening ducts of salivary glands, soft palate, tonsillar fossa, uvula, and oropharynx.

4.2.1. Clinical features

Clinical features must be definitively identified to evaluate the patient's condition properly. Clinical features can be classified as follows.

http://dx.doi.org/10.5772/54645

a. Signs of inflammation

Rubor: This symptom is usually present when the infection is close to an external tissue surface, due to vasodilation.

Tumor: This may be present at an infection site, due to accumulation of inflammatory exudate or pus.

Calor: This is due to warm blood from deeper tissues at the site of the infection, increased velocity of blood flow, and an increased rate of metabolism.

Dolor: This is due to pressure on sensory nerve endings, caused by distension of tissues, caused by the action of liberated or activated factors, such as kinins and histamine.

Loss of function: This is due to mechanical factors or reflex inhibition of muscle movements, associated with pain. This is reflected in difficulty in chewing and swallowing and respiratory issues.

b. Fever

Fever is one of the most consistent signs of infection. However, other conditions that may manifest fever should also be considered. Non-infectious inflammatory disorders, like rheumatoid arthritis, excess catabolism, as in thyrotoxicosis, neoplastic disease, like lymphoma, and post-operative release of endogenous pyrogens, which stimulate the hypothalamic thermoregulation centers, should be considered.

c. Repeated Chills

Generally seen in the presence of bacteraemia and pyogenic abscesses.

d. Lymphadenopathy

The condition of the lymph nodes depend on whether the situation is acute or chronic. In acute infections, lymph nodes are soft, tender, and enlarged. Surrounding tissues are edematous and the overlying skin is erythematous. In chronic infections, lymph nodes are firm, non-tender, and enlarged. Edema of surrounding tissue may not be present. The location of affected lymph nodes may indicate the site of an infection.

e. Headache

This is usually associated with fever, and its thought to be due to stretching of sensitive structures surrounding dilated intracranial arteries.

f. Other Clinical Features

Other clinical features include the presence of draining sinuses or fistulae, difficulty in opening the mouth, difficulty in swallowing, increased salivation, changes in phonation, difficulty in breathing.

- Clinical Symptoms of Possibly Life-Threatening Infections are as follows:

Respiratory impairment, difficulty in swallowing, impaired vision or eye movement or both, change in voice quality, lethargy, decreased level of consciousness, agitation, hypoxia.

- Clinical Symptoms of Toxicity are as follows:

Pallor, increased rate of respiration, fever, lethargy, diaphoresis.

- Central Nervous System Changes Associated with Infection are as follows:

Decreased level of consciousness, evidence of meningeal irritation, severe headache, stiff neck, vomiting, and oedema of the eyelids and other abnormal eye signs.

4.3. Radiological examination

A radiological examination may be helpful in locating the offending teeth or other underlying causes. Various radiographs can be useful, such as intraoral periapical radiographs, orthopantomographs, and lateral oblique views of the mandible. A-P and lateral views of the neck can be helpful in detecting retropharyngeal space infections. Other imaging techniques, such as computed tomography, magnetic resonance imaging, and xeroradiography, are also used for detection of the localization of infection and infection-affected tissues. CT scanning is the gold standard in head and neck imaging. It is the advanced imaging modality most widely used in the evaluation of facial infections. A CT scan can show the extent of soft tissue involvement, such as the extent of the inflammatory process, the epicenter of the inflammatory process, differentiation between myositis–fasciitis and abscess formation, and can accurately demonstrate the airway status and lymph node involvement [8].

5. Antibiotic therapy in dentofacial infections

Choosing the appropriate antibiotic for treating an odontogenic infection must be done with care. When all factors are considered, the clinician may decide that no antibiotic is necessary at all, whereas in other situations, broad-spectrum or even combination antibiotic therapy may be indicated. Various factors must be considered when choosing an antibiotic from the nearly 70 that are currently available. Although appropriate use may result in dramatic resolution and cure of patients with infections, inappropriate use of antibiotics provides little or no benefit to offset the risks and expense associated with antibiotic administration. Recent studies have shown that even the administration of oral penicillin promotes the growth of penicillin-resistant organisms in the oropharyngeal flora of the patient. Thus, the following guidelines should be considered when choosing a specific antibiotic.

Determination of the need for antibiotic administration. A common misconception is that all infections, by definition, require antibiotic administration. This is not necessarily the case. In some cases, antibiotics are not useful and may even be contraindicated. In making this determination, three factors must be considered.

1. The seriousness of the infection.

2. Whether adequate surgical treatment can be achieved.

3. The state of the patient's host defenses.

When these three factors are balanced, several definite indications for antibiotic use become clear. These are:

- Swelling extending beyond the alveolar process
- Cellulitis
- Trismus
- Lymphadenopathy
- Fever
- Severe pericoronitis
- Osteomyelitis

Based on the same three criteria, antibiotic therapy is not indicated in other situations, such as:

- Patient demand
- Toothache
- Periapical abscess
- Dry socket
- Multiple dental extractions in a non-compromised patient
- Mild pericoronitis
- Drained alveolar abscess

In summary, antibiotics should be used when clear evidence exists of bacterial invasion into deeper tissues, which is greater than the host defenses can overcome. Patients who have an impaired ability to defend themselves against infection and patients who have infections that are not immediately amenable to surgical treatment should also be considered for antibiotic therapy. Antibiotics should not be used when no evidence of bacterial invasion of deeper tissues is found. It should be remembered that antibiotics do not improve wound healing and do not benefit non-bacterial infections.

- **Routine empirical antibiotic use.** Because the microbiology and antibiotic sensitivity of many oral pathogens is well-known, it is reasonable to use one of the effective antibiotics empirically. This means to give the antibiotic with the assumption that an appropriate drug is being given. The drug of choice is usually penicillin. Alternative drugs for use in a penicillin-allergic patient are clindamycin and azithromycin. Metronidazole is useful against anaerobic bacteria and should be reserved for a situation in which only anaerobic bacteria are suspected or used in combination with an antibiotic that has an anti-aerobic

bacteria effect, like penicillin. The most widely used, effective, orally administered antibiotics are:

- Penicillin
- Amoxicillin
- Clindamycin
- Azithromycin
- Metronidazole
- Moxifloxacin
- **Narrowest spectrum antibiotic use.** It is preferable to use an antibiotic with the narrowest spectrum that is effective against the organism(s) involved in the infection. The use of a broad-spectrum antibiotic should be avoided, because it increases the risk of the development of resistant microbial strains and also increases the risk of superinfections, by disrupting the normal bacterial flora in various body cavities and permitting ordinarily nonpathogenic bacteria to proliferate and cause disease.
- **Antibiotic usage with the lowest incidence of toxicity and side effects.** Most antibiotics have a variety of toxicities and side effects that limit their usefulness. These range from mild to so severe that the antibiotic cannot be used in routine clinical practice. The older antibiotics usually used for odontogenic infections have a surprisingly low incidence of toxicity-related problems. The more recent antibiotics, on the other hand, may have significant toxicities and drug interactions. Thus, it is becoming increasingly important for the clinician to understand the toxicities, side effects, and drug interactions of the drugs that are prescribed.
- **Use of a bactericidal antibiotic, if possible.** Antibiotics may either kill bacteria or interfere with their reproduction. Bactericidal antibiotics usually interfere with cell-wall production in newly forming or growing bacteria. The antibiotic actually kills the bacteria, while the white blood cells, complement, and antibodies of the host play a less important role. Bacteriostatic antibiotics interfere with bacterial reproduction and growth. This slowing of bacterial reproduction allows the host defenses to move into the area of infection, phagocytose existing bacteria, and kill them. Thus, bacteriostatic antibiotics require reasonably intact host defences. Therefore, for patients with compromised host defences, bactericidal antibiotics should be the drug of choice [9,10,11].

6. Surgical management of odontogenic infections

The primary principle of the surgical management of odontogenic infections is to perform surgical drainage and to remove the cause of the infection. Surgical management may range from something as simple as an endodontic extirpation of the necrotic tooth pulp to treatment as complex as the wide incision of soft tissue in the submandibular and neck regions for a

http://dx.doi.org/10.5772/54645

severe infection. The primary goal in surgical management of infection is to remove the cause of infection and to provide drainage of accumulated pus and necrotic debris. Surgical incision and drainage helps to get rid of toxic purulent material, to decompress edematous tissues, to allow better perfusion of blood, which contains antibiotic and defense elements, and to increase oxygenation of the infected area. When an abscess is drained surgically, appropriate dental treatment also should be instituted to achieve quick resolution. This may involve exploration of either the entire anatomical space or the abscess cavity. The abscess cavity is then irrigated with betadine and saline solution. A drain is inserted into the depth of the space. It may simply pass through a single incision and remain in the depth of the space, or it may be a through-and-through drain. The drain is typically secured to one of the margins of the incision with a suture. The method of opening an abscess ensures that no blood vessel or nerve in the region is damaged, and can be defined in ten steps:

1. **Topical anesthesia.** Local anesthesia is achieved with the help of ethyl chloride spray; local anesthesia can then be achieved by subcutaneous ring blockage using a local anesthetic solution, such as articaine + epinephrine or lidocaine + epinephrine.

2. **Incision.** This is made over a point of fluctuation in the most dependent area along the skin crease, through undamaged skin and subcutaneous tissue.

3. **If pus is not encountered,** further deepening of the surgical site is achieved with sinus forceps.

4. **Closed forceps** are pushed through the deep fascia and advanced towards the pus collection.

5. **The abscess cavity** is entered and forceps opened in a direction parallel to vital structures.

6. **Pus flows** along the sides of the incision. [Figure 3]

7. **Explore** the entire cavity for additional loci.

8. **Placement of a drain.** A soft corrugated rubber drain is inserted into the depth of the abscess cavity, and the external part is secured to the wound margin with the help of a suture. [Figure 4]

9. **The drain** is left in place for at least 24 h.

10. **A dressing** is applied over the site of the incision, without pressure.

The purpose of the drain is to allow the discharge of tissue fluids and pus from the wound by keeping it patent. The drain also allows debridement of the abscess cavity by irrigation. Tissue fluids flow along the surface of drain. Thus, it is not always necessary to make perforations in the drain, which could weaken and possibly cause fragmentation within the tissue. Drains should be removed when the drainage is nearly completed. Drains have been shown to allow *ingress* of skin flora along their surfaces. Some forms of drains, such as latex drains in particular, can be irritating to the surrounding tissues and may themselves stimulate some exudate formation. Thus, drains are usually left in infected wounds for 2–7 days. Removal is achieved by simply cutting the suture and slipping the drain from the wound.

Figure 3. Drainage of pus after incision.

Figure 4. Through and through drain placed.

It is critical to keep in mind that the primary method for treating odontogenic infections is surgical removal of the source of the infection and draining of anatomical spaces affected by indurated cellulitis or abscesses. Whenever an abscess or cellulitis is diagnosed, it must be drained by the surgeon. Failure to do so will result in worsening of the infection and failure

http://dx.doi.org/10.5772/54645

of the infection to resolve, even if antibiotics are given. Even if a tooth cannot be opened or extracted, an incision and drainage procedure should be performed [12,13].

7. Specific infections

7.1. Osteomyelitis

Osteomyelitis is defined as inflammation of the bone. Different from other infectious circumstances seen in the jaws, it involves adjacent cortical plates and often periosteal tissues. The incidence of osteomyelitis is much higher in the mandible because of the dense, poorly vascularized cortical plates. It is much less common in the maxilla due to the excellent blood supply from multiple feeder vessels. In addition, the maxillary bone is much less dense than the mandible. Osteomyelitis has been associated with multiple systemic diseases, including diabetes, autoimmune states, malignancies, malnutrition, and acquired immunodeficiency syndrome [14]. Medications linked to osteomyelitis include steroids, chemotherapeutic agents, and bisphosphonates [15,16]. Local conditions that adversely affect the blood supply can also predispose the host to a bone infection. Radiation therapy, osteopetrosis, and bone pathology can alter the blood supply to the area and provide a potential foothold for osteomyelitis. The most common cause of suppurative osteomyelitis is an odontogenic infection [17]. Depending on the signs and symptoms, osteomyelitis can be classified as acute, subacute, and chronic forms. Radiographic changes do not appear immediately in the acute suppurative form of osteomyelitis, because it may take about 2 weeks for the trabecular pattern of bone to change and areas of radiolucency to start to appear, usually accompanied by periostitis. If acute osteomyelitis is not treated effectively, it can lead to chronic suppurative osteomyelitis. The infection may be a manifestation of lowered patient resistance; this sometimes occurs in immunosuppressed patients on medication or those suffering from an impaired immune defense, as in acute leukemia, human immunodeficiency virus (HIV) infection, poorly controlled diabetes mellitus, or malnutrition.

Clinically, the disease is dominated by pain and the development of intraoral and/or extraoral sinuses. Induration of soft tissues overlying the infected segments of the jawbones is marked and distension of the periosteum with pus or inflammatory exudate, which may cause trismus and difficulty in swallowing. Regional lymph nodes are usually tender and enlarged. A pathological fracture may develop if the inferior border of the mandible is damaged by the infection process. The radiographic picture of chronic osteomyelitis is loss of detail of the trabecular pattern of the osseous architecture, giving the bone a mottled or moth-eaten appearance. The ischemic or necrotic islands of bone tend to sequestrate, appearing more radiopaque than the surrounding bone; these form a sequestrum of necrotic bone. [Figure 5,6]

In younger persons, subperiosteal new bone formation appears adjacent to the diseased area. This new bone, known as involucrum, tends to be structureless or granular in appearance radiographically and may surround the necrotic sequestrum and pus lying within the bone (18).

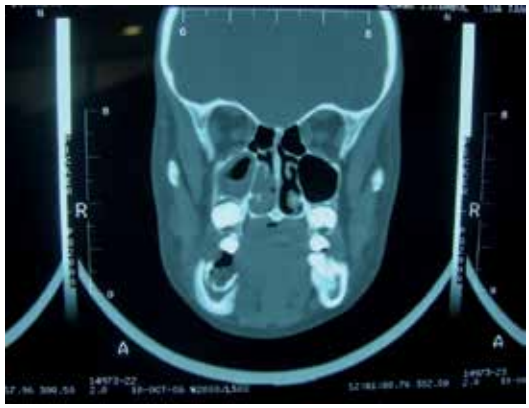

Figure 5. Osteomyelitis right mandible.

Figure 6. Sequestrum.

Management of osteomyelitis involves two aspects: medical and surgical. Clearly, the first step in the treatment of osteomyelitis is correct diagnosis of the condition. A tentative diagnosis is made from a clinical evaluation, radiographic evaluation, and tissue diagnosis. The clinician must be aware that malignancies can mimic the presentation of osteomyelitis and must be kept in the differential diagnosis until ruled out by tissue histopathology. Tissues from the affected site should be sent for Gram staining, culturing, sensitivity determination, and histopathologic evaluation. Empirical antibiotic treatment should be started, based on Gram staining results of the exudate or the suspected pathogens likely to be involved in the maxillofacial region. Definitive culture and sensitivity reports generally take several days or longer but are valuable in guiding the surgeon to the best choice of antibiotics, based on the patient's specific causative organism(s) [17]. Surgical aspects include drainage, debridement, and sequestrectomy, removal of the source of the infection and, if necessary, decortication of the mandible, and possibly resection and reconstruction of the affected bone after the infection is controlled [Figures 7,8,9].

http://dx.doi.org/10.5772/54645

Figure 7. Access to the sequestrum.

Figure 8. Removal.

7.2. Osteoradionecrosis

This type of bone necrosis occurs following radiotherapy to the jaw region and often becomes infected secondarily [19]. Radiotherapy induces endarteritis obliterans, which reduces vascularity and renders the bone vulnerable to infection. Once secondary infection develops, it typically spreads through the bone, but sequestration is delayed in these cases. Patients who have undergone radiotherapy are potentially at risk of developing this type of osteomyelitis, and the mandible is particularly at risk if it has received more than 55 Gy of radiation. Extraction and other surgical procedures should be carried out as atraumatically as possible. Primary closure of the socket and pre- and postoperative antibiotic treatment, antiseptic mouthwash, and good oral hygiene are essential. The use of hyperbaric oxygen to increase the blood supply to the affected bone has proven successful in the management of these cases, as have other new and experimental treatments [20]. Better collimation of the radiation beam and

Figure 9. Removed sequestrum.

protection of tissues adjacent to tumors have reduced, although not eliminated, this unpleasant sequel.

7.3. Osteonecrosis secondary to bisphosphonate therapy

Bisphosphonates reduce pain and bone destruction due to metastatic disease, particularly in patients with multiple myeloma, breast, and prostate carcinoma. The medication inhibits bone resorption by reducing osteoclastic activity [21]. Long-term administration of high-dose intravenous bisphosphonates may lead to osteonecrosis of the jaw bones. This is due mainly to a reduction in vascularity, which, together with inhibition of osteoclastic activity, reduces bone turnover. Both are required to protect the bone from the risk of necrosis and added superinfection. There is a lesser risk of this condition occurring in patients taking oral bisphosphonates to prevent osteoporosis. The mandible is most often affected and the disease usually arises after dental treatment. The patient may present with either a non-healing extraction socket or exposed bone, which does not respond to conservative management and antibiotic therapy. Extraction of infected or periodontally involved teeth should be carried out before the administration of bisphosphonates, if possible, and surgery should be avoided whenever possible. It has been suggested that the reparative ability of the bone can be assessed by measuring the serum C-terminal telopeptide (CTX) [22]. Peri- and postoperative antibiotics are essential for extractions. Chlorhexidine mouthrinse pre- and post-extraction is also considered valuable. In non-urgent cases, the risk may be reduced if the bisphosphonate is withheld for 3 months prior to surgery. This must, however, be done in consultation with the physician prescribing the drug.

7.4. Actinomycosis

This is a chronic suppurative granulomatous infective process, characterized by the development of swelling in the face and neck region. It is normally a soft tissue infection but can

occasionally involve bone. The causative microorganism is *Actinomyces israelii*, which is present in the normal oral flora. Damage to the tissue, resulting from either lower tooth extractions or jaw fractures, creates a condition of low oxygen tension in which the organism becomes invasive. The condition starts as a swelling, which may occur up to several weeks after the trauma, usually within the submandibular region [Figure 10]. The swelling appears first as a firm and indurated lesion and the overlying skin is usually inflamed and firm, but may also have a bluish color. Within the swelling, multiple abscesses may form with sinuses draining fluid containing yellow granules (so-called sulfur granules) that appear microscopically as a mass of Gram-positive mycelia and polymorphs. Radiographic examination may reveal little destruction of affected bone because the infection is essentially one of the soft tissue. Penicillin is the drug of choice, in addition to adequate incision and drainage. The organism is penicillin-sensitive but it takes time for the antibiotic to penetrate the granulomatous reaction of the body. Antibiotic treatment must be continued for at least 6 weeks. Surgical removal of any infection will facilitate recovery [4].

Figure 10. Actinomycosis.

7.5. Syphilis

This is a chronic infectious disease, caused by the spirochete *Treponema pallidum*. Although now rare, primary (the chancre), secondary (skin rashes, lymphadenopathy, mucous patches, and snail track ulcers), and tertiary (gumma or syphilitic leukoplakia) may be found in the oral cavity. The first and second stages are highly infectious. Bony changes may occur during the tertiary stage of syphilis. The periosteum is a common site for the development of gumma, with the midline of the palate being classically involved, leading, in time, to oronasal fistula. This appears radiographically as peeling of the periosteum, away from the underlying bone, and the formation of sclerotic bony margins at the periphery. Gumma may extend to the underlying bone and cause syphilitic osteomyelitis. The condition is diagnosed by the identification of *Treponema pallidum* using dark-field microscopy, serological tests, and biopsy of the granulomatous tissue. Long-term penicillin is the drug of choice, in addition to local

measures to deal with damaged soft tissue, sequestered bone, and involved teeth. The fourth stage of syphilis is rare; it affects the cardiovascular system, causing aortic aneurysms or aortic valve incompetence. The central nervous system may also become involved, which may lead to dementia or spinal cord disease [4].

Author details

Onur Gonul*, Sertac Aktop, Tulin Satilmis, Hasan Garip and Kamil Goker

Department of Oral and Maxillofacial Surgery, Marmara University, Istanbul, Turkey

References

[1] Hought RT, Fitzgerald BE, Latta JE, Zallen, RD. Ludwig's angina: report of two cases and review of the literature from 1945 to January 1979. J Oral Surg 1980;38:849–55.

[2] Miloro M. Peterson's Principle of Oral and Maxillofacial Surgery. Second Edition.. In Miloro M.,Ghali G. E., Larsen P. E., Waite P. Editors. BC Decker Inc. 2004 p.277-79

[3] Flynn TR, Topazian RG. Infections of the oral cavity. In: Waite D, editor. Textbook of practical oral and maxillofacial surgery. 3rd Ed. Philadelphia (PA): Lea & Febiger; 1987. p. 273–310.

[4] Andersson L. Oral and Maxillofacial Surgery. In Andersson L., Kahnberg K. E., Pogrel M.A.editors Wiley Blackwell 2010 p.280-314

[5] Flynn T. Anatomy and surgery of oral and maxillofacial infections. J Oral Maxillofac Surg 2006; 64: 100–5

[6] Malik N. A. Textbook of Oral and Maxillofacial Surgery. Secpnd Edition. Jaype Brothers Medical Publishers (P) Ltd. India 2008 p. 587-636

[7] Hupp J. R. Contemporary Oral and Maxillofacial Surgery. In Hupp J. R., Ellıs III E., Tucker R. M. Editors.Fifth Edition. Mosby Elsevier 2008

[8] Miller WD, Furst IM, Sandor GKB, et al. A prospective blinded comparison of clinical examination and computed tomography in deep neck infections. Laryngoscope 1999; 109:1873–9

[9] Flynn TR, Halpern LR. Antibiotic selection in head and neck infections. Oral Maxillofac Surg Clin North Am 2003;15:17–38.

[10] Kuriyama T, Karasawa T, Nakagawa K, Nakamura S, Yamamoto E. Anatomical susceptibility of major pathogens of orofacial odontogenic infections to 11 β-lactam antibiotics. Oral Microbiol Immunol 2002; 17: 285–9

[11] Fazakerley MW, McGowan P, Hardy P, et al. A comparative study of cephradine, amoxycillin and phenoxymethylpenicillin in the treatment of acute dentoalveolar infection.Br Dent J 1993;174:359–63.

[12] Flynn T. Surgical management of oral infections. Atlas Oral Maxillofac Surg Clin North Am 2000; 8: 77–100.

[13] Flynn TR. The timing of incision and drainage. In: Piecuch JF, editor. Oral and maxillofacial surgery knowledge update 2001. Rosemont (IL): American Association of Oral and Maxillofacial Surgeons; 2001. p. 75–84.

[14] Marx RE. Chronic osteomyelitis of the jaws. Oral Maxillofac Surg Clin North Am 1991;3:367–81.

[15] Marx RE. Pamidronate and zoledronate induced avascular necrosis of the jaws. J Oral Maxillofac Surg 2003;61:1115–8.

[16] .Migliorati CA. Bisphosphonates and oral cavity avascular bone necrosis. J Clin Oncol2003;21:4253–4.

[17] Koorbush GF, Fotos P, Goll TK. Retrospective study of osteomylitis. Aetiology, demographics, risk factors and management in 35 cases. Oral Surg Oral Med Oral Pathol1992; 74: 149–54.

[18] Cierny G,Mader J, Pennick J. A clinical staging system for osteomyelitis. Contemp Orthop 1985;10:17.

[19] Marx RJ. Osteonecrosis: a new concept of its pathology. J Oral Maxillofac Surg 1983; 41: 283–8.

[20] Marx RE, Johnson RP, Kline SN. Prevention of osteoradionecrosis: a randomized prospective clinical trial of hyperbaric oxygen versus penicillin. J Am Dent Assoc 1985; 111:49–54.

[21] Mavrokokki T, Cheng A, Stein B, Goss A. Nature and frequency of bisphosphonate associated osteonecrosis of the jaws in Australia. J Oral Maxillofac Surg 2009; 65: 415–23.

[22] Lyons A, Ghazali N. Oral bisphosphonate induced osteonecrosis, risk factors, prediction of risk using CTX testing, prevention, and treatment. Br J Oral Maxillofac Surg 2008; 46: 653–61.

Chapter 4

Non-Odontogenic Oral and Maxillofacial Infections

Petr Schütz and Hussein Hassan Hamed Ibrahim

Additional information is available at the end of the chapter

http://dx.doi.org/10.5772/54304

1. Introduction

While odontogenic infections are daily encountered in dental and oral and maxillofacial surgery practices, some practitioners may be unfamiliar with the wide range of other infections of diverse etiology, some of them relatively uncommon, or even rare. Patients so affected come to their attention either through referrals from primary care providers or due to patients' uncertainty about where to seek help for diseases manifesting themselves in the orofacial area. Also in hospital environment, where majority of oral and maxillofacial surgeons practice, one regularly receives requests for consultations about patients who need interdisciplinary cooperation despite the fact that their conditions primarily belong to the sphere of specializations like ENT surgery, ophthalmology, dermatology and others. The purpose of this chapter is to provide an update on such conditions and demonstrate the ways oral and maxillofacial surgeon can participate in their diagnosis and management.

2. Facial skin infections

2.1. Impetigo

Impetigo is a highly contagious infection of the superficial epidermis. It is usually caused by *Staphylococcus aureus* or Group A streptococci [1]. The form of impetigo that penetrates deeper into the dermis and may leave a scar is called ecthyma. Impetigo occurs most frequently among economically disadvantaged children aged 2–5 years, although older children and adults may also be afflicted under conditions of poor hygiene, high humidity and warm temperatures. Prospective studies of streptococcal impetigo have demonstrated that the responsible microorganisms initially colonize the unbroken skin. Inoculation of surface organisms into the skin happens after a mean interval of 10 days by abrasions, minor trauma, or insect bites [2].

INTECH
open science | open minds

© 2013 Schütz and Hamed Ibrahim; licensee InTech. This is a paper distributed under the terms of the Creative Commons Attribution License (http://creativecommons.org/licenses/by/3.0), which permits unrestricted use, distribution, and reproduction in any medium, provided the original work is properly cited.

2.1.1. Clinical presentation

The most frequent locations of impetigo are the face and extremities. Two clinical forms are recognized: non-bullous and bullous. The lesions of non-bullous impetigo begin as papules that rapidly evolve into vesicles surrounded by an area of erythema. Then they become pustules that gradually enlarge and break down over a period of 4–6 days to form characteristic golden yellow crusts [3]. (Figure 1)

Figure 1. Non-bullous impetigo of paranasal skin with a central denuded area and peripheral crust.

Bullous lesions appear initially as superficial vesicles that rapidly enlarge to form flaccid bullae filled with clear yellow fluid, which later becomes darker, more turbid, and sometimes purulent. The bullae may rupture, often leaving a thin brown crust resembling lacquer [4]. The lesions heal slowly and leave depigmented areas. Bullous impetigo is caused by strains of *S. aureus* that produce a toxin causing cleavage in the superficial skin layer. In the past, nonbullous lesions were usually caused by streptococci. Now, most cases are caused by staphylococci alone or in combination with streptococci [5].

2.1.2. Treatment

The therapeutic approach to impetigo depends on the number of lesions, their extent and location (in a face proximity to eyelids or mouth), and the need to limit spread of infection to other individuals. The best topical agent is mupirocin, although resistance has been described; other agents, such as bacitracin and neomycin, are considerably less effective. Topical therapy with mupirocin is equivalent to oral systemic antimicrobials and may be used when lesions are limited in number. Patients who have numerous lesions or who are not responding to topical agents should receive oral antibiotics effective against both *S. aureus* and *Streptococcus pyogenes.* The preferred antibiotics are penicillinase resistant penicillins or first-generation cephalosporins, because *S. aureus* currently accounts for most cases of bullous impetigo, as well as for a substantial portion of nonbullous infections [3].

http://dx.doi.org/10.5772/54304

2.2. Folliculitis

Folliculitis is defined as purulent infection of hair follicles limited to the epidermis. Predisposing factors are hot and humid conditions, obesity, diabetes mellitus, long-term antibiotic or corticosteroid use, and immunosuppression [1].

2.2.1. Clinical presentation and etiology

Folliculitis is characterized by clusters of small, erythematous papules or pustules, usually in body areas prone to friction and heavy perspiration. The face belongs to the most often involved areas. The most common form of folliculitis is *sycosis barbae* a staphylococcal infection related to shaving. (Figure 2)

Figure 2. Sycosis barbae with peripheral cellulitis.

The fungal counterpart of sycosis barbae is *tinea barbae* caused by various dermatophytes. Other possible etiological agents include *Enterobacteriaceae* (often associated with prolonged antibiotic therapy), *Pseudomonas aeruginosa* (associated with hot tubs and wet suits) [6], *Malassezia furfur*, herpes simplex virus, varicella-zoster virus and *Demodex* mites. Non-infectious folliculitis include eosinophilic folliculitis thought to be an autoimmune process directed against the sebocytes [7] and a papulopustular follicular eruption after treatment with epidermal growth factor receptor (EGF-R) inhibitors [8].

2.2.2. Treatment

Uncomplicated superficial folliculitis may respond to improved hygiene supported by use of antibacterial soap. If this simple measure is not sufficient, topical antibiotic cream can be used. Refractory or deep infections may require administration of systemic antibiotics. Selection of appropriate antibiotic is based on knowledge of the common microorganisms involved in the particular type of infection before results of microbiology examination and antibiotic sensitivity tests are available. Herpetic folliculitis responds to oral antivirals (e.g.

valaciclovir). Eosinophilic folliculitis may respond to isotretinoin, metronidazole, UV-B phototherapy, indometacin or itraconazole [1]. Infectious folliculitis may progress to involve deeper layer of the dermis and finally spread to subcutaneous tissue.

2.3. Furuncle and carbuncle

Furuncle is purulent infection involving the hair follicle and extending to surrounding subcutaneous tissue. (Figure 3)

Figure 3. Furuncle of the upper lip. Note progression of infection to right paranasal area.

Furuncles can occur anywhere on hairy skin. A carbuncle is the coalescence of several furuncles with pus draining from multiple follicular orifices. Carbuncles frequently develop on the nape and are more likely to be seen in diabetic patients [3]. In immunocompetent individuals, furuncles and carbuncles are usually caused by *S. aureus*. (Figure 4)

Figure 4. Carbucle of right cheek in an immunocompetent patient.

http://dx.doi.org/10.5772/54304

2.3.1. Clinical presentation

In the face, furuncles are frequently seen on the chin, upper lip and paranasal area. Each lesion consists of an inflammatory nodule and an overlying pustule through which hair emerges. Furuncles of the nasal vestibule can be insidious and not obvious upon cursory examination and their symptoms, namely swelling of upper lip and infiltrate of upper oral vestibule, can lead to false impression of odontogenic infection. In patients affected by a facial furuncle, fever and malaise are common. Lesions are extremely painful and they are surrounded by area of cellulitis and collateral edema. (Figure 5)

Figure 5. Furuncle of the nasal vestibule referred with suspicion of an odontogenic abscess.

2.3.2. Treatment

Small furuncles may burst and heal spontaneously [1]. Application of moist hot dressing can promote drainage. Also gentle removal of overlying crust and necrotic central plug can be helpful; however attempts to express purulent content should be discouraged. Conservative management is preferable and only rarely cases of furuncles or carbuncles progressing into subcutaneous abscess require incision and drainage. In the face, whenever possible, this should be done through intraoral route to avoid facial scarring. Systemic antibiotics are necessary in instances of substantial collateral cellulitis, alteration of general condition and signs of developing facial thrombophlebitis. This initial empirical therapy should be aimed at supposed staphylococcal etiology. Until recently, staphylococcal infections acquired outside of the healthcare setting have been frequently methicillin-sensitive and responsive to a wide range of antibiotics. Since 1980, methicillin-resistent staphylococcus aureus (MRSA) infections have been reported in community outbreaks. These organisms have been called community-acquired or community-associated MRSA, as opposed to hospital acquired MRSA [9]. Hospital acquired MRSA is usually resistant to at least three β-lactam antibiotics and is usually susceptible only to vancomycin, sulfamethoxazole, and nitrofurantoin. Com-

munity acquired MRSA is more likely to be susceptible to clindamycin and has varying susceptibility to tetracycline, fluoroquinolone, erythromycin and vancomycin [10].Outbreaks of furunculosis may occur in families and other groups involved in close personal contact, like prisoners, members of sports teams or outdoor recreation groups [3,11]. Inadequate personal hygiene and exposure to others with furuncles play important role. Control of outbreaks may require bathing with antibacterial soaps, thorough laundering of clothing, towels, bed spreads, separate use of towels and washcloths. Eradication of staphylococcal carriage among colonized persons should be attempted. The prevalence of nasal staphylococcal colonization in the general population is 20–40%, but not all carriers develop recurrent skin infections. Eradication of nasal colonization can be achieved by application of mupirocin ointment twice daily in the anterior nares for the first 5 days each month [12].

2.4. Cellulitis

Cellulitis is diffusely spreading soft tissue infection not associated with underlying suppurative foci. It involves rapidly spreading areas of edema, erythema, and may be accompanied by lymphangitis and regional lymphadenitis [13].

2.4.1. Clinical presentation

In orofacial areas cellulitis is routinely seen as an early stage of odontogenic infections and it is present also at the periphery of other defined skin infections and infected traumatic wounds (Figure 6).

Figure 6. Nonodontogenic facial cellulitis following expression of comedones.

It can also occur as disease per se when organisms enter through breaches in the skin. The breaks in the skin can be small and clinically inconspicuous. Predisposing factors for these infections include conditions that make the skin more fragile or local host defenses less effective, such as obesity, previous cutaneous cuts, venous insufficiency, lymphatic obstruction or other causes [3].Cellulitis of non-odontogenic origin is most commonly caused by β-hemolytic streptococci (usually group A) but may also be caused by other streptococcal species. Less frequently, *S. aureus* may be involved, especially in cases involving penetrating trauma. An etiologic diagnosis of simple cellulitis is frequently difficult and generally unnecessary for patients with mild signs and symptoms [3].

http://dx.doi.org/10.5772/54304

2.4.2. Treatment

Antibiotic treatment alone is effective in most patients with simple cellulitis. Therapy should include an antibiotic active against streptococci. A large percentage of patients can receive oral medications. Suitable agents include dicloxacillin, cephalexin, clindamycin, or erythromycin. Parenteral therapy is indicated for severely ill patients or for those unable to tolerate oral medications. Reasonable choices include a penicillinase-resistant penicillin such as nafcillin, a first-generation cephalosporin such as cefazolin, or clindamycin or vancomycin for patients with penicillin allergies [3]. In cases of uncomplicated cellulitis, 5 days of antibiotic treatment is as effective as a 10-day course [14].

2.5. Erysipelas

Erysipelas is a well-demarcated, painful skin infection characterized by intense erythema. It is almost always caused by β-hemolytic streptococci. The term erysipelas is often used inconsistently and some physicians use it to describe simple cellulitis. The distinction between these two terms relates to the depth of inflammation; erysipelas affects the upper dermis, including the superficial lymphatics, whereas cellulitis involves the deeper dermis and subcutaneous fat. In practice however, distinguishing between cellulitis and erysipelas clinically may be difficult [3].

2.5.1. Clinical presentation

Erysipelas is distinguished clinically from other forms of cutaneous infection by the following two features: The lesions are raised above the level of the surrounding skin, and there is a clear line of demarcation between involved and uninvolved tissue [15]. (Figure 7)

Figure 7. Facial erysipelas.

The skin surface may resemble an orange peel because superficial cutaneous edema surrounds the hair follicles, which causes dimpling. Vesicles, bullae, and cutaneous hemorrhage in the form of petechiae or ecchymoses may develop. Systemic manifestations like fever, tachycardia, hypotension, and leukocytosis may occur, even before the skin abnormalities appear. In older textbooks, pictures of erysipelas of the face characteristically involved the butterfly area, which is nowadays rarely seen.

2.5.2. Treatment

The first-line treatment of erysipelas is intravenous benzyl-penicillin. In penicillin allergic patients, clindamycin may be used. Anti-staphylococcal drugs are considered if patients fail to improve or have features suggestive of staphylococcal infection like bullous eruptions [1].

2.6. Craniofacial necrotizing fasciitis

Necrotizing fasciitis (NF) is rapidly progressing bacterial infection spreading along the deep fascial planes with relative sparing of skin and underlying muscles [16]. Necrotizing infection may involve any combination of dermis, subcutaneous tissue, fascia or muscle. Blood supply to the fascia is typically more tenuous than that of muscle or healthy skin, making the fascia more vulnerable to infectious processes. Additionally, the propensity for fluid collection between involved fascia and adjacent tissues further weakens fascial immune protection [9]. The incidence of NF increases with age and most adult cases occur in patients with underlying chronic illness like diabetes, alcohol/drug abuse, immunosuppression, malignancy or chronic systemic diseases. Most patients with NF have polymicrobial infections with an average of 4.4 organisms isolated per infection [17,18]. Although these polymicrobial infections can spread widely and become life-threatening, they tend to be less aggressive than infections caused by a limited number of highly virulent pathogens. These may cause very rapidly spreading necrotizing infections in an immunologically intact host through production of exotoxins. Such pathogens most commonly include *S. pyogenes* (group A hemolytic streptococcus), group B streptococcus, community acquired MRSA, and *Clostridium spp* [9].Involvement of the head and neck is rare. Only 67 cases were reported between 1945 and 1990. Recently, increased awareness of the condition resulted in more reports of cervicofacial NF appearing in the literature. Cervico-facial NF can be divided into two groups: cervical and craniofacial. Cervical NF is characterized more frequently by polybacterial etiology, mainly odontogenic source of infection, predominance of males and higher mortality. Craniofacial NF does not have gender preference, has lower mortality, but cosmetic and functional consequences are often severe.

2.6.1. Clinical presentation

Craniofacial NF predominantly originates from periorbital regions;d only one microorganism is usually identified from cultures, most commonly group A hemolytic streptococci. Initial symptoms may resemble simple cellulitis or erysipelas. The distinguishing features are fast progression, pain disproportionate to clinical findings, systemic toxicity and presence of gas. Gas is best detected by CT scan. Fully developed specific clinical picture includes edema that extends beyond skin erythema, cutaneous anesthesia, skin ecchymosis that precedes skin necrosis and presence of bullae [8].

2.6.2. Treatment

The promptness of initial surgical debridement is considered decisive for favorable outcome [19,20]. Patients treated surgically on the day of admission have distinctively better progno-

sis. The early incision and debridement of all involved spaces can salvage the skin, which later in the progress of disease succumbs to necrosis due to thrombosis of feeding vessels. All necrotic tissues should be excised, the defects should be kept open and debridement should be repeated until a completely healthy granulating wound is obtained. While the surgical treatment should be performed promptly, it cannot be as aggressive as in the extremities and trunk, where large areas of skin and subcutaneous tissue are often sacrificed. It is necessary to preserve as much of the anatomic structures as possible to avoid significant cosmetic disfigurement and functional limitations. Simultaneous immediate antibiotic therapy should consist of high-dose penicillin G or ceftriaxone in addition to metronidazole and clindamycin for anaerobic coverage. Clindamycin is a potent suppressor of bacterial toxin synthesis, facilitates phagocytosis of *S. pyogenes* by inhibiting M-protein synthesis and causes suppression of lipopolysaccharide-induced monocyte synthesis of TNF-α [21]. Numerous recent published reports claim substantial reduction in mortality and length of hospital stay when hyperbaric oxygenotherapy is used as adjunctive treatment [22].

3. Infected tissue fillers

Injectable soft tissue fillers (ISTFs) are widely popular in facial rejuvenation. ISTFs are usually injected into the deep dermis or dermal – subdermal junction for wrinkles, skin creases or depressed scars [23]. Recently there is a tendency to more frequent use of fillers injected into deep subcutaneous layers for augmentation [24]. ISTFs are effective in treating volume loss and soft tissue redistribution [25].

3.1. Tissue fillers

All ISTFs with exception of autologous fat are foreign alloplasts. Host tissue response to their presence depends on material type [26]. They can be differentiated as volumetric and structural, or fibroplastic, based on the biomechanics of filling effect [27]. Another practically important property is their time of tissue survival differentiating them into temporary, long lasting or semi-permanent and permanent (Table 1).

The most commonly used ISTFs are homogenous polymer gels, both degradable and nondegradable. They are volumetric; the filling effect stems from the gel itself. Common representatives of *degradable homogenous ISTFs* are hyaluronic acid and collagen. They are hydrophilic and closely resemble substances normally present in tissues. Both are degraded by naturally occurring enzymes. *Nondegradable homogenous ISTFs* are represented by polyacrylamide hydrogel and silicone gel. Polyacrylamide gel is hydrophilic, consisting of polyacrylamide, to which water molecules are loosely attached. These water molecules are readily exchanged with those of the surrounding tissue. The macrophages enter the gel, become transformed into fibroblasts that connect and eventually form a vascular fibrous network. Polyacrylamide hydrogel is widely resistant to degradation and phagocytosis [26]. Silicone gel differs from the other polymer gels by being hydrophobic, which results in dispersion in the tissue in the form of rounded vacuoles or droplets, which do not interact with the host

tissue. However they stimulate response of macrophages and foreign body giant cells and are frequently seen within these cells as small round inclusions. *Combination or structural ISTFs* are composed of two components: Solid microparticles dissolved in a transient carrier gel. Microparticles remain in the tissue after the carrier gel has been degraded and thus, elicit a foreign-body reaction, which results in fibrosis responsible for the final filling effect. Some of the microparticles are nondegradable and add to the resulting filling effect, others are slowly degraded over a period of several years [26].

Category	Brand name	Description	Duration
Collagen	Zyderm	Highly purified bovine dermal collagen in a phosphate-buffered physiological saline containing 0.3% lidocaine	2-4 months
	Zyplast	Highly purified bovine dermal collagen cross-linked with glutaraldehyde in a phosphate-buffered physiological saline containing 0.3% lidocaine	3-6 months
	Cosmoderm	Highly purified human-based collagen in a phosphate-buffered physiological saline containing 0.3% lidocaine	3-6 months
	Cosmoplast	Highly purified human-based collagen cross-linked with glutaraldehyde in a phosphate-buffered physiological saline containing 0.3% lidocaine	3-4 months
HA derivatives	Hylaform	HA of rooster combs, 500µ particles, 20 % cross-linked	3-6 months
	Restylane	HA from S. equi, cross-linked with BDDE; NASHA; 400 µ gel particles, 1% cross-linked	6 months
	Perlane	HA from S. equi, cross-linked with BDDE; NASHA; 940-1090 µ gel particles	6-12 month
	Juvederm	HA from *S. equi* cross-linked with BDDE in homogenized gel	3-6 months
	Prevelle Silk	HA from *S. equi* cross-linked with 0.3% lidocainein homogenized gel	2-3 months
CHA derivatives	Radiesse	CHA microspheres 25-45 µ in a gel of water, glycerin, and sodium carboxymethylcellulose	1-2 years
PLL derivatives	Sculptra	Poly-L-lactic acid mixed with mannitol and sodium carboxymethylcellulose	1-2 years
PMM derivatives	Artefill	PMM microspheres 30-50 µ in water-based gel of 3.5% bovine collagen, 0.3% lidocaine, phosphate buffer, and 0.9% NaC	Permanent
Silicone	Silikon 1000	Purified polydimethylsiloxane	Permanent
Hydrogels	Aquamid	97.5% apyrogenic water and 2.5% polyacrylamide	Permanent
	Bio-Alcamid	96% apyrogenic water and 4% polyalkylimide	Permanent
Autogenous fat	-	Hand –held syringe aspirate, usually from hips or abdomen, sedimented or centrifuged	Semi-permanent

Table 1. Overview of ISTFs. HA = hyaluronic acid, CHA = Calcium hydroxylapatite, BDDE = butanediol diglycidyl ether, NASHA = nonanimal stabilized hyaluronic acid, PLL = Poly-L-lactic acid, PMM = polymethylmetacrylate

http://dx.doi.org/10.5772/54304

3.2. Complications of tissue fillers

Complications can be attributed to the product properties, method of delivery and reaction of the recipient's immune system. It is convenient to divide complications according to the time of onset. *Immediate complications* are usually related to faulty application. They include palpable or visible implants due to superficial injection, uneven distribution, overcorrection, undercorrection and hypersensitivity. The most serious immediate complication is vascular compromise by mechanism of either direct arterial embolization of filler or local overfilling leading to venous compression in the treated area [28].*Early onset complications* appear between 2 – 3 days or weeks after injection. Early non-inflammatory nodules are localized accumulations of filler material. Early inflammatory nodules are red, painful and should be treated as infections. If there is any fluctuation or impending skin erosion, incision and drainage with culture should be performed. Empiric antibiotic treatment should begin with a macrolide or tetracycline and should be continued for 4 to 6 weeks [29]. *Late* (several weeks to 1 year) *or delayed* (>1 year) *complications* usually present as nodules or subdermal masses. Stimulatory fillers such as polylactic acid and calcium hydroxylapatite, or silicone may give rise to fibrotic nodules. Immune response to filler material or chronic infection can lead to formation of granulomas [30-34]. They should be treated as foreign body infections with macrolide or tetracycline, and strong consideration should be given to two-drug therapy. If there is no response in 7 to 10 days, intralesional corticosteroids can be injected while maintaining the patient on oral antibiotics [29]. Infrequent but the most serious late complications of ISTF present themselves as acute facial cellulitis or abscess.

3.3. Role of biofilms

Delayed complications of ISTFs have been attributed to biofilms [35]. Biofilms are defined as a structured community of microorganisms encapsulated within a self-developed polymeric matrix and irreversibly adherent to a living or inert surface [36]. They are also often characterized by structural heterogeneity, genetic diversity and complex community interactions. They respond to stimuli, grow and maintain a homeostatic environment. Extracellular polymeric matrix of biofilms may interfere with macrophage phagocytosis and allow for easier exchange of extrachromosomal DNA plasmids encoding antimicrobial resistance. All surgical implants like orthopedic appliances, heart valves, indwelling catheters, stents or other forms of foreign material may be compromised by biofilms. Active clinical infections can flare up weeks, months and even years after initial surgery. Bacteriemia caused by dental treatment, contaminated surgery, or trauma can activate infective response of a chronic biofilm. Once the biofilm has been activated, it leads to acute purulent infection. The active infection can be controlled with antibiotic therapy, but the underlying biofilm can persist and generate a recurrence [27,37,38]. The biofilm theory remains a popular explanation for late infectious complications of ISTFs; but it has been recently challenged and requires further proof [39].

3.4. Clinical presentation and diagnosis

Acute purulent inflammation caused by infected facial ISTF closely resembles acute odontogenic infection: it causes painful facial swelling, redness, extensive collateral edema and palpable in-depth fluctuation. Deep buccal space and periorbital region are most frequently involved. The general condition is usually altered by fever, malaise and pain. Laboratory sings of acute bacterial infection are present. However, intraoral clinical and x-ray examination fails to discover an odontogenic source of infection, and even if possible odontogenic infectious focus is identified, typical signs of acute odontogenic infection, such as oral vestibule swelling and redness, tooth mobility, or sensitivity to axial percussion are missing [40]. (Figure 8)

Figure 8. A. 32y old female underwent cheek augmentation by injections of unknown substance in a cosmetic salon 3 years earlier. One week before admission she underwent another injection in periorbital areas. B. Foreign glue-like material with blood admixture drained from the right buccal space. C.Large amount of foreign material mixed with sanguinopurulent exudate drained from the left buccal space. D. Sonography (US) of left cheek. E. US of right cheek; note hypoechogenic loci with scattered hyperechogenic foci of foreign material in the subcutaneous layer.

Many patients fail to report filler injections on initial interview because they do not consider them as medical procedures or are embarrassed[41,42]. Patients with acute facial infections of uncertain origin should therefore be specifically questioned about a history of cosmetic procedures. Despite of it, some patients will admit application of ISTF only later, when they are confronted with finding of foreign material in a drained exudate.Ultrasound (US) examination can be helpful in establishing the presence of ISTF and its precise location [41,42]. CT imaging may be indicated if there is a suspicion of infection spread, especially orbital cellulitis.

3.4.1. Treatment

Treatment should follow established principles of dealing with acute purulent infection i.e. eliminate source of infection, drain involved anatomical spaces and provide antibiotic and supportive therapy. When ISTF becomes infected, antibiotic treatment can only mitigate the process and sooner or later after discontinuation of medication recurrence is inevitable. It is therefore necessary to remove all infected material, which is usually identical with drainage of involved spaces. Only small amounts of ISTFs can be removed by aspiration [43], thus in cases of deep abscesses incision and drainage is the treatment of choice. To avoid facial scar-

ring, intraoral incision is the preferred route. More than one deposit of filler material can be present in any treated area and while one focus is drained another one can remain dormant and consequently undetected on clinical examination. This can lead to recurrence [40]. Characteristic histopathologic findings allow the identification of the specific filler agent. This can be important especially in litigation cases where a number of different fillers have been injected in the same site over the time, or where patients had not been correctly informed about fillers and potential risks [44].

4. Cervico-facial lymphadenitis

A disease process involving lymph nodes (LNs) is referred to as lymphadenopathy. Lymphadenopathies have multiple etiologies, the most common of which are infection, neoplasia and autoimmune diseases. Inflammation of LN is known as lymphadenitis. The lymphatic system of the cervicofacial region serves as the initial line of defense against infections of all structures within the head, neck, and upper respiratory tract [45].

4.1. Anatomy and pathophysiology

Diagnosis of the lymphatic infections must be based on the knowledge of anatomic location of LNs, the area and the pattern of lymphatic drainage, and their defense mechanism [45,46]. The lymphatic system of the head and neck contains about 300 nodes, and the extranodal lymphatics of the palatine, pharyngeal and lingual tonsils are known as the lymphatic ring of Waldayer. All the lymphatics from the head and neck drain into the deep cervical LNs [47]. Superficial nodal enlargement usually reflects invasion through an epithelial surface (e.g. skin, oral mucosa), whereas deep nodal enlargement results from an infectious process involving more central structures (e.g. middle ear, posterior pharynx).[45] Lymph nodes contain T- and B-lymphocytes as well as antigen-presenting macrophages (dendritic cells). Tissue lymph enters the LN via one or more afferent vessels and percolates through a series of reticuloendothelial-lined channels that coalesce and drain through an efferent lymphatic vessel. [45] Once infection occurs, a series of LN reactions follow according to the type and nature of the infectious agent. These will result into signs and symptoms with presentation, which can be acute, subacute, or chronic and can be localized or generalized. Infection of the LNs of the orofacial region can be bacterial, viral, protozoal or fungal. The most common pathogens causing lymphadenitis in the orofacial region include bacterial pathogens as *S. aureus, S. pyogenes*, *Bartonella Henselae*, *Francisella tularensis*, *Treponema pallidum*, as well as tuberculous and non-tuberculous *Mycobacteria*. Many cases of cervical adenopathy associated with viral illnesses are due to reactive hyperplasia. Causes of the associated upper respiratory tract infection include rhinovirus, parainfluenza virus, influenza virus, respiratory syncytial virus, coronavirus, adenovirus, and rheovirus. Other common viral etiologies include cytomegalovirus and Epstein-Barr virus. Less frequent etiologies include mumps, measles, rubella, varicella, herpes simplex, human herpes virus 6 (roseola), and coxsackie viruses. Approximately 10% of patients with acquired infections due to *Toxo-*

plasma gondii also present with cervical lymphonoditis. Fungal infections of orofacial LNs are mentioned later.

4.2. Acute bacterial lymphadenitis

Most cases of acute bacterial lymphadenitis occurs in children aged 1 to 4 years. Forty percent to 80% of cases in this age group are due to *S. aureus* or *Strep. pyogenes*. Lymphadenitis due to *Stepr. pyogenes* should be suspected if the patient presents with the typical vesicular, pustular, or crusted lesions of impetigo involving the face or scalp. The most commonly involved LNs in decreasing order of frequency are the submandibular, upper cervical, submental, occipital, and lower cervical nodes. [45]

4.2.1. Clinical presentation and diagnosis

Patients typically present with concomitant pharyngitis, tonsillitis, acute otitis media, or impetigo. Acute cervical lymphadenitis can also occur following animal bites or scratches. However, there may be a time gap between initial infection at the site of entry and lymphadenitis. LNs enlargement is mostly unilateral, associated with systemic manifestations, such as fever, and malaise. Infected LNs tend to be quite tender with collateral cellulitis and edema. Erythema and increased temperature of the overlying skin are signs of impending liquefaction. Diagnosis is usually based on the clinical picture. Laboratory tests are nonspecific and seldom required. In contrast, laboratory evaluation plays a crucial role in determining the etiology of subacute, chronic, and generalized lymphadenopathy.

4.2.2. Treatment

Because staphylococci and streptococci are the most common pathogens, initial therapy usually includes a β-lactamase resistant antibiotic; this agent is used because of the high incidence of penicillin resistance in isolated staphylococci. Other treatment options include cephalexin, oxacillin, or clindamycin. Very young patients or patients with severe symptoms may require hospitalization for initiation of parenteral antibiotic therapy and close observation. For older patients with dental or periodontal disease, the antibiotic regimen should include coverage for anaerobic oral flora (i.e., penicillin V or clindamycin). Reports from multiple centers have documented an increasing frequency of community-acquired methicillin-resistant *S. aureus* (CA-MRSA) skin and soft tissue infections, including lymphadenitis. Failure to respond to appropriate first-line antibiotic therapy should prompt consideration of expanding coverage to include methicillin-resistant strains of *S. aureus*. [45] Therapy is usually administered for 10 days and continued for at least 5 days beyond resolution of acute signs and symptoms. If a primary site is identified, cultures should be obtained and treatment directed to that site as well. There should be marked clinical improvement after 2 to 3 days of therapy, although complete resolution of nodal enlargement may require several weeks [45].If there is no response to conservative therapy, an attempt to identify etiologic agent can be done by fine needle aspiration (FNA) under US control. The aspiration of an affected node is successful in 60% to 88% of cases [46]. Fluctuance develops in about 25% of patients. Adequate drainage should be ascertained by incision under GA and no loculations

http://dx.doi.org/10.5772/54304

or pockets of pus left behind. Specimens of pus should be sent for Gram stain, aerobic and anaerobic cultures, as well as for acid-fast stains and mycobacterial culture. In immunocompromised patients also KOH preparation, fungal cultures and tissue biopsy should be considered. (Figure 9)

Figure 9. A. Abscessed submandibular lymph node in 4y old boy with a 10-day history of submandibular swelling treated by amoxicillin. Infection source was not indentified. B. Culture of drained pus yielded *S. aureus*.

Drainage should be maintained by insertion of drains (e.g. Penrose or corrugated rubber drain), left in place for 2-3 days. Dressings are changed whenever it becomes saturated by exudate. Antibiotic therapy can be discontinued as soon as clinical improvement is obvious.

4.3. Cat scratch disease

Cat scratch disease (CSD) follows inoculation of *Bartonella Henselae* through broken skin or mucous membranes. *B. Henselae* is a small, pleomorphic gram negative bacillus. The reservoir *for B. Henselae* is the domestic cat and 1/3 of cats or more are infected. Cat fleas become infected and replicate *B. Henselae* following ingestion of blood from an infected cat. Experimentally, *B. Henselae* was transmitted by transferring fleas from bacteremic cats to specific pathogen-free cats. In another experiment, cats have been infected with *B. henselae* by intradermal inoculation of feces derived from infected fleas. Although the exact mode of transmission of *B. henselae* to humans remains unclear, contamination of the claws or teeth with infected flea feces may be required for transmission. [47]

4.3.1. Clinical presentation and diagnosis

CSD presents as regional lymphadenitis associated with a characteristic skin lesion at the site of inoculation. An erythematous skin papule or pustule typically develops 3-10 days after contact with an infected cat (scratch, bite or lick). The patient may suffer low-grade fever and malaise, anorexia, headache and splenomegaly. Regional lymphadenitis develops 5 days to 2 months later. Often the primary site of involvement has resolved by the time lymphadenopathy is noted. The most common sites of lymphadenopathy are the axilla (52%) and the neck (28%). Patients usually present with a single large tender node. Involved LNs undergo sequential changes of lymphoid hyperplasia, granuloma formation, microabscess development, and in some cases suppuration. The most common atypical presentation of

CSD is Parinaud's oculoglandular syndrome (POS). This occurs in up to 17% of CSD patients due to autoinoculation of the eye by rubbing it with their hands after cat contact. POS is manifested either as conjunctivitis with parotid swelling caused by intraparotid lymphadenitis or as an ocular granuloma. Diagnosis of CSD has traditionally required the presence of 3 of 4 criteria: Contact with a cat resulting in a primary lesion, regional lymphadenopathy in the absence of other causes of lymphadenopathy, a positive skin test, and the presence of characteristic histopathological features. The CSD skin test is performed by intradermal injection of heat-inactivated material obtained from a node of a patient fulfilling the diagnostic criteria of the disease. Because of safety concerns about the use of human-derived reagents and the lack of widespread availability, serologic testing for antibodies to *B. henselae* is considered a suitable alternative to skin testing. Aspirate from lymph node contains no bacteria that can be cultured by routine methods. Isolation of *Bartonella* is typically time-consuming, often requiring a 2- to 6-week or longer incubation for primary isolation. The resulting isolate must then be identified by biochemical or genetic methods. [48]

4.3.2. Treatment

The disease is usually self-limited. Treatment is mainly supportive, with reassurance, hot moist compresses and analgesics. It may be necessary to aspirate pus or surgically remove an excessively large lymph node. Benefits of antibiotic therapy is doubtful. Azithromycin has been shown to be associated with more rapid resolution of nodal enlargement. Tetracycline or erythromycin therapy may also be helpful. [49]

4.4. Tularemia

Tularemia is a highly contagious disease caused by *Francisella tularensis*, a fastidious gram-negative coccobacillus, characteristically isolated as small, poorly staining gram-negative rods seen mostly as single cells. *Francisella tularensis* is maintained in the environment by various terrestrial and aquatic mammals such as ground squirrels, rabbits, hares, voles, muskrats, water rats, and other rodents. In many parts of the world, the disease caused by *F. tularensis* is known under colloquial names such as rabbit fever, hare fever, deerfly fever, and lemming fever. A wide range of arthropod vectors have been implicated in the transmission of tularemia between mammalian hosts, specially ticks, biting flies and mosquitoes. [51]

4.4.1. Clinical presentation and diagnosis

Tularemia in humans can occur in several forms, depending to a large extent on the route of entry. Many cases of disease caused by lower-virulence strains are undiagnosed. The most common form of the disease is ulcero-glandular tularemia, which usually occurs as a consequence of a bite from an infected arthropod vector. After an incubation period of 3 to 5 days, the patient experiences the sudden onset of flu-like symptoms, especially chills, fever, headache, and generalized aches. An ulcer forms at the site of infection. Bacteria are disseminated from this site via the lymphatic system to regional LNs. The enlargement of these LNs often resembles the classical bubo associated with bubonic plague. During early bacteremic

http://dx.doi.org/10.5772/54304

phase of the infectious bacteria may be disseminated also to other tissues such as the spleen, liver, lungs, kidneys, intestine, central nervous system, and skeletal muscles. A rare variation of ulcero-glandular disease is oculo-glandular tularemia, where the conjunctiva is the initial site of infection, usually as a result of the transfer of bacteria on the fingertips. The disease is marked by the appearance of ulcers and nodules on the conjunctiva, and without treatment the infection spreads to the regional LNs. The ingestion of infected food or of bacteria in drinking water can result in oropharyngeal tularemia, characterized by sore throat with enlargement of the tonsils and the formation of a yellow-white pseudo membrane, accompanied by swollen cervical LNs. Other, more serious clinical forms of disease are gastrointestinal and pneumonic tularemia. Isolation of bacteria from clinical specimens is possible; however, it needs a special culturing technique. Because of the difficulty in culturing *F. tularensis*, most cases of tularemia are diagnosed on the basis of clinical picture and/or serology. The detection of serum antibodies is most frequently achieved by agglutination or an ELISA. [51]

4.4.2. Treatment

The drugs of choice for the treatment of tularemia include streptomycin, gentamicin and ciprofloxacin. Ciprofloxacin was the antibiotic with the lowest level of therapeutic failure and with the fewest side effects and was also shown to be suitable for children and in a case where relapse was evident after initial gentamicin therapy [52].

4.5. Syphilis

Syphilis is a sexually transmitted disease caused by infection with *Treponema pallidum*, a Gram-negative bacterium, which is an obligate internal parasite of spiral shape. Natural infection with *T. pallidum* is limited to the human host and is usually transmitted by sexual contact; the infectious lesion is on the skin or mucous membrane. *Treponema pallidum* rapidly penetrates intact mucous membranes or microscopic dermal abrasions and, within a few hours, enters the lymphatics and blood to produce systemic infection. The disease progresses in a series of overlapping stages: primary, secondary, latent, and tertiary. Disease transmission between mother and child in utero results in congenital syphilis. [53]

4.5.1. Clinical presentation and diagnosis

Incubation time from exposure to development of primary lesions at the site of inoculation averages 3 weeks but can range from 10-90 days. A papule develops at the site of infection and breaks down to form an ulcer - chancre. The lesion is usually singular, painless, with base infiltration and hardened high margins. After the appearance of the chancre, regional lymphadenopathy occurs. Secondary syphilis develops about 4-10 weeks after the appearance of the primary lesion. Systemic manifestations include malaise, fever, myalgias, arthralgias, lymphadenopathy, and rash. Widespread mucocutaneous lesions are observed over the entire body and may involve the palms, soles, and oral mucosa. The skin lesions are usually macular, discrete, reddish brown, and 5 mm or smaller in diameter; however, they can be pustular, annular, or scaling. The two principal oral lesions associated with secondary

syphilis are mucous patches and maculopapular lesions involving the hard palate and manifesting as flat to slightly raised firm red lesions. Of these, wet mucous patches are the most contagious. Even untreated the patient will eventually lose infectivity and pass into latent stage. Tertiary syphilis develops 4-8 years later with progressive multi-organ involvement. The typical tertiary stage lesion is gumma, which in orofacial regions usually involves the hard palate and tongue. [54,55] Regardless of the stage of disease and location of lesions, histopathologic hallmarks of syphilis include endarteritis and a plasma cell rich infiltrate. However, lesional histopathology is not diagnostic. Definitive diagnostic methods are dark field examination and direct immunoflurescent tests of lesional exudates that detect presence of *Treponemata*, but are applicable only in presence of primary or secondary lesions. Diagnosis is commonly made by serologic testing; however, no one test is sufficient in itself. The most commonly used screening tests are the Rapid Plasma Reagin (RPR) and the Venereal Disease Research Laboratory (VDRL). These are non-specific, non-treponemal tests that use reagin, cardiolipin-lecithin-cholesterol antigens to test for antibodies against *T. pallidum*. The most specific serologic tests for syphilis are the fluorescent treponemal antibody absorbed assay (FTA.Abs) and the microhemagglutination essay for antibody to *T. pallidum* (MHA-TP). These detect antibodies that are produced against treponemal antigens. [54]

4.5.2. Treatment

Parenteral penicillin G is the drug of choice is for all stages of syphilis. Selection of the appropriate penicillin preparation is important, because *T. pallidum* can reside in sequestered sites like CNS and aqueous humor that are poorly accessed by some forms of penicillin. Penicillin desensitization may be used in patients with known penicillin allergies if necessary. The Jarisch-Herxheimer reaction is an acute febrile reaction frequently accompanied by headache, myalgia, fever, and other symptoms that usually occur within the first 24 hours after the initiation of any therapy for syphilis. Patients should be informed about this possible adverse reaction. [56] Studies on the efficacy of ceftriaxone and azithromycin as an alternative for the treatment of syphilis in penicillin allergic patients are presently inconclusive, and Center for Disease Control (CDC) guidelines neither support nor refute its use. [53]

4.6. Infectious mononucleosis

Infectious mononucleosis (IM), a common cause of cervical lymphadenitis, is caused by Epstein-Barr virus (EBV), and is its most frequent clinical manifestation. IM is called also “glandular fever”. EBV is ubiquitous herpes virus associated with nasopharyngeal carcinoma, Burkitt’s lymphoma, Hodgkin’s disease, and other lymphoproliferative disorders in immune-deficient individuals. Young children most likely acquire primary EBV infection from close contact that involves exchange of oral secretions via shared items such as toys, bottles, and utensils. Before the age of 10, primary infection is usually asymptomatic or produces an acute illness that is often not recognized as being due to EBV. In adolescents and young adults, primary EBV infection is acquired chiefly by direct intimate oral contact which allows for salivary exchange, and frequently presents as IM. That is where another colloquial name “kissing disease” comes from. Aside from oral transmission, there are reports about

transmission by sexual intercourse, contaminated blood, transplanted hematopoietic cells, solid organs, or by intrauterine transmission. [57]

4.6.1. Clinical presentation and diagnosis

Infectious mononucleosis most often begins insidiously, with vague malaise, followed several days later by fever, fatigue, sore throat, and swollen posterior cervical lymph nodes. Some patients experience an abrupt influenza-like onset, with fever, chills, and body aches. Hepatitis, documented by abnormal liver function tests, is seen in 80% of cases. A useful clinical clue unique to primary EBV infection is eyelid edema, which gives the patient a slit-eyed appearance and may be accompanied by facial puffiness. Virtually all patients given penicillin derivatives develop a rash. Complications include conjunctivitis, hemophagocytic syndrome, myocarditis, neurologic diseases other than meningoencephalitis, pancreatitis, parotitis, pericarditis, pneumonitis, psychological disorders, and splenic rupture. [57]The diagnosis of infectious mononucleosis cannot be made on clinical grounds alone. The appropriate laboratory tests include detection of the presence of atypical lymphocytes, Paul-Bunnel test, monospot test, and detection of EBV antibodies against the viral capsid.

4.6.2. Treatment

The treatment is mainly symptomatic during periods of fever and malaise and includes limitation of activities, supplementation fluids, nutrition, antipyretics and analgesics. Corticosteroids are indicated for management of complications, such as impending airway obstruction, autoimmune anemia, and autoimmune thrombocytopenia. A number of antiviral drugs have been also used with varying degree of efficiency. [58]

4.7. Rubella

Rubella is an acute febrile illness of viral origin characterized by rash and lymphadenopathy that affects children and young adults. *Rubella virus* is a member of the *Togaviridae* family but in spite of that, it is not transmitted by arthropods. The usual way of transmission is by droplets from the nose or throat. Rubella is commonly known as German measles or 3-day measles. [59] Infection during the early pregnancy may result in serious congenital malformations and mental disability. Widespread immunization against rubella is critical to preventing this so called congenital rubella syndrome. [60]

4.7.1. Clinical presentation and diagnosis

Rubella infection begins with low grade fever and swollen, tender lymph nodes, usually in the back of the neck or behind the ears. Morbilliform rash appears on the face and spreads downward to the trunk and extremities. As it spreads down, it usually clears on the face. This rash is often the first sign of illness that a patient or a parent notices. No feature of the rash is pathognomic and it looks like many other viral rashes. Other symptoms of rubella, more common in teens and adults, include headache, loss of appetite, mild conjunctivitis with rhinitis, swollen lymph nodes in other parts of the body, and arthralgia.A clinical diag-

nosis of rubella may be difficult, because many exanthematic diseases may mimic rubella infection. The laboratory diagnosis of rubella can be made either though serologic testing or by viral culture. The serologic diagnosis consists of demonstrating the presence of rubella-specific IgM antibody in a single serum sample or observation of a significant (>4-fold) rise in rubella-specific IgG antibody titers between the acute and convalescent serum specimens drawn 2-3 weeks apart. The nasopharyngeal or throat swab taken 6 days before and after onset of rash is a good source of rubella virus that can be cultured and identified. [59]

4.7.2. Treatment

Rubella is mild self-limited illness and no specific treatment is indicated. Maintenance of good hydration, especially replacement of fluids lost through diarrhea or emesis, is the mainstay of management. Intravenous rehydration may be necessary if dehydration is severe. In children and patients with clinical signs of vitamin A deficiency vitamin A supplementation should be considered. Post exposure prophylaxis should be considered in unvaccinated contacts. [59]

4.8. Toxoplasmosis

Toxoplasma gondii is a coccidian protozoan of worldwide distribution that can infect a wide range of animals, birds as well as humans. The cat was identified as the definitive host; however *T. gondii* is unusual in that its propagation does not require passage through the definitive host (felids in whose intestinal tissues the sexual cycle occurs). About 1/3 of the world's human population is estimated to be infected. Humans can be infected from tissue cyst present in raw or undercooked meat, or from oocysts that are the product of sexual cycle in cat intestines. Oocysts are very resistant to harsh environmental conditions and are highly infectious. [61] Avoidance of cats during pregnancy is essential, because of the risk of transmission to the fetus with serious consequences, especially when transmission occurs in early pregnancy.

4.8.1. Clinical presentation and diagnosis

Primary infection in the immunocompetent individual is usually asymptomatic. In approximately 10% of this patient group, a non-specific and self-limiting illness is manifested most typically by isolated cervical or occipital lymphadenopathy lasting for less than four to six weeks. Toxoplasmic lymphadenitis most frequently involves a solitary lymph node without systemic symptoms or extranodal disease. The lymph nodes are usually discreet, non-tender, and do not suppurate. Toxoplasmosis can also cause localized lymphadenopathy outside the head and neck areas or generalized lymphadenopathy. After the acute phase, almost all patients will remain chronically infected with tissue cysts that are dormant and cause no clinical symptoms. In contrast, toxoplasmosis in patients who are immunocompromised can be a life-threatening infection. In an immune-deficient patient, the infection can become acutely disseminated and result in pneumonitis, chorioretinitis and encephalitis. [62,63]Toxoplasmic lymphadenitis is most often diagnosed by lymph node biopsy and/or serological assays. Pathological features diagnostic of toxoplasmic lymphadenitis include a re-

active follicular hyperplasia, irregular clusters of epithelioid histiocytes encroaching on and blurring the margins of the germinal centers, and focal distention of sinuses with monocytoid cells. The presence of these histological abnormalities alone, when typical, can suffice for the diagnosis. However, to increase the diagnostic yield, serological testing (ELISA, PCR, and IFA) is recommended both in patients with the classical histological features and in those patients with atypical histological findings. Fine needle aspiration cytology (FNAC) is rarely useful for the diagnosis, since it allows visualization of only a few isolated cells and does not permit the evaluation of lymph node architecture. *Toxoplasma gondii* may be cultured in the presence of living cells where the typical intracellular and extracellular organism can be seen. [63]

4.8.2. Treatment

Acute infection can be treated with a combination of pyrimethamine and sulfadiazine or trisulfapyrimidines. Treatment with pyrimethamine, sulfadiazine and folinic acid is usually reserved for patients who are immunocompromised and those patients who are immunocompetent but have severe or persistent symptoms. Duration of treatment varies from 2-4 months depending upon resolution of clinical signs and symptoms. Alternative drugs include spiramycin, clindamycin, trimethoprime-sulfamethoxazole and various other sulfonamide drugs. Spiramycin is recommended for use in pregnancy till delivery. [63]

5. Orofacial tuberculosis

Tuberculosis (TB) is chronic granulomatous infection caused by *Mycobacterium tuberculosis* or *Mycobacterium bovis.* TB is one of the most prevalent diseases in the world. In 2010, there were estimated 12 million prevalent cases (178 cases per 100 000 population) and 1.1 million deaths worldwide among human immunodeficiency virus (HIV) negative persons. Of the 8.8 million incident cases in 2010, 1.0 million – 1.2 million (12–14%) were among people living with HIV. Approximately 1.4 million people died of TB in 2010. TB is the second leading cause of death from an infectious disease worldwide, after HIV. Most of the estimated number of cases in 2010 occurred in Asia (59%) and Africa (26%). The five countries with the largest number of incident cases were India, China, South Africa, Indonesia and Pakistan. The high incidence of TB in developing countries is associated with poor hygiene. [64] Primary disease most commonly affects the lungs, with secondary infection to other organs and tissues, either by hematogenic or lymphatic spread, or by inoculation of infected sputum. Extrapulmonary TB (EPTB) constitutes 15% to 20% of all cases of TB among immunocompetent adults, and it accounts for more than 50% of the cases in HIV positive individuals. [65] The proportion of EPTB among all TB cases in different parts of the world has increasing tendency. [66] Most of the extrapulmonary TB infections are secondary. [65] Head and neck TB is responsible for nearly 10% of all extrapulmonary manifestations of the disease. [67] Primary infection of orofacial region can happen by droplet transmission from a TB patient and affect Waldeyer's ring, with secondary spread to lymphatic nodes. Lymph nodes of the neck can also be affected by spread from the pulmonary focus via hematoge-

nous or lymphatic routes [68]. TB cervical lymphadenitis seems to be the most frequent manifestation of EPTB in the maxillofacial region [68-71]. Oral mucosa TB is relatively uncommon. The intact oral mucosa acts as a natural barrier to the mycobacterial invasion because of its epithelial thickness, tissue antibodies, oral saprophytes, and salivary enzymes, as well as cleansing action of the saliva [72]. Oral primary or secondary infection is possible if natural barrier of healthy mucosa or skin is violated by pre-existing inflammatory process or trauma. Consumption of infected milk is thought to be an important source of infection of the oral cavity [68]. Secondary infection by direct inoculation from a pulmonary source to the larynx, oral cavity and nasopharynx is also possible. Some reports cite oral mucosa [73] or mandible and adjacent masticatory muscles [74] as the most frequent location of orofacial TB. Involvement of the temporomandibular joint (TMJ) has been repeatedly reported in recent years and is considered by some authors as frequently misdiagnosed condition [67,75-7]. Other infrequent head and neck locations reported have include the eye, ear, salivary glands, nose, thyroid, nasopharynx, retropharyngeal space and larynx [68,69,71].

5.1. Clinical presentation and diagnosis

Because of frequent absence of classic symptoms associated with pulmonary disease, such as fever, cough, weight loss, anorexia, and night sweats, diagnosing EPTB can be a clinical challenge [76]. In the neck, according to ENT literature, the posterior triangle nodes, upper jugular and supraclavicular nodes are most commonly involved [68-70]. Maxillofacial literature describes submandibular and submental nodes as the most often involved lymphatic nodes [73,74,78]. This discrepancy obviously reflects referral bias. Most patients present with an isolated discrete node or a collection of matted nodes. Fluctuant mass or draining sinuses are seen in less than 10% of cases [69,78-9] (Figure 10).

Figure 10. A. 35y old male presented with a 6-month history of lasting recurrent abscesses in the left submandibular area. He was repeatedly prescribed courses of antibiotics without success. B. CT examination revealed multiple enlarged lymphatic nodes with signs of liquefaction. C. Aspiration yielded several ml of pus, which was sent for microbiology examination. Culture results reported presence of *Mycobacteriium tuberculosis*. D. After 6 months of combined chemotherapy with INH, rifampicin and ethambutol.

The most frequent locations of oral TB are tongue, vestibular buccal mucosa, gingiva, hard and soft palate. Sometimes the initial presentation can be non-healing extraction wound. Lesions of the oral cavity usually present as painful ulcer and thus mimic squamous cell carcinoma. Most TB lesions are located in the anterior portions of the oral cavity such as the

buccal mucosa or vestibule area near the corner of the mouth or lower lip; in contrast the usual location of oral squamous cell carcinoma is on the lateral border of the tongue and retromolar area [73]. Underlying bone can also get directly infected but TB osteomyelitis is probably more frequently due to hematogenic spread. The posterior mandible is more commonly involved, especially the ramus of the mandible and the attached musculature. Rich arterial supply of the masseter and medial pterygoid muscles can play important role as the lesions are frequently seen to involve the outer cortical plates, whereas the medullary bone is unaffected [74]. Tuberculosis of TMJ can be a hematogenic infection or develop by progression from TB otitis media [68,77]. Presenting clinical features are pain, trismus, and swelling. Thus, TMJ TB should be considered in the differential diagnosis of patients presenting with pain and stiffness of the joint [76]. Diagnostic process should begin with imaging methods depending on a location of the lesion: US and CT with contrast or MRI for neck lesions, panoramic X-ray and/or CT for facial bone lesions, MRI for evaluation of TMJ. Patients suspected of EPTB should have biopsy with acid fast smear, histopathology and culture of the lesion, chest radiograph, and sputum culture. While active pulmonary TB occurs infrequently in immunocompetent patients with EPTB, HIV seropositive patients with normal chest films can have active pulmonary TB. Mycobacterial sputum cultures should be performed in this group of patients regardless of chest film results [79]. FNAC is a minimally invasive diagnostic tool and has an established role in the diagnosis of EPTB, including oral lesions. It is easily performed and can be easily repeated. The complication rate following FNAC is small compared to surgical biopsy. Cytology smears should show the epithelioid granuloma with or without necrotic material. In patients with equivocal results on FNAC there may be need for open biopsy when the suspicion of TB is high. Granulomas with necrosis, which are more specific for TB, are more common in excisional biopsy specimens compared with FNAC specimens[79]. Patients with lymphatic EPTB show variable response to the tuberculin skin test [78]. The Mantoux test is positive in more than 90% cases of osteoarticular TB. However, a positive test may also indicate a hypersensitivity reaction to tuberculin proteins or a previous exposure rather, than active TB infection [76]. The diagnosis of TB in the absence of a positive culture requires a combination of epidemiologic and histopathologic criteria as well as a trial of antituberculous medication [79].

5.2. Treatment

Conservative therapy with anti-tuberculous drugs (isoniazid, rifampicin, pyrazinamide, ethambutol and streptomycin) is the mainstay of treatment. In majority of patients the therapy is started based on pathology results while waiting for culture results, which are not available before 3 weeks. Treatment duration is typically 6 months, and this duration has been shown to be as effective as regimens of 9–18 months. [79] Adjuvant surgical intervention can be necessary in cases of TB lymphadenitis with large, matted lymph nodes or fluctuant, cold abscesses in the neck. However, these nodes often lie adjacent to great vessels and, if due care is not exercised, injury to great vessels or incomplete excision of the nodes may occur. TB of the TMJ may require abscess drainage, sequestrotomy or even condylectomy. TB of the facial bones may require sequestrectomy and/or sauceriation. TB of the saliva-

ry gland, oral cavity and ear respond very well to antituberculous therapy and do not require surgical management.

6. Atypical (non-tuberculous) mycobacteriosis

Nontuberculous mycobacteria (NTM) are ubiquitous organisms that typically reside in soil. They are facultative pathogens and their pathogenicity depends on the interaction between the microorganism and the host's immune system. About 90% of NTM infections involve the pulmonary system. Other frequent locations are lymph nodes, skin, soft tissues and bones. [80] Even less frequent are central nervous system disease, keratitis, and otitis media [81]. The most frequently isolated species is *Mycobacterium avium* and *M. intracellulare* (known together as M. avium-intracellulare complex), followed by *M. scrofulaceum*, *M. kansasii*, *M. malmoense*, and *M. hemophilum*. However, a growing number of previously unrecognized slow-growing mycobacteria have been recently implicated. Some NTM species are ubiquitous and others have more restricted distribution. Evidence of human-to-human transmission is lacking.[82-3]

6.1. Clinical presentation and diagnosis

In orofacial region the most prevalent location of infection by NTM are lymphatic nodes. The disease most commonly affects children with peak incidence at 1-5 years of age [82-4]. The port of entry is probably oropharyngeal mucosa and the lymphatic vessels that drain the mouth and pharynx. Primary infectious focus can also be facial skin [84]. The disease is usually unilateral and affects jugulodigastric, submandibular, parotid/pre-auricular, submental, and posterior triangle lymph nodes. Most patients are otherwise healthy and a chronic neck mass that does not respond to antimicrobial therapy is their sole clinical sign. On average the cervicofacial lymphadenopathy is present for 12 weeks before the proper diagnosis is established and treatment initiated [82]. The size of the infected lymph node can range from 1 to 6 cm and is typically non-tender. The nodes can occasionally liquefy, which is accompanied by fixation of overlying skin, violaceous discoloration, parchment-like transformation of skin and finally formation of draining sinus. In untreated cases, healing usually occurs by unsightly fibrotic scaring and calcification. (Figure 11)

Contrast-enhanced CT imaging picture characteristic of NTM lymphadenitis is asymmetrical lymphadenopathy with contiguous, low density ring-enhancement. Inflammatory changes involving the subcutaneous tissue, such as fat stranding are absent but necrotic foci within skin and subcutaneous tissue are not uncommon [85]. PPD testing has been shown to produce variable results. NTM-specific antigen skin testing can be a useful diagnostic measure, but it is rarely readily available [82]. Diagnosis depends upon the identification of NTM. This requires obtaining material for culture. Tissue samples by FNAC or tissue biopsy are usually necessary, because sampling of draining or ulcerated lesions by swabs do not provide sufficient diagnostic yield. FNAC is the preferred diagnostic technique for patients who do not undergo surgical excision. Histological appearance of necrotizing granuloma-

http://dx.doi.org/10.5772/54304

tous inflammation with various degrees of caseation is also diagnostic. The most important differential diagnosis is TB lymphadenitis. [82]

Figure 11. A. 36y old man had a 3-month history of lasting submandibular swelling not responding to antibiotic therapy. FNAC examination gave the result of granulomatous necrotizing lymphadenitis. B. Lymphatic node was extirpated under GA. Chest X-ray, PPD test a sputum culture were negative. C. Histopathology examination revealed epithelial granulomas with giant cells. No fast acid staining organisms were observed. Because lymph node culture also failed, presumptive diagnosis of NTM infection was made. Patient was lost to further follow-up.

6.2. Treatment

Treatment of uncomplicated NTM lymphadenitis is surgical excision [86-7]. Total excision should be performed as early as possible to prevent spread and subsequently more difficult surgery with possible cosmetic consequences. Adjacent normal-appearing enlarged lymph nodes should also be excised. Curettage might be considered as an alternative in cases of adherence of the facial nerve branches. Incision and drainage lead to sinus tract formation with chronic discharge and should be avoided [87]. In a clinical trial including 100 children with culture or polymerase chain reaction confirmed diagnoses, surgery was more effective than chemotherapy with cure rates 96% and 66%, respectively. However, for patients with discharging sinus or proximity of facial nerve branches, chemotherapy can be the preferred therapeutic modality. Chemotherapy must also be considered for patients in whom surgical treatment is unsuccessful. Chemotherapy usually includes clarithromycin and rifabutin. [86]

7. Salivary gland infections

Salivary glands (SGs) are exocrine, merocrine glands. Major SGs are the parotid, submandibular and sublingual. The minor SGs are distributed through the mucosa of the oral cavity. While both major and minor SGs can become infected, infection usually affects major SGs, especially the parotid gland. Infection of SGs can be bacterial, viral, fungal, or as was recently documented, protozoal.

7.1. Bacterial infections

Bacterial infections of the SGs typically result from retrograde propagation of bacteria through their ducts from oral cavity. This process is promoted by stasis of salivary flow. [88]

Predisposing factors for the ductally ascending infection are dehydration, xerogenic drugs and salivary gland diseases associated with reduced saliva secretion or ductal obstructions. Other possible modes of infection are through transitory bacteremia, especially in the neonatal period, or direct spread from adjacent infectious processes. [89,90]

7.1.1. Acute bacterial sialadenitis

The parotid gland is the most common site of acute suppurative salivary infection. Saliva of the parotid gland is primarily serous and therefore provides less protection against ascending bacteria. On the other hand, mucoid saliva produced by the submandibular and sublingual glands contains many antimicrobial protective elements, including lysozymes and IgA antibodies. Mucins also contain sialic acid, which agglutinates bacteria, preventing its adherence to host tissues. Specific glycoproteins found in mucins bind epithelial cells, competitively inhibiting bacterial attachment to these cells. [89] Submandibular sialadenitis is less frequent and accounts for approximately 10% of all cases of sialadenitis of the major SGs. Majority of submandibular gland infections is related to sialolithiasis of Wharton's duct. Submandibular secretions are more mucinous, and therefore more viscid; they also are more alkaline, containing a higher percentage of calcium phosphates. These circumstances contribute to the fact that 85-90% of salivary calculi are located in the submandibular duct. [89] (Figure 12)

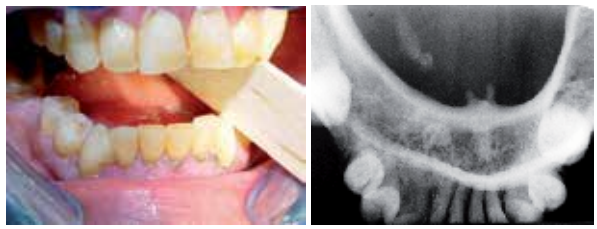

Figure 12. A. 40y old female patient presented with painful infiltrate of right sublingual area and trismus. Mucosa of oral floor was erythematous and right Wharton's duct orifice discharged pus.B. Occlusal intraoral X-ray film disclosed presence of 2 sialoliths. These were removed after incision of distal portion of the duct, which was irrigated by saline. Infection resolved in 1 week.

The most common pathogens associated with acute bacterial infections of SGs are *S. aureus* and anaerobic bacteria. The predominant anaerobes include *Prevotella* and *Porphyromonas*, *Fusobacterium* spp. and *Peptostreptococcus* spp. Less frequent are streptococci including *S. pneumoniae*, and gram-negative organisms, including *Escherichia coli*, *Klebsiella pneumoniae*, and *Pseudomonas aeruginosa*. [91]

7.1.1.1. Clinical presentation and diagnosis

Local symptoms include a rapid onset of pain, swelling, and induration of the involved gland. Overlying skin can become purplish as infection progresses. Stensen's or Wharton's ducts may appear erythematous and gentle massage of the gland will frequently result in a

suppurative discharge from the duct orifice. In submandibular infections, a calculus may be palpable along the course of Wharton's duct. Because of the resistance of the fibrous capsule, particularly that surrounding the parotid gland, palpation of the abscessed gland may fail to reveal fluctuance. Systemic manifestations like fever, chills, malaise are frequent. [92] Laboratory examination revels leukocytosis with neutrophilia. Purulent secretions from duct orifice should be sent for microbiology examination. CT or US imaging of the gland may reveal abscess formation; however they are not indicated at the beginning of the disease. In the case of submandibular gland infection, orthopantomogram may disclose a salivary stone. Sialography is contraindicated in the acute phases of sialadenitis because it is extremely painful and can exacerbate the existing inflammation. [89]

7.1.1.2. Treatment

Elimination of the etiological factor such as ductal obstruction by sialolith is essential. Other therapeutic measures include proper hydration, stimulation of saliva flow, analgesics and local heat application to ease the discomfort. Capable patients should be instructed on regular external or bimanual massage, starting from the distal bed of the gland and working in the direction of duct drainage. [92] Initially broad-spectrum antimicrobial therapy is indicated to cover all possible aerobic and anaerobic pathogens. Clindamycin, cefoxitin, imipenem, the combination of metronidazole and macrolide or penicillin plus a β-lactamase inhibitor, provide adequate coverage. Later the therapy should be guided by results of culture and antibiotic sensitivity. Presence of methicillin-resistant staphylococci may mandate the use of vancomycin or linezolid. [90] In most cases of acute submandibular sialadenitis removal of duct obstruction and conservative therapy are sufficient to resolve the disease. In cases of acute bacterial parotitis, especially in medically compromised patients like diabetics, infection process often reaches the stage of abscess, despite antibiotic treatment. US, CT or MRI imaging help to recognize this condition. In such instances evacuation of pus becomes necessary. Small, superficially located abscess can be aspirated. The classical approach to drainage of parotid abscess involves anteriorly based facial flap, and multiple, superficial, radial incisions in the parotid fascia parallel to the facial nerve branches [89]. Based on our experience, we consider such radical surgery unnecessary and impractical, and instead utilize incision placed in natural skin crease, as close as possible to the abscess, and dissect bluntly using fine mosquito forceps (Figure 13).

7.1.2. Chronic bacterial sialadenitis

Like in acute sialadenitis, the causative event in chronic sialadenitis is believed to be a lowered secretion rate with subsequent salivary stasis. This can be due to neglected underlying obstruction (duct stenosis, stone or foreign body). Another major cause of chronic sialadenitis is Sjögren's syndrome. Approximately 2% of patients with Sjögren's syndrome are affected each year [93]. Repeated acute suppurative infections lead over time to permanent damage characterized by sialectasis, ductal ectasia, and progressive acinar destruction combined with a lymphocytic infiltrate. The structure of parenchyma and function of the gland are gradually destroyed. This leads to decrease in salivary secretion and further promotes

recurrences in a vicious circle. Some authors feel that chronic sialadenitis is in most instances either autoimmune or of unknown etiology with superimposed bacterial infections and should not be designated as a chronic bacterial infection [94].

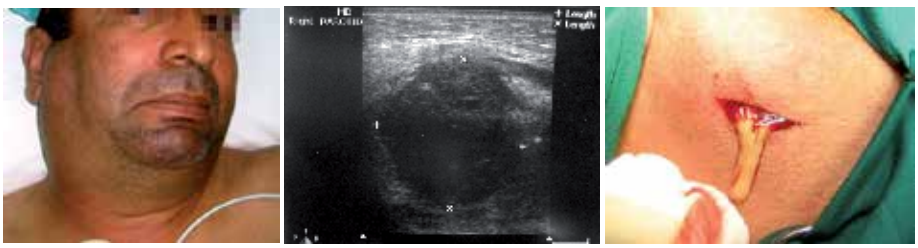

Figure 13. A. 55y old diabetic man presented with a 2-week swelling of the right parotid gland treated via antibiotics. B. US examination revealed an abscess cavity in lower pole of the parotid gland. C. Abscess was drained from small skin incision parallel to natural skin crease.

7.1.2.1. Clinical presentation and diagnosis

Chronic sialadenitis is characterized by recurrent moderate swelling of the affected gland alternating with asymptomatic remissions. During flare-up the duct orifice appears inflamed with accompanying purulent discharge. Symptomatology tends to become progressively more severe with increasing number of flare-ups. Eventually in some patients, the clinical manifestations of a flare-up can mimic that seen in acute sialadenitis including abscess formation [95]. With recurrent infection the gland atrophies and is replaced by fibrotic tissue, which makes it permanently palpable. Many patients with chronic parotitis seek medical attention because of a non-tender asymptomatic parotid lump or diffuse swelling. Chronic sclerosing sialadenitis of submandibular gland, characterized by progressive periductal fibrosis, dilated ducts with a dense lymphocyte infiltration with lymphoid follicle formation and acinar atrophy, is known as Küttner's tumor. It creates a diagnostic dilemma, because clinically it resembles a submandibular gland tumor and it is the known fact that 80% of tumors presenting in this organ are malignant [96].Clinical diagnosis of chronic sialadenitis needs validation by imaging. Common diagnostic methods are US and sialography. Sialography can evaluate the possible cause and the location of obstruction and enables assessment of progression; however, it is an invasive method and is currently being supplanted by MRI sialography, which provides 3-dimensional images of the salivary gland without contrast medium or exposure to ionizing radiation [97]. A new effective method for diagnosis and also treatment of the obstructive disorders of SGs is sialoendoscopy [98,99].FNAC or incisional biopsy is advised for lesions that are still not diagnosed after complete clinical and radiographic evaluation.

7.1.2.2. Treatment

An appropriate antibiotic should be used during an acute flare-up. Specific treatment is instituted for any structural abnormality, stricture or calculus. Oral and dental hygiene with

http://dx.doi.org/10.5772/54304

mouthwashes, massage and compresses are useful. In the majority of cases of chronic parotitis, the disease will subside without an operation. More aggressive treatment is justified only for those patients with persistent problems. Total parotidectomy is advised only with frequent attacks and severe, progressive disability [100]. In a case of chronic submandibular sialadenitis, when the function is destroyed, the treatment is by surgical excision. Interventional sialoendoscopy is an innovative approach to management of chronic sialadenitis. It mainly includes sialolith or ductal polyp removal. When present, sialodochitis can be controlled by continuous lavage and drug perfusion in the duct. It has also been reported that polyethylene stents can be used to prevent obstruction of the duct lumen by postoperative edema, to allow particles of calculus to be washed out by the saliva and to reduce the possibility of stenosis. [99]

7.1.3. Juvenile recurrent parotitis

This separately recognized suppurative disease of the parotid glands is characterized by recurrent unilateral or bilateral parotid swellings that may persist into adulthood. Age of onset is most commonly between 3 and 6 years, while complete remission is usual at the time of puberty. An early age at the first episode is associated with an increased risk of recurrences. The episodes of parotid swelling may occur several times per year and overall number of recurrences can reach several dozen. [101,102] The etiology and pathogenesis of this condition are largely unknown. Numerous factors were suggested as causative: congenital malformation of the ductal system, hereditary and genetic factors, allergy, autoimmune disease, IgA or IgG3 deficiency [102,103].

7.1.3.1. Clinical presentation and diagnosis

Findings include recurrent episodes of glandular swelling which typically last for several days up to 2 weeks, and which may occur more than 10 times per year, generalized malaise and pain. On clinical examination the affected gland is swollen and tender, mostly without overlying skin changes. Saliva expressed from the duct is thick and contains floccules of inspissated mucus or pus. US is the appropriate initial imaging investigation, and is usually supplemented by sialography after acute symptoms have subsided. (Figure 14)

Figure 14. A. 15y old boy with history of recurrent right parotid swelling since the age of 6. B. Orrifice of Stensen's duct is slightly erythematous and expressed saliva contains whitish floccues. C. US examination showed numerous hypoechogenic loci consistent with sialectasis.

7.1.3.2. Treatment

Acute episodes are managed conservatively with hydration, stimulation of salivation, fomentations and analgesic-antipyretic medication. Patients with fever and frank purulent exudation may require a course of antibiotics. The sialography with iodinated oil may itself cause an improvement of the condition [104].

7.2. Viral infections

Viral infection of the SGs most commonly occurs through hematogenous dissemination, although infection by retrograde ductal migration does occur. Viral infestation of salivary parenchyma can be accompanied with local and/or systemic manifestations. There is a wide range of viral infections that can involve SGs, which include *Coxsackie virus* A and B3, P*arainfluenza virus B*, *Influenza virus*, *ECHO virus* type 9, *Epstein-Barr virus*, HIV, enteroviruses, *Cytomegalovirus* and *Lymphocytic choriomeningitis virus*. [89,92]

7.2.1. Mumps

Mumps is the most common childhood viral disease, causing nonsuppurative acute sialadenitis. Adults are rarely infected due to life-long immunity incurred by childhood exposure or MMR vaccination. Mumps virus, the causative agent of mumps infection, is an enveloped RNA virus that belongs to the genus *Rubulavirus* in the family *Paramyxoviridae*. The virus is endemic in the community and spreads efficiently by air-borne droplets from salivary, nasal and urinary excretions. The incubation period is between 15 to 24 days and averages 18-19 days. Infective virus is shed through the saliva for up to a week following gland enlargement. [89]

7.2.1.1. Clinical presentation and diagnosis

Mumps is characterized by pain and swelling of one or both parotid glands, accompanied by low-grade fever, arthralgia, malaise, and headache. Bilateral parotid gland swelling occurs in most cases, but submandibular gland swelling can also occur in rare cases. Progression of parotid gland swelling can be rapid and sufficient to cause displacement of the pinna. Pain is usually exacerbated by the physiologic stimulus of eating, which causes contractile ejection of saliva from the inflamed gland. Findings at the orifice of the parotid duct are usually absent but sometimes the orifice can become edematous and erythematous. Ductal epithelial desquamation may lead to secondary ductal obstruction and dilatation. While the parotids are the most commonly affected organs, parotitis is not a primary or necessary step for mumps infection. More fulminant infections occasionally progress to include meningoencephalitis, orchitis, pancreatitis, and nephritis. Routinely obtained laboratory tests are usually unremarkable except for occasional leukopenia. Elevations in serum salivary type iso-amylase parallels the pattern and duration of glandular swelling. Laboratory investigation is rarely required given the characteristic features present in all but exceptional cases. A laboratory diagnosis is based on isolation of the mumps virus, detection of viral

nucleic acid, or serological confirmation. Histological examination reveals substantial cytoplasmic vacuolization of acinar cells. [89,92,105]

7.2.1.2. Treatment

As with any viral illness, there is no specific antiviral therapy for mumps and treatment is mostly symptomatic and supportive: supplemental hydration and rest, with dietary modifications to minimize glandular secretory activity. Generally, the symptoms of viremia, including fever, arthralgia, malaise, and headache, begin to abate within 3 to 7 days. The resolution of gland swelling usually requires several weeks, frequently proceeding asymmetrically. [92]

7.3. Fungal infections

Fungal infection is an unusual cause of SG pathology, however there are several reports in the literature about infection of salivary gland with *Candida albicans* [106], *Candida glabrata* [107] *Apophysomyces elegans* [108] and *Rhizopus s*pp. [109]. Fungal salivary infection usually occurs in debilitated hosts and this is maybe due to the toxicity of saliva to fungi under normal conditions. The definite diagnosis is made by culturing the purulent discharge from duct or by culture of the pus obtained at surgical drainage of the abscess, but most readily by tissue biopsy. The treatment will involve an appropriate antifungal medication depending on the laboratory analysis, incision and drainage of any formed abscess and total or partial excision of the gland because some infections are invasive and life threatening.

7.4. Parasite infections

Apart from involvement of the parotid gland by toxoplasmosis [110], we were able to find only one case of parasitic SG infestation in the English literature. A nematode larva, morphologically consistent with *Strongyloides stercoralis* was found in the cytological examination of a 41-year-old man who underwent incision and drainage of a right-sided parotid swelling because of poor response to the aspiration and drainage with intravenous antibiotic therapy. The abscesses regressed significantly after administration of Ivermectin. [111]

7.5. Granulomatous infections

Granulomatous SG infections not infrequently represent a manifestation of a chronic granulomatous disease involving the lymphatic network in and around the parotid gland. Also direct infiltration of the adjacent glandular parenchyma occurs in fulminant cases. Manifestations frequently feature asymptomatic gradual enlargement of a nodule within the gland substance, suggesting a neoplasm. Included among these diseases are mycobacterial diseases (tuberculous and atypical forms), actinomycosis, cat scratch disease, and tularemia. [92] For details see respective sections of this chapter.

8. Paranasal sinuses infections

Sinusitis is one of the most common condtions in primary care. Because infection causes inflammation of both the sinuses and the nasal cavity, the term "rhinosinusitis" instead of the more common sinusitis has been recently coined [112,113]. The precipitating factor in acute sinusitis seems to be blockage of the sinus ostium, typically the maxillary sinus ostium situated under the middle turbinate, with mucus retention and subsequent infection. Viral infection of upper respiratory tract triggers most cases. Only 0.2-2% of cases become complicated by bacterial infection [113]. Worsening symptoms after 5 days or persistent symptoms beyond 10 days (but less than 12 weeks) indicate non-viral rhinosinusitis; whereas viral disease lasts less than 10 days [112]. A small proportion of cases of bacterial sinusitis can arise as a result of periapical infection or untreated post-extraction oro-antral communication. Odontogenic maxillary sinusitis comprises 10–12% of bacterial sinusitis; however, recent studies suggest that this figure is much more frequent and closer to 30%. [114]

8.1. Clinical presentation and diagnosis

Acute rhinosinusitis, according to The European Academy of Allergology and Clinical Immunology, is characterized by two or more of the following symptoms: nasal congestion with blockage, discharge (anterior or postnasal drip), facial pain and/or pressure and reduction or loss of smell, lasting less than 12 weeks. Additional symptoms, not invariably present, are toothache of upper teeth, pain on stooping, and fever or malaise. [115]

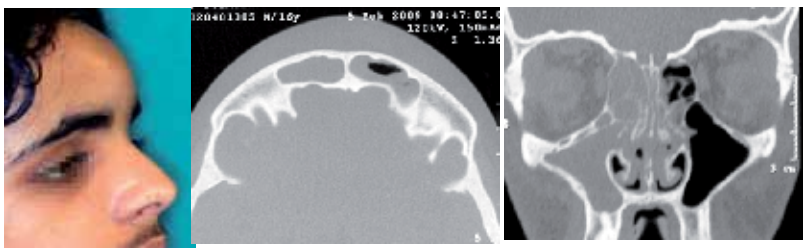

Figure 15. A. 16y old male hospitalized in ENT department was referred to rule out odontogenic source of his right sided pansinusitis. B. Notice distended edematous soft tissues of forehead. C. Complete opacification of all right sided paranasal sinuses. Patient was treated by endoscopic sinus surgery and intravenous antibiotics.

Chronic rhinosinusitis is characterized by nasal congestion or blockage lasting more than 12 weeks and accompanied by at least one of the following symptoms: facial pain or pressure, discolored nasal discharge or postnasal drip and reduction or loss of smell. Most instances of sinusitis are diagnosed clinically. In the workup of suspected acute rhinosinusitis, plain radiography is neither useful nor warranted [115]. X-ray examination of the sinuses, CT, ultrasonography, sinus puncture, and culture of aspirate can be helpful in complicated and chronic cases [112]. Dental symptoms, such as pain and dental hypersensitivity, do not reliably predict an odontogenic cause. The most usual characteristic of an odontogenic sinusitis is the presence of unilateral symptoms [114].The complications of sinusitis are due largely to

the proximity of the paranasal sinuses to the anterior cranial fossa and orbit, as well as the venous drainage of the mid-facial structures into the intracranial venous sinuses. Up to 75% of orbital infections are attributable to sino-nasal disease, namely ethmoiditis. Frontal sinusitis may lead to osteomyelitis of the frontal bone (Pott's puffy tumor) [116]. Other life- threatening complications include extradural and subdural empyema, meningitis, intracranial abscess, and cavernous sinus thrombosis. (Figure 15)

8.2. Treatment

Acute rhinosinusitis is managed symptomatically with analgesics and topical steroid spray. Symptom relief can also be achieved with the use of topical saline douches and sprays. Antibiotics are recommended if symptoms are severe, persistent (>5 days), or progressive. [112,118] The gold standard for establishing bacterial etiology of acute rhinosinusitis is a maxillary sinus tap. However, it is not a routine procedure and is usually reserved for research purposes or for patients not responding to initial medical therapy. A suitable alternative may be nasopharyngeal culture. [118] Even in the absence of detectable sinus bacterial infection, the presence of nasopharyngeal bacterial colonization can result in the development of secondary bacterial sinusitis. Inflammation of the mucosal lining of the paranasal sinus causes a functional obstruction of the osteomeatal complex. It is thought that oxygen within the sinus is depleted as molecular oxygen is absorbed, resulting in negative pressure promoting the aspiration of bacteria from the nasopharynx. Another mechanism of paranasal sinus inoculation with bacteria is nose blowing. [118] Once a bacterial cause is established based on clinical presentation, empiric antimicrobial therapy should be initiated, depending on the resistance patterns of the usual pathogens: *S. pneumoniae*, *H. influenzae* and *M. catarrhalis*. Antibiotics that cover β-lactamase producing bacteria, like amoxicillin–clavulanate, are reasonable choices. Other options include cephalosporins or macrolides. [112] If an antibiotic is effective, clinical improvement should be seen within 2–3 days [118].

Clinical studies have recently confirmed that about 60% of presumed bacterial sinusitis resolves spontaneously without antibiotics. For instance, in a double-blind, randomized, placebo-controlled factorial trial of 240 adults (aged ≥16 years) with acute non-recurrent bacterial sinusitis, neither an antibiotic nor a topical steroid alone or in combination were effective in altering the symptom severity, the duration, or the natural course of the condition [119]. Despite this evidence, antibiotics are still overused, which ads to treatment costs, puts patients at risk of adverse events and ads to growing antimicrobial resistance [113].Treatment of *chronic rhinosinusitis* should begin with topical nasal steroids along with aggressive treatment of any underlying cause or comorbid allergy. Oral steroids should be reserved for refractory cases. Caution should be taken in at-risk groups, including patients with diabetes or active peptic ulceration. Antibiotics may be indicated in patients who have failed to respond to initial intranasal steroid therapy or in those who have severe symptoms with evidence of persistent nasal bacterial infection. [112,113] Surgery for rhinosinusitis should be considered only after conservative treatment has failed or complications develop. In acute rhinosinusitis sinus lavage performed endoscopically or via external trephination of canine fossa can drain pus and decompress the affected sinus. Traditional open sinus proce-

dures for chronic rhinosinusitis, like Caldwell-Luc operation, have been supplanted by endoscopic techniques. With a better understanding of normal mucociliary clearance pathways and anatomy of the osteomeatal complex, functional endoscopic sinus surgery is now the mainstay of surgical treatment. [112] Patients with recurrent acute sinusitis or chronic sinusitis should be evaluated for underlying allergy. As many as 60% of patients with chronic sinusitis have allergic sensitivities to perennial allergens like house dust mites, cockroaches, pet dander and fungi. These allergies should be identified and treated before the patients are considered for sinus surgery [113].Although symptoms and exam findings in odontogenic and nonodontogenic sinusitis are similar, odontogenic sinusitis differs in the pathogenesis, spectrum of microbiology findings and treatment strategies and its therapy is therefore not discussed in this chapter.

9. Orbital infections

Infections of the orbit make up less than 1% of all orofacial acute bacterial inflammations. Their rarity may lead to late diagnosis and consequential serious complications: impairment of visual acuity, blindness, or in extreme cases even death due to intracranial spread [120].The orbit is surrounded by frontal bone, major and minor wing of sphenoid bone, orbital facet of vertical plate of palatinal bone, lamina papyracea of ethmoid bone, lacrimal bone, maxilla and zygomatic bone. Several of these bones contain pneumatized paranasal sinuses. The ethmoidal sinus and maxillary sinus are separated from the orbital cavity by very thin bone shell. There are also numerous bony foramina and fissures containing neurovascular bundles, along which the infection processes can spread into orbit and intracranially: optical foramen, superior and inferior orbital fissure, anterior and posterior ethmoidal foramen, infraorbital canal and foramen, nasolacrimal canal, supraorbital and supratrochlear foramen. Another route of orbital involvement by adjacent infectious process is thromboflebitis of orbital veins, which are connected to facial venous system by angular, infraorbital, supraorbital, supratrochlear and pterygoid plexus veins. The ophthalmic veins communicate also with the veins of the sinuses, especially the ethmoid sinus. The ophthalmic veins drain into the cavernous sinus, and therefore infections can spread intracranially. Veins in this region are valveless and can have retrograde flow. This makes venous orbital system prone to congestion. [121] Orbital infections are usually classified as pre-septal or post-septal according to their relationship to orbital septum, connective tissue membrane, which arises from the orbital margin and radiates into upper and lower tarsus of the eyelids. [121]. Conditions regarded as preseptal orbitocellulitis are quite frequent. They accompany many orofacial and upper respiratory infection processes, especially odontogenic infections originating in the maxilla. Children are regularly affected by this scary-looking condition; however, it recedes readily after the underlying cause has been eliminated. In these cases periorbital soft tissues and eyelids are affected by edema, but ocular findings like globe position, motility and vision remain normal. Only post-septal processes can therefore be considered true orbital infections. (Figure 16)

http://dx.doi.org/10.5772/54304

Figure 16. old girl hospitalized in the ophthalmology ward was referred to rule out odontogenic source of preseptal orbitocellulitis. Note crusted nasal secretion suggesting acute rhinosinusitis.

In postseptal orbital cellulitis there is diffuse edema of the orbital contents and actual infiltration of the adipose tissue with inflammatory cells and bacteria, but no discrete formation of abscess. In subperiosteal orbital abscess, there is a collection of pus between the periosteum and the bony wall of the orbit, while in intraorbital abscess pus collection is present within the orbital tissues. [122,123] (Figure 17)

Figure 17. Clinical presentation of acute postseptal orbitocellulitis with chemosis, proptosis and ophthalmoplegia. Courtesy of Dr. Sabreyah Al-Saleh, Ophthalmology Department, Al-Adan Hospital.

The close relationship between the orbit and paranasal sinuses is responsible for the majority of orbital infections, especially in children. Paranasal sinusitis, mostly ethmoiditis followed by maxillary sinusitis, precedes 60 – 84% of orbital infections. [124,125] Other sources of orbital infections are trauma, retained foreign bodies, periorbital suppurative skin diseases, hordeolum or chalazion, dacryocystitis and conjunctivitis. Odontogenic infection of the orbit is rare. The pathway can be via the maxillary sinus, the canine fossa with a thrombophlebitis of the angular vein, or the pterygopalatine fossa and infratemporal fossa and further through the inferior orbital fissure. [120] The causative microorganisms in acute orbital infections are usually those associated also with paranasal sinusitis. Before introduction of vaccination, *H. influenzae* was the most common pathogen responsible for orbital cellulitis.

Currently, the most common bacterial isolates include the *Staphylococcus* species, *Pseudomonas* species, *Streptococcus* species, *Moraxella catarrhalis*, and *Eikinella corrodens* as well as anaerobic organisms like *Peptostreptococcus*, *Fusobacterium*, and microaerophilic *Streptococcus*. [121] In young children aerobes prevail, while in older patients anaerobes can also be found. Polymicrobial infections are more frequent in adult patients. [122]

9.1. Clinical presentation and diagnosis

Symptoms depend on the stage of the infectious process, which begins with postseptal orbital cellulitis accompanied by swelling and erythema of eyelids, conjunctival chemosis, limited ocular motility, visual disturbances and proptosis due to developing intraconal edema. Development of subperiosteal abscess can lead to displacement of the bulbus with resulting diplopia. Intraconal progress of infection is marked by increasing exophthalmia, abnormal pupillary reflexes, ophthalmoplegia, impaired color vision and decreasing visual acuity. Eyeball is painful to touch and patient suffers from severe headache. The disease is accompanied by septic fever and laboratory signs of acute bacterial infection. Untreated or inadequately treated disease finally progresses into thrombophlebitis of cavernous sinus with complete paralysis of related cranial nerves, loss of vision, altered mental status and generalized sepsis. Mortality rate of cavernous sinus thrombophlebitis remains high. There is usually very little to be gained by conventional radiology examination. Plain radiographs are reserved for very young children in whom the risk of sedation for the CT scan and radiation burden outweigh the possible diagnostic yield [121]. CT scan or MRI imaging should be performed without delay to serve as an indicator and guide for surgical intervention. I it will help to elucidate the status of the paranasal sinuses, where majority of infections originate. Although CT still remains the modality of choice for the diagnostic workup of orbital infection, MRI should be considered particularly in the pediatric population [126]. Recently, there was some progress in employment of US as a readily available, inexpensive imaging method for diagnosing and monitoring orbital infections, especially in children, where radiation dose is a major concern [127].

9.2. Treatment

Patients with cellulitis, without evidence of a subperiosteal or intraorbital abscess, can usually be treated with parenteral antibiotics alone. The antibiotic should be broad spectrum and to cover aerobes as well as anaerobes. Second- or third-generation cephalosporins, ampicillin-sulbactam, ticarcillin-clavulanate, clindamycin, aminoglycosides, fluoroquinolones or carbapenems are among those recommended. [121,128] Surgical incision and drainage of the subperiosteal or intraorbital abscess is the mainstay of therapy and should be considered an emergency procedure. Primary source of infection should be addressed at the same time. The optimal way of draining orbital abscess is endoscopic access via paranasal sinuses, namely in cases originating in sinusitis [128]. Otherwise, surgical access to the orbit is through periorbital skin incisions like Lynch, infraorbital or lateral eyebrow. Cosmetic approaches used in orbital traumatology are not indicated here, because they do not allow placement of proper drains and/or they would bring purulent exudate into the conjunctival

http://dx.doi.org/10.5772/54304

sac and contaminate the cornea. Surgical intervention should be complemented by aggressive intravenous antibiotic therapy without waiting for results of microbiology examination and sensitivity testing. Benefits of corticosteroid therapy aimed at reducing orbital edema is questionable. It should be administered only if mycotic etiology has been ruled out.

10. Interstitial fungal infections

There are about 100,000 different species of fungi worldwide, but only a few are pathogenic for humans, and most of them show distinct geographic distribution. With the exception of candidiasis, other fungal infections are extremely rare and consequently medical and dental practitioners have limited experience and knowledge in their diagnosis and management. Accurate and early diagnosis, which often is not easy, should lead to prompt and aggressive therapy to prevent spread, dissemination and death. Fungal infections rarely afflict healthy immunocompetent individuals. However, recent years saw a dramatic increase in the numbers of immunocompromised patients, above all HIV infected persons, diabetics, patients with hematologic malignancies, transplant recipients and other patients receiving immunosuppressive drugs. Clinicians should be aware of these rare mycoses and include them in the differential diagnosis when dealing with unusual or unexplained symptoms. The laboratory methods available to diagnose fungal infections include biopsy and culture of tissue, body fluids, secretions, tests for antigens and serum antibodies. Biopsy investigation is the key to correct diagnosis and should include special stains such as periodic acid-Schiff and Grocott-Gomori methenamine silver nitrate. For yeasts, culture is necessary to identify the etiologic agents. Filamentous fungi, in particular zygomycetes and dimorphic fungi can be diagnosed by histological examination and pertinent stains with or without isolation of the fungus from the same site. [129]

10.1. Candidiasis

Candida, the most common cause of opportunistic infection worldwide, is thin-walled, small yeast (4-6 μ) that reproduce by budding. The genus *Candida* includes approximately 154 species, but only 6 are frequently isolated in human infection. *Candida albicans* is the most abundant and significant species. Other causative agents include *C. tropicalis*, *C. glabrata*, *C. parapsilosis*, *C. krusei*, and *C. lusitaniae*. Invasive *Candida* disease is composed of a variety of entities, including candidemia, disseminated candidiasis, endocarditis, meningitis, and endophthalmitis. [130] In orofacial areas the most frequent form of *Candida* infection is stomatitis. It takes on several well known clinical manifestations, like angular cheilitis, denture stomatitis and rhomboid median glossitis. These superficial mucosal diseases are usually due to local compromising factors and can be found in otherwise healthy individuals. Topical antifungal treatment with correction of underlying problem is usually sufficient for cure. Disorders of cell-mediated immunity are associated with severe or recurrent pseudomembranous candidiasis, whereas neutropenia or impaired neutrophil functions are associated with invasive infections. [131] (Figure 18)

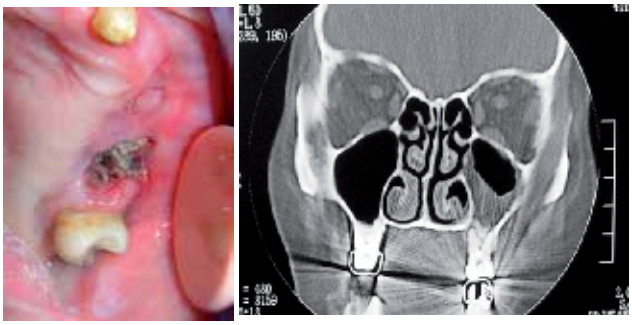

Figure 18. A. 40y old diabetic woman was referred by a dentist for evaluation of non-healing wound after extraction of tooth 26 done 6 months earlier. B. CT examination revealed partial opacification of the maxillary sinus and signs of osteomyelitis. The patient underwent surgical debridement. Histopathology examination revealed massive *Candida* infiltration.

10.2. Cryptococcosis

The *Cryptococcus* genus includes spherical opportunist yeasts that generally lack a mycelium but have a polysaccharide capsule. Two *Cryptococcus* species can cause diseases in humans. *Cryptococcus neoformans* is ubiquitously distributed. It has been isolated in the soil and in the feces of birds, such as pigeons, canaries, and parrots. *Cryptococcus gattii* has the koala bear as a natural reservoir, and it is endemic in Australia, where it is also frequently found on eucalyptus trees. *Cryptococcus neoformans* infection generally affects immunocompromised hosts, whereas *C. gattii* is more often isolated in immunocompetent subjects. [129] Cryptococcosis is one of the most common life-threatening systemic fungal infections in HIV infected patients with mortality rate of 30-40%. The onset of the infection follows inhalation of the spores, with primary localization in lungs from which they spread through the bloodstream to the central nervous system, causing meningitis. There have been only sporadic reports of orofacial manifestations. The affected locations included oral mucosa, parotid gland, paranasal sinuses and temporal area with associated osteomyelitis. [132-6]

Combination of amphotericin-B and flucytosine is the treatment of choice for the first 2 weeks, followed by fluconazole maintenance therapy.

10.3. Aspergillosis

Aspergillosis is an infection caused by a fungus of the *Aspergillus* family. *Aspergillus* species are commonly found in the soil and decaying vegetation. Infections due to *Aspergillus* species are caused in most cases by *Aspergillus fumigatus*, far ahead of *Aspergillus flavus*, *Aspergillus niger*, *Aspergillus terreus* and other *Aspergillus* species. [137] The manifestation and severity of the aspergillosis depends upon the immune status of the patient. Although *Aspergillus* conidia inhalation is very common, the disease is rare in healthy subjects. Patients at highest risk are those with hematological malignancies and severe neutropenia, AIDS, chronic obstructive pulmonary disease, solid organ transplant recipients, and patients in the

intensive care unit receiving steroids. Invasive *Aspergillus* infections most commonly affect the lung and paranasal sinuses. Other forms of the disease are central nervous aspergillosis, osteomyelitis, endophthalmitis, endocarditis, and disseminated form of aspergillosis. [129,137] The maxillary sinus is the most common orofacial site of invasive aspergillosis. The disease is characterized by spread of the fungus from the sinus into adjacent structures. If not aggressively treated, it can invade the brain, causing a high mortality rate. Commonly reported symptoms of invasive sinus aspergillosis are nasal congestion, nasal discharge, abnormal findings in the nasal cavity, buccal swelling with pain, and hypoesthesia. Primary oral invasive aspergillosis is rare. The most frequently affected site is the gingiva, followed by the hard palate. The necrotic mucosal ulceration can progress to affect underlying bone. [138] A case of mandibular involvement has also been reported after tooth extraction in a diabetic patient. [129]Successful treatment of invasive aspergillosis requires prompt diagnosis and rapid institution of aggressive therapy. Any delay or nonaggressive therapy can result in the spread of infection with lethal consequences. Treatment of choice is surgical debridement with antifungal therapy using amphotericin B, itraconazole, voriconazole, and echinocandins. [137,138] The most frequent form of aspergillosis encountered in maxillofacial area of immunocompetent patients is *Aspergillus* mycetoma (AM) of the maxillary sinus. Also known as aspergilloma or fungus ball, it is a noninvasive extramucosal mycotic infection. Predisposing factors include poorly ventilated sinus, a pre-existing chronic sinusitis, or foreign bodies in the sinus. Overfilling of endodontic sealers into the sinus may be a cause. Zinc oxide contained in sealers paralyzes the epithelial cilia and causes edema and hyperemia of the soft tissues that may promote *Aspergillus* growth. Symptomatic patients usually present with signs of chronic sinusitis with nasal secretions, pain, and sometimes facial edema. The disease can be also asymptomatic and is revealed during routine radiographic examination. The treatment of AM is surgical. Traditional Caldwell-Luc procedure, which has been used until recently, has detrimental consequences for sinus physiology. It was supplanted by endoscopic sinus surgery with middle meatal antrostomy. Combined approach with intraoral surgical access remains reserved for selected cases in which endoscopic surgery does not permit complete removal of fungus material and foreign bodies. General or local antifungal drugs are not indicated. [139]

10.4. Zygomycosis

Zygomycosis is fungal infection also known under designations phycomycosis or mucormycosis. The term phycomycosis is obsolete and refers to some of organisms currently classified as *Zygomycota*. The term mucormycosis refers to fungi in the order *Mucorales*. While the term zygomycosis includes also *Entomophthorales*, the order of *Zygomycetes*, as possible etiological agents, the term mucormycosis excludes this group and concerns only organisms belonging to the order of *Mucorales*. The order of *Entomophthorales* is of limited concern because it does not possess the same degree of invasiveness as *Mucorales*. Two genera of *Entomophthorales* are known to be implicated in human disease: *Conidiobolus* and *Basidiobolus*, responsible for subcutaneous infections and, less frequently, for disseminated forms. [140]

The phylum *Zygomycota* comprises about 600 species, principally occurring in soil enriched with decaying organic matter. The usual human pathogens belong to genera *Absidia*, *Mucor*, *Rhizomucor* and *Rhizopus*. The predominant human pathogen is *Rhizopus (oryzae) arrhizus*, accounting for 60% of all forms of zygomycosis and 90% of rhino-orbito-cerebral zygomycosis cases. [141]The mechanism of inoculation is most often by inhalation of spores and therefore respiratory tract or lungs are affected. Up to one half of all zygomycosis cases originate in paranasal sinuses. Another important infection route is percutaneous inoculation. This includes traumatic and surgical wounds, medicine or illicit drug injections, tattoo, insect bites or stings. Deglutition of contaminated food, drinks, herbal or homeopathic remedies can lead to infections of digestive tract. Other organs can be affected either by direct or hematogenic spread due to angioinvasive nature of the fungus.The infection typically occurs in immuno-compromised patients. The main target group consists of poorly controlled diabetes mellitus patients. Diabetic ketoacidosis leads to dysfunction of monocytes/macrophages and impairment of action of neutrophiles. Another target group is patients with solid tumors, leukemias and lymphomas with chemotherapy-induced neutropenia being the principal risk factor. Other risk factors are systemic steroids, myelosuppresive therapy in bone marrow and solid organ transplant recipients, iron overload and its deferoxamin treatment in patients on dialysis. Wide-spectrum antibiotics can promote zygomycosis by eliminating bacterial competition. [141-3] Cases of zygomycosis have also been reported among healthy individuals with no known risk factor. [144] Many of these cases have been ascribed to *Apophysomyces elegans*, relatively recently discovered *Zygomycete*. [145] The majority of cases in previously healthy patients follow invasive procedures or trauma with extensive damage of soft tissues. Local ischemia and resulting acidosis can provide favorable conditions for proliferation of an infection.

10.4.1. Clinical presentation and diagnosis

Majority of orofacial zygomycosis cases originate in paranasal sinuses, especially in diabetic patients. Initial signs include nasal obstruction, mucopurulent or bloody nasal discharge, nasal crusting, facial pain, headache, facial swelling, and cellulitis. In acutely progressing cases, orbital involvement is a common clinical feature, even on presentation. (Figure 19)

Zygomycosis should be considered in all patients with orbital inflammation associated with multiple cranial nerve palsies and retinal or orbital infarction, regardless of their immunologic status. Initial orbital involvement is an alarming sign, because it can lead to intracranial progression with grave prognosis. CT scan at this initial stage often reveals only minimal mucosal thickening of the sinuses. Blood tests, cerebrospinal fluid examinations, and cultures from paranasal sinuses fluid are of no diagnostic help; only the detection of typical fungal hyphae in the infected tissue is diagnostic. The early collection of biopsy sample is therefore of utmost importance. [146-8] Chronically developing zygomycosis of paranasal sinuses results in extensive necrosis and destruction of mid-facial bony architecture and can manifest itself by hard palate ulceration over necrotic bone and finally palate perforation. (Figure 20)

http://dx.doi.org/10.5772/54304

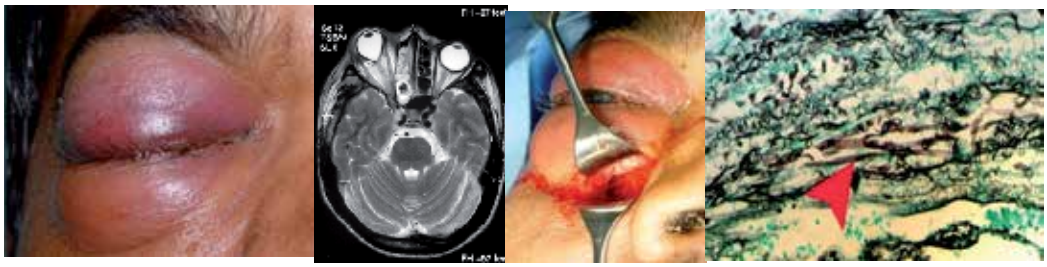

Figure 19. A. Ten day orbital cellulitis in a previously healthy young man, unsuccessfully treated by antibiotics and corticosteroids.B. MRI scan revealed proptosis with stretching of the optical nerve, deformation of the bulbus, thickening of ocular muscles, inflammatory changes of orbital fat, homolateral ethmoid cells and temporal fossa. C. Exploratory orbitotomy encountered bulging avascular periorbita. D. Groccot-Gomori stain of biopsy specimen depicted hyphae of zygomycete, which was classified by subsequent culture as *Apophysomyces elegans*. Despite orbital exenteration and Amphotericin B therapy the patient died 5 days later due to intracranial invasion. [145]

Figure 20. A. Female patient treated by chemotherapy for acute myeloid leukemia was referred for evaluation of extensive palatal necrotic ulcer. B. CT scan revealed nearly complete opacification of maxillary sinus. Patient underwent partial maxillectomy and was diagnosed with zygomycosis. She died later due to complications of chemotherapy.

10.4.2. Treatment

Effective therapy requires prompt surgical intervention, systemic antifungal drug administration and reversal of the underlying immunocompromising condition. The only agent active against most *Zygomycetes* species has been until recently amphotericin B. It is the drug of choice for treatment of zygomycosis and it is recommended that therapy should be started as soon as the diagnosis is confirmed. The use of amphotericin B is limited by frequent side effects, most importantly the dose-limiting nephrotoxicity. Most of the negative side effects can be avoided by using preparations of amphotericin B combined with lipid structures. Also introduction of new azoles such as posaconazole and voriconazole may provide hope for better therapeutic outcomes. [149,150] Zygomycetes invading host tissues have a tendency to grow inside vascular channels, which leads to thrombosis and subsequent ischemic tissue necrosis. Intracavitary/interstitial and cerebrospinal fluid perfusion pathways may ensure availability of antibiotic in tissues affected by intra-arterial invasion by mycelia and thrombosis. [151] The overall mortality rate of zygomycosis is approximately 44% but

for patients with rhinocerebral form it reaches 85% and remains more or less unchanged despite progress in antifungal pharmacotherapy. [152]

10.5. Histoplasmosis

Histoplasmosis is a mycosis caused by *Histoplasma capsulatum*, a saprophytic dimorphic fungus found globally in soil. Dimorphic fungi are microorganisms that can grow either in mycelial form in the external environment or in yeast-like form in the host tissues. The morphologic transformation from mold to yeast confers virulence to these microorganisms, so that they are able to cause disease even in immunocompetent hosts. [129] Endemic locations of histoplasmosis include the Ohio and Mississippi River valley, scattered areas of Central and South America, Africa, Asia, the Far East, and Australia. [153] Human contamination occurs by inhalation of the airborne spores, which are phagocyted by pulmonary macrophages and reside within a membrane-bound vacuole. Immunocompetent persons exposed to a low inoculum develop antigen-specific CD41 T-lymphocyte mediated cellular immune responses with activation of macrophages and the disease is controlled. [154] In immunocompromised host, mainly HIV-positive patients, *H. capsulatum* can spread through the reticuloendothelial system and lead to potentially lethal generalized disease. Upper aerodigestive involvement has been reported in patients with chronic pulmonary and chronic disseminated forms of histoplasmosis and may be the initial or only manifestation of the disease. [155] It may also be the first manifestation of AIDS. Lesions frequently present as painful ulcers covered by pseudomembrane, nodules, or vegetations. Oral lesions associated with *H. capsulatum* may occur in isolation or associated with pharyngeal and laryngeal lesions and are present in 30% to 50% of patients with disseminated histoplasmosis. They may mimic other ulcerated lesions, such as squamous cell carcinoma, tuberculosis, and other deep mycoses. [156-8] Specific complication of pulmonary histoplasmosis is the development of a mediastinal granuloma, characterized by a mediastinal mass (3-10 cm) comprised mostly of caseous mediastinal lymph nodes that have matted together and broken down into a single semiliquid encapsulated lesion. Histoplasmosis infection in the neck is a rare presentation and is probably due to the spread of histoplasmosis from the mediastinum to cervical lymph nodes. Neck masses have histopathology characteristics similar to histoplasmosis mediastinal granulomas. [159] Surgical treatment of histoplasmosis orofacial lesions by itself is not effective and must be complemented by antifungal therapy. Typical management of severe disease first involves treatment with amphotericin B, followed by oral itraconazole. Treatment with itraconazole will need to continue for at least 1 year. In milder cases, oral itraconazole or ketoconazole is sufficient. [156]

11. Deep neck infections

Infections of deep fascial compartments of the head and neck can be challenging in diagnosis and management. Because of the anatomic communication between fascial neck spaces, the infection processes easily spread beyond the original site and can lead to life threatening complications. Most deep neck abscesses are polymicrobial; the average number of isolates

http://dx.doi.org/10.5772/54304

is five (range 1–10). Anaerobic bacteria can be isolated from most abscesses when appropriate culture techniques are employed. Predominant anaerobic organisms isolated in peritonsillar, lateral pharyngeal and retropharyngeal abscesses are *Prevotella*, *Porphyromonas*, *Fusobacterium* and *Peptostreptococcus spp*. Aerobic organisms are group A β-hemolytic streptococci, *S. aureus* and *H. influenzae*. [90,160]

11.1. Peritonsillar abscess

The most common deep neck infection is peritonsillar abscess. Peritonsillar abscesses mostly occur as a complication of repeated episodes of bacterial tonsillitis, but they can occasionally occur as a complication of a viral infection, such as Epstein–Barr virus mononucleosis. The infection penetrates into the potential space between the superior constrictor pharyngis muscle and the tonsillar capsule. [90,161]

11.1.1. Clinical presentation and diagnosis

The peritonsillar abscess is usually preceded by acute pharyngotonsillitis. The initial focus of infection may have been resolved by the time of presentation. [161] Affected tonsil is swollen and inflamed, but the soft palate does not bulge. The uvula is edematous and pushed towards the opposite side of the infection. Patients have difficulty in swallowing or speaking. They may be drooling because of pain on swallowing. Pain gradually increases in severity, radiates to the ear and causes trismus as a result of spasm of the medial pterygoid muscle. The breath has a foul odor. Ipsilateral cervical lymph nodes are enlarged and tender. CT examination, or intra-oral US, is helpful in distinguishing between abscess and cellulitis. [90]

11.1.2. Treatment

The therapy of choice is needle aspiration or incision and drainage of the abscess under local or general anesthesia, supported by administration of parenteral antibiotics. Hospitalization and general anesthesia are required in younger children. It is important to obtain adequate specimens for microbial culture from the abscess as a variety of organisms can be recovered. Specimens are best collected at the time of surgical drainage by needle aspiration. [160] Patients with a peritonsillar abscess and a history of recurrent tonsillitis should be considered for tonsillectomy after the acute episode has subsided. It is also possible to drain abscesses by tonsillectomy during the acute stage of the disease.

11.2. Parapharyngeal abscess

The parapharyngeal space is a crevice extending from the level of hyoid bone to the base of the skull. Its lateral border is made up by the medial pterygoid muscle and part of ascending ramus of the mandible, the deep lobe of parotid gland with its investing fascia and inner surface of sternocleidomastoid muscle with its investing fascia. The medial border is composed of the buccopharyngeal fascia covering the lateral surface of the superior constrictor muscle. The pterygomandibular raphe, formed by the junction of the buccinator and the su-

perior constrictor pharyngis muscles, is the anterior border. In this area parapharyngeal space has intimate relationship to pterygomandibular space. The posterior border is made up by the alar fascia and along it parapharyngeal space communicates with the retropharyngeal space. Superior border is the skull base and inferiorly parapharyngeal space communicates with paravisceral neck space. The styloid process and muscles attached to it, together with surrounding loose connective tissue and stylohyoid ligament, create styloid septum, dividing the parapharyngeal space into prestyloid and retrostyloid compartments. The prestyloid compartment does not contain any important structures except ascendant palatine artery, and is closely adjacent to the tonsillar fossa and the medial pterygoid muscle. The retrostyloid compartment contains internal carotid artery, internal jugular vein, the cranial nerves IX - XII, and the cervical sympathetic trunk, as well as lymphatic nodes. Parapharyngeal space can be infected from various sources including the pharynx, tonsils, parotid gland, submandibular space, retropharyngeal space, masticator space, and local lymph nodes. The most frequent source of parapharyngeal infection is peritonsillar abscess. [162] Complications arising from infections of the parapharyngeal space are caused predominantly by involvement of the retrostyloid compartment. They include Horner's syndrome or cranial nerves IX to XII palsies. Involvement of the vagus nerve or laryngeal edema and obstruction can lead to sudden death. Suppurative jugular thrombophlebitis (Lemierre syndrome) is characterized by an anaerobic septic thrombus occluding the internal jugular vein, often with bacteremia and metastatic foci of infection. [163] Carotid artery erosion and rupture also can occur, with devastating consequences, characteristically preceded by small ''herald bleeds''. [164] In addition, infections of the parapharyngeal space can spread to other spaces of the head and neck.

11.2.1. Clinical presentation and diagnosis

The clinical manifestations of the parapharyngeal space infection depend on whether the prestyloid, retrostyloid or both compartments are involved. The clinical symptoms of infection of the prestyloid compartment are dysphagia, trismus, and pain involving the ipsilateral side of the neck with potential projection to the ipsilateral ear. Flexion of the neck intensifies pain by physical compression of the space. On physical examination, swelling and induration may be noticed at the angle of the mandible and parotid area. When an adequate oro-pharyngeal examination is not hampered by trismus, the lateral pharyngeal wall is often found displaced medially. There may be other physical findings associated with the portal of infection, like tonsillitis or pharyngitis. However, often the infection focus does not cause prominent symptoms. An antecedent pharyngitis or tonsillitis may already have resolved. Isolated infections of the retrostyloid compartment of the parapharyngeal space lack the intense trismus associated with prestyloid compartment infections. Occasionally, the parotid gland, which is adjacent to the retrostyloid compartment, may become swollen. Edema may involve the epiglottis and larynx, leading to dyspnea. An oropharyngeal examination may miss swelling of the pharyngeal wall because the swelling can be hidden behind the palatopharyngeal arch. Some of patients thus have no specific localizing signs and may present with sepsis of occult origin. The diagnosis may become apparent only on imaging or after the development of neurologic or vascular complications. Infections of either compart-

http://dx.doi.org/10.5772/54304

ment are associated with systemic toxicity, fevers, chills, and potentially rigors. [90, 161] (Figure 21).

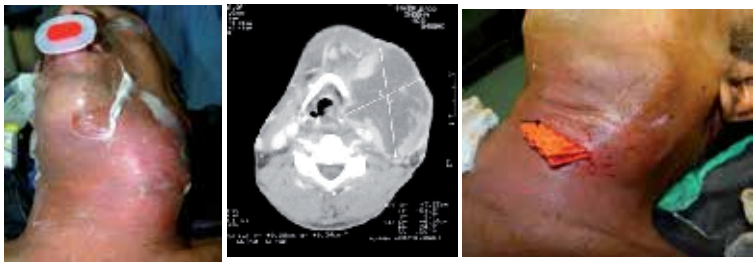

Figure 21. A. Huge neck abscess previously managed by insufficient incision and antibiotic therapy. B. CT scan with contrast shows displacement of airway and compression of great vessels. C. Drainage of abscess by liberal neck incision.

11.2.2. Treatment

Infections of the parapharyngeal space, especially prestyloid compartment, are usually suppurative and have tendency to spread rapidly. They should be managed by early surgical drainage and antibiotic therapy. Some authors suggest that infections localized to the retrostyloid compartment with no clinical evidence of sepsis or airway compromise may respond to intravenous antibiotics without surgery. [165] These two forms can be differentiated by contrast CT scans. [166]

11.3. Retropharyngeal abscess

The retropharyngeal space is surrounded anteriorly by the posterior wall of the pharynx, superiorly by occipital bone and bilaterally by loose connective tissue contiguous with both parapharyngeal spaces. The posterior wall is made up by the alar fascia derived from the deep layer of cervical fascia. Retropharyngeal space extends caudally and communicates with the mediastinum. Retropharyngeal abscesses occur more frequently in children. It is surmised that young children are more prone to retropharyngeal abscesses due to the numerous lymph nodes in the space, while in adolescents and adults retropharyngeal lymphatics are regressed [167]Retropharyngeal abscesses in adult age occur mostly in immunocompromised patients or as a foreign body complication. [168]

11.3.1. Clinical presentation and diagnosis

Clinical manifestations of retropharyngeal space infections and abscesses can vary from mild retropharyngeal pain and malaise to severe respiratory distress and systemic toxicity. Patients often experience an abrupt onset of high fever that is associated with drooling, dysphagia, neck pain on hyperextension, and dyspnea. Respiratory distress can develop because of the anterior displacement of the pharyngeal wall and the supraglottic structures. On transoral examination, bulging of the posterior oropharynx may be seen or palpated, al-

though palpation of the lesion may lead to abscess rupture with aspiration or asphyxiation. The oropharynx can be examined carefully, only in a cooperative patient, who should be placed in the Trendelenburg position. Suction equipment must be ready in the event of abscess rupture. [90,161] The CT scan is the gold standard imaging technique, and plays a critical role in surgical decision-making. Described abnormalities are the presence of fluid-like opacities with rim enhancement, scalloping, gas collections, soft-tissue swelling, and obliterated fat planes.

11.3.2. Treatment

Management includes intravenous administration of antibiotics and drainage of the abscess. Intraoral approach is currently the preferred route. A needle aspiration might be a sufficient treatment when it retrieves pus. If not, the surgical procedure should be completed by incision and drainage. Most abscesses can be drained by peroral incision and suction. When the risk of airway obstruction is great, tracheostomy may be needed. External incision is required rarely, when the abscess is extending laterally to the great vessels or inferiorly towards the mediastinum. [90] However, several studies dealing with pediatric population pointed out the poor correlation between CT scan abnormalities and pus finding during the surgery [169] or reported successful treatment of CT diagnosed abscesses by antibiotics without surgery. [170]

11.4. Danger space and prevertebral space infections

The danger space is located posterior to the alar fascia and is bounded by the prevertebral fascia posteriorly. It is delineated superiorly by the base of the skull; inferiorly it extends through the posterior mediastinum to the diaphragm. Infections of the danger space usually develop by direct spread from adjacent spaces. Infections of danger and prevertebral space can extend throughout the posterior mediastinum and may involve the retroperitoneum. Occasionally, the purulent material from the posterior mediastinum ruptures into the pleural cavity, causing a pyothorax and secondary pleural effusions. Another feared consequence of mediastinal invasion is pericarditis with pericardial effusion and potentially tamponade. [162] The prevertebral space is the crevice between the prevertebral fascia and spinal column. It extends from the base of the skull down to the coccyx and is contiguous with the sheath of psoas muscle. Infections of the prevertebral space usually develop from hematogenic osteomyelitis/discitis of the cervical spine. They can also result from iatrogenic penetrating injuries of the trachea or esophagus. Infections of the prevertebral space behave in a different manner from infections of the retropharyngeal and danger spaces. Complications commonly arise from spinal epidural cord compression resulting in paralysis. They can also lead to psoas muscle abscess, because of the open communication of the prevertebral space down to the psoas muscle. Infections of the vertebrae or disc may cause local destruction with mechanical instability of the spine. [162]

http://dx.doi.org/10.5772/54304

11.5. Bezold's abscess

Bezold's abscess occurs when a purulent mastoiditis erodes the bone of the mastoid tip. The infection process is prevented from reaching the skin surface by the intervening neck musculature. When left untreated, the pus can track along the fascial planes of the digastric or sternocleidomastoid muscles and spread downward to the carotid sheath. The classic Bezold's abscess was first reported in 1881 following a cadaver study in which pus was found to track from the medial side of the mastoid process through the incisura digastrica. Treatment consists of incision and drainage of neck abscess and elimination of mastoid infection in addition to wide spectrum antibiotics. [171] (Figure 22)

Figure 22. A. Patient treated for otitis media developed painful neck swelling with torticollis. B. CT examination revealed abscess cavity involving the right sternocleidomastoid muscle. C. The abscess was drained from two neck incisions placed in skin creases.

11.6. Cervical Necrotizing Fasciitis

Cervical necrotizing fasciitis (CNF) is a rapidly progressing destructive, polymicrobial infection that spreads alongside deep fascial planes of the neck. It most frequently develops from odontogenic sources, but can be also caused by progression of tonsillar and pharyngeal abscesses, injury to the tissues by a foreign body or catheterization, and postoperative wound infections. If not treated promptly and radically, it can reach the thorax and develop into descending necrotizing mediastinitis. CNF complicated by mediastinitis has 41% mortality according to the recent literature review. [172] (Figure 23)

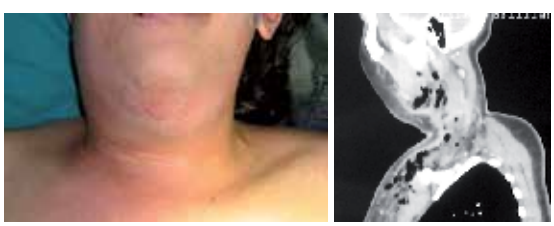

Figure 23. Fig. 23. A. Involvement of neck and upper chest wall with necrotizing fasciitis. B. CT scan shows extensive hallmark gas formation.

General principles of diagnosis and management of NF are described in the previous section dealing with facial skin infections. Early aggressive incision and drainage and debridement, along with close surveillance with repeat CT scans and retreatment, when indicated, are compulsory if any chances for favorable outcome are to be retained. No definitive treatment for descending necrotizing mediastinitis has been established. The primary treatment currently involves drainage through a combined cervical and thoracic approach, although some authors believe that cervical drainage alone is sufficient. [173]

Author details

Petr Schütz* and Hussein Hassan Hamed Ibrahim

*Address all correspondence to: petrschutz@yahoo.com

Al-Adan Dental Center, Al-Adan Hospital, Ministry of Health, State of Kuwait

References

[1] Torok ME, Conlon CP: Skin and soft tissue infections. Medicine 2009;37(11) 603-609.

[2] Ferrieri P, Dajani AS, Wannamaker LW, Chapman SS. Natural history of impetigo. I. Site sequence of acquisition and familial patterns of spread of cutaneous streptococci. The Journal of Clinical Investigation 1972;51(11) 2851–2862.

[3] Stevens DL, Bisno AL, Chambers HF, Everett ED, Dellinger P, Goldstein EJC et al.: Practice guidelines for the diagnosis and management of skin and soft-tissue infections. Clinical Infectious Diseases 2005;41(10) 1373-1406.

[4] Hirschmann JV. Impetigo: etiology and therapy. Current Clinical Topics in Infectious Diseases 2002;229(1) 42-51.

[5] Darmstadt GL, Lane AT. Impetigo: an overview. Pediatric Dermatology. 1994;11(4) 293–303.

[6] Gregory DW, Schaffner W. Pseudomonas infections associated with hot tubs and other environments. Infectious Disease Clinics of North America 1987;1(3) 635-648.

[7] Nervi SJ, Schwartz RA, Dmochowski M. Eosinophilic pustular folliculitis: a 40 year retrospect. Journal of the American Academy of Dermatology 2006;55(2) 285-289.

[8] Duvic M. EGFR inhibitor-associated acneiform folliculitis: assessment and management. American Journal of Clinical Dermatology 2008;9(5) 285-294.

[9] May AK. Skin and soft tissue infections. The Surgical Clinics of North America 2009;89(2) 403–420.

[10] Zimbelman J, Palmer A, Todd J. Improved outcome of clindamycin compared with beta-lactam antibiotic treatment for invasive Streptococcus pyogenes infection. The Pediatric Infectious Disease Journal 1999;18(12) 1096–1100.

[11] Zimakoff J, Rosdahl VT, Petersen W, Scheibel J. Recurrent staphylococcal furunculosis in families. Scandinavian Journal of Infectious Diseases 1988;20(4) 403–5.

[12] Raz R, Miron D, Colodner R, Staler Z, Samara Z, Keness Y. A 1-year trial of nasal mupirocin in the prevention of recurrent staphylococcal nasal colonization and skin infection. Archives of Internal Medicine 1996;156(10) 1109–1112.

[13] Swartz MN. Clinical practice. Cellulitis. The New England Journal of Medicine 2004;350(9) 904–912.

[14] Hepburn MJ, Dooley DP, Skidmore PJ, Ellis MW, Starnes WF, Hasewinkle WC. Comparison of short-course (5 days) and standard (10 days) treatment for uncomplicated cellulitis. Archives of Internal Medicine 2004;164(15) 1669–1674.

[15] Bisno AL, Stevens DL. Streptococcal infections in skin and soft tissues. The New England Journal of Medicine 1996;334(4) 240–245.

[16] Green RJ, Dafoe DC, Raffin TA. Necrotizing fasciitis. Chest 1996;110(1) 219–229.

[17] Elliott DC, Kufera JA, Myers RA. Necrotizing soft tissue infections: risk factors for mortality and strategies for management. Annals of Surgery 1996;224(5) 672–683.

[18] Brook I, Frazier EH. Clinical and microbiological features of necrotizing fasciitis. Journal of Clinical Microbiology 1995;33(9) 2382–2387.

[19] Shindo ML, Nalbone VP, Dougherty WR. Necrotizing fasciitis of the face. Laryngoscope 1997;107(8) 1071–1079.

[20] Panda NK, Simadri S, Sridhara SR. Cervicofacial necrotizing fasciitis: can we expect a favourable outcome? The Journal of Laryngology and Otology 2004;118(10) 771–777.

[21] Schurr C, Burghartz M, Miethke T, Kesting M, Hoang N, Staudenmaier R: Management of facial necrotizing fasciitis. European Archives of Oto-rhino-laryngology 2009;266(3) 325–331.

[22] Krenk L, Nielsen HU, Christensen ME. Necrotizing fasciitis in the head and neck region: an analysis of standard treatment effectiveness. European Archives of Oto-rhino-laryngology 2007;264(8) 917–922.

[23] Buck DW 2nd, Alam M, Kim JY. Injectable fillers for facial rejuvenation: A review. Journal of Plastic, Reconstructive & Aesthetic surgery 2009; 62(1) 11-18.

[24] Lahiri A, Waters R. Experience with Bio-Alcamid, a new soft tissue endoprosthesis. Journal of Plastic, Reconstructive & Aesthetic surgery 2007;60(6) 663-667.

[25] Davis EC, Callender VD. Aesthetic dermatology for aging ethnic skin. Dermatologic Surgery 2011;37(7) 901- 917.

[26] Christensen LH. Normal and pathologic tissue reactions to soft tissue gel fillers. Dermatologic Surgery 2007;33(Suppl 2) 168-175.

[27] Monheit GD, Rohrich RJ. The nature of long-term fillers and the risk of complications. Dermatologic Surgery 2009;35(Suppl 2) 1598-1604.

[28] Kwon D-Y, Park MH, Koh S-B, Dhong E-S, Baek S-H, Ryu HJ, Park KW. Multiple arterial embolism after illicit intranasal injection of collagenous material. Dermatologic Surgery 2010;36(7) 1196-1199.

[29] Sclafani AP, Fagien F. Treatment of injectable soft tissue filler complications. Dermatologic Surgery 2009;35(Suppl 2) 1672-1680.

[30] Ficarra G, Mosqueda-Taylor A, Carlos R. Silicone granulomas of the facial tissues: A report of seven cases. Oral Surgery, Oral Medicine, Oral Pathology, Oral Radiology, and Endodontics 2002;94(1) 65-73.

[31] Lombardi T, Samson J, Plantier F, Husson C, Küffer R. Orofacial granulomas after injection of cosmetic fillers. Histopathologic and clinical study of 11 cases. Journal of Oral Pathology & Medicine 2004;33(2) 115-120.

[32] Poveda R, Bagan JV, Murillo J, Jimenez J. Granulomatous facial reaction to injected cosmetic fillers - a presentation of five cases. Medicina Oral, Patología Oral y Cirugía Bucal 2006;11(1) E1-5.

[33] Karagozoglu H, van der Waal I. Polyacrylamide soft tissue filler nodule mimicking a mucoepidermoid carcinoma. International Journal of Oral and Maxillofacial surgery 2008;37(6) 578-580.

[34] Jham BC, Nikitakis NG, Scheper MA, Papadimitriou JC, Levy BA, Rivera H. Granulomatous foreign-body reaction involving oral and perioral tissues after injection of biomaterials: A series of 7 cases and review of the literature. Journal of Oral and Maxillofacial Surgery 2009;67(2) 280-285.

[35] Rohrich RJ, Monheit G, Nguyen AT, Brown SA, Fagien S. Soft-tissue filler complications: The important role of biofilms. Plastic and Reconstructive Surgery 2010;125(4) 1250- 256.

[36] Costerton JW, Steward PS, Greenberg EP. Bacterial biofilms: a common cause of persistent infections. Science 1999; 284(5418) 1318-1322.

[37] Rohrich RJ, Nguyen AT, Kenkel JM: Lexicon for soft tissue implants. Dermatologic Surgery 2009;35(Suppl 2) 1605-1611.

[38] Christensen LH. Host tissue interaction, fate, and risks of degradable and nondegradable gel fillers. Dermatologic Surgery 2009;35(Suppl 2) 1612-1619.

[39] Lemperle G, Nicolau P, Scheiermann N. Is there any evidence for biofilms in dermal fillers? Plastic and Reconstructive Surgery 2011;128(2) 84e-85e.

[40] Schütz P, Ibrahim HH, Hussain SS, Ali TS, El-Bassuoni K, Thomas J. Infected facial tissue fillers: Case series and review of the literature. Journal of Oral and Maxillofacial Surgery 2012;doi:10.1016/j.joms.2011.11.014

[41] Shelke LW, Van Den Elzen H, Erkamp PPM, Neumann HAM. Use of ultrasound to provide overall information on facial fillers and surrounding tissue. Dermatologic Surgery 2010;36(Suppl 3) 1843-1851.

[42] Wortsman X, Wortsman J, Orlandi C, Cardenas G, Sazunic I, Jemec GBE. Ultrasound detection and identification of cosmetic fillers in the skin. Journal of the European Academy of Dermatology and Venereology 2012;26(3) 292-301.

[43] Wilson YSH, Ellis DAF. Large needle suction aspiration of permanent fillers. Laryngoscope 2011;121(10) 2146-2149.

[44] Requena L, Requena C, Christensen L, Zimmermann US, Kutzner H, Cerroni L. Adverse reactions to injectable soft tissue fillers. Journal of the American Academy of Dermatology 2011;64(1) 1-34.

[45] Gosche JR, Vick L. Acute, subacute, and chronic cervical lymphadenitis in children. Seminars in Pediatric Surgery. 2006;15(2) 99-106.

[46] Darville T, Jacobs RF. Lymphadenopathy, lymphadenitis and lymphangitis. In: Jenson HB, Baltimore RS (eds.) Pediatric Infectious Diseases: Principles and Practice, 2nd edition, Philadelphia: Saunders, 2002. p610-629.

[47] Breitschwerdt EB, Kordick DL. Bartonella infection in animals: carriership, reservoir, potential, pathogenicity, and zoonotic potential for human infection. Clinical Microbiology Reviews 2000;13(3) 428–438.

[48] Anderson BE, Neuman MA. Bartonella spp. as emerging human pathogens. Clinical Microbiology Reviews 1997;10(2) 203-219.

[49] Bass JW, Freitas BC, Freitas AD, Sisler CL, Chan DS, Vincent JM, Person DA, Claybaugh JR, Wittler RR, Weisse ME, Regnery RL, Slater LN.. Prospective randomized double blind placebo-controlled evaluation of azithromycin for treatment of catscratch disease. The Pediatric Infectious Disease Journal 1998;17(6) 447-452.

[50] Shapiro DS, Schwartz DR. Exposure of Laboratory Workers to Francisella tularensis despite a bioterrorism procedure. Journal of Clinical Microbiology 2002;40(6) 2278-2281.

[51] Ellis J, Oyston PCF, Green M, W. Titball RW. Tularemia. Clinical Microbiology Reviews 2002;15(4) 631-646.

[52] Risi GF, Pombo DJ. 1995. Relapse of tularemia after aminoglycoside therapy — case report and discussion of therapeutic options. Clinical Infectious Diseases 1995;20(1) 174-175.

[53] Euerle B. Syphilis. http://emedicine.medscape.com/article/229461-overview (accessed 17 July 2012)

[54] Scott CM, Flini SR. Oral syphilis - re-emergence of an old disease with oral manifestations. International Journal of Oral and Maxillofacial Surgery 2005;34(1) 58-63.

[55] Compilato D, Amato S, Campisis G. Resurgence of syphilis: a diagnosis based on unusual oral mucosa lesions. Oral Surgery, Oral Medicine, Oral Pathology, Oral Radiology, and Endodontics 2009;108(3) e45-e49.

[56] [Guideline] Workowski KA, Berman S. Sexually transmitted diseases treatment guidelines, 2010. MMWR. Recommendations and reports : Morbidity and mortality weekly report. Recommendations and reports / Centers for Disease Control 2010;59(RR-12) 1-110.

[57] Odumade OA, Hogquist KA, Balfour HH Jr. Progress and problems in understanding and managing primary Epstein-Barr virus infections. Clinical Microbiology Reviews 2011;24(1) 193-209.

[58] David Lawee. Mild infectious mononucleosis presenting with transient mixed liver disease. Case report with a literature review. Canadian Family Physician 2007;53(8) 1314-1316.

[59] Ezike E. Pediatric rubella. http://emedicine.medscape.com/article/968523-overview (accessed 10 July 2012).

[60] Castillo-Solorzano C, Carrasco P, Tambini G, Reef S, Brana M, de Quadros CA. New horizons in the control of rubella and prevention of congenital rubella syndrome in the Americas. The Journal of Infectious Diseases 2003;187(Suppl 1) 146-152.

[61] Kim K, Weiss LM. Toxoplasma: the next 100 years. Microbes and Infection 2008;10(9) 978–984.

[62] McCabe RE, Brooks RG, Dorfman RF, Remington JS. Clinical spectrum in 107 cases of toxoplasmic lymphadenopathy. Reviews of Infectious Diseases 1987;9(4) 754-774.

[63] Taila AK, Hingwe AS, Johnson LEl. Toxoplasmosis in a patient who was immunocompetent: a case report. Journal of Medical Case Reports 2011,5:16 http://www.jmedicalcasereports.com/content/5/1/16 (accessed 3 August 2012)

[64] World Health Organization: Global tuberculosis control: WHO report 2011. http://www.who.int/tb/publications/global_report/2011/gtbr11_full.pdf (accessed 7 May 2012).

[65] Sharma SK, Mohan A:. Extrapulmonary tuberculosis. The Indian Journal of Medical Research 2004;120(4) 316-354.

[66] Peto HM, Pratt RH, Harrington TA, LoBue PA, Armstrong LR. Epidemiology of extrapulmonary tuberculosis in the United States,1993-2006. Clinical Infectious Diseases 2009;49(9) 1350-1357.

[67] Helbling CA, Lieger O, Smolka W, Iizuka T, Kuttenberger J. Primary tuberculosis of the TMJ: Presentation of a case and literature review. International Journal of Oral and Maxillofacial Surgery 2010;39(8) 834-838.

[68] Prasad KC, Sreedharan S, Chakravarthy Y, Prasad SC. Tuberculosis in the head and neck: Experience in India. Journal of Laryngology and Otology 2007;121(10) 979-985.

[69] Nalini B, Vinayak S. Tuberculosis in ear, nose, and throat practice: its presentation and diagnosis. American Journal of Otolaryngology 2006;27(1) 39-45.

[70] Nohrström E, Kentala E, Kuusela P, Mattila PS: Tuberculosis of the head and neck in Finland. Acta Oto-laryngologica 2007;127(7) 770-774.

[71] Menon K, Bem C, Gouldesbrough D, Strachan DR. A clinical review of 128 cases of head and neck tuberculosis presenting over a 10-year period in Bradford, UK. Journal of Laryngology and Otology. 2007;121(4) 362-368.

[72] Pekiner FN, Erseven G, Borahan MO, Gümrü B: Natural barrier in primary tuberculosis inoculation: oral mucous membrane. The International Journal of Tuberculosis and Lung Disease 2006;10(12) 1418.

[73] Wang WC, Chen JY, Chen YK, Lin LM. Tuberculosis of the head and neck: A review of 20 cases. Oral Surgery, Oral Medicine, Oral Pathology, Oral Radiology, and Endodontics 2009;107(3) 381-386.

[74] Andrade NN, Mhatre TS. Orofacial Tuberculosis—A 16-Year Experience With 46 Cases. Journal of Oral and Maxillofacial Surgery 2012;70(1) e12-e22.

[75] Kreiner M. Tuberculosis of the temporomandibular joint: Low prevalence or missed diagnosis? Journal of Craniomandibular Practice 2006;24(4) 234.

[76] Ranganathan, LK, Mathew GC, Gandhi S, Manohar M. Tuberculosis of temporomandibular joint presenting as swelling in the preauricular region. Journal of Oral and Maxillofacial Surgery 2012;70(1) e28-31.

[77] Gandhi S, Ranganathan LK, Bither S, Koshy G. Tuberculosis of temporomandibular joint: a case report. Journal of Oral and Maxillofacial Surgery 2011;69(6) e128-130.

[78] Weiler Z, Nelly P, Baruchin AM, Oren S. Diagnosis and treatment of cervical tuberculous lymphadenitis. Journal of Oral and Maxillofacial Surgery 2000,58(5) 477-481.

[79] Polesky A, Grove W, Bhatia G. Peripheral tuberculous lymphadenitis: epidemiology, diagnosis, treatment, and outcome. Medicine (Baltimore) 2005;84(6) 350–362.

[80] Falkinham JO 3rd. Epidemiology of infection by nontuberculosis mycobacteria. Clinical Microbiology Reviews 1996;9(2) 177-215.

[81] Griffith DE, Aksamit T, Brown-Elliott BA, Catanzaro A, Daley C, Gordin F, Holland SM, Horsburgh R, Huitt G, Iademarco MF, Iseman M, Olivier K, Ruoss S, von Reyn CF, Wallace RJ Jr, Winthrop K; ATS Mycobacterial Diseases Subcommittee; American Thoracic Society; Infectious Disease Society of America. An official ATS/IDSA statement: diagnosis, treatment, and prevention of nontuberculous mycobacterial disease. American Journal of Respiratory and Critical Care Medicine 2007;175(4) 367-416.

[82] Penn R, Steehler MK, Sokohl A, Harley EH. Nontuberculous mycobacterial cervicofacial lymphadenitis - a review and proposed classification system. International Journal of Pediatric Otorhinolaryngology 2011;75(12) 1599–1603.

[83] Lindeboom JA, Prins JM, Bruijnesteijn van Coppenraet ES, Lindeboom R, Kuijper EJ. Cervicofacial lymphadenitis in children caused by Mycobacterium haemophilum. Clinical Infectious Diseases 2005;41(11) 1569-1575.

[84] Lindeboom JA, Kuijper EJ, Bruijnesteijn van Coppenraet ES, Prins JM. First case of an oculofacial lesion due to Mycobacterium haemophilum infection in an immunocompetent child. Oral Surgery, Oral Medicine, Oral Pathology, Oral Radiology, and Endodontics 2006;101(6) 774-776.

[85] Robson CD, Hazra R, Bames PD, Robertson RL, Jones D, Husson RN. Nontuberculous mycobacterial infection of the head and neck in immunocompetent children: CT and MR findings. Americal Journal of Neuroradiology 1999;20(10) 1829–1835.

[86] Lindeboom JA, Kuijper EJ, Prins JM, Bruijnesteijn, van Coppenraet ES, Lindeboom R, Prins JM. Surgical excision versus antibiotic treatment for nontuberculous mycobacteria cervical lymphadenitis in children: a multicenter randomized, controlled trial. Clinical Infectious Diseases 2007;44(8) 1057-1064.

[87] Lindeboom JA. Surgical treatment for nontuberculous mycobacterial (NTM) cervicofacial lymphadenitis in children. Journal of Oral Maxillofacial Surgery 2012;70(2) 345-348.

[88] Fox PC. Bacterial infections of salivary glands. Current opinion in dentistry 1991;1(4) 411-414.

[89] McQuone SJ. Acute viral and bacterial infections of the salivary glands. Otolaryngologic Clinics of North America 1999;32(5) 793-811.

[90] Brook I. Non-odontogenic abscesses in the head and neck region. Periodontology 2000, Vol. 49, 2009, 106–125

[91] Brook I. The bacteriology of salivary gland infections. Oral and Maxillofacial Surgery Clinics of North America 2009;21(3) 269-274.

[92] Kane WJ, McCaffrey TV: Infectious Diseases of the Salivary Glands. In: Cummings CW, Fredrickson JE, Harker LA, Krause C, and Schuller D. (eds.) Otolaryngology-Head and Neck Surgery, St. Louis: C.V. Mosby; 1991.

[93] Rice DH. Chronic inflammatory disorders of the salivary glands. Otolaryngologic clinics of North America 1999;32(5) 813-818.

[94] Templer JW. Parotitis. http://emedicine.medscape.com/article/882461-overview (accessed 18 August 2012).

[95] Mandel L. Differentiating acute suppurative parotitis from acute exacerbation of a chronic parotitis: Case reports. Journal of Oral and Maxillofacial surgery 2008;66 1964-1968.

[96] Kiverniti E, Singh A, Clarke P. Küttner's tumour: an unusual cause of salivary gland enlargement. Hippokratia 2008;12(1): 56-58.

[97] Kalinowski M, Heverhagen JT, Rehberg E, Klose KJ, Wagner H-J. Comparative study of MR sialography and digital subtraction sialography for benign salivary gland disorders. American Journal of Neuroradiology 2001;23(10) 1485–1492.

[98] Qi S, Liu X, Wang S. Sialoendoscopic and irrigation findings in chronic obstructive parotitis. Laryngoscope. 2005;115(3) 541-545.

[99] Yu C, Zheng L, Yang C, Shen N. Causes of chronic obstructive parotitis and management by sialoendoscopy. Oral Surgery, Oral Medicine, Oral Pathology, Oral Radiology, and Endodontics. 2008;105(3) 365-370.

[100] Sharma R. Superficial parotidectomy for chronic parotid sialadenitis. International Journal of Oral and Maxillofacial Surgery 2012; http://dx.doi.org/10.1016/j.ijom.2012.04.003

[101] Sitheewue M, Sivachandran Y, Varathan V, Ariawardana A, Ranasinghe A. Juvenile recurrent parotitis: clinical, sialographic and ultrasonographic features. International Journal of Pediatric Dentistry 2007;17(2) 98-104.

[102] Kolho KL, Saarinen R, Paju A, Stenman J, Stenman UH, Pitkäranta A. New insights into juvenile parotitis. Acta Paediatrica 2005;94(11) 1566-1570.

[103] Reid E, Douglas F, Crow Y, Hollman A, Gibson J. Autosomal dominant juvenile recurrent parotitis. Journal of Medical Genetics 1998;35 417-419.

[104] Katz P, Hartl DM, Guerre A. Treatment of juvenile recurrent parotitis. Otolaryngologic Clinics of North America 2009;42(6) 1087–1091.

[105] Hviid A, Rubin S, Mühlemann K . Mumps. Lancet. 2008;371(9616) 932-944.

[106] Even-Tov E, Niv A, Kraus M, Nash M. Candida parotitis with abscess formation. Acta Oto-laryngologica 2006;126(3) 334-336.

[107] Leibowitz JM, Montone KT, Basu D. Warthin tumor presenting as a fungal abscess in an immunocompetent host: case report and review of the literature. Head & Neck 2010;32(1) 133-136.

[108] Goyal A, Tyagi I, Syal R, Marak RS, Singh J. Apophysomyces elegans causing acute otogenic cervicofacial zygomycosis involving salivary glands. Medical Mycology 2007;45(5) 457-461.

[109] Chandu A, MacIsaac RJ, MacGregor DP, Campbell MC, Wilson MJ, Bach LA. A case of mucormycosis limited to the parotid gland. Head & neck. 2005;27(12) 1108-1111.

[110] Hadi U, Rameh C. Intraglandular toxoplasmosis of the parotid gland pre- or postoperative diagnosis? American Journal of Otolaryngology 2007;28(3) 201-204.

[111] Tsai YT, Yeh CJ, Chen YA, Chen YW, Huang SF. Bilateral parotid abscesses as the initial presentation of strongyloidiasis in the immunocompetent host. Head & Neck. 2012;34(7) 1051-1054.

[112] Ah-See KW, Evans AS. Sinusitis and its management. British medical journal 2007;334(7589) 358-361.

[113] Meltzer EO, Hamilos DL. Rhinosinusitis diagnosis and management for the clinician: a synopsis of recent consensus guidelines. Mayo Clinic proceedings 2011;86(5)427-443.

[114] Patel NA, Ferguson BJ. Odontogenic sinusitis: an ancient but underappreciated cause of maxillary sinusitis. Current Opinion in Otolaryngology & Head & Neck Surgery 2012, 20(1) 24–28.

[115] Fokkens W, Lund V, Bachert C, Clement P, Helllings P, Holmstrom M, Jones N, Kalogjera L, Kennedy D, Kowalski M, Malmberg H, Mullol J, Passali D, Stammberger H, Stierna P; EAACI. EAACI position paper on rhinosinusitis and nasal polyps executive summary. Allergy 2005;60(5) 583-601.

[116] Karaman E, Hacizade Y, Isildak H, Kaytaz . Pott's puffy tumor. The Journal of Craniofacial Surgery 2008;19(6) 16941697.

[117] Lang EE, Curran AJ, Patil N, Walsh RM, Rawluk D, Walsh MA. Intracranial complications of acute frontal sinusitis. Clinical Otolaryngology and Allied Sciences 2001;26(6) 452-457.

[118] Mandal R, Patel N, Ferguson BJ. Role of antibiotics in sinusitis. Current Opinion in Infectious Diseases 2012;25(2) 183–192.

[119] Williamson IG, Rumsby K, Benge S, Moore M, Smith PV, Cross M, Little P. Antibiotics and topical nasal steroid for treatment of acute maxillary sinusitis: a randomized controlled trial. Journal of the American Medical Association. 2007;298(21) 2487-2496.

[120] Blake FAS, Siegert J, Wedl J, Gbara A, Schmelzle R: The acute orbit: etiology, diagnosis, and therapy. Journal of Oral and Maxillofacial Surgery 2006;64(1) 87-93.

[121] Schwarz G. Etiology, diagnosis, and treatment of orbital infections. Current Infectious Disease Reports 2002;4(3) 201–205.

[122] Vairaktaris E, Moschos MM, Vassiliou S, Baltatzis S, Kalimeras E, Avgoustidis D, Pappas Z, Moschos MN. Orbital cellulitis, orbital subperiosteal and intraorbital abscess. Report of three cases and review of the literature. Journal of Cranio-maxillofacial surgery 2009;37(3) 132-136.

[123] Thakar A, Tandon DA, Thakar MD, Nivsarkar S. Orbital cellulitis revisited. Indian Journal of Otolaryngology Head & Neck Surgery 2000;52(3) 235-242.an Journal of Otolaryngology and Head and Neck Surgery Vol. 52 No. 3, July - 0

[124] Moloney JR, Badham NJ, McRae A. The acute orbit. Preseptal (periorbital) cellulitis, subperiosteal abscess and orbital cellulitis due to sinusitis. Journal of Laryngology and Otology. Supplement 1987;12 1-18.

[125] O'Ryan F, Diloreto D, Barber HD, Bruckner R. Orbital infections: diagnosis and surgical treatment. Journal of Oral and Maxillofacial Surgery 1988;46(11) 991-997.

[126] De Wyngaert R, Casteels I, Demaerel P. Orbital and anterior visual pathway infection and inflammation. Neuroradiology 2009;51(6) 385–396.

[127] Kaplan DM, Briscoe D, Gatot A, et al: The use of standardized orbital ultrasound in the diagnosis of sinus induced infections of the orbit in children: A preliminary report. International Journal of Pediatric Otorhinolaryngology 1999;48(2) 155-162.

[128] Lusk R. Complications of Sinusitis. In: Mitchell RB, Pereira KD, eds. Pediatric Otolaryngology for the Clinician. Totowa, NJ: Humana Press; 2009.

[129] Iatta R, Napoli C, Borghi E, Montagna MT. Rare mycoses of the oral cavity: a literature epidemiologic review. Oral Surgery, Oral Medicine, Oral Pathology, Oral Radiology, and Endodontology 2009;108(5) 647-655.

[130] Anaissie EJ: Clinical Mycology and Antifungal Therapy. http://www.medscape.org/viewarticle/495502_print (accessed 20 August 2012)

[131] Maartens G, Wood MJ. The clinical presentation and diagnosis of invasive fungal infections. The Journal of Antimicrobial Chemotherapy 1991;28(Suppl A) 13-22.

[132] Mehrabi M, Bagheri S, Leonard MK Jr, Perciaccante VJ. Mucocutaneous manifestation of cryptococcal infection: report of a case and review of the literature. Journal of Oral and Maxillofacial Surgery 2005;63(10) 1543-1549.

[133] Liew C, Barreto L, Mills C. Interesting case: An unusual case of oral ulceration. British Journal of Oral and Maxillofacial Surgery 2006;44(5) 350.

[134] Kantarciğlu AS, Gulenc M, Yücel A, Uzun N, Taskin T, Sakiz D, Atlas K. Cryptococcal parotid involvement: an uncommon localization of Cryptococcus neoformans. Medical Mycology 2006;44(3) 279-278.

[135] Scheer M, Rabbels J, Neugebauer J, Cornely OA, Drebber U, Zöeller JE. Combined intra- and extracranial cryptococcal infection of a 20-year-old patient in right temporal area. Journal of Oral and Maxillofacial Surgery 2011;69(1) 222-226.

[136] Prendiville S, Bielamowicz SA, Hawrych A, Deeb ZE. Isolated cryptococcal sphenoid sinusitis with septicemia, meningitis, and subsequent skull base osteomyelitis in an immunocompetent patient. Otolaryngology--Head and Neck Surgery 2000;123(3) 277-279.

[137] Karthaus M. Prophylaxis and treatment of invasive aspergillosis with voriconazole, posaconazole and caspofungin: review of the literature. European Journal of Medical Research 2011;16(4) 145-152.

[138] Fuqua TH, Sittitavornwong S, Knoll M, Said-Al-Naief N. Primary invasive oral aspergillosis: an updated literature review. Journal of Oral and Maxillofacial Surgery 2010;68(10) 2557-2563.

[139] Costa F, Polini F, Zerman N, Robiony M, Toro C, Politi M. Surgical treatment of Aspergillus mycetomas of the maxillary sinus: Review of the literature. Oral Surgery, Oral Medicine, Oral Pathology, Oral Radiology, and Endodontology 2007;103(6) e23-e29.

[140] Bigliazzi C, Poletti V, Dell'Amore D, Saragoni L, Colby TV. Disseminated basidiobolomycosis in an immunocompetent woman. Journal of Clinical Microbiology 2004;42(3) 1367-1369.

[141] Ribes JA, Vanover-Sams CL, Baker DJ. Zygomycetes in human disease. Clinical Microbiology Reviews 2000;13(2) 236-301.

[142] Nithyanandam S, Jacob MS, Battu RR, Thomas RK, Correa MA, D'Souza O. Rhino-orbito-cerebral mucormycosis. A retrospective analysis of clinical features and treatment outcomes. Indian Journal of Ophthalmology 2003;51(3) 231-236.

[143] Pagano L, Offidani M, Fianchi L, Nosari A, Candoni A, Piccardi M, Corvatta L, D'Antonio D, Girmenia C, Martino P, Del Favero A; GIMEMA (Gruppo Italiano Malattie EMatologiche dell'Adulto) Infection Program. Mucormycosis in hematologic patients. Haematologica 2004;89(2) 207-214.

[144] Verma GR, Lobo DR, Walker R, Bose SM, Gupta KL. Disseminated mucormycosis in healthy adults. Journal of Postgraduate Medicine 1995;41(2) 40-42.

[145] Schütz P, Behbehani JH, Khan ZU, Ahmad S, Kazem MA, Dhar R, Eskaf W, Hamed HH and Cunnigham L, Jr.: Fatal rhino-orbito-cerebral zygomycosis caused by Apophysomyces elegans in a healthy patient: clinical therapeutic conference. Journal of Oral MaxillofacialSsurgery, 2006;(64)12 1795-1802.

[146] Roden MM, Zaoutis TE, Buchanan WL, Knudsen TA, Sarkisova TA, Schaufele RL, Sein M, Sein T, Chiou CC, Chu JH, Kontoyiannis DP, Walsh TJ. Epidemiology and outcome of zygomycosis: a review of 929 reported cases. Clinical Infectious Diseases 2005;41(5) 634-653.

[147] Fairley C, Sullivan TJ, Bartley P, Allworth T, Lewandowski R. Survival after rhino-orbital-cerebral mucormycosis in an immunocompetent patient. Ophthalmology 2000;107(3) 555-558.

[148] Dhiwakar M, Thakar A, Bahadur S. Improving outcomes in rhinocerebral mucormycosis—early diagnostic pointers and prognostic factors. Journal of Laryngology and Otology 2003;117(11) 861-865.

[149] Adler-Moore J, Proffit TR: AmBisome. Liposomal formulation, structure, mechanism of action and preclinical experience. The Journal of Antimicrobial Chemotherapy 2002;49(Suppl 1) 21-30.

[150] Page RL 2nd, Schwiesow J, Hilts A. Posaconazole as salvage therapy in a patient with disseminated zygomycosis: case report and review of the literature. Pharmacotherapy 2007;27(2) 290-298.

[151] Adler DE, Milhorat TH, Miller JI. Treatment of rhinocerebral mucormycosis with intravenous, interstitial and cerebrospinal fluid administration of amphotericin B: Case report. Neurosurgery 1998;42(3) 644-648.

[152] Islam MN, Cohen DM, Celestina LJ, Ojha J, Claudio R, Bhattacharyya IB. Rhinocerebral zygomycosis: an increasingly frequent challenge: update and favorable outcomes in two cases. Oral Surgery, Oral medicine, Oral Pathology, Oral Radiology, and Endodontology 2007;104(5) e28-e34.

[153] Cano MV, Hajjeh RA. The epidemiology of histoplasmosis: a review. Seminars in Respiratory Infections 2001;16(2) 109-18.

[154] Woods JP, Heinecke EL, Luecke JW, Maldonado E, Ng JZ, Retallack DM, Timmerman MM. Pathogenesis of Histoplasma capsulatum. Seminars in Respiratory Infections 2001;16(2) 91-101.

[155] Scully C, Almeida OP. Orofacial manifestations of the systemic mycoses. Journal of Oral pathology and Medicine 1992;21(7) 289-94.

[156] Akin L, Herford AS, Cicciù M. Oral presentation of disseminated histoplasmosis: A case report and literature review. Journal of Oral and Maxillofacial Surgery 2011 ; 69(2) 535-541.

[157] Mignogna MD, Fedele S, Lo Russo L, Ruoppo E, Lo Muzio LA. A case of oral localized histoplasmosis in an immunocompetent patient. European Journal of Clinical Microbiology & Infectious Diseases 2001;20(10) 753-5.

[158] Rahman MT, Bakar NH, Philip R, Shamsudin AR. Oral histoplasmosis presenting as oral ulcer in a non-HIV patient. The Southeast Asian Journal of Tropical Medicine and Public Health 2004;35(2) 388-390.

[159] Johnson JA, Loyd JE, Wheat LJ, Netterville JL. A case series and review of histoplasmosis infection in the neck. Archives of Otolaryngology--Head & Neck surgery 2010;136(9) 916-919.

[160] Brook I. Microbiology and management of peritonsillar, retropharyngeal, and parapharyngeal abscesses. Journal of Oral and Maxillofacial Surgery 2004;62(12) 1545–1550.

[161] Sakaguchi M, Sato S, Ishiyama T, Katsuno S, Taguchi K. Characterization and management of deep neck infections. International Journal of Oral and Maxillofacial Surgery 1997;26(2) 131–4.

[162] Reynolds SC, Chow AV. Life-lhreatening infections of the peripharyngeal and deep fascial spaces of the head and neck. Infectious Disease Clinics of North America 2007;21(2) 557–576

[163] Dool H, Soetekouw R, van Zanten M, Grooters E. Lemierre's syndrome: three cases and a review. European Archives of Oto-rhino-laryngology 2005;262(8) 651–4.

[164] Singh I, Meher R, Agarwal S, Raj A. Carotid artery erosion in a 4-year child. International Journal of Pediatric Otorhinolaryngology 2003;67(9) 995-998.

[165] Sichel JY, Attal P, Hocwald E, Eliashar R. Redefining parapharyngeal space infections. The Annals of Otology, Rhinology, and Laryngology 2006;115(920) 117–123.

[166] Boscolo-Rizzo P, Marchiori C, Zanetti F, Vaglia A, Da Mosto MC. Conservative management of deep neck abscesses in adults: the importance of CECT findings. Otolaryngology--Head and Neck surgery 2006;135(6) 894–899.

[167] Chang L, Chi H, Chiu NC, Huang FY, Lee KS. Deep neck infections in different age groups of children. Journal of Microbiology, Immunology, and Infection 2010;43(1) 47–52.

[168] Harkani A, Hassani R, Ziad T, Aderdour L, Nouri H, Rochdi Y, Raji A. Retropharyngeal abscess in adults: Five case reports and review of the literature. ScientificWorldJournal 2011;11 1623–1629.

[169] Hoffmann C, Pierrot S, Contencin P, Morisseau-Durand MP, Manach Y, Couloigner V. Retropharyngeal infections in children. Treatment, strategies and outcomes. International Journal of Pediatric Otorhinolaryngology 2011;75(9) 1099-1103.

[170] McClay JE, Murray AD, Booth T: Intravenous antibiotic therapy for deep neck abscessess defined by computed tomography. Archives of Otolaryngology--Head & Neck Surgery 2003;129(11) 1207-1212.

[171] Uchida Y, Ueda H, Nakashima T. Bezold's abscess arising with recurrent cholesteatoma 20 years after the first surgery: with a review of the 18 cases published in Japan since 1960. Auris, Nasus, Larynx 2002;29(4) 375-378.

[172] Sarma T, Sengupta T, Miloro M, Kolokythas A. Cervical necrotizing fasciitis with descending mediastinitis: literature review and case report. Journal of Oral and Maxillofacial surgery 2011;70(6) 1342-1350.

[173] Roccia F, Pecorari GC, Oliaro A, Passet E, Rossi P, Nadalin J, Garzino-Demo P, Berrone S. Ten years of descending necrotizing mediastinitis: management of 23 cases. Journal of Oral and Maxillofacial Surgery 2007;65(9) 1716-24.

Section 3

Oral and Maxillofacial Pathologies: Diagnosis and Management

Chapter 5

Diagnosis and Management of Common Oral and Maxillofacial Lesions

Taghi Azizi

Additional information is available at the end of the chapter

http://dx.doi.org/10.5772/54646

1. Introduction

Diagnosis and management of oral and maxillofacial lesions is of paramount important to practicing surgeons. Multiple references and textbooks are needed to study these lesions. Herein we attempted to gather common pathological entities occurring in this region and describe the characteristics, clinical presentation, histopathology, diagnosis and management of each in one chapter. Epithelial tumors are presented first.

2. Epithelial tumors

Common epithelial tumors of concern to oral and maxillofacial surgeons are: Inverted papilloma, Squamous cell carcinoma, Pleomorphic adenoma, Mucoepidermoid carcinoma, Sinonasal undifferentiated carcinoma, Adenoid cyctic carcinoma, Basal cell carcinoma and Verrucous carcinoma.

2.1. lnverted papilloma

2.1.1. Clinical features

Inverted papillomas characteristically arise from the lateral nasal wall in the region of the middle turbinate or ethmoid recess, and often extend secondarily into the sinuses, especially the maxillary sinus. Nasal obstruction is the most common presenting symptom. Other manifestations include nasal drainage, epistaxis, anosmia, headaches (especially frontal), epiphora, proptosis and diplopia. Pain, on the other hand, is an uncommon initial complaint,

INTECH
open science | open minds

© 2013 Azizi; licensee InTech. This is a paper distributed under the terms of the Creative Commons Attribution License (http://creativecommons.org/licenses/by/3.0), which permits unrestricted use, distribution, and reproduction in any medium, provided the original work is properly cited.

occurring in only about, 10% of all cases. When present, it should always arouse suspicion of secondary infection or malignant change (Fig. 1).[1,2]

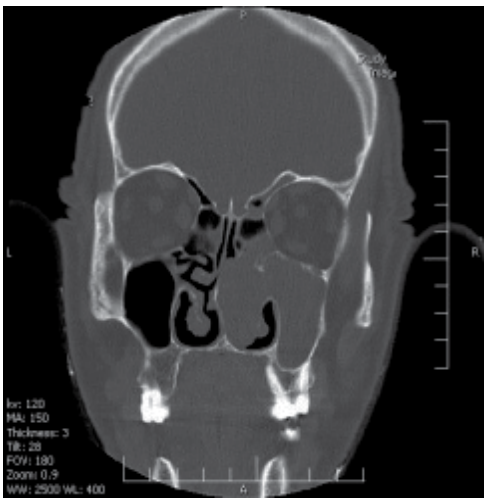

Figure 1. Inverted papilloma of the right nasal cavity and maxillary sinus.

2.1.2. Histopathology

Inverted papillomas are composed exclusively or almost exclusively of hyperplastic ribbons of basement membrane-enclosed epithelium that grow endophytically into the underlying stroma. Infrequently, a minor exophytic component may be seen. The epithelium is multilayered, usually 5-30 cells thick, and formed of squamous or ciliated columnar (respiratory epithelial) cells admixed with mucocytes. Nonkeratinizing squamous or transitional-type epithelium tends to predominate, and is often covered by a single layer of ciliated columnar cells (Fig. 2).[1,-3]

2.1.3. Treatment and prognosis

Complete surgical excision is the treatment of choice. Inadequate excision of lesions probably accounts for the local recurrence rate of 22-50% [1-,3]

2.2. Squamous cell carcinoma

2.2.1. Clinical features

Squamous cell carcinoma (SCC) of the jaws or antrum is not an uncommon malignancy. It is largely of unknown cause but may be related to known carcinogens. However, unlike squamous cell carcinomas in other head and neck sites, squamous cell carcinomas of the paranasal sinuses have been associated only weakly with tobacco use. It occurs more often in men (2–5 times) and affects individuals with a mean or median age of 60 to 65 years. Signs and

http://dx.doi.org/10.5772/54646

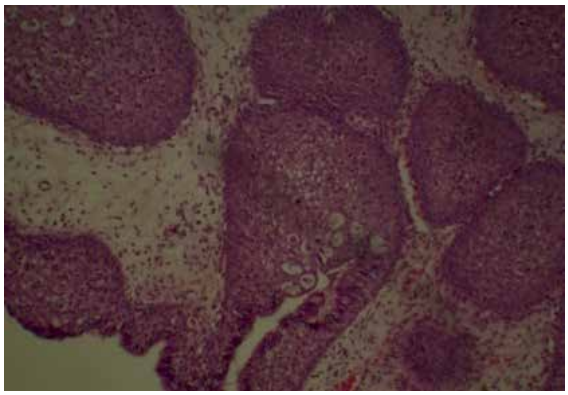

Figure 2. Inverted papilloma low power photomicrograph. Note epithelial-lined, duct-like structures that endophytically project into the underlying stroma

symptoms depend on the stage of the disease and direction of tumor growth. Early on, they are vague and often confused with other lesions. [1,3- 8] Complaints can be grouped into five categories: nasal, oral, ocular, facial, and neurological. Nasal manifestations include unilateral stuffiness, obstruction rhinorrhea, and epistaxis. Oral findings include pain referred to the upper premolar and molar teeth; loosening of the teeth; swelling or ulceration of the palate, alveolar ridge, or gingivobuccal sulcus; or a fistula. Common ocular features consist of swelling of the eyelids, excessive tearing, visual disturbances, and proptosis. Facial symptoms from involvement of the anterior wall of the sinus and are characterized by swelling and asymmetry of the cheeks. Neurological manifestations are often due to tumor infiltration of the branches of the fifth cranial nerve with subsequent numbness or paresthesia of the lips or cheek. Approximately 10% to 15% of patients present with positive regional lymph nodes, usually the upper jugular, submandibular and retropharyngeal. Distant metastases at the time of diagnosis, however, are uncommon [9-11] Clinically, it usually appears exophytic with an indurated margin. Extension into structures, such as the tongue, cheek, oral cavity, alveolus or palate, infratemporal fossa, and periorbital soft tissue, is not uncommon (Fig. 3). [1,3-8]

Figure 3. Squamous cell carcinoma ulcerated lesion of the hard palate

2.2.2. Radiographic features

Computed tomography and MRI are indispensable, not only in determining the extent of disease, but also in assisting the surgeon in selecting the best operative approach (Fig. 4).

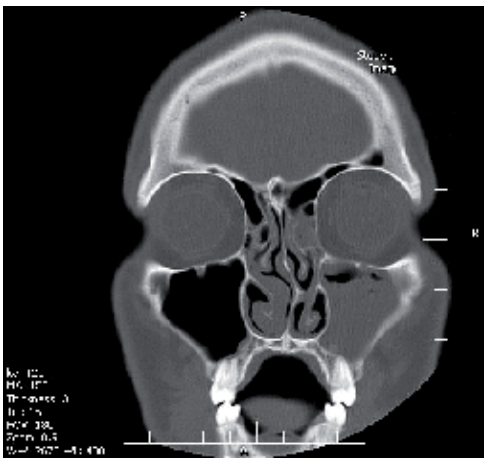

Figure 4. SCC of the right maxillary sinus.

2.2.3. Histopathologic features

The vast majority of squamous carcinomas are either well or moderately differentiated. Poorly differentiated tumors are less common (Fig. 5).[2]

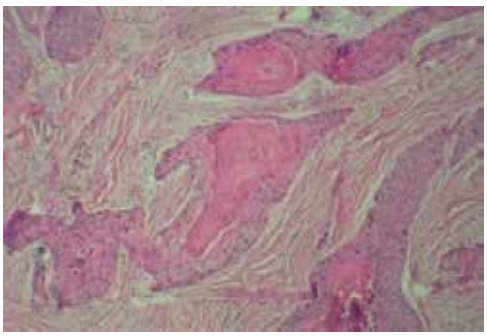

Figure 5. Moderately differentiated SCC; small nests of squamous cells with central keratinization.

2.2.4. Treatment and prognosis

SCC of the jaws and oral cavity usually is treated by block resection and 1-2 cm free margins. Some cases are treated by radiotherapy or combined radical surgery and radiotherapy. However, even with radical treatment the prognosis is poor, with a 5-year survival rate of

http://dx.doi.org/10.5772/54646

approximately 40%. The presence of metastatic deposits in local lymph nodes reduces the survival rate to less than 8%, as does involvement of the pterygopalatine fossa. With or without cervical node involvement, death usually occurs from local destruction and the inability to control the primary disease [1,3- 8] Because the tumors of the sinus are generally advanced at the time of diagnosis, a combination of surgery and radiation is used in most instances, with or without chemotherapy. Local recurrence, seen in about 30% to 45% (range 18–75%) of cases, is the most common cause of treatment failure and death. Virtually, all recurrences appear within two years of therapy and most within one year. During the course of the disease, 25% to 30% of patients will develop positive regional lymph nodes and 10% to 20% may experience distant metastases.[9,10,11]

2.3. Pleomorphic adenoma

Pleomorphic adenoma is the most common salivary gland tumor and accounts for about 60% of all salivary neoplasms[1,2,8]

2.3.1. Clinical features

Pleomorphic adenomas are usually slow-growing painless masses. Small tumors typically form smooth, mobile, firm lumps but larger tumors tend to become bossellated and may attenuate the overlying skin or mucosa. Pain or facial palsy is uncommon but are occasionally seen, usually in relation to infarcted tumors. The size of most tumors vary from about 2-5 cm but some reported cases have been massive. In the palate, tumors are usually seen at the junction of the hard and soft palate unilaterally. In the hard palate they feel fixed due to the proximity of the underlying mucoperiosteum.[2,8]

2.3.2. Histopathology

Pleomorphic adenoma shows a remarkable degree of morphological diversity The essential components are the capsule, epithelial and myoepithelial cells, and mesenchymal or stromal elements. The epithelial component shows a wide variety of cell types including cuboidal, basaloid, squamous, spindle cell, plasmacytoid and clear cells. Rarely, mucous, sebaceous and serous acinar cells are seen. These cells are cytologically bland and typically have vacuolated nuclei, without prominent nucleoli, and a low mitotic activuty. The epithelium usually forms sheets or duct-like structures. The mesenchymal-like component is mucoid/myxoid, cartilaginous or hyalinized and sometimes this tissue forms the bulk of the tumor (Fig. 6). [1]

2.3.3. Treatment and prognosis

Although pleomorphic adenoma is a benign tumor it can cause problems in clinical management due to its tendency to recur and the risk of malignant transformation. Therefore it should be removed with free margins and the adjacent bone i.e. hard palate (or a layer of bone i.e. cortex of mandible). Recurrences are rare in the minor glands but in a meta-analysis of parotid tumors 3.4% of tumors recurred after 5 years and 6.8% after 10 years with a range of 1-50%.

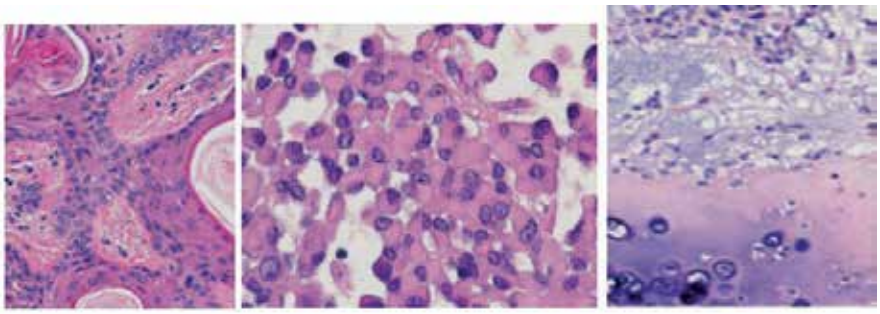

Figure 6. Pleomorphic adenoma. A.Squamous differentiation B.Plasmacytoid differentiation. C. Chondroid differentiation.

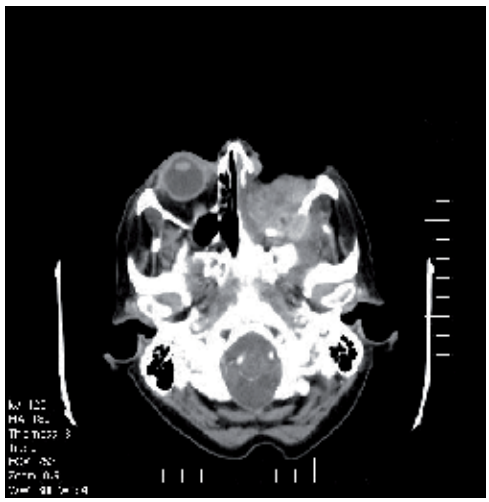

Figure 7. CT scan of mucoepidermoid carcinoma in right maxillary sinus.

Many recurrent pleomorphic adenomas are multifocal and some are so widely distributed that surgical control becomes impossible.[2]

2.4. Mucoepidermoid carcinoma

2.4.1. Clinical and radiographic features

Mucoepidermoid carcinoma is most common in the parotid gland and usually appears as an asymptomatic swelling. Mucoepidermoid carcinoma is the most common malignant salivary gland tumor in children. The minor glands constitute the second most common site, especially in the palate. Intraosseous tumors also may develop in the jaws. Pain or facial nerve palsy may develop, usually in association with high grade tumors. [1,2,8]. CT scan and MRI are essential prior to treatment (Fig.7).

http://dx.doi.org/10.5772/54646

2.4.2. Histopathologic features

As its name implies, *mucoepidermoid carcinoma* is composed of a mixture of mucus-producing cells and squamous (epidermoid) cells The mucous cells vary in shape but contain abundant foamy cytoplasm that stains positively with mucin stains. The epidermoid cells are characterized by squamoid features, often demonstrating a polygonal shape, intercellular bridges, and. rarely, keratinization. In addition, a third type of cell—the intermediate cell is typically present and is believed to be a progenitor of both the mucous and the epidermoid cells. Intermediate cells vary in appearance from small, basaloid ("maternal") cells to slightly larger ovoid cells with scant, pale eosinophilic cytoplasm. Some tumors also show variable numbers of clear cells (Fig.8).[1]

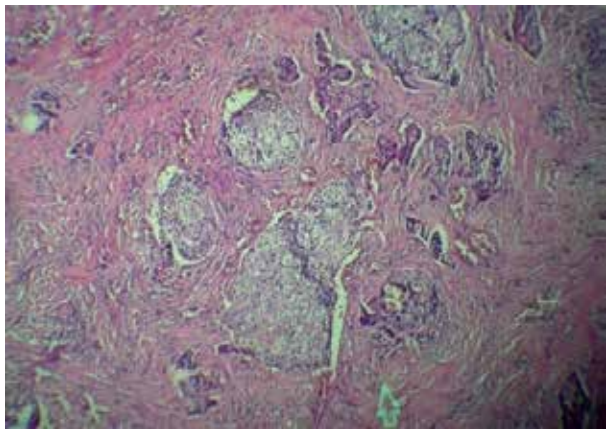

Figure 8. High-grade salivary-type mucoepidermoid carcinoma cells, and rare mucinous cells exhibiting mild nuclear changes, cords and strands of squamoid cells and clear pleomorphism.

2.4.3. Treatment and prognosis

The treatment of mucoepidermoid carcinoma is predicated by the location, histopathologic grade, and clinical stage of the tumor. Early-stage tumors of the parotid can often be treated by subtotal parotidectomy with preservation of the facial nerve. Advanced tumors may necessitate total removal of the parotid gland, with sacrifice of the facial nerve. Submandibular gland tumors are treated by total removal of the gland. Mucoepidermoid carcinomas of the minor glands usually are treated by assured complete surgical excision with free margins. For low-grade. Neoplasms, only a modest margin of surrounding normal tissue may needed to be removed, but high-grade or large tumors warrant wider resection, similar to that required for squamous cell carcinomas. If there is underlying bone destruction, then the involved bone must be excised. Radical neck dissection is indicated for patients with clinical evidence of metastatic disease and also may be considered for patients with larger or high-grade tumors. Postoperative radiation therapy also may be used for more aggressive tumors.[1] The prognosis depends on the grade and stage of the tumor. Patients with low-grade tumors generally

have a good prognosis. For most primary sites, local recurrences or regional metastases are uncommon, and around 90% to 98% of patients are cured. The prognosis for those with intermediate-grade tumors is slightly worse than that for low-grade rumors. The outlook for patients with high-grade tumors is guarded, with only 30% to 54% of patients surviving.[1]

2.5. Sinonasal undifferentiated carcinoma

Sinonasal undifferentiated carcinoma (SNUC) is a rare, highly aggressive, and clinicopathologically distinctive neoplasm of the nasal cavity and paranasal sinuses. The tumor was first described in 1986. Since then fewer than 100 cases have been reported. In the earlier literature, tumors of this type were probably reported as anaplastic or undifferentiated carcinomas. The histogenesis is uncertain; some investigators have theorized that the cell of origin may be related to the Schneiderian membrane or olfactory epithelium. The pathogenesis of SNUC is poorly understood. A few cases have been associated with a history of smoking or the presence of Epstein-Barr virus (EBV). Although a strong correlation with these factors has not been established. In some instances, patients have developed SNUC secondary to radiation therapy for nasopharyngeal carcinoma or retinoblastoma.[1,3-8]

2.5.1. Clinical and radiographic features

Although a broad age range (3rd- 9th decades) has been reported, there is a tendency for older patients to be affected, with a median age at presentation being in the 6th decade. Men are affected more commonly than women, with a male to female ratio of approximately 2:1 to 3:1. SNUC is well known for rapid development of locally extensive disease. The neoplasm typically appears as a large tumor mass that can involve multiple regions of the sinonasal tract, usually including the nasal cavity, maxillary sinus, and ethmoid sinuses. In addition, extension into contiguous sites—such as the nasopharynx, orbit, and cranial cavity—is common. Inferior penetration into the oral cavity is possible as well. There is usually relatively rapid development of multiple sinonasal symptoms, including nasal obstruction, discharge, epistaxis, swelling, and pain. Orbital involvement may lead to proptosis, periorbital swelling, diplopia and vision loss. Cranial nerve palsies are a common finding as well. Radiographic assessment is best performed by CT or MRI, which typically reveals a large, expansile sinonasal mass with bony destruction and invasion of adjacent structures (Fig.9). [1-8]

2.5.2. Histopathologic features

Sinonasal undifferentiated carcinoma is characterized by trabeculae, ribbons, sheets, and nests of polygonal cells with minimal cytoplasm and pleomorphic, hyperchromatic vesicular nuclei. No squamous or glandular differentiation should be observed. Mitotic figures are numerous. Tumor necrosis, apoptosis. and lymphovascular invasion are usually prominent. The surface epithelium overlying the tumor may exhibit dysplasia or carcinoma *in situ.* Immunohistochemical staining for cytokeratin or epithelial membrane antigen is typically positive (Fig. 10). [1 -8]

http://dx.doi.org/10.5772/54646

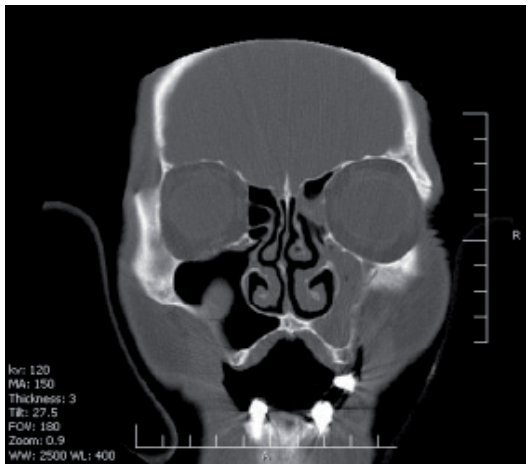

Figure 9. Sinonasal undifferentiated carcinoma mass in the right maxillary sinus.

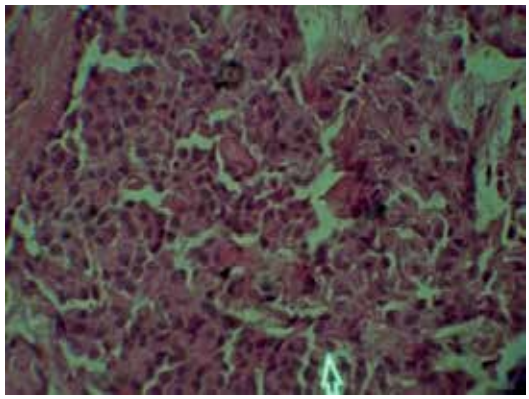

Figure 10. Undifferentiated carcinoma neoplastic cells with characteristic, chromatically uniform, vesicular nuclei, with no evidence of squamous differentiation.

2.5.3. Treatment and prognosis

The standard approach has been aggressive multimodal therapy, including complete surgical resection when feasible followed by adjuvant radiation and/or chemotherapy. The prognosis for this lesion is extremely poor, with an overall 5-year survival rate of less than 20%. However, a few centers recently have reported promising results with induction chemotherapy followed by radiation and surgical resection of any remaining disease. This newer treatment approach has been associated with 2-year survival rates of 64% to75%. High-dose chemotherapy and bone marrow transplantation may extend the life of the patient. Local recurrence is common and is the major cause of morbidity and mortality. Metastasis is possible, usually to cervical lymph nodes, bone, liver, or brain. [1-8]

2.6. Adenoid cystic carcinoma

2.6.1. Clinical and radiographic features

The adenoid cystic carcinoma usually appears as a slow growing mass. Pain is a common and important finding, occasionally occurring early in the course of the disease before there is a noticeable swelling. Patients often complain of a constant, low-grade, dull ache, which gradually increases in intensity. Facial nerve paralysis may develop with parotid tumors. Palatal tumors can be smooth surfaced or ulcerated. Tumors arising in the palate or maxillary sinus often show radiographic evidence of bone destruction of the hard palate with extension of the tumor into the nasal cavity and maxillary sinuses (Fig.11).[1-8]

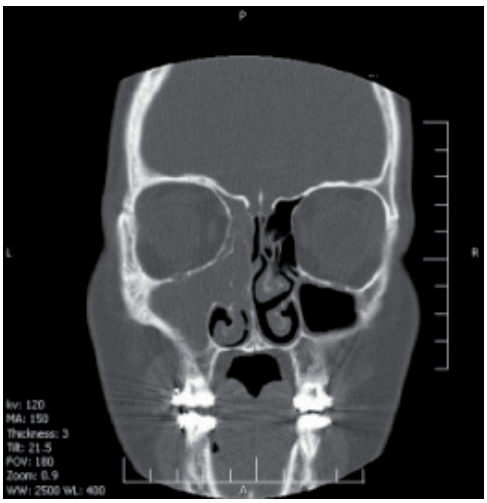

Figure 11. Adenoid cystic carcinoma. Note destruction of the left maxillary sinus.

2.6.2. Histopathologic features

Three major patterns are recognized: [1] cribriform. [2] tubular, and [3] solid. Usually a combination of these is seen, and the tumor is classified based on the predominant pattern (Fig.12).[1-8]

2.6.3. Treatment and prognosis

Adenoid cystic carcinoma is a relentless tumor that is prone to local recurrence and eventual distant metastasis. Surgical excision is usually the treatment of choice, and adjunct radiation therapy may slightly improve patient survival in some cases. Because metastasis to regional lymph nodes is uncommon, neck dissection typically is not indicated. Because of poor overall prognosis, regardless of treatment, clinicians should be cautioned against needlessly aggressive and mutilating surgical procedures for large tumors or cases showing metastases. [1- 8]

http://dx.doi.org/10.5772/54646

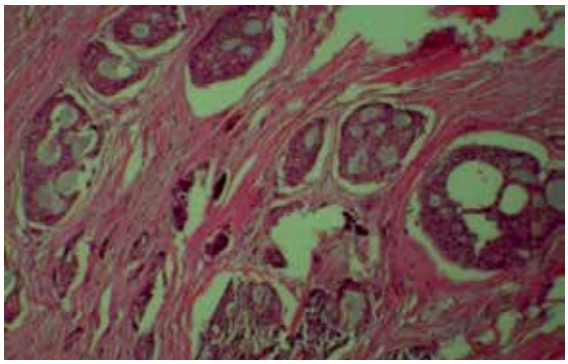

Figure 12. Adenoid cystic carcinoma; cribriform variants may show tumor cell sheets containing cylindrical, pseudoluminal spaces.

2.7. Basal cell carcinoma

2.7.1. Clinical features

Basal cell carcinoma (BCC), the most common skin cancer (and the most common of all cancers), is a locally invasive, slowly spreading, primary epithelial malignancy that arises from the basal cell layer of the skin and its appendages. Basal cell carcinoma is a disease of adult caucasions, especially those with fair complexions. Although most patients are older than 40 years of age at the time of diagnosis, some lesions are detected as early as the second decade of life, particularly in patients with red or blonde hair and blue or green eyes. Approximately 80% of lesions occur on the head and neck, with the remainder involving the trunk and limbs[1,8]

2.7.2. Histopathologic features

The basal cell carcinoma displays a considerable diversity of appearances under the microscope i.e. nodulocystic (noduloulcerative), superficial, adenoid, pigmented, infiltrative, morpheaform, and keratotic. The noduloulcerative pigmented, and syndrome-related basal cell carcinomas are comprised of uniform ovoid, dark-staining basaloid cells with moderate-sized nuclei and relatively little cytoplasm. The cells are arranged into well-demarcated islands and strands, which appear to arise from the basal cell layer of the overlying epidermis and invade into the underlying dermal connective tissue. Epithelial islands typically demonstrate palisading of the peripheral cells; frequently a clear zone of artifactual retraction is seen between the epithelial islands and the connective tissue (Fig.13).[1,8]

2.7.3. Treatment and prognosis

The treatment of basal cell carcinoma often depends on the size and site of the lesion. Small lesions (lesions < l cm) are treated by routine surgical excision, laser ablation or electrodesiccation and curettage (with 3- to 5 mm margins of clinically normal-appearing skin beyond the visible lesion). These methods result in a cure rate of 95% to 98%. Radical surgical excision and

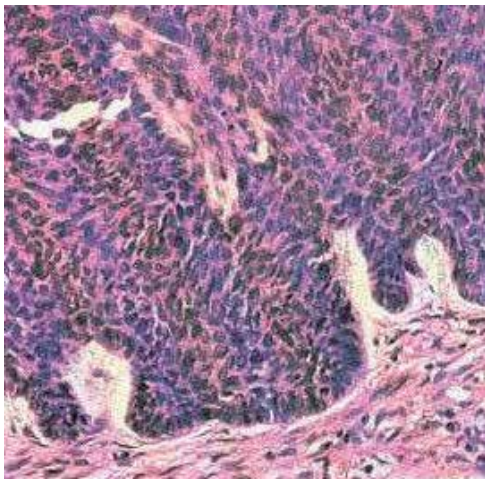

Figure 13. BCC. Tumor nests are composed of small, monotonous cells with dark nuclei and scant basophilic cytoplasm.

radiation therapy are recommended for large or aggressive lesions. For sclerosing types of BBC, recurrent lesions, or lesions situated near embryonic planes of fusion (along which these tumor cells tend to invade), a procedure called Mohs micrographic surgery should be used. This technique essentially uses frozen-section evaluation of specially mapped and marked surgical specimens to determine whether tumor tissue has been left behind. If it has, then the surgeon can return immediately to that particular area and remove more tissue, repeating the process until the patient is free of diseased margins.[1,8]

2.8. Verrucous carcinoma

Verrucous carcinoma (VC) is a nonmetastasizing variant of well-differentiated squamous cell carcinoma (SCC) characterized by an exophytic, warty, slowly growing neoplasm with invading margins.[2,8]

2.8.1. Clinical features

Hoarseness is the most common presenting symptom; other symptoms include airway obstruction, weight loss, dysphagia, and throat pain. Enlarged lymph nodes are common and reactive rather than neoplastic (Fig. 14).[2,8]

2.8.2. Histopathology

VC consists of thickened club-shaped papillae and blunt intrastromal invaginations of well-differentiated squamous epithelium with marked keratinization and thin fibrovascular cores. The squamous epithelium lacks cytologic criteria of malignancy, and by morphometry, the cells are larger than those seen in SCC. Mitoses are rare, and observed in the basal layers (Fig. 15).[2,8]

http://dx.doi.org/10.5772/54646

Figure 14. Verrucous carcinoma wart-like appearance.

Figure 15. Verrucous carcinoma. A large lesion with abundant keratosis arranged in "church-spire" configuration. There is a broad, pushing border of infiltration.

2.8.3. Treatment and prognosis

Patients with VC may be treated by excision (by laser or surgery), or by radiotherapy. Although surgery is more effective, radiotherapy is an acceptable alternative for patients who are poor surgical candidates.

3. Malignant soft tissue tumors

Malignant soft tissue tumors included here are Fibrosarcoma, Malignant fibrous histocytoma, Angiosarcoma, Rhabdomyosarcoma, Leiomyosarcoma, Kaposi sarcoma, Liposarcoma.

3.1. Fibrosarcoma

3.1.1. Clinical features

Presenting complaints are typically related to a nasal mass, obstruction or epistaxis, nasal discharge, pain or swelling in the facial region, or sensory changes involving the regional nerves. Radiographic studies typically documented a nasal or paranasal sinus mass with some associated bone erosion [12-14] This is also seen in the jaws.

3.1.2. Histopathologic features

Unlike the fibromatoses, fibrosarcomas are highly cellular proliferations. The spindle cells are often oriented in well-formed fascicle that frequently intersect at approximately 90 degree angles, creating a herringbone" pattern. Nuclear pleomorphism is usually not striking, but mitotic figures are often abundant, even in well-differentiated forms of the tumor. In the head and neck region, most fibrosarcomas are well-differentiated, low-grade neoplasms (Fig. 16).[1,8]

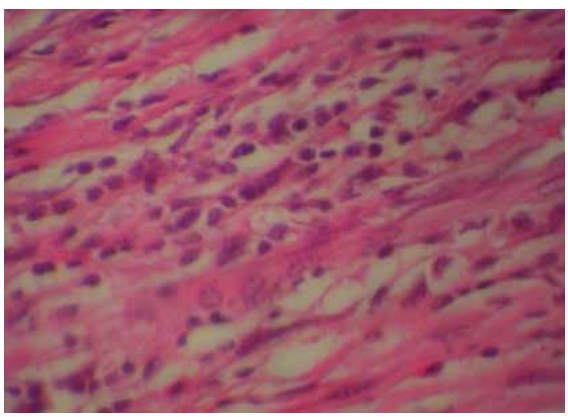

Figure 16. Low-grade fibrosarcoma consists of interlacing fascicles of spindle cells infiltrating around seromucinous glands.

3.1.3. Immunohistochemistry

The immunohistochemical reactivity of fibrosarcoma does not differ from that of aggressive fibromatosis. The neoplastic cells are often strongly reactive for vimentin and weakly reactive

http://dx.doi.org/10.5772/54646

for actin. Negativity for epithelial markers (cytokeratin epithelial membrane antigen) and 8-100 protein is helpful in excluding differential diagnosis.[2,8]

3.1.4. Treatment and prognosis

Optimal treatment for aggressive fibromatosis is wide surgical resection. Unfortunately, this is often not an option in the head and neck region. Accordingly, the behavior in this location is more aggressive than in areas of easy resectability. In the head and neck, recurrence rates approach 60 to 70 percent excluding oral and paraoral lesions which are more amenable to surgery and have a recurrence rate of approximately 25 %. [2,8]

3.2. Malignant fibrous histiocytoma

3.2.1. Clinical features

Patients may have nasal obstruction, often associated with epistaxis while pain, sinusitis, nasal discharge, swelling, anosmia, and proptosis are less common. Malignant fibrous histiocytoma (MFH) is currently used as a diagnosis of exclusion for sarcomas. Only 3% of MFH occur in the head and neck, with 30% of these arising in the sinonasal area.[2,8]

3.2.2. Histopathology

Sinonasal MFH are generally infiltrative and ulcerative, but can occasionally be circumscribed. Pleomorphic MFH, the most frequent morphologic subtype of MFH in the sinonasal tract, is characterized by spindle to pleomorphic cells in a storiform growth pattern, with easily identified mitotic figures including atypical forms, and necrosis. The cells are fusiform with, indistinct cytoplasm. Tumoral giant cells with multiple nuclei may be found (Fig. 17).[1,2,8]

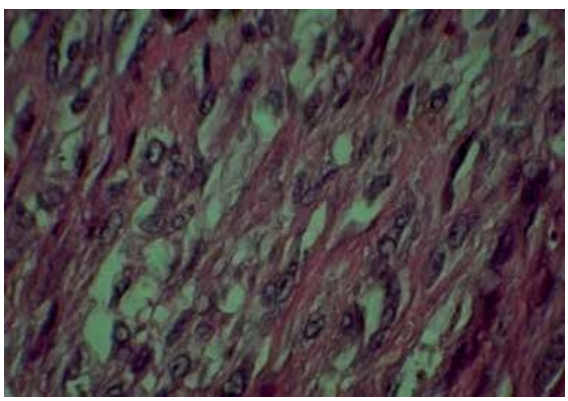

Figure 17. Malignant fibrous histocytoma showing spindle-shaped cells with storiform pattern.

3.2.3. Immunohistochemistry

MFH is usually positive for vimentin and focally for actins. Importantly, MFH is a diagnosis of exclusion and is generally negative for desmin, skeletal muscle specific markers, S100 protein, HMB-45, epithelial markers and lymphoid markers.[2,8]

3.2.4. Treatment and prognosis

Compared with other anatomical sites, MFHs of the head and neck generally have a slightly lower rate of recurrence and metastases.[15]

3.3. Angiosarcoma

Angiosarcoma is a malignant neoplasm of vascular phenotype whose constituent tumor cells have endothelial features.

3.3.1. Clinical features

Presenting symptoms include swelling, pain, epistaxis, deviation or swelling of tonsils, nasal obstruction, and sinusitis. [16,17]

3.3.2. Histopathology

Most sinonasal angiosarcomas are histologically low-grade. They infiltrate the adjacent tissues and bone, accompanied by necrosis and hemorrhage. They are comprised of tortuous anastomosing vascular channels that dissect the stroma, capillary sized vessels and cavernous vascular spaces. The lining endothelial cells range from flat to plump spindly to epithelioid, and often form papillary tufts (Fig. 18). [1- 8]

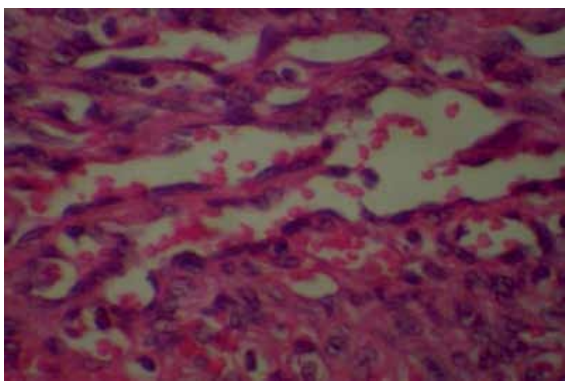

Figure 18. Angiosarcoma shows large vessel like spaces partially lined by enlarged, hyperchromatic endothelial cells.

http://dx.doi.org/10.5772/54646

3.3.3. Immunohistochemistry

Angiosarcomas are immunoreactive for CD34, CD31, Factor VIII R-Ag and vimentin, and focally keratin (especially the epithelioid variant) and actin [18]

3.3.4. Treatment and prognosis

Patients are usually treated by surgical resection with radiation and/or chemotherapy. Recurrences are common (50%), likely due to incomplete excision or possible multifocality. Metastasis is uncommon, and the predilection sites are the lung, liver, spleen, and bone marrow. [1,2,4,5,7,8,19]

3.4. Rhabdomyosarcoma

3.4.1. Clinical and radiographic features

Rhabdomyosarcoma primarily occurs during the first decade of life but also may occur in teenagers and young adults. It is rare in people older than 45 years, and approximately 60% of all cases occur in males. Embryonal rhabdomyosarcomas are most common in the first 10 years of life and account for about 60% of all cases. Alveolar rhabdomyosarcomas occur most often in persons between 10 and 25 years of age: they account for 20% to 30% of all tumors. Pleomorphic rhabdomyosarcomas represent less than 5% of all cases and show a peak prevalence in patients older than 40 years of age. The tumor is most often a painless, infiltrative mass that may grow rapidly. In the head and neck region the face and orbit are the most frequent locations followed by the nasal cavity. The palate is the most frequent intraoral site, and some lesions may appear to arise in the maxillary sinus and break through into the oral cavity[1- 8]

3.4.2. Histopathologic features

Several microscopic patterns of pediatric rhabdomyosarcoma are recognized including: Embryonal rhabdomyosarcoma, Non Otherwise Specified, Botryoid, Spindle, Alveolar rhabdomyosarcoma, Undifferentiated sarcoma and Anaplastic rhabdomyosarcoma. The anaplastic cells vary according to type (Fig.19).

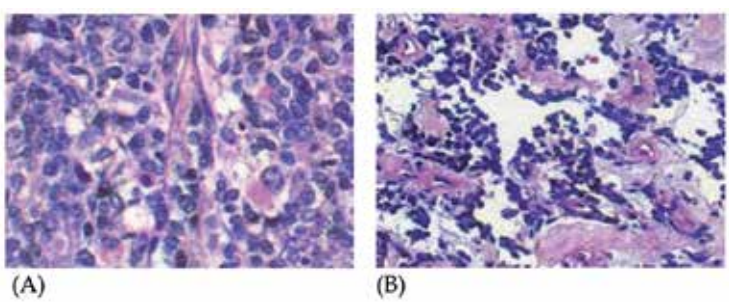

Figure 19. A. Embryonal rhabdomyosarcoma. B. Alveolar subtype of rhabdomyosarcoma.

3.4.3. Immunohistochemistry

There is immunoreactivity for desmin, muscle specific actin, myoglobin, fast myosin, nuclear MyoD1 and nuclear myogenin (skeletal muscle myogenin myf4). CD99 may be positive in 16% of cases [20,21].

3.4.4. Treatment and prognosis

Before 1960 the prognosis for a patient with rhabdomyosarcoma was extremely poor, with more than 90% of patients dying. With the advent of multimodal therapy during the past several decades, the prognosis has improved dramatically. Treatment typically consists of local surgical excision followed by multiagent chemotherapy (vincristine actinomycin D. and cyclophosphamide). Postoperative radiation therapy also is used, except for localized tumors that have been completely resected at initial surgery. The 5-year survival rate for embryonal rhabdomyo sarcoma not otherwise specified [NOS]) is around 66%, although the figures for botryoid (95%) and spindle cell variants (88%) are much better. The 5-year survival rate for alveolar rhabdomyosarcoma is only 53%. and survival drops to slightly less than 50% for anaplastic rhabdomyosarcoma and undifferentiated sarcomas. [1-8]

3.5. Leiomyosarcoma

Leiomyosarcoma is a malignant tumor of smooth muscle phenotype.

3.5.1. Clinical features

Patients may have swelling, pain and the duration of symptoms is usually long. There is usually no lymphadenopathy. Plain radiographs show opacification of the nasal cavity or sinus(es), often suggesting sinusitis Only a small number of sinonasal leiomyosarcomas have been reported, accounting for <1% of all non-epithelial tumors. They occur in all ages, with a peak in the 6th decade (mean, 53 years) without a gender difference. [2,22]

3.5.2. Histopathology

Leiomyosarcomas are infiltrative neoplasms accompanied by surface ulceration Bone or cartilage invasion is more frequent than surface or seromucinous gland invasion. Leiomyosarcomas are composed of right-angle intersecting bundles of spindle cells. Pallisading storiform and "haemangiopericytoma -like" patterns can occur. The tumors are hypercellular, but coagulative tumor necrosis and hemorrhage can create a hypocellular appearance. The tumor cells have elongated, vesicular to hyperchromatic, lobulated or indented nuclei with blunt ends ("cigar shaped"). The cytoplasm is fibrillary and eosinophilic, with frequent perinuclear vacuolation. Mitoses, both typical and atypical, are present to a variable degree. [2,22] Histochemistry and immunoprofile intracytoplasmic glycogen can be demonstrated with a PAS stain. Masson trichrome stain demonstrates red, longitudinally oriented parallel fibrils within the cytoplasm. Tumor cells are diffusely and strongly immunoreactive for vimentin, actin(smooth muscle or muscle- specific), desmin and h-caldesmon.There is

http://dx.doi.org/10.5772/54646

generally no reactivity with keratin CD34, CD117, S-100 protein or HMB-45 The Ki-67 index is usually >15% (Fig. 20).[2,3,22]

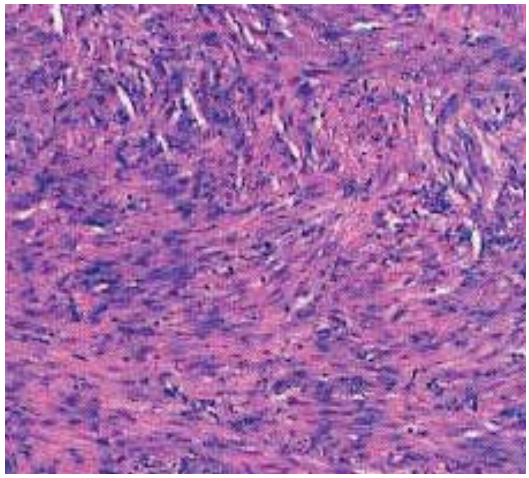

Figure 20. Leiomyosarcoma fascicles of spindle-shaped cells with conspicuous eosinophilic cytoplasm.

3.5.3. Treatment and prognosis

About half of the reported cases develop local recurrence, often within a year and nearly 1/3 of these patients subsequently develop metastasis (mostly to the lungs and liver). Complete surgical excision is difficult to achieve, and radiation and chemotherapy are used with variable success. Poor prognostic factors include involvement of more than one contiguous site, large tumor size (>5 cm), high mitotic count (>20/10 high power field), tumor necrosis, and tumor stage. [2,22,23]

3.6. Kaposi sarcoma

Kaposi sarcoma (KS) is a locally aggressive tumor that typically presents with cutaneous lesions in the form of multiple patches, plaques or nodules but may also involve mucosal sites, lymph nodes and visceral organs. The disease is uniformly associated with HIV and human herpes virus 8 (HHV-8) infection.[2,8]

3.6.1. Clinical features

KS is characterized by the appearance of purplish, reddish blue or dark brown macules, plaques and nodules that may ulcerate. They are particularly frequent in distal extremities and may be accompanied by lymphedema. Early oral KS is represented by solitary or multiple red or bluish flat lesions, while the later stage is characterized by a nodular, sometimes massive appearance with or without secondary ulceration (Fig. 21). [2,8]

Figure 21. Kaposi sarcoma of the palate.

3.6.2. Histopathology

KS lesions of the skin or the mucosa are uncharacteristic and present with subtle vascular proliferation; vascular spaces are increased in number, of irregular shape, and may dissect collagen fibres in the superficial corium. They often run parallel to the epithelium. The vascular proliferation is often perivascular and periadnexal. Endothelial cells lining the spaces are flattened or more oval, with little atypia. Preexisting blood vessels may protrude into the lumen of new vessels. Admixed are sparse lymphocytes and plasma cells; frequently, extravasated erythrocytes and deposits of hemosiderin surround the vascular structures (Fig. 22). [2,8]

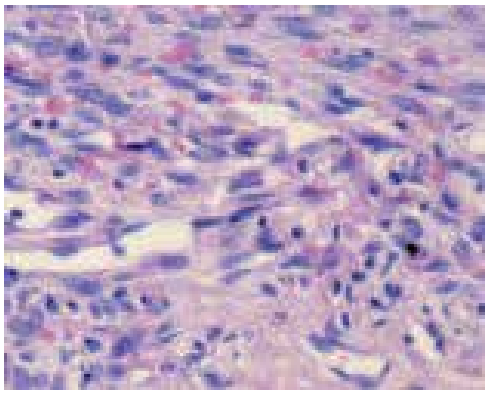

Figure 22. Vascular slits and sparsely distributed lymphocytes of KS.

3.6.3. Immunohistochemistry

The lining cells of clearly developed vascular structures are usually positive for vascular markers, while the spindle cells consistently show positive reaction for CD34 and commonly

http://dx.doi.org/10.5772/54646

for CD31 but are factor VIII negative. All cases, irrespective of epidemiologic subgroup, are HHV-8 positive. The new marker FLI1, a nuclear transcription factor, appears to be expressed in almost 100% of different vascular tumors, including KS [24]

3.6.4. Treatment and prognosis

The evolution of disease depends on the epidemiological-clinical type of KS and on its clinical extent. It is also modified by treatment that includes surgery, radio and chemotherapy. [25]

3.7. Liposarcoma

3.7.1. Clinical features

Liposarcomas are primarily seen in adults, with peak prevalence between the ages of 40 and 60. The tumor is typically a soft, slow-growing, ill-defined mass that may appear normal in color or yellow. Pain or tenderness is uncommon: when present, it is usually a late feature. The neck is the most common site for liposarcomas of the head and neck region. The most frequent oral locations are the tongue and cheek.[1,8]

3.7.2. Histopathologic features

Most liposarcomas can be divided into three major categories: 1. Well-differentiated liposarcoma/atypical lipomatous tumor, 2. Myxoid/round cell liposarcoma, 3. Pleomorphic liposarcoma(Fig.23). [1,8]

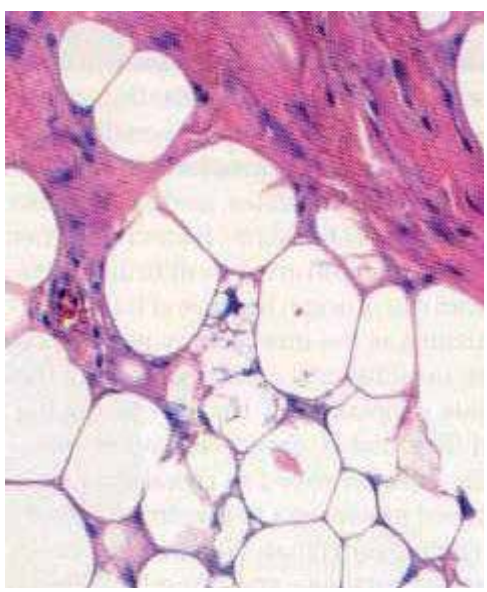

Figure 23. Liposarcoma showing lipoblasts interspersed between mature appearing adipocytes.

3.7.3. Treatment and prognosis

Radical excision is the treatment of choice for most liposarcomas throughout the body. In spite of this, around 50% of all tumors recur. The overall 5-year survival rate ranges from 59% to 70%. There is a 10-year survival rate of approximately 50%[1,8]

4. Benign and malignant odogentic tumors

Benign and malignant odogentic tumors included here are the Calcifying epithelial odontogenic tumor (CEOT), Ameloblastic fibroma (AF), Cementoblastoma, Odontoma, Odontogenic myxoma, Ameloblastoma, Ameloblastic carcinoma and Adenomatoid odontogenic tumor.

4.1. Calcifying epithelial odontogenic tumor (CEOT)

CEOT accounts for approximately 1% of all odontogenic tumors occurring in patients between 20 and 60 years of age, with a mean age of 40 years. There is no gender predilection. Most cases are intraosseous, approximately 6% arise in extraosseous locations. Intraosseous tumors affect the mandible more often than the maxilla with a ratio of 2:1.[2,8]

4.1.1. Clinical and radiographic features

The tumor presents as an asymptomatic slow-growing expansile mass of the jaw. Peripheral gingival lesions are firm painless masses. Radiographically, most CEOTs present as mixed radiolucent-radiopaque lesions, but they may show considerable variation. They may be unilocular or multilocular. In about half of the cases, an unerupted tooth, most often a mandibular third molar, is associated with the lesion. CT and MRI provide useful information in the diagnosis and treatment of CEOT [26]

4.1.2. Histopathology

The tumor consists of a fibrous stroma with islands and sheets of polyhedral epithelial cells with abundant eosinophilic cytoplasm, sharply defined cell borders and well-developed intercellular bridges. Their nuclei are frequently pleomorphic, with giant nuclei being common. Mitotic figures are rarely encountered unless malignant transformation occurs (Fig. 24).[27]

4.1.3. Treatment and prognosis

The CEOT is a locally invasive tumor. Small tumors may be enucleated, but larger ones require local resection. An overall recurrence rate of about 14% has been noted.A relatively higher recurrence rate of 22% has been noted for the clear cell variant. [28,29]

http://dx.doi.org/10.5772/54646

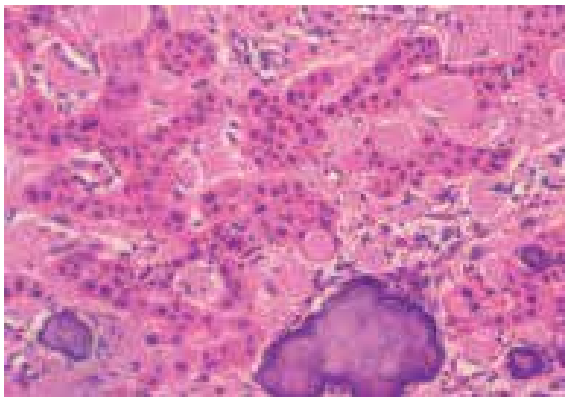

Figure 24. CEOT depicting fibrous stroma with islands and sheets of polyhedral epithelial cells with abundant eosinophilic cytoplasm.

4.2. Ameloblastic Fibroma (AF)

4.2.1. Clinical and radiographic features

Most cases of AF present as a painless swelling or are discovered due to disturbances of tooth eruption. Radiographically, the tumor presents as a well-demarcated radiolucency, often in connection with a malpositioned tooth (Fig.25).[30]

Figure 25. AF presenting as well demarcated osteolysis with sclerotic rim.

4.2.1. Histopathology

The epithelial component of AF consists of branching and anastomosing epithelial strands that form knots of varying size. These have a peripheral rim of columnar cells similar to the inner enamel epithelium that embraces a loosely arranged spindle-shaped epithelium identical to stellate reticulum.The epithelial component resembles ameloblastoma. The stromal compo-

nent however differs in that it is an immature cell-rich myxoid tissue with an embryonic appearance. Some AFs may contain granular cells (Fig.26). [30]

Figure 26. Ameloblastic fibroma with strands and islands of odontogenic epithelium showing peripheral palisading, embedded in a cell-rich ectomesenchyme resembling the dental papilla.

4.2.2. Treatment and prognosis

Treatment consists of enucleation and curettage. Recurrence may occur but this does not justify initial aggressive treatment.[30] Rarely, AF may progress to malignancy (ameloblastic fibrosarcoma).

4.3. Cementoblastoma

Cementoblastoma is a rare benign neoplasm which forms cementum-like material attached to the tooth root.

4.3.1. Clinical features

Cementoblastomas are rare, accounting for only about 4% of cementum-containing lesions. There is no significant gender predilection and lesions are discovered in the 2nd-3rd decades. Lesions present with varied levels of pain and a swelling of the buccal or lingual aspect of the alveolar ridge as a result of bone expansion. The involved tooth usually remains vital. There is a predilection for the mandibular, particularly the mandibular permanent first molar.[5,8]

4.3.2. Radiologic features

The tumor is well-defined, radiopaque or mixed density, round mass, intimately associated with the tooth root. Additionally, a thin radiolucent rim surrounds the tumor, representing the periodontal ligament. Root resorption is common. Irregular soft tissue may surround the lesion (Fig. 27). [5,8]

http://dx.doi.org/10.5772/54646

Figure 27. Radiograph of a radiodense calcified mass attached to the root of the mandibular first molar is characteristic for a cementoblastoma.

4.3.3. Histopathologic features

Cementoblastoma is composed of a dense mass of cementum in a loose fibrovascular stroma. Lesions usually show prominent cementoblastic rimming and may demonstrate a characteristic basophilic appearance and reversal lines of the cementum. Multinucleated osteoclastic giant cells are usually present. The periphery may have radiating columns of unmineralized tissue (Fig. 28). [5,8]

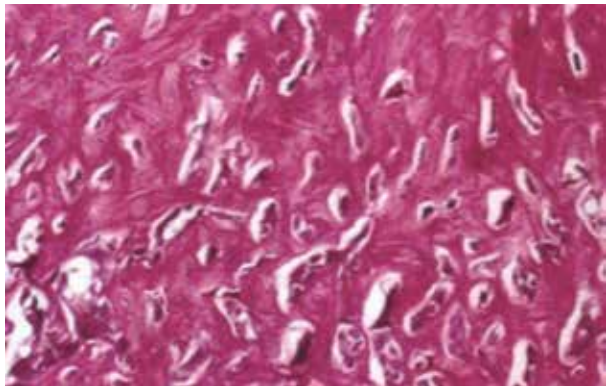

Figure 28. Cementoblastoma. Mineralized tissue containing numerous plump cementoblasts.

4.3.4. Treatment and prognosis

Treatment requires removal of the mass and associated tooth, usually a surgical extraction. Recurrences do not occur, unless the lesion is incompletely removed.[1,8]

4.4. Odontoma (complex and compound)

Odontoma is the most common odontogenic tumor, although it may best be classified as a hamartoma composed of enamel, dentin, pulpal tissue, and cementum. Academically, odontomas are subclassified into two types, although management is identical: *compound* when composed of rudimentary teeth-like structures and *complex* when composed of haphazardly arranged tooth structure. [5,8]

4.4.1. Clinical features

Odontoma occurs more frequently than all other odontogenic tumors combined. Odontomas show no gender predilection. Odontomas develop most commonly in the first two decades, the time normal teeth are developing and erupting. Most odontomas are asymptomatic, found incidentally on routine dental radiographs, while larger lesions may interfere with eruption of normal adjacent teeth, prompting radiographic investigation. [5,8]

4.4.2. Radiologic features

Odontomas present as a radiodense calcified mass surrounded by a thin radiolucent rim. Compound odontomas will appear like small, malformed teeth while complex odontomas present as radiodense masses of calcified tooth material, slightly more difficult to diagnose[5,8]

4.4.3. Histopathology

Sections of immature, developing compound odontomas show several dysmorphic tooth germs in a loosely textured connective tissue with cords and islands of odontogenic epithelium. Much of the enamel matrix is preserved in spite of decalcification The distinction between complex and compound odontoma is mainly based on the presence of tooth- like structures in compound odontomas (Fig. 29). [5,8]

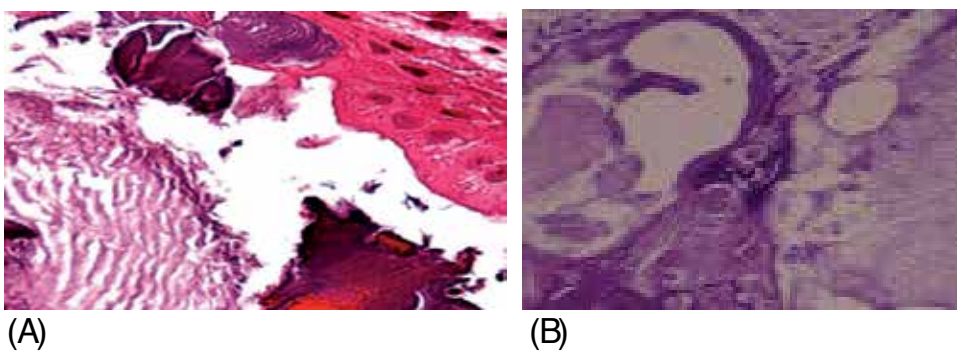

Figure 29. A. Compound odontoma. Enamel matrix and odontogenic epithelium in an odontoma. B. Odontoma, complex type. Enamel, dentin, and cementum-like tissue are arranged in a haphazard pattern.

http://dx.doi.org/10.5772/54646

4.5. Odontogenic Myxoma (OM) /Myxofibroma

4.5.1. Clinical and radiographic features

Small OMs are asymptomatic. Large OMs cause painless expansion. Cortical perforation may occur when large. Unilateral sinonasal obliteration may mimic nasal polyposis. Radiographically, OM appears as a unilocular or multilocular radiolucency, sometimes showing a fine "soap bubble" or"honeycomb" appearance occasionally with fine trabeculations. The borders of the tumor are usually well-defined and corticated but can be poorly defined or diffuse. Root displacement occurs, as does root resorption. Larger OMs may present with periosteal reactions. CT may reveal the fine bony septa and allows for anatomic deliniation.[1,2,31]

4.5.2. Histopathology

OM is characterized by randomly oriented stellate, spindle-shaped and round cells with long, fine, anastomosing pale or slightly eosinophilic cytoplasmic processes extending from the centrally placed nucleus. Cells are evenly dispersed in an abundant mucoid or myxoid stroma that contains only a few fine collagen fibres. Binucleated cells, mild pleomorphism and mitotic figures may occur. Rests of odontogenic epithelium are not obvious in most lesions and are not required for establishing final diagnosis. Some OMs may permeate into the marrow spaces in a pseudo-malignant pattern. Some OMs have a tendency to produce collagen fibres and are designated myxofibroma. There is no evidence that these more collagenous variants behave differently. Histochemical studies show that the ground substance is rich in acid mucopolysaccharides, primarily hyaluronic acid and, to a lesser degree, chondroitin sulphate (Fig.30). [1,2,32]

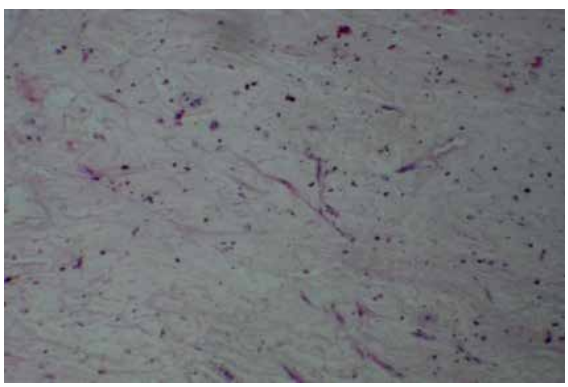

Figure 30. Odontogenic myxoma with randomly oriented stellate, spindle-shaped and round cells with long cytoplasmic processes.

4.5.3. Treatment and prognosis

The tendency of OM to permeate into marrow spaces makes effective enucleation and curettage difficult. Small lesions have been successfully treated in this way but larger lesions may require complete excision with free margins. Recurrence rates from various studies average about 25% but in spite of this, the prognosis is good. Recurrence usually follows incomplete removal within 2 years but may also occur later. Death may ensue due to cranial base extension.[1-3,33]

4.6. Ameloblastoma

4.6.1. Clinical and radiographic features

Ameloblastoma occurs exclusively in the jaws, rarely in the sinonasal cavities. Most maxillary cases occur in the posterior region. Small lesions may be asymptomatic swellings of the jaws. Pain or paraesthesia is rare. They may be unilocular or multilocular radiolucencies resembling cysts and they may reveal scalloped borders [1,2,34]. The most typical radiographic feature is that of a multilocular radiolucent lesion. The lesion is often described as having a "soap bubble" appearance (when the radiolucent loculations are large) or as being "honeycombed"(when the loculations are small). Buccal and lingual cortical expansion is frequently present. Resorption of the roots of teeth adjacent to the tumor is common. In many cases an unerupted tooth, most often a mandibular third molar is associated with the radiolucent defect. Solid ameloblastomas may radiographically appear as unilocular radiolucent defects, which may resemble almost any type of cystic lesion (Fig. 31). [1-5]

Figure 31. Ameloblastoma involved maxillary sinus.

4.6.2. Histopathology

The follicular and plexiform patterns are the most common. Less common histopathologic patterns include the acanthomatous, granular cell, desmoplastic, and basal cell types (Fig. 32).[1-3, 8]

http://dx.doi.org/10.5772/54646

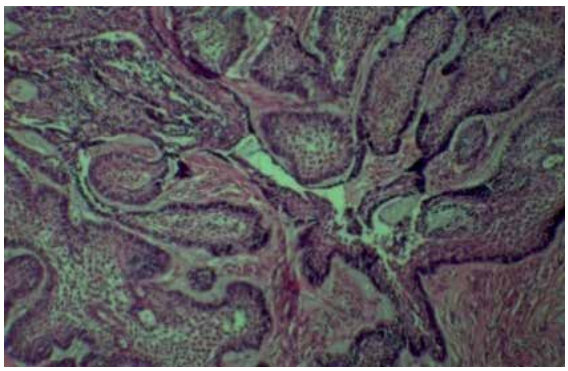

Figure 32. Follicular ameloblastoma

4.6.3. Treatment and prognosis

Patients with conventional solid or multicystic intraosseous ameloblastomas have been treated by a variety of means. These range from simple enucleation and curettage to *en bloc* resection. Other surgeons advocate that the margin of the resection should be at least 1.0 to 1.5 cm past the radiographic limits of the tumor. Ameloblastomas of the posterior maxilla are particularly dangerous because of the difficulty of obtaining an adequate surgical margin around the tumor. Marginal resection is the most widely used treatment but recurrence rates of up to 15% have been reported after marginal or block resection.[1,2,8]

4.7. Ameloblastic carcinomas

4.7.1. Clinical and radiographic features

Only 19 cases have been reported to occur in the maxilla. Males and females are equally affected. The posterior segments of the jaws represent the most common site. Generally, ill defined or irregularly marginated radiolucencies are characteristic. Cortical expansion often with perforation, may be present as well as infiltration into adjacent structures (Fig. 33).[2,35]

4.7.2. Histopathology

Ameloblastic carcinoma is characterized by malignant cytologic features in combination with the overall histological pattern of an ameloblastoma. A tall columnar cellular morphology with pleomorphism mitotic activity, focal necrosis, perineural invasion and nuclear hyperchromatism may be present. Peripheral palisading and so-called reverse or inverted nuclear polarity will be present. A stellate reticulum structure will usually be seen. Cystic spaces may be present that are lined by epithelium Atypical cells form nests and broad ribbons which may branch and anastomose with focal areas of subtle necrosis to more obvious central, comedo necrosis like areas (Fig. 34).[1,2,36]

Figure 33. Ameloblastic carcinoma in maxillary sinus

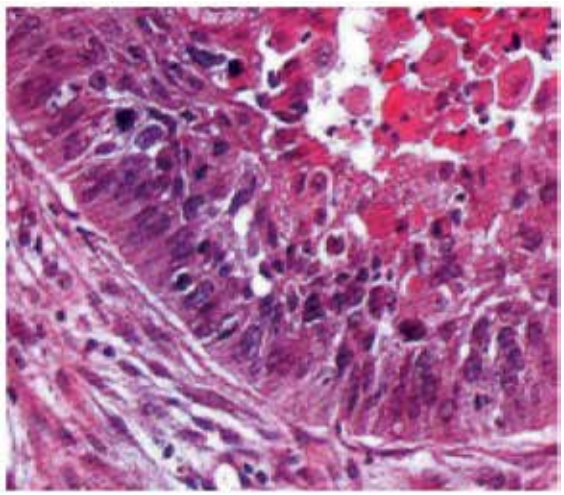

Figure 34. Ameloblastic Carcinoma. A tall columnar cellular morphology with pleomorphism mitotic activity

4.7.3. Treatment and prognosis

Maxillary ameloblastic carcinomas demonstrate tumor-related deaths or pulmonary metastases in over one-third of cases. Mandibular counterparts behave in a similar manner, where local recurrences are likely to precede metastases. [1,2,27,37]

4.8. Adenomatoid odontogenic tumor

4.8.1. Clinical and radiographic features

Intraosseous AOTs may be found in association with unerupted permanent teeth (follicular type), in particular the four canines that account for 60% with the maxillary canines alone accounting for 40%. Most AOTs are asymptomatic. When growth of the intraosseous variants

http://dx.doi.org/10.5772/54646

causes cortical expansion, it may present as a palpable bony-hard swelling with or without slight pain. The intraosseous AOTs may cause displacement of neighbouring teeth. The peripheral variant presents as a fibroma or an epulis-like lesion of the gingiva Radiographically, the intraosseous, follicular AOT, shows a well-defined, unilocular radiolucency around the crown and often part of the root of an unerupted permanent tooth, mimicking a dentigerous cyst. If not associated with an unerupted tooth (extrafollicular type), AOT presents as a unilocular radiolucent lesion. In two thirds of the intraosseous variant, the radiolucency shows discrete radiopaque foci. The peripheral variant may disclose erosion (saucerization) of the alveolar bone crest.(Fig.35).[1,2,8]

Figure 35. AOT involving the maxillary sinus.

4.8.2. Histopathologic features

Microscopically, the tumor is composed of spindle shaped epithelial cells that form sheets, strands, or whorled masses of cells in a scant fibrous stroma. The epithelial cells may form rosette-like structures about a central space, which may be empty or contain small amounts of eosinophilic material. This material may stain for amyloid. The tubular or ductlike structures, which are the characteristic feature of the adenomatoid odontogenic tumor, may be prominent, scanty, or even absent in a given lesion. These consist of a central space surrounded by a layer of columnar or cuboidal epithelial cells. The nuclei of these cells tend to be polarized away from the central space. The mechanism of formation

of these tubular structures is not entirely clear but is likely the result of the secretory activity of the tumor cells, which appear to be preameloblasts. In any event, these structures are not true ducts, and no glandular elements are present. Small foci of calcification may also be scattered throughout the tumor (Fig. 36).[1,2]

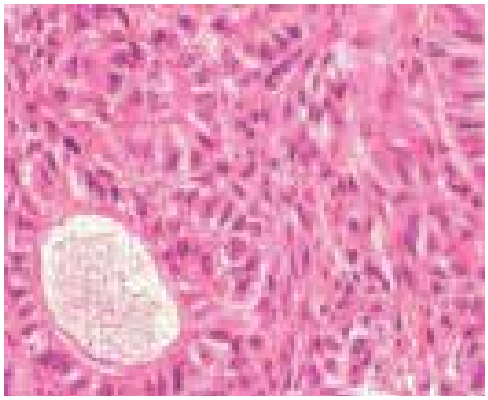

Figure 36. AOT. Solid, cell-rich area of minimal stromal connective tissue showing duct-like structures.

4.8.3. Treatment and prognosis

The adenomatoid odontogenic tumor is completely benign: because of its capsule, it enucleates easily from the bone. Aggressive behavior has not been documented, and recurrence after enucleation seldom, if ever, occurs. [1-8]

5. Lesions of hematologic origin

These include: Hodgkins, Burkitt's lymphoma, Plasmacytoma (multiple myeloma) and Non-Hodgkins lymphoma.

5.1. Hodgkins lymphoma

5.1.1. Clinical features

Hodgkin's lymphoma almost always begins in the lymph nodes, and any lymph node group is susceptible. Oral involvement has been reported, but it is rare. In about 30% of patients with Hodgkin's disease, other systemic signs and symptoms may be present, such as weight loss, fever, night sweats, and generalized pruritus (itching).[1,8]

5.1.2. Histopathologic features

Hodgkin's lymphoma is recognized to comprise two main forms. [1] Nodular Ivmphocyte-predominant Hodgkin's lymphoma and [2] Classic Hodgkin's lymphoma, the latter of which

http://dx.doi.org/10.5772/54646

is divided into five subtypes. Although this group of diseases has certain features in common, current immunohistochemical and molecular biologic techniques have allowed distinctions to be made among the various types. The common features include effacement of the normal nodal architecture by a diffuse, often mixed, infiltrate of inflammatory cells that is interspersed with large, atypical neoplastic lymphoid cells. In the case of classical Hodgkin's lymphoma, this atypical cell is known as a Reed- Sternberg cell (Fig. 37). [1,8]

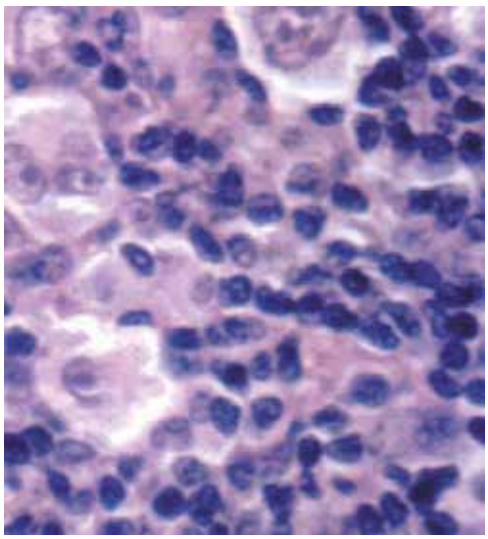

Figure 37. Hodgkin's lymphoma. This high-power photomicrograph shows the characteristic Reed-Sternberg cell.

5.1.3. Treatment and prognosis

The treatment of Hodgkin's lymphoma depends on the stage of involvement. Patients who had limited disease often were managed by local radiation therapy alone. Recent treatment trends, however, combine less extensive radiotherapy fields with milder multiagent chemotherapy regimens to maximize disease control and minimize long-term complications of therapy. [1,8]

5.2. Burkitt's lymphoma

Burkitt's lymphoma is a malignancy of B-lymphocyte origin that represents an undifferentiated lymphoma[1,8]

5.2.1. Clinical and radiographic features

As many as 50% to 70% of the cases of endemic Burkitt's lymphoma present in the jaws. The malignancy usually affects children (peak prevalence, about 7 years of age) who live in Central Africa, and a male predilection is usually reported. The posterior segments of the jaws are more commonly affected, and the maxilla is involved more commonly than the mandible (a

2:1 ratio). Sometimes all four quadrants of the jaws show tumor involvement. The tendency for jaw involvement seems to be age related; nearly 90% of 3 year-old patients have jaw lesions, in contrast to only 25% of patients older than age 15. Sporadic Burkitt's lymphoma tends to affect patients over a greater age range than is noted for the African tumor. Although the abdominal region is typically affected, jaw lesions have been reported in sporadic cases.[1,8] The growth of the tumor mass may produce facial swelling and proptosis. Pain, tenderness, and paresthesia are usually minimal, although marked tooth mobility may be present because of the aggressive destruction of the alveolar bone. Premature exfoliation of deciduous teeth and enlargement of the gingiva or alveolar process may also be seen. The radiographic features are consistent with a malignant process and include a radiolucent destruction of the bone with ragged, ill-defined margins. [1,8]

5.2.2. Histopathologic features

Burkitt's lymphoma histopathologically represents an undifferentiated, small, noncleaved B-cell lymphoma. The lesion has broad sheets of tumor cells that exhibit round nuclei with minimal cytoplasm. Each tumor nucleus often has several prominent nucleoli and numerous mitotic cells. Immunohistochemical studies using markers identify proliferating cells (e.g. Ki-67) typically show that almost 100% of the tumor cells are in the process of replicating. On viewing the lesion on low-power magnification, a classic "starry-sky" pattern is seen (Fig. 38) [1,8]

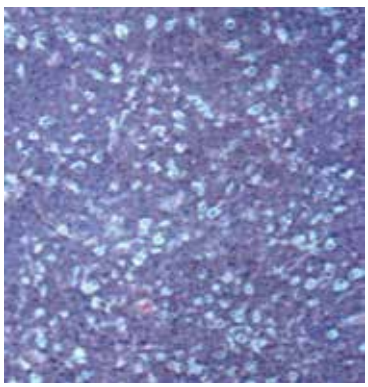

Figure 38. Burkitt's lymphoma "starry-sky" appearance, a pattern caused by interspersed histiocytic cells with abundant cytoplasm

5.2.3. Treatment and prognosis

Burkitt's lymphoma is an aggressive malignancy that usually results in the death of the patient within 4 to 6 months after diagnosis if it is not treated. Treatment generally consists of an intensive chemotherapeutic regimen, which emphasizes the use of high doses of cyclophosphamide. More than 90% of the patients respond to this treatment. The prognosis for Burkitt's lymphoma in the past was poor, with a median survival time of only months.

http://dx.doi.org/10.5772/54646

5.3. Plasmacytoma

The plasmacytoma is a unifocal, monoclonal, neoplastic proliferation of plasma cells that usually arises within bone. [1- 8]

5.3.1. Clinical and radiographic features

The plasmacytoma usually is detected in an adult male, with an average age at diagnosis of 55 years. The male-to-female ratio is 3:1. Most of the lesions present centrally within a single bone.

Approximately 80% to 90% of extramedullary plasmacytomas develop in the head and neck region, and such lesions have been reported in the tonsils, nasopharynx, and paranasal sinuses. [1-8]

5.3.2. Histopathologic features

The histopathologic features of the plasmacytoma are identical to those of multiple myeloma. Sheets of plasma cells show varying degrees of differentiation. Immunohistochemical studies demonstrate that these plasma cells are monoclonal. As many as 25% to 50% of these patients also show a monoclonal gammopathy on evaluation by serum protein immunoelectrophoresis (Fig. 39).[1-8]

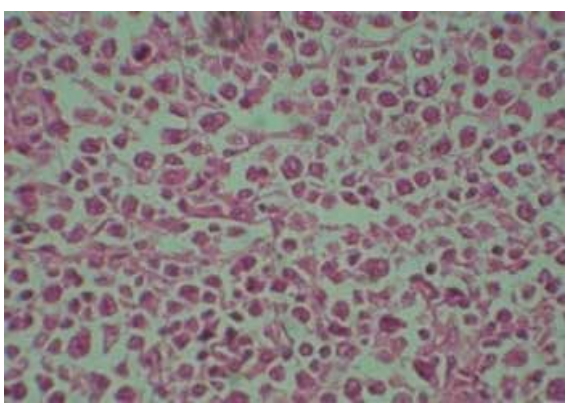

Figure 39. Plasmacytoma. Sheets of monomorphous-appearing plasma cells

5.3.3. Immunohistochemistry

Immunohistochemically, the plasma cells express cytoplasmic immunoglobulin with light chain restriction. CD20 is negative in most cases, and some cases express CD79a. PAX-5 is negative, while Oct-2 and Bob.1 are frequently positive. There is usually expression of CD38, CD138 and VS38, markers characteristically positive in but not specific for plasma cells.Epithelial membrane antigen is commonly positive, and rare cases can show cytokeratin immu-

noreactivity (often with a dot pattern). Leukocyte common antigen, CD31 or CD56 is sometimes positive. [1-8]

5.3.4. Treatment and prognosis

Plasmacytomas are usually treated with radiation therapy, and typically a dose of at least 4000 cGy is delivered to the tumor site. A few lesions have been surgically excised with good results, although this is not the preferred treatment in most instances. Unfortunately, when patients with plasmacytoma of bone are observed on a long-term basis, most will eventually develop multiple myeloma. [1-8]

5.4. Non-Hodgkin's lymphoma

5.4.1. Clinical and radiographic features

Lymphomas of the paranasal sinuses commonly show bony destruction and local extension to adjacent structures including the orbit, palate, nasal cavity, nasopharynx, and soft tissues in the cheek and infratemporal fossa. The maxillary sinus is the most commonly involved paranasal sinus. Patients may present with nasal obstruction, epistaxis, nasal discharge, pain and nasal swelling or facial swelling. Locally advanced cases can cause destruction of midline facial structures. The nasal septum or palate may be perforated. Extension to the orbits can lead to proptosis and visual disturbance. Regional lymph node involvement may occur in some patients. Occasional patients have systemic symptoms including fever and weight loss. Hemophagocytic syndrome with pancytopenia occurs at presentation in a minority of patients with extranodal NK/T cell lymphoma of nasal type. [1-8, 38]Lymphoma in patients with AIDS usually occurs in extranodal locations, with the CNS being the most common site. Oral lesions are seen in approximately 4% of patients with AIDS-related NHL and most frequently involve the gingiva, palate, tongue, tonsil, or maxillary sinus (Fig. 40). [1-8]

5.4.2. Histopathologic features

Non-hodgkins lymphoma consists of several subtypes: Diffuse small cleaved cell, Diffuse mixed small and large cell, Diffuse large cell, Diffuse large cell immunoblastic, Follicular large cell, Small noncleaved cell, Lymphoblastic, Follicular mixed small and large cell, Small lymphocytic and Follicular small cleaved cell variants.

5.4.3. Immunohistochemistry

The lymphoma most commonly exhibits an NK-cell immunophenotype of CD2+, surface CD3(Leu4)-, cytoplasmic CD3+, CD56+. CD43 and CD45RO are commonly positive, but other T-cell markers (including CD5) and NK-cell markers (CD16, CD57) are usually negative[1-8,39]

5.4.4. Treatment and prognosis

Radiotherapy and/or systemic chemotherapy is the treatment of choice for localized disease. Treatment of DLBCL follow protocols for similar tumors elsewhere in the body, as some series

http://dx.doi.org/10.5772/54646

Figure 40. Non-hodgkins lymphoma with destruction in the left maxillary sinus.

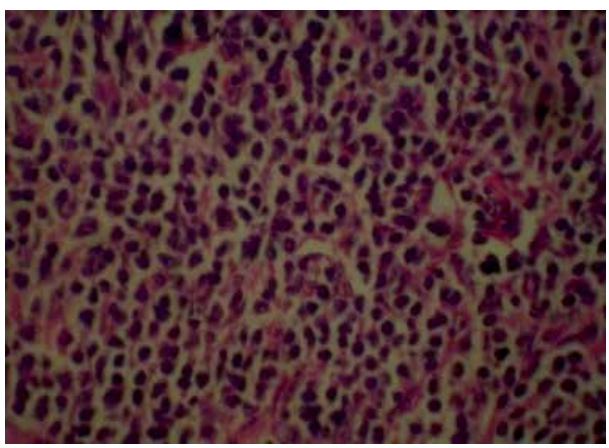

Figure 41. Non-Hodgkins lymphoma; Diffuse small cell lymphoma.

showed that chemotherapy might be beneficial. The overall survival for extranodal NK/T cell lymphoma of nasal-type is only 30-50%. In patients achieving complete remission, local relapse occurs in one-third to one-half of cases, and systemic failure is also common. Factors associated with a worse outcome include: Advanced stage, poor systemic status and severe disease.There is no conclusive evidence to suggest that the histological grading of NK/T cell lymphoma can predict the clinical outcome. Expression of cutaneous lymphocyte antigen (CLA) may be associated with a worse prognosis, but this finding has yet to be confirmed. [1-8]

6. Bone tumors

Cherubism, Paget's Disease, Osteoid osteoma, Osteoma, Juvenile ossifying fibroma, Fibrous dysplasia, Giant cell tumor (central and peripheral), Chondrocarcoma, Osteosarcoma and Ewing's sarcoma are common bone tumors discussed herein.

6.1. Cherubism

Cherubism is a rare, autosomal dominant inherited disease that causes bilateral swelling of at least the mandible but often also the maxilla. [1,5,8]

6.1.1. Clinical features

Males are affected more commonly than females and most patients present in early childhood. There is often a history of other afflicted family members. The resulting painless, symmetrical, facial deformity mimics the angelic faces of the cherubs portrayed in Renaissance and Baroque paintings, hence its name. Sometimes there is upward displacement of both eyes. The disease progression is self-limited, stabilizing at the end of puberty. Complications developing from the jaw disorder can result in poor dentition, impacted teeth, and malaligned teeth. [1,5,8]

6.1.2. Radiologic features

Radiographic findings are not pathognomonic, but the presence of bilateral, usually symmetrical involvement of the maxilla and mandible is certainly most suggested. The affected jaw areas show cortical expansion and attenuation (thinning) as well as a soap bubble-like multilocular radiolucency. Teeth and tooth germs may be displaced (Fig.42).[1,5,8]

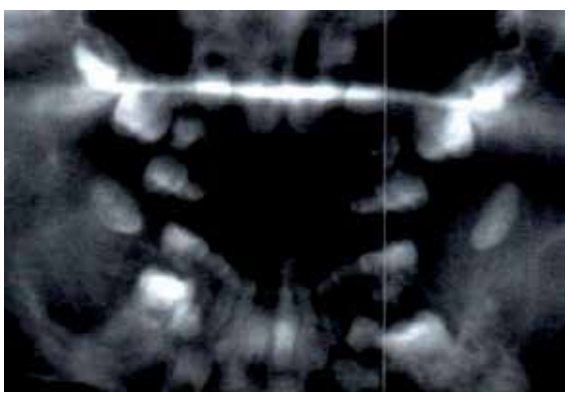

Figure 42. Bilateral soap bubble-like radiolucencies with displaced teeth and tooth germs in cherubism.

http://dx.doi.org/10.5772/54646

6.1.3. Histopathologic features

Cherubism shows multinucleated, osteoclast-like giant cells lying in a fibroblastic background stroma. The fibroblastic tissue may vary in cellularity from very dense to cell-poor. Mitotic figures may be encountered but are usually not numerous and not atypical. The giant cells mostly cluster in areas of hemorrhage, but they also may lie more dispersed among the lesion. Bone formation is usually confined to the periphery of the lesion, as a reactive remodeling.There may also be a component consisting of immature odontogenic tissue due to developing tooth germs lying within the lesional tissue (Fig.43). [1,5,8]

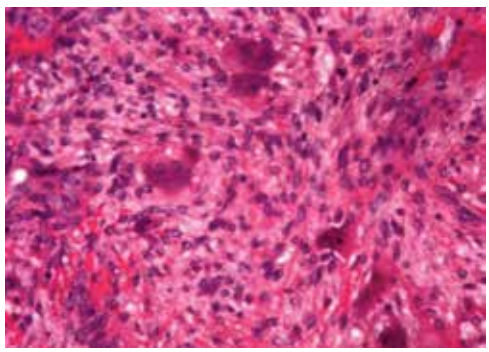

Figure 43. Histologically cherubism shows moderately cellular fibroblastic tissue with dispersed osteoclast-like giant cells and some extravasation of erythrocytes.

6.1.4. Prognosis and therapy

With the onset of puberty, the lesions may lose their activity and may mature to fibrous tissue and bone. Facial deformity may necessitate cosmetic surgery.

6.2. Paget's disease

Paget's disease of bone is a condition characterized by abnormal and anarchic resorption and deposition of bone, resulting in distortion and weakening of the affected bones. The cause of Paget's disease is unknown, but inflammatory, genetic, and endocrine factors may be contributing agents. In some studies 15% to 40% of affected patients have a positive family history of the disease. In recent years, recurrent mutations in the sequestosome 1 gene (SQSTA11, also known as p62) which participates in the regulation of osteoclastic activity via the nuclear factor-KB (NF-KB) transcription activation pathway, have been identified in *both* familial and sporadic cases of the disease. [1,8]

6.2.1. Clinical and radiographic features

Jaw involvement is present in approximately 17% of patients diagnosed with Paget's disease. Maxillary disease, which is far more common than mandibular involvement, results in enlargement of the middle third of the face. In extreme cases, the alteration results in a lion-

like facial deformity (leontiasis ossea). Nasal obstruction, enlarged turbinates, obliterated sinuses, and deviated septum may develop secondary to maxillary involvement. The alveolar ridges tend to remain symmetrical but become grossly enlarged. If the patient is dentulous then the enlargement causes spacing of the teeth. Edentulous patients may complain that their dentures no longer fit because of the increased alveolar size. Radiographically, the early stages of Paget's disease reveal a decreased radiodensity of the bone and alteration of the trabecular pattern. Particularly in the skull, large circumscribed areas of radiolucency may be present (osteoporosis circumscripta (Fig.44).[1,8]

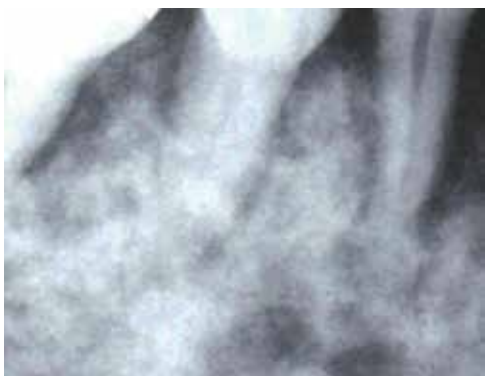

Figure 44. Paget's disease. Periapical film showing the "cotton wool" appearance of the bone.

6.2.2. Histopathologic features

Microscopic examination shows an apparent uncontrolled alternating resorption and formation of bone. In the active resorptive stages, numerous osteoclasts surround bone trabeculae and show evidence of resorptive activity. Simultaneously, osteoblastic activity is seen with formation of osteoid rims around bone trabeculae. A highly vascular fibrous connective tissue replaces the marrow. A characteristic microscopic feature is the presence of basophilic reversal lines in the bone. These lines indicate the junction between alternating resorptive and formative phases of the bone and result in a "jigsaw puzzle." or "mosaic," appearance of the bone (Fig. 45). [1,8]

6.3. Osteoid osteoma

Osteoid osteoma is a benign bone-forming tumor of limited growth potential, usually less than 1.5 cm, typically associated with nocturnal pain that is relieved by salicylates. It is very rare in the head and neck. It occurs in young patients (first three decades), with male predominance. On plain radiographs, dense cortical sclerosis surrounds a radiolucent nidus. Histologically, the nidus shows interconnected, ossified woven bone rimmed by osteoblasts. Fibrous tissue, vessels and multinucleated giant cells are identified inbetween the bony trabeculae (Fig.46).[1,2,8]

http://dx.doi.org/10.5772/54646

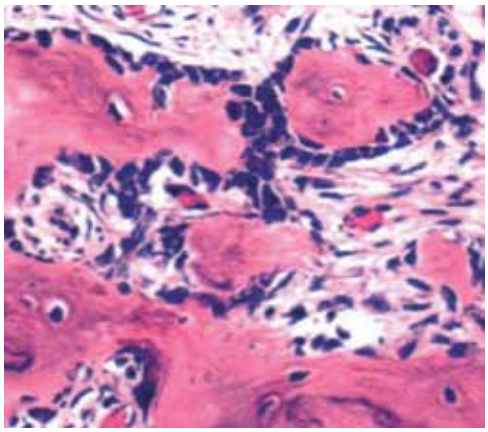

Figure 45. Paget's disease. Osteoblastic and osteoclastic activity surround the bone trabeculae.

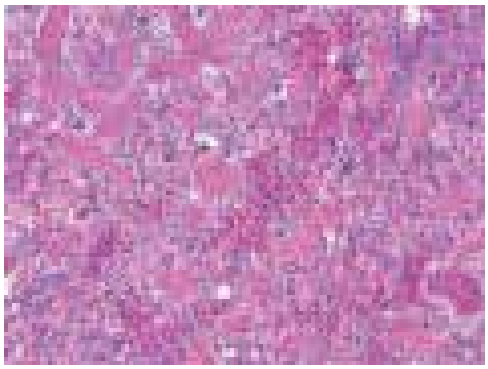

Figure 46. Osteoid osteoma. Osteoblasts surround the trabeculae.

6.3.1. Treatment and prognosis

Most cases of ostcoid ostcoma are treated by local excision or curettage. The prognosis is good, and some lesions will regress even after incomplete excision. [1,2,8]

6.4. Osteoma

6.4.1. Clinical and radiographic features

Osteomas are benign tumors composed of mature compact or cancellous bone. Osteomas are essentially restricted to the craniofacial skeleton and rarely symptomatic. Although pain, swelling, sinusitis, and nasal discharge are possible. In rare cases, paranasal sinus osteomas may expand into orbital structures and result in proptosis, diplopia, and decreased visual acuity. [1-8] Osteomas of the jaws may arise on the surface of the bone, as a polvpoid or sessile mass (periosteal, peripheral or exophytic osteoma). Or they may be located in the medullary

bone (endosteal or central osteoma). Extraskeletal lesions of soft tissue, typically located within muscle or the dermis of the skin (osteoma cutis), also are possible. Most jaw osteomas are detected in young adults and are generally asymptomatic. Paranasal sinus lesions also are possible and are actually more common than gnathic lesions. The frontal sinus is most commonly involved, followed by the ethmoid and maxillary sinuses. [1-8] Radiographically. osteomas appear as circumscribed sclerotic masses. Periosteal osteomas may show a uniform sclerotic pattern or may demonstrate a sclerotic periphery with a central trabecular pattern. Smaller endosteal osteomas are difficult, if not impossible, to differentiate from foci of sclerotic bone representing the end stage of an inflammatory process (condensing osteitis, focal chronic sclerosing osteomyelitis) or from noninflammatory foci of sclerotic bone (idiopathic osteosclerosis). The true nature of these osteomas can be confirmed only by documentation of continued growth (Fig.47). [1-8]

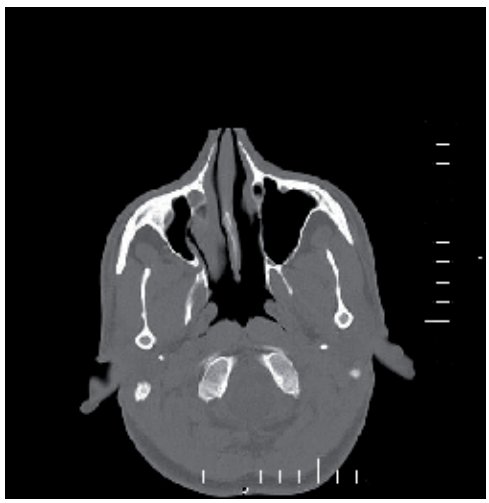

Figure 47. Osteoma in left side of maxilla.

6.4.2. Histopathologic features

A well-circumscribed nodule of mature dense bone is the characteristic feature.Bony trabeculae sometimes are rimmed by osteoblasts. Between bony trabeculae there may be fibrous tissue or fatty stroma with varying amounts of hematopoietic elements. Occasionally there are foci of mature cartilage (Fig.480.[1,8]

6.4.3. Treatment and prognosis

Paranasal sinus osteomas may not require removal unless they become large or symptomatic; small, periosteal lesions may be removed endoscopically. Whereas larger lesions typically require an open surgical approach. Osteomas are completely benign, and patients do not experience malignant change. Recurrence after excision is extremely rare.[1- 8]

http://dx.doi.org/10.5772/54646

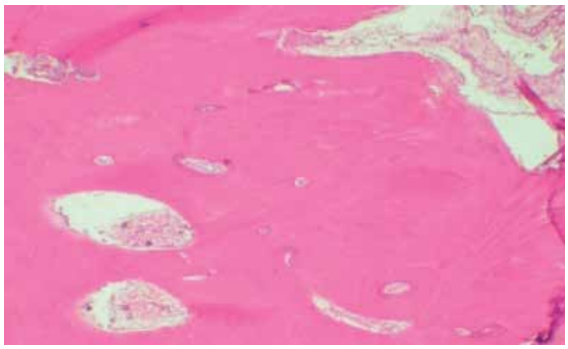

Figure 48. Osteoma. Trabeculae of lamellar bone with an intervening bland fibrous stroma.

6.5. Juvenile ossifying fibroma

Although the two forms demonstrate different histopathologic and clinical features, several investigators have chosen to compromise and accept two patterns of juvenile ossifying fibroma: [1] trabecular and [2] psammomatoid.[1- 8]

6.5.1. Clinical and radiographic features

In most instances, the neoplasms often grow rapidly, are well-circumscribed, and lack continuity with the adjacent normal bone. The lesions are circumscribed radiolucencies that in some cases contain central radiopacities. In some cases "ground glass" opacification may be observed. The age at diagnosis varies, with reported cases occurring in patients from younger than 6 months to older than 70 years of age. Lesions arising in the paranasal sinuses penetrate the orbital, nasal, and cranial cavities. Nasal obstruction, exophthalmos. or proptosis may be seen. Rarely, temporary or permanent blindness occurs in maxillary lesions exhibiting aggressive behavior (Fig.49).[1-8]

Figure 49. CT of Juvenile ossifying fibroma in left maxillary sinus.

6.5.2. Histopathologic features

Both patterns are typically nonencapsulated but well demarcated from the surrounding bone. The tumor consists of cellular fibrous connective tissue that exhibits areas that are loose and other zones that are so cellular that the cytoplasm of individual cells is hard to discern because of nuclear crowding. Myxomatous foci are not rare and often are associated with pseudocystic degeneration. Mitotic figures can be found but are not numerous. Areas of hemorrhage and small clusters of multinucleated giant cells are usually seen (Fig.50).[1-8]

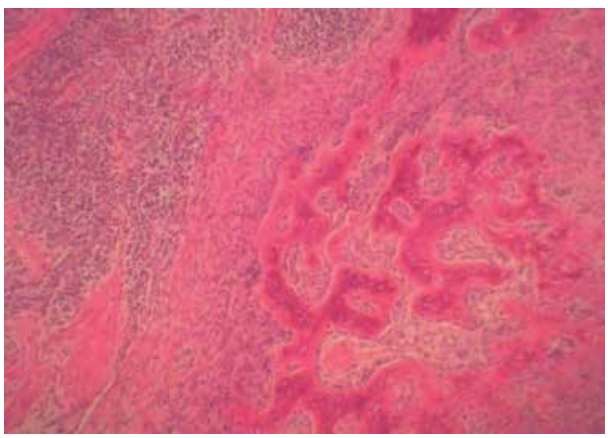

Figure 50. Juvenile ossifying fibroma bony trabeculae lined by a rim of osteoblasts

6.5.3. Treatment and prognosis

For smaller lesions, complete local excision or thorough curettage appears adequate. For some rapidly growing lesions, wider resection may be required. In contrast to the negligible recurrence rate seen in the common types of ossifying fibromas. Recurrence rates of 30% to 58% have been reported for juvenile ossifying fibromas. Malignant transformation has not been documented.[1-8]

6.6. Fibrous dysplasia

Fibrous dysplasia is a developmental tumor-like condition that is characterized by replacement of normal bone by an excessive proliferation of cellular fibrous connective tissue intermixed with irregular bony trabeculae. Fibrous dysplasia is a sporadic condition that results from a postzygotic mutation in the GNAS1 (guanine nucleotide-binding protein, a-stimulating activity polypeptide 1] gene. Clinically, fibrous dysplasia may manifest as a localized process involving only one bone, as a condition involving multiple bones, or as multiple bone lesions in conjunction with cutaneous and endocrine abnormalities (Fig.51). [1 -8]

http://dx.doi.org/10.5772/54646

Figure 51. Clinical features of fibrous dysplasia

6.6.1. Clinical and radiographic features

6.6.1.1. Monostotic fibrous dysplasia of the jaws

The disease is limited to a single bone. This type accounts for about 80% to 85% of all cases, with the jaws being among the most commonly affected sites. The chief radiographic feature is a fine "ground glass" opacification that results from superimposition of a myriad of poorly calcified bone trabeculae arranged in a disorganized pattern. When the maxilla is involved, the lesional tissue displaces the sinus floor superiorly and commonly obliterates the maxillary sinus. Imaging studies in cases with maxillary involvement may show increased density of the base of the skull involving the occiput, sphenoid, roof of the orbit, and frontal bones. This is the most characteristic radiographic feature of fibrous dysplasia of the skull (Fig.52). [1 -8]

6.7. Polyostotic fibrous dysplasia

6.7.1. Jaffe-Lichtenstein syndrome and McCune-Albright Syndrome

Involvement of two or more bones is termed polyostotic fibrous dysplasia. a relatively uncommon condition. The number of involved bones varies from a few to 75% of the entire skeleton. When seen with *cafe au lait* (coffee with milk) pigmentation, the process is termed Jaffe-Lichtenstein syndrome. Polyostotic fibrous dysplasia also may be combined with *cafe au lait* pigmentation and multiple endocrinopathies. such as sexual precocity, pituitary adenoma, or hyperthyroidism. This pattern is known as the McCune-Albright Syndrome.[1-8]

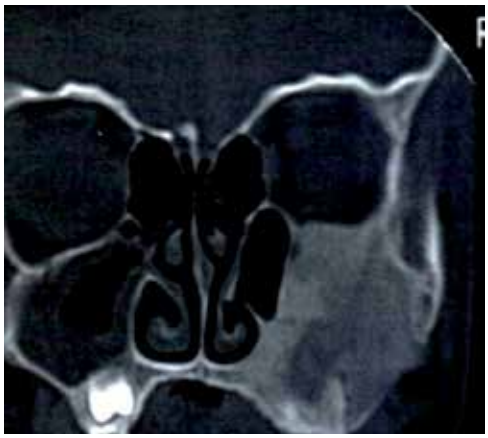

Figure 52. Fibrous dysplasia of the maxilla.-ground glass appearance.

6.7.2. Histopathologic features

The prototypical appearance of fibrous dysplasia consists of irregularly shaped trabeculae of osteoid and woven bone diffusely embedded in a cellular fibrous tissue stroma (Fig.53).[1,2]

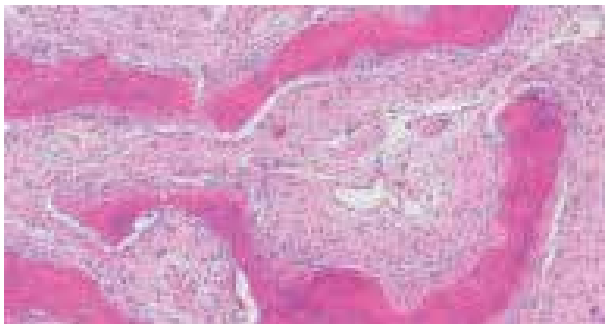

Figure 53. Fibrous dysplasia. Trabeculae of woven bone without osteoblastic rimming.

6.7.3. Treatment and prognosis

Clinical management of fibrous dysplasia of the jaws may present a major problem. Although smaller lesions, may be surgically treated in their entirety without too much difficulty, the diffuse nature and large size of many lesions particularly those of the maxilla, preclude removal without extensive surgery. In many cases, the disease tends to stabilize and stop enlarging when skeletal maturation is reached. Some lesions, however, continue to grow, although slowly, in adult patients. Some patients with minimal cosmetic or functional deformity may not require or desire surgical treatment. Cosmetic deformity with associated psychologic problems or functional deformity may dictate surgical shaving in the younger patient. Such a procedure usually entails surgical reduction of the lesion to an acceptable

http://dx.doi.org/10.5772/54646

contour without attempts to remove the entire lesion. The cosmetic result is usually good, but regrowth may occur over time. [1 -8]

6.8. Giant cell granuloma

6.8.1. Clinical and radiographic features

Molar and premolar areas are more often affected than the anterior parts or the ascending ramus. Involvement of the condyle or maxillary sinus is rare. Most cases present as asymptomatic incidental findings. Some, however, present with pain or paraesthesia, swellings or loosening of teeth. Nasal obstruction may occur. Central or peripheral giant cell lesions (GCL) are expansile, radiolucent and often multiloculated lesions, rarely mixed opacities, with scalloped and mostly well-defined but non-corticated borders. With increasing size, multilocularity is more often noticed (Fig. 54). [1,2,40]

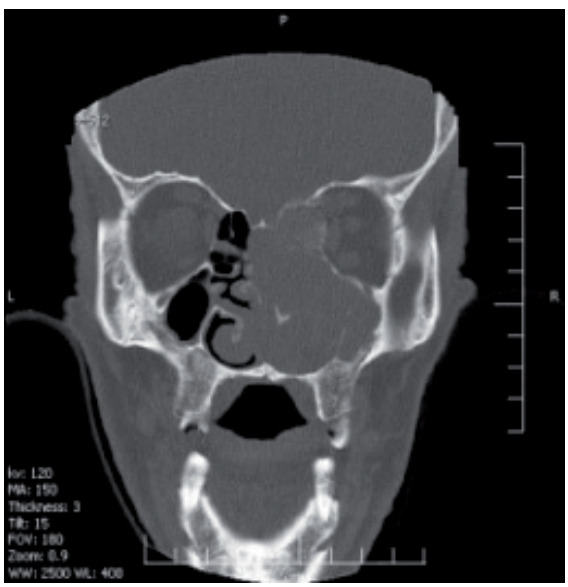

Figure 54. Giant cell lesion with destruction of the maxillary sinus.

6.8.2. Histopathology

The lesion consists of spindle-shaped fibroblastic or myofibroblastic cells, loosely arranged in a fibrous, sometimes fibromyxoid, vascularized tissue hemosiderin deposits, macrophages with hemorrhagic areas, lymphocytes, granulocytes and, rarely, plasma cells. Especially in the hemorrhagic, areas, evenly dispersed or small clusters of osteoclast-like giant cells are found. In addition, traversing collagen bundles are present, often accompanied by metaplastic bone formation giving the lesion a somewhat lobular appearance (Fig. 55). [1,2,3,41]

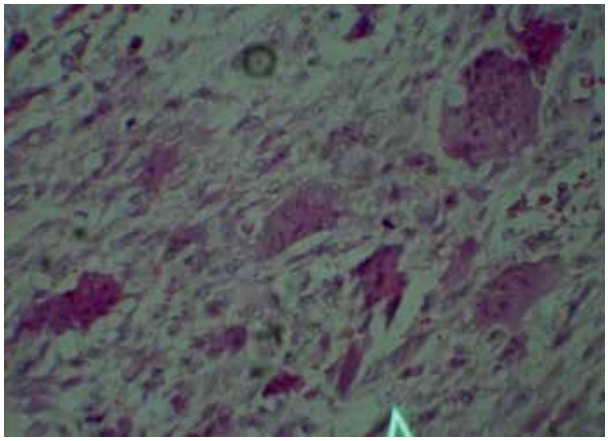

Figure 55. Giant cell lesion; scattered multinucleated cells surrounded by a fibrous tissue stroma.

6.8.3. Treatment and prognosis

Histological findings are not predictive of biological behaviour. The treatment of GCL is careful enucleation. In case of recurrences, more extensive surgery should be considered. Administration of calcitonin (intranasal or subcutaneously), or glucocorticoids (intralesional) has proven effective in some cases. Also antiangiogenic therapy with interferon alpha has been successfully applied. [1,2,3]

6.9. Chondrosarcoma

Chondrosarcoma is a malignant tumor characterized by the formation of cartilage.

6.9.1. Clinical and radiographic findings

A painless mass or swelling is the most common presenting sign. This may be associated with separation or loosening of teeth. Chondrosarcoma may involve the alveolar portion of the maxilla, the maxillary sinus or the nasal septum. Radiographically, the tumor usually shows features suggestive of a malignancy, consisting of a radiolucent process with poorly defined borders. The radiolucent area often contains scattered and variable amounts of radiopaque foci, caused by calcification or ossification of the cartilage matrix. Some chondrosarcomas show extensive calcification and radiographically appear as a densely calcified mass with irregular peripheral margins. Penetration of the cortex can result in a sunburst pattern similar to that seen in some osteosarcomas. When occurring in the head and neck, chondrosarcomas arise most frequently in the maxilla.[1,2,5] Maxillary tumors involve primarily the maxillary sinuses and nasal cavity and are less confined as they quickly erode the thin maxillary bone walls. Early jaw symptoms frequently include malocclusion with developing diastemas, loose teeth and eventual bony destruction (Fig. 560. [1- 5]

http://dx.doi.org/10.5772/54646

Figure 56. Chondrosarcoma of the left maxilla

6.9.2. Histopathologic features

Chondrosarcomas are composed of cartilage showing varying degrees of maturation and cellularity. In most cases, typical lacunar formation within the chondroid matrix is visible, although this feature may be scarce in poorly differentiated tumors. The tumor often shows a lobular growth pattern, with tumor lobules separated by thin fibrous connective tissue septa (Fig. 57). [1- 5]

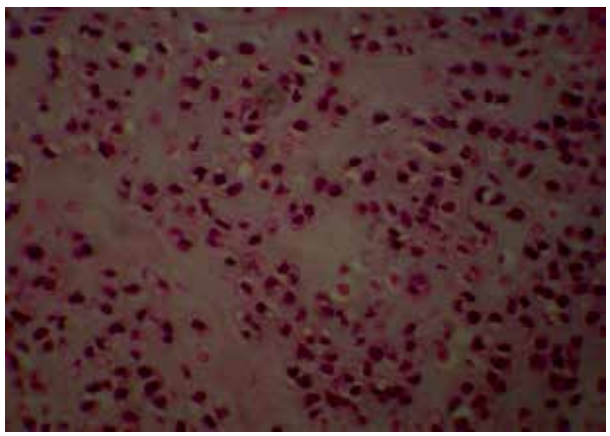

Figure 57. Chondrosarcoma. Cartilaginous neoplasm shows an abundant matrix that surrounds chondrocytes and mild nuclear irregularities.

6.9.3. Treatment and prognosis

The prognosis for chondrosarcoma is related to the size, location, and grade of the lesion. The most important factor is the location because this has the greatest influence on the ability to achieve complete resection. The most effective treatment for chondrosarcoma is radical surgical excision. Radiation and chemotherapy are less effective when compared with osteosarcoma and are primarily used for unresectable high-grade chondrosarcomas.[5,6] Chondrosarcomas are associated with an excellent prognosis if the lesions are completely resected. Approximately 20% of patients die of tumor, most often with uncontrolled local recurrence. Mesenchymal chondrosarcoma is a high-grade tumor with an unpredictable prognosis. Patients with tumor of the facial skeleton do better than those with tumors of the remainder of the skeleton[1,2,4- 6]

6.10. Osteosarcoma

6.10.1. Clinical and radiographic features

The maxilla and mandible are involved with about equal frequency. Mandibular tumors arise more frequently in the posterior body and horizontal ramus rather than the ascending ramus. Maxillary lesions are discovered more commonly in the inferior portion (alveolar ridge, sinus floor, palate) than the superior aspects (zygoma, orbital rim). Swelling and pain are the most common symptoms Loosening of teeth, paresthesia. and nasal obstruction (in the case of maxillary tumors) also may be noted. Some patients report symptoms for relatively long periods before diagnosis, which indicates that some rare osteosarcomas of the jaws grow rather slowly. The radiographic findings vary from dense sclerosis to a mixed sclerotic and radiolucent lesion to an entirely radiolucent process. The peripheral border of the lesion is usually ill-defined and indistinct, making it difficult to determine the extent of the tumor radiographically. In some cases, an extensive osteosarcoma may show only minimal or subtle radiographic change with only slight variation in the trabecular pattern. Occasionally, there is resorption of the roots of teeth involved by the tumor. This feature is often described as "spiking" resorption as a result of the tapered narrowing of the root. The "classic" sunburst or sun ray appearance caused by osteophytic bone production on the surface of the lesion is noted in about 25% of jaw osteosarcomas. Often this is appreciated best on an occlusal projection. In few cases a triangular elevation of the periosteum, referred to as *Codman's triangle*, may be observed (Fig. 58).[1,3,8]

6.10.2. Histopathologic features

Depending on the amount of osteoid, cartilage or collagen fibers produced by the tumor, many pathologists subclassify osteosarcomas into Osteoblastic, Chondroblastic and Fibroblastic subtypes. These histopathologic subtypes, however, do not have influence on the prognosis. Other less commonly encountered histopathologic variations include malignant fibrous histiocytoma-like, small cell, epithelioid, telangiectatic and giant cell-rich (Fig. 59).[1,2,8]

http://dx.doi.org/10.5772/54646

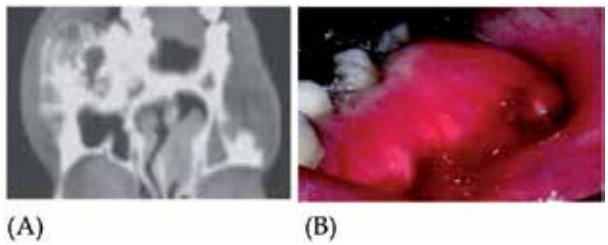

Figure 58. A. CT scan of an osteosarcoma of the maxilla. B. Oral view.

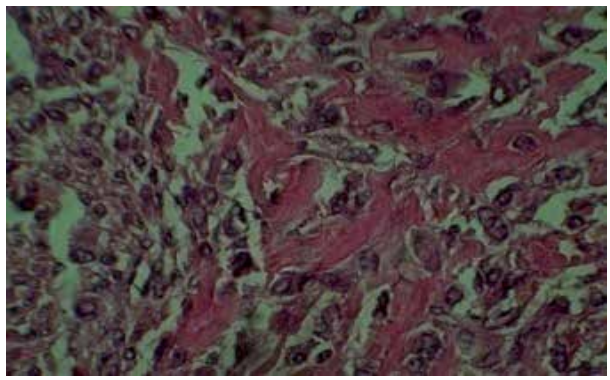

Figure 59. Osteosarcoma. Dense, irregular osteoid separated by a cellular stroma.

6.10.3. Treatment and prognosis

Multicenter investigations of different therapies to osteosarcoma of long bones have led to an improved prognosis that now appears superior to that associated with gnathic neoplasms. These protocols involve neo adjuvant (preoperative) chemotherapy followed by radical surgical excision with careful pathologic examination of the specimen to evaluate the chemotherapeutic effects on the tumor. Adjuvant (postoperative) chemotherapy is used and may be modified if poor histopathologic response to the neoadjuvant regimen is noted. Some investigators have demonstrated 4-year survival rates exceeding 80% with this approach Limited numbers of patients with jaw osteosarcomas have been treated with these protocols, and superior results have been claimed compared with surgical treatment alone.[1,2]

6.11. Ewing Sarcoma (EWS) /Primitive Neurvoectodermal Tumor (PNET)

6.11.1. Clinical features

Sinonasal EWS/PNET most commonly occur in the maxillary sinus and nasal fossa and mandible [1,2,8] Symptoms include pain, mass, and obstruction. The tumor can be polypoid when arising from the nasal cavity. Bony erosion may or may not be present [2,8]

6.11.2. Histopathology

The tumor is composed of densely distributed, uniform, small to medium sized, round cells with a high nuclear to cytoplasmic ratio and fine chromatin. Mitotic activity is high, and coagulative necrosis is common. Some cases show more densely clumped chromatin or a greater degree of nuclear pleomorphism. Home Wright rosettes are rare Fig. 60.[1,2,8]

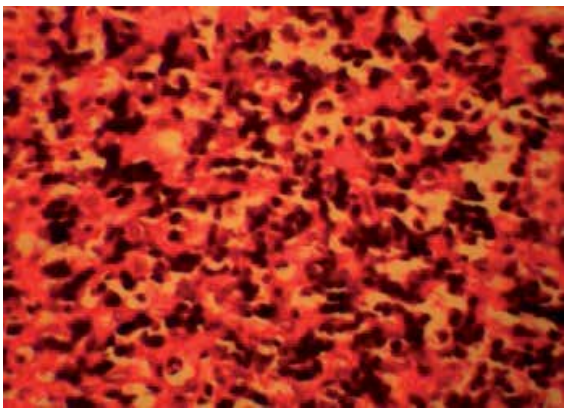

Figure 60. Ewing sarcoma. Intermediate-sized cells, scanty cytoplasm and increased mitotic figures.

6.11.3. Immunohistochemistry

The immunophenotype includes reactivity for CD99 (MIC2, O13, HBA-71, p30/32, and 12E7), vimentin, and on occasion focally for keratins. Some cases express neural markers, such as synaptophysin, S100 protein, NSE, neurofilament protein, GFAP, and chromogranin. Fli-1 (one portion of the gene fusion product of EWS/FLI1) can be detected by immunohistochemistry. [2,8]

6.11.4. Treatment and prognosis

Regardless of anatomic site in the head and neck region, complete excision is the treatment of choice, as radiation and chemotherapy have less value. For Sinonasal lesions, the 5-year survival rate is approximately 10 to 21 percent. [1,2,8]

7. Neuroectodermal tumors

Neurofibroma, Schwannoma,Malignant melanoma are common neuroectodermal lesions.

7.1. Neurofibroma

This benign tumor of peripheral nerve sheath phenotype with mixed cellular components, including Schwann cells, perineurial hybrid cells and intraneural fibroblasts.

http://dx.doi.org/10.5772/54646

7.1.1. Clinical features

Symptoms include epistaxis, rhinorrhoea, swelling, mass, obstruction, and pain [1,8]

7.1.2. Histopathology

Neurofibromas are generally submucosal paucicellular lesions. They are composed of spindled cells with wavy, dark-staining nuclei and scanty cytoplasm, in a background of wavy collagen fibres, myxoid stroma and mast cells. The center of the lesion usually shows residual neuritis (Fig. 61).[1,2,8]

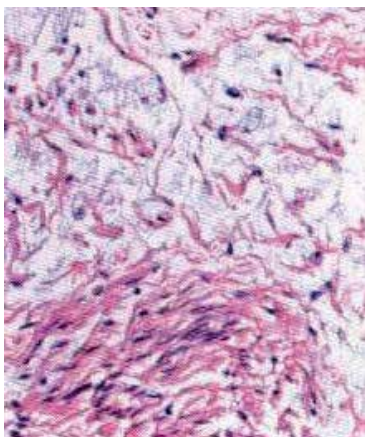

Figure 61. Oral neurofibroma. Spindle cells with dark serpentine nuclei are surrounded by a myxoid matrix.

7.1.3. Immunohistochemistry

The tumor is diffusely immunoreactive for S100 protein, but the proportion of positive cells is lower than that in schwannoma. CD34 stains the admixed fibroblasts.[2]

7.1.4. Treatment and prognosis

Neurofibromas are benign and have a very low recurrence rate. A small percentage of cases may undergo malignant transformation[1,8]

7.2. Schwannoma

A usually encapsulated, benign tumor composed of differentiated, neoplastic Schwann cells.

7.2.1. Clinical and radiographic features

Less than 4% of schwannomas involve the nasal cavity and paranasal sinuses and they occur in middle aged adults with an equal gender distribution. Sinonasal schwannomas arise from the branches of the trigeminal (5th cranial) nerve and autonomic nervous system, and most

commonly involve the ethmoid and maxillary sinuses, followed by the nasal cavity, sphenoid and frontal sinuses. The presenting symptoms include obstruction, rhinorrhea, epistaxis, anosmia, headache, dysphagia, hearing loss facial or orbital swelling, and pain Sinonasal schwannoma ranges in size up to 7 cm. It is a well-delineated but non-encapsulated globular, firm to rubbery yellow-tan mass. The cut surfaces show tan-grey, yellowish, solid to myxoid and cystic tissue, commonly with hemorrhage.[1,2,8]

7.2.2. Histopathology

Schwannoma is composed of cellular Antoni A areas with Verocay bodies and hypocellular myxoid Antoni B areas. The cells are fusiform with elongated fribillary cytoplasm, and buckled to spindled nuclei which show little pleomorphism, although scattered large pleomorphic or bizarre cells can be present in some cases. Nuclear palisading is often evident in some foci. There are frequently small to medium-sized vessels with ectasia, thrombosis and perivascular hyalinization in the Antoni B areas. Extensive degenerative changes can occur, and may result in only a thin rim of recognizable tumor. Cellular variants exhibit only the Antoni A pattern, but no fascicular growth or Verocay bodies (Fig. 62).[2,42]

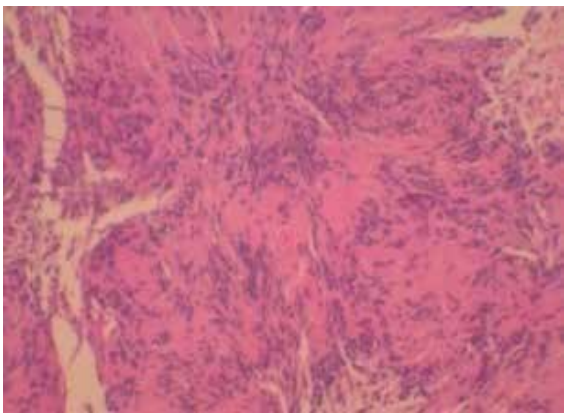

Figure 62. Schwannoma cellular areas (Antoni A) and loose, myxoid foci (Anroni B)

7.2.3. Immunohistochemistry

The tumor cells are strongly and diffusely immunoreactive for S100 protein. CD34 only stains some more slender cells in the Antoni B areas. Neurofilament is absent. GFAP and keratins may be positive.[1,8]

7.2.4. Treatment and prognosis

This tumor has a very low recurrence potential. Schwannoma is a benign tumor and transformation is rare.[1,8]

http://dx.doi.org/10.5772/54646

7.3. Malignant melanoma

7.3.1. Clinical features

More than half of mucosal melanomas occur in the head and neck area (including the oral and sinonasal regions). Symptoms include nasal obstruction, epistaxis, nasal polyp, pain, nasal discharge of variable duration, and melanorrhoea ("coal flecked" or brown nasal discharge (Fig. 63).[1,2,43]

Figure 63. Malignant melanoma involving maxillary sinus and alveolar ridge.

7.3.2. Histopathology

The tumors are comprised of epithelioid, spindled, plasmacytoid, rhabdoid and/or multi-nucleated tumor cells. The cells are generally medium to large-sized They have a high nuclear to cytoplasmic ratio with pleomorphic nuclei containing prominent eosinophilic nucleoli and intranuclear cytoplasmic inclusions. Nuclear molding may be present. The cytoplasm is usually densely eosinophilic, and variably contains melanin pigment. Mitoses, including atypical forms, are frequent and easily identifiable. Vascular invasion and neurotropism may be identified in up to 40% of cases. An inflammatory infiltrate admixed with pigment-laden histiocytes is commonly identified within or adjacent to the tumor. Tumor cell necrosis is common, particularly in tumors displaying a peritheliomatous or pseudopapillary growth pattern. Other growth patterns include solid, alveolar or sarcomatoid (Fig. 64). [1-8]

7.3.3. Immunohistochemistry

Malignant melanoma expresses S100 protein, vimentin and variably HMB45, tyrosinase, melan-A and microphthalmia transcription factor. Neuron specific enolase, CD117, CD99

synaptophysin, CD56, and CD57 have been reported to be occasionally positive but epithelial membrane antigen, cytokeratins, and muscle markers are not expressed. [2,43]

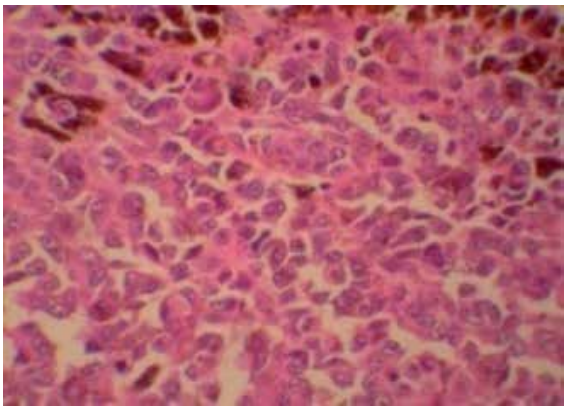

Figure 64. Malignant melanoma. Malignant cells with a high nuclear to cytoplasmic ratio with pleomorphic nuclei containing prominent eosinophilic nucleoli.

7.3.4. Treatment and prognosis

The features best related to tumor behavior are the stage of disease and the depth of invasion. Surgical excision is the mainstay of treatment although the extent of the excision is somewhat controversial. Older literature suggests that surgical margins of 3 to 5 cm around the tumor are necessary to achieve control, regardless of the site of the lesion. More recent studies indicate that a 1-cm margin is adequate for small cutaneous tumors less than 2 mm in thickness. For larger, more deeply invasive tumors, wide surgical excision still is recommended.[1,2,8]

Author details

Taghi Azizi*

Assistant Professor of Oral and Maxillofacial Pathology, Trauma Research Center, Baqiyatallah University of Medical Sciences, Iran

References

[1] Neville, oral and maxillofacial pathology,3rd edition, Saunders 2009

[2] Leon Barnes,John w.pathologic and genetic head and neck tumors.2007

[3] Steven G, Silverberg, surgical pathology and cytopathology, 4th edition, Churchill livingstone Elsevier, 2006

[4] Leon Barnes,et-al.surgical pathology head and neck.volume 1, 3rd edition, 2009 by informa healthcare USA, inc, p(374-376)

[5] Lester D.R.Thompson, head and neck pathology a volume in the series foundations in diagnostic pathology, Churchill livingstone, 2006.p(497-510)

[6] Douglas R.Gnepp,MD, Diagnostic surgical pathology of the head and neck,second edition,, 2009 by sunders, an imprint of Elsevier Inc.

[7] Edward B. stelow. Stacy E. mils, Biopsy interpretation of the upper Aerodigestive tract and Ear, 2007

[8] Rosai and Akermans.,surgical pathology.,10th edition.,volume1,2.,mosby/.20011

[9] Lieberman P. Rhinitis—allergic and nonallergic. Hosp Pract (Off Ed) 1988; 23:117–132

[10] Mygind N. Pathogenesis of allergic rhinitis. Acta Otolaryngol Suppl (Stockh) 1979; 360:9–12.

[11] Mabry RL. Allergic rhinosinusitis. In: Bailey BJ, Johnson JT, Kohut RI, et al. ed. Head Neck Surgery—Otolaryngology.Philadelphia: JB Lippincott, 1993:290–301

[12] Murray JC, Pollack SV, Pinnel SR. Keloids: a review. J Am Acad Dermarol1981;4:461-70.

[13] Sheehy JL. Diffuse exostoses and osteomata of the external auditory canal: a report of 100 operations. Otolarygol Head Neck Surg 1982;90:337--42.

[14] Heffner DK, Hyams VJ. Cystic chondromalacia (endochondral pseudocyst) of the auricle. Arch Pathol LabMed 1986;110:740-3

[15] Barnes L, Kanbour A (1988). Malignant fibrous histiocytoma of the head and neck. A report of 12 cases. Arch Otolaryngol Head Neck Surg 114: 1149-1156 Laryngoscope 96: 1381-1384

[16] Oysu C, Aslan I, Bilgic B, Yazicioglu E (2001). Malignant triton tumor of the parapharyngeal space. J Laryngol Otol 115:573-575

[17] Nicolai P, Tomenzoli D, Berlucchi M, Facchetti F, Morassi L, Maroldi R (2000). Malignant triton tumor of the ethmoid sinus and nasal cavity. Ann Otol Rhinol Laryngol109: 880-886

[18] Wong KF, So CC, Wong N, Siu LL, Kwong YL, Chan JK (2001). Sinonasal angiosarcoma with marrow involvement at presentation mimicking malignant lymphoma cytogenetic analysis using multiple techniques. Cancer Genet Cytogenet 129: 64-68

[19] Panje WR, Moran WJ, Bostwick DG, Kitt VV (1986). Angiosarcoma of the head and neck: review of 11 cases.

[20] Hicks J, Flaitz C (2002). Rhabdomyo - sarcoma of the head and neck in children. Oral Oncol 38: 450-459

[21] Tonin PN, Scrable H, Shimada H, Cavenee WK (1991). Muscle-specific gene expression in rhabdomyosarcomas and stages of human fetal skeletal muscle development. Cancer Res 51: 5100-51

[22] Huang HY, Antonescu CR (2003). Sinonasal smooth muscle cell tumors: a clinicopathologic and immunohistochemical analysis of 12 cases with emphasis on the low-grade end of the spectrum. Arch Pathol Lab Med 127: 297-304

[23] Fu YS, Perzin KH (1975). Nonepithelial tumors of the nasal cavity, paranasal sinuses, and nasopharynx: a clinicopathologic study. IV. Smooth muscle tumors(leiomyoma, leiomyosarcoma). Cancer 35: 1300-1308.

[24] Folpe AL, Chand EM, Goldblum JR, Weiss SW (2001). Expression of Fli-1, nuclear transcription factor, distinguishes a vascular neoplasms from potential mimics. Am J Surg Pathol 25: 1061-1066

[25] Rohrmus B, Thoma-Greber EM, Bogner JR, Rocken M (2000). Outlook in oral and cutaneous Kaposi's sarcoma Lancet 356: 2160

[26] Cross JJ, Pilkington RJ, Antoun NM, Adlam DM (2000). Value of computed tomography and magnetic resonance imaging in the treatment of a calcifying epithelial odontogenic (Pindborg) tumor. Br J Oral Maxillofac Surg 38: 154-157.

[27] Veness MJ, Morgan G, Collins AP, Walker DM (2001). Calcifying epithelial odontogenic (Pindborg) tumor with malignant transformation and metastatic spread Head Neck 23: 692-696.

[28] Franklin CD, Pindborg JJ (1976). The calcifying epithelial odontogenic tumor. A review and analysis of 113 cases. Oral Surg Oral Med Oral Pathol 42: 753-765

[29] Hicks MJ, Flaitz CM, Wong ME, McDaniel RK, Cagle PT (1994). Clear cell variant of calcifying epithelial odontogenic tumor: case report and review of the literature. Head Neck 16: 272-277

[30] Philipsen HP, Reichart PA, Praetorius F (1997). Mixed odontogenic tumors and odontomas. Considerations on interrelationship. Review of the literature and presentation of 134 new cases of odontomas. Oral Oncol 33: 86-99.

[31] Piattelli A, Trisi P (1992). Morphodif - ferentiation and histodifferentiation of the dental hard tissues in compound odontoma: a study of undemineralized material. J Oral Pathol Med 21, 340-342.

[32] Martins C, Carvalho YR, do Carmo MA (2001). Argyrophilic nucleolar organizer regions (AgNORs) in odontogenic myxoma (OM) and ameloblastic fibroma (AF). J Oral Pathol Med 30: 489-493

[33] A. Pahl S, Henn W, Binger T, Stein U, Remberger K (2000). Malignant odontogenic myxoma of the maxilla: case with cytogenetic confirmation. J Laryngol Otol114: 533-535

[34] Chidzonga MM (1996). Ameloblast - oma in children. The Zimbabwean experience. Oral Surg Oral Med Oral Pathol Oral Radiol Endod 81: 168-170

[35] Dhir K, Sciubba JJ, Tufano RP (2003 Ameloblastic carcinoma of the maxilla.

[36] Cox DP, Muller S, Carlson GW, Murray D (2000). Ameloblastic carcinoma ex ameloblastoma of the mandible with malignancy- associated hypercalcemia. Oral Surg Oral Med Oral Pathol Oral Radiol Endod 90: 716-722.

[37] Simko EJ, Brannon RB, Eibling DE(1998). Ameloblastic carcinoma of the mandible. Head Neck 20: 654-659

[38] Takahashi N, Miura I, Chubachi A, Miura AB, Nakamura S (2001). A clinicopathological study of 20 patients with T/natural killer (NK)-cell lymphoma-associated hemophagocytic syndrome with special reference to nasal and nasal-type NK/T-cell lymphoma. Int J Hematol 74: 303-308.

[39] Jaffe ES, Chan JK, Su IJ, Frizzera G, Mori S, Feller AC, Ho FC (1996). Report of the Workshop on Nasal and Related Extranodal Angiocentric T/Natural KillerCell Lymphomas. Definitions, differentia diagnosis, and epidemiology. Am J Surg Pathol 20: 103-111

[40] Stavropoulos F, Katz J (2002). Central giant cell granulomas: a systematic review of the radiographic characteristics with the addition of 20 new cases. Dentomaxillofac Radiol 31: 213-217

[41] El Labban NG, Lee KW (1983). Myofibroblasts in central giant cell granuloma of the jaws: an ultrastructural study.Histopathology 7: 907-918.

[42] Shugar JM, Som PM, Biller HF, Som ML, Krespi YP (1981). Peripheral nerve sheath tumors of the paranasal sinuses. Head Neck Surg 4: 72-76

[43] Briele HA, Walker MJ, Das Gupta TK(1985). Melanoma of the head and neck. Clin Plast Surg 12: 495-504

Section 4

Large and Agressive Maxillofacial Cysts: Trends in Management

Chapter 6

Treatment of Large Cysts of the Mandible with Autografts of Cancellous Bone from the Tibia

Piotr Malara

Additional information is available at the end of the chapter

http://dx.doi.org/10.5772/53859

1. Introduction

Modern maxillofacial surgery is involved in treating a wide spectrum of diseases of the head and neck. Infectious diseases, cancers, traumas, as well as congenital and acquired malformations lie within the scope of this specialty. An important part of this specialty is treating diseases of the oral cavity and jaw bones, especially the removal of impacted teeth and orthognathic surgery. Treatment of large cysts is still a challenge for maxillofacial surgeons. The two-stage treatment is time-consuming, uncomfortable for patients and requires frequent check-ups. One-stage cystectomy of large cysts with water-tight closure of the postoperative bone cavity predisposes to complications (i.e. infection). Moreover, the weakened bone structure is prone to fractures in the postoperative period. This is why there is particular interest to fill the bone cavities with autografts and alloplastic materials. In the majority of cases no early complications are observed after cancellous bone harvesting from proximal tibia by medial approach to fill the bone cavities after cystectomies. Only moderate pain is experienced by the patients just after surgery allowing for early ambulation. Postoperative hospital stay ranges normally from 5 to 8 days depending on the size of the intraoral wound after cystectomy. However, the same day discharge postoperatively may be done. The volume of cancellous bone obtained ranges from 8 to 21 cm^3.This chapter is based on our own experience and the literature review supportng the statement that cancellous bone harvesting from the proximal tibia via a medial approach is a relatively complication-free surgical procedure, which should be recommended when large postoperative cavities in mandible need to be grafted with significant amounts of cancellous bone. The aim of the chapter is to present the operative technique of cancellous bone harvesting from proximal tibia for filling large bone cavities after cystectomies. This chapter presents extensive step-by-step description of the

INTECH
open science | open minds

© 2013 Malara; licensee InTech. This is a paper distributed under the terms of the Creative Commons Attribution License (http://creativecommons.org/licenses/by/3.0), which permits unrestricted use, distribution, and reproduction in any medium, provided the original work is properly cited.

operative technique. Special attention is focused on postoperative care and early rehabilitation. Possible complications related to the donor site, such as fractures due to the weakening of the tibia and donor site morbidity is presented in detail. The necessary period of postoperative hospital stay and mean volume of cancellous bone obtained will also be discussed.

2. Background

A serious problem in maxillofacial surgery is the persistence of a bone cavity as a result of a disease or after enucleation of intraosseous lesions. It is mostly associated with significant weakening of bony structures depending on the size of the bone cavity. In case of large cavities pathological bone fractures may appear as a result of even relatively slight trauma. Removal of a large intraosseous lesion may also cause esthetic problems and long-term functional problems. Moreover, in many cases tight closure of a bone cavity with soft tissue is difficult, which may cause further problems in the process of postoperative treatment. Tight closure of large bone cavities inevitably causes empty spaces. First, post-operative empty spaces fill with extravasated blood from adjacent tissues. Considering the regeneration process, it is a beneficial process, as the clot created from extravasated blood can lead to healing of the bone cavity as a result of a cascade of biochemical and cellular processes. It forms fibrous tissue which then goes through the process of mineralization, which results in filling of the bone cavity with newly created, full-fledged bone tissue. This process takes place according to the scenario above only in case of relatively small bone cavities. In cases with large bone cavities, which exceeds 4 cm, there is a risk of multiple complications in healing which result from the retraction of the clot which appears in the closed post-operative cavity. Consequently, it may lead to the appearance of defective bone-like tissue which does not fulfill histological and clincal criteria. It is also important to remember that most operations in maxillofacial surgery are conducted via intraoral access. The consequence of conducting the surgery in an unsterile environment of the oral cavity is superinfection of the bone bed during the surgery and wound contact with bacterial flora of the oral cavity in the post-operative phase. Infection of a hematoma in the bone cavity with bacterial flora of the oral cavity may result in suppuration. The appearance of suppuration within the facial skeleton might progressively spread to adjacent spaces, in many cases making regenerative processes impossible, treatment length and expensive; it may also result in the occurrence of life-threatening complications. Therefore, in the case of large cysts their complete enucleation and closure via mucoperiosteal flap may leave a large empty space predisposed to infection of the hematoma which forms inside it during the post-operative period. Weakened bone structure also constitutes a risk for mandible fractures. Thus, special attention is paid to fill bone cavities with autogenous grafts and alloplastic materials. The advantage of autotransplantation is the fact that they have osteoconductive as well as osteogenic properties to accelerate the regeneration of bone, which should be the primary goal of the surgical procedure.

http://dx.doi.org/10.5772/53859

3. Grafts

Most often autogenous bone grafts, as well as xenogenic and alloplastic materials are used to fill the cavities. Xenogenic materials are deprived of the organic components, which means that they include only inorganic components. It is similar to alloplastic materials which consist mainly of hydroxyapatite or calcium tri-phosphates. The advantage of alloplastic materials is the lack of a donor site and the reduction of patient discomfort. Its main drawback is that the materials consist mainly of inorganic components only. When implanted in the cavity they constitute a scaffold for infiltrating new blood vessels and connective tissue fibers; then they constitute a substrate of an inorganic phase for mineralization of the bone matrix. Therefore they mainly have osteoconductive properties with no osteogenic and osteoinductive properties. Therefore when such materials are used, significantly slower healing of bone cavities should be expected in comparison with grafts of bone tissue which are rich in living osteogenic cells and substances with osteoinductive properties.

Therefore bone grafts are a frequently used form of surgical treatment in maxillofacial surgery such as atrophy, congenital malformations, trauma and defects emerging as a result of cancer. Considering the fact that autogenous grafts are performed within the same body, the problem of potential graft rejection due to immunological incompatibility does not exist. While it is a significant problem in case of heterogeneous and xenogenic grafts [1]. Autografts are claimed to be the golden standard of reconstructive surgery; because the graft consists of organic and inorganic parts, and a large pool of osteogenic cells. As opposed to soft tissue grafts, the inorganic part of the bone graft creates a scaffold which functions as a bridge for the cells coming from the rim of the recipient site. The graft is colonized by cells, which undertake their functions and allow the survival of the graft [2]. Graft healing takes from three to six months and it is connected with a specified pattern of vascular and cellular processes [3].

The process of healing is connected with resorption and remodeling of the bone graft. The resorption degree and its pace depend on numerous factors, including the size of the grafted bone, its quality, as well as the quality of the donor site and the method of attachment of the graft in the recipient site [4]. It can be concluded from clinical observations that the smaller volume of grafted bone tissue, the slower the rate of graft resorption. The method of attachment of the graft in the recipient site is extremely important. On one hand, the attachment should ensure stable mounting of the grafted bone. Even the slightest movements of the graft on its base significantly increase the rate of resorption. On the other hand stability of the graft should be ensured using the smallest possible number of binding materials. The smaller amount of binding material, the slower the rate of the graft resorption clinically observed.

In transplant surgery two types of bone tissue coexisting in the human body can be used. Cortical bone thanks to the presence of Haversian channels, shows good osteoconductive properties. Due to its mechanical properties it can be used in cases when recreation of tridimensional cavities within the facial part of the skeleton is required. As opposed to cortical bone, cancellous bone is extremely rich in osteogenic cells. Living osteoblasts of cancellous

bone may survive even for a few hours from the time of harvesting of the tissue; early revascularization in closed cavities takes place after 48 hours. The disadvantage of the cancellous bone grafts is their small mechanical endurance. It is also connected with the lack of possibility to use them in case of tridimensional reconstructions [5].

4. Cysts

An example of bone cavities in which the cancellous bone grafts can be used is a post-cystectomy cavity. Cysts in jaw bones occur relatively often and they are pathological changes within the facial skeleton. They are pathological spaces filled with liquid or semi-liquid content. Sometimes they are lined with epithelium. Their occurrence is not connected with the accumulation of purulent discharge. Development of jaw cysts is often asymptomatic. They are often diagnosed accidentally during routine dental or radiological examinations. Sometimes in case of large cysts located on the surface a deformation or facial asymmetry is observed. Cysts located directly under the mucosa of the oral cavity cause significant thinning of mucosa which has a bluish color in such cases. In a situation when developing cysts cause significant distension of bone structure, bending and crepitation of bone cortex can be felt during palpation. Cysts can also undergo secondary infection and then problems associated with purulent infection become most visible. Besides clinically diagnosed asymmetry, long-term growth of cysts may lead to tooth root movement, occlusion disorders and loosening of neighboring teeth. When a patient uses dentures, the ones that have been used up until that time may not be well-adjusted any more. In the mandible developing cysts may lead to disturbances of sensation from damage of the inferior alveolar nerve. Moreover, loss of bone tissue which occurs because of developing cysts may lead to pathological fractures of the mandible.

Cysts can be divided in many categories. From a practical point of view, cysts which appear most often are radicular cysts, also known as inflammatory. Their appearance is related with a presence of a non-vital tooth. In case of the absence of a tooth in the dental arch after the eruption time, an eruption cyst, a dentigerous cyst or a keratocystic odontogenic tumor must be taken into consideration. Among additional examinations, radiological examinations play a most significant role in the diagnosis of a cyst. In case of large cysts it is necessary to have an orthopantomographic (OPG) image to reveal the whole lesion. In radiological assessment the following should be taken into consideration: translucency of the lesion, its size and shape, the surrounding border changes, its relation to adjacent teeth, maxillary sinus and the lower alveolar nerve, displacement or resorption of teeth and the presence of opacity within the lesion.

Differential diagnosis of radiological entities observed within the facial skeleton should consider central giant cell granuloma, ameloblastoma, calcifying fibroma, myxoma and multiple myeloma.

The treatment of choice used in case of bone cysts is complete enucleation. Self-regeneration in most cases leads to complete healing of the bone cavity. While this method of treatment is

http://dx.doi.org/10.5772/53859

acceptable in the case of small cysts, this approach arouses some controversies in the case of large cysts, especially those located in the mandible [6].

Marsupialization is a method of treating such changes which has been used to this day [7]. This procedure includes opening the cyst, draining its content and exposing the lining epithelium to the oral cavity. It is a relatively simple procedure and it has an advantage of reducing the risk of damaging the structures adjacent to the cyst, for example when the cyst spreads between the roots of vital teeth or in the direction of the lower alveolar nerve. Moreover, this method of treatment is recommended for older people and compromised patients for whom a lengthy surgical procedure is contraindicated. Its disadvantage is that pathologically changed tissue which lines the cyst remains in the body for another 6-18 months, during which the post-operative cavity is filled respectively with lint compresses, wax obturators and acrylate obturators. Marsupialization of cysts has good treatment results, however it is long-term, it requires frequent check-ups and it is rather uncomfortable for patients [8]. The whole surgical procedure should be finished with complete excision of pathologically transformed tissue at a later date together with a histopathological verification of the removed tissue. As mentioned above, the method of choice is a complete one-phase enucleation of the cyst. During the procedure the lining of the cyst should be precisely separated from adjacent structures so that the whole lesion can be enucleated in one piece. Surgical access is through the mucosa of the oral cavity and bone covering the cyst. The soft tissue incision should be performed far from the margins of the lesion to ensure the course of the suture line does not overlie the bone defect.

5. Diagnostics and pre-surgical procedures

Radiographs. Within pre-operative diagnostics in all patients with suspected mandibular cysts orthopantomographic (OPG) radiographs are taken (Fig. 1).

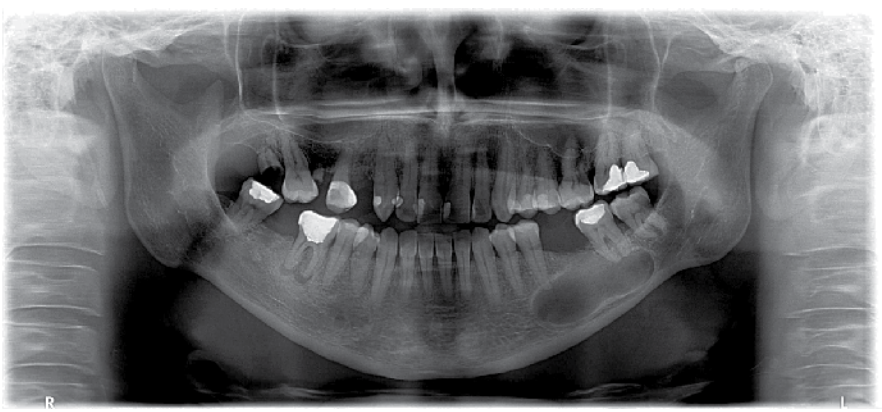

Figure 1. OPG of a large cyst in the left mandible.

Biopsy. Biopsy for histopatological examination is also taken in the outpatient department. Patients with histopatological diagnosis of odontogenic cysts with sharply demarcated osteosclerotic margin and largest dimension exceeding 4 cm are candidates for surgical treatment to enucleate the cyst and direct fill the post-cystectomy defect with autogenous graft from the proximal tibia [8].

Computed tomography. A computed tomography (CT) scan of the facial skeleton is performed (Fig. 2), as well as an X-ray of the knee joints in the antero-posterior and lateral views (Fig. 3 and 4).

It is essential to consider data from the case history in selecting a limb to harvest cancellous bone (lack of previous fractures etc.), as well as the results of radiological examination (for lesions, defects etc. of the proximal tibia). When both limbs can constitute donor sites, the patient's preference should be taken into consideration.

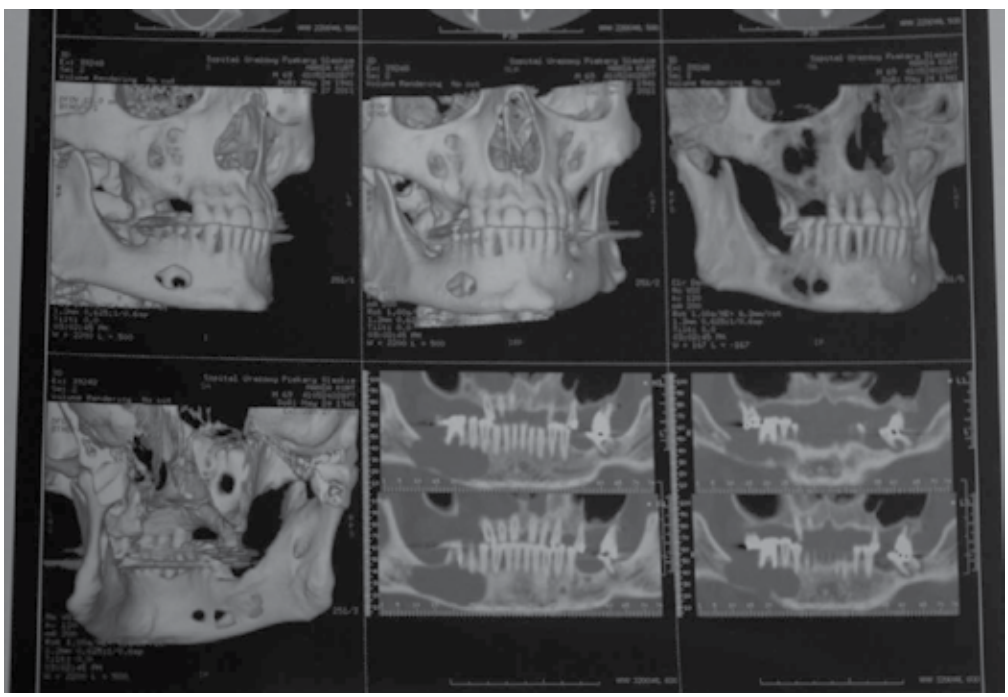

Figure 2. CT scans of a large cyst in the right mandible.

http://dx.doi.org/10.5772/53859

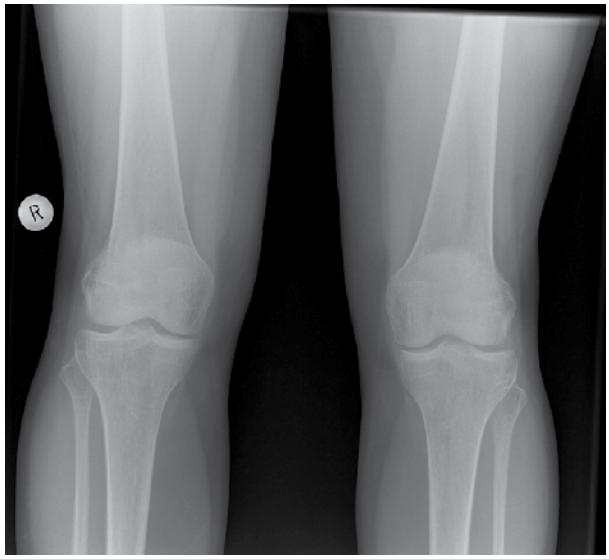

Figure 3. The P-A view of knee joints.

Figure 4. A lateral view of a knee joint.

6. Surgical technique for harvesting cancellous bone from the proximal tibia via medial access

The tibia is a long bone, at the proximal end of which there are two condyles: medial and lateral. Between the condyles there is an intercondylar eminence limited on the sides by two intercondylar protuberences - medial and lateral. Both condyles are surrounded by vertically falling margo infraglenoidalis, below which tibial tuberosity is located at the front [10]. Tibial tuberosity is palpable, and defining its location is essential to avoid damaging the articular surface of a knee joint during the procedure. The patellar tendon, under which small branches of the upper and lower medial popliteal artery run, is attached to the proximal part of the tibial tuberosity. The tibialis anterior muscle is located on the lateral surface of the tibia below the preparation line which is necessary for proper access to the proximal base [10].

The procedure for harvesting cancellous bone from the proximal tibia can be carried out under general anesthesia or sedation. The skin around the knee and proximal part of the shin should be washed with antiseptics and the surgical field should be protected with sterile drapes. Medial access is possible via a skin incision 2-3 cm long 2 cm below and 2 cm medial from the anterior tibial tuberosity (Fig. 5).

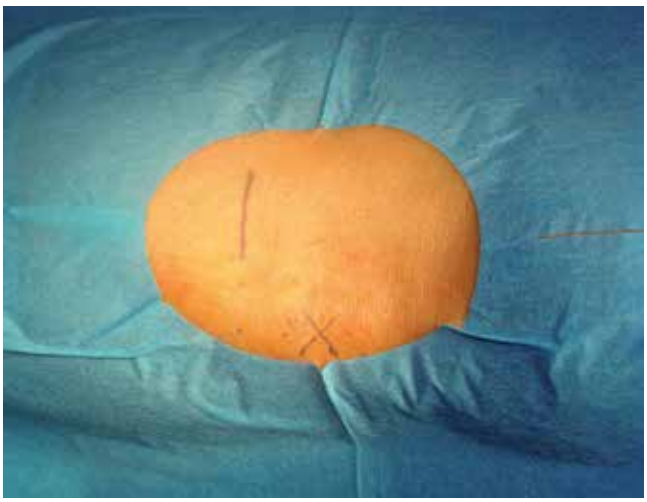

Figure 5. 2-3 cm long incision is run 2 cm below and 2 cm medial to the anterior tibialis tuberosity.

The incision site is injected with 2 cc of 2% lignocaine with noradrenaline (1:80000) down to the periosteum. The incision is performed with blade no.10 through all the layers to the periosteum. Then the periosteum is reflected with a raspator in a way that allows free access to the medial surface of the proximal base. Soft tissues are retracted with Langenbeck retractors. The opening in the cortical plate of the tibia is performed using a trephine 8mm in diameter mounted on a surgical handpiece at 120 revolutions per minute with copious sterile saline irrigation (Fig. 6).

http://dx.doi.org/10.5772/53859

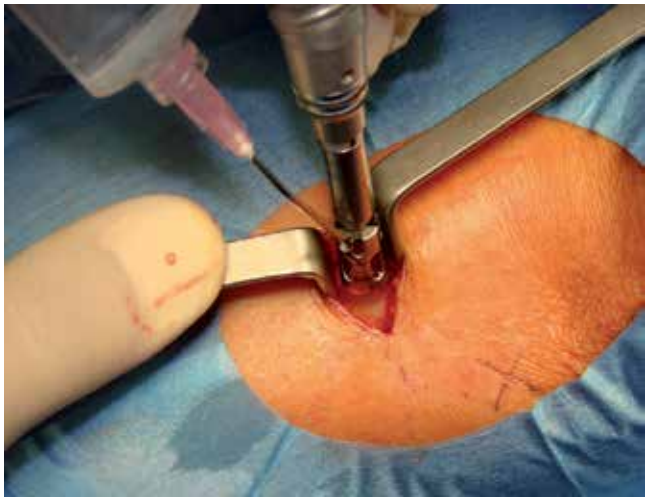

Figure 6. An opening in the cortical bone of tibia is made with a trephine 8 mm in diameter mounted on a surgical handpiece.

Then, through the opening straight and angled bone curettes of various sizes are used to mobilize cancellous bone. The curettes are not used to extract cancellous bone, but to separate cancellous bone from compact bone. A bone collector mounted on a surgical suction is used to extract cancellous bone (Fig. 7).

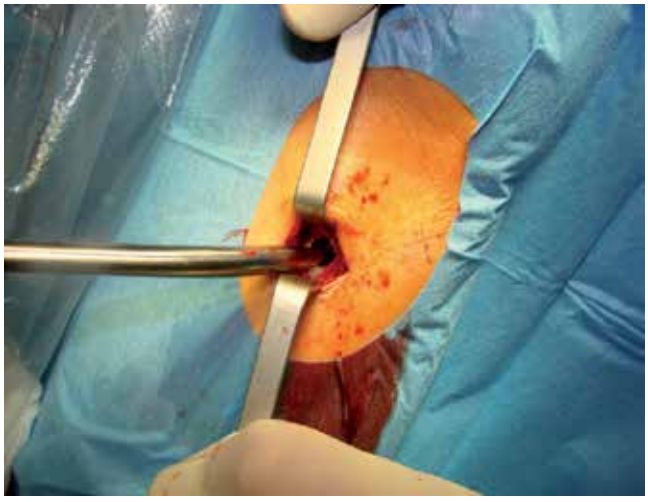

Figure 7. Cancellous bone from tibia is captured and removed with a bone collector connected to a suction.

In order to easily isolate fragments of cancellous bone extensive flushing with saline is performed through the opening. The procedure is performed until the moment when it is not possible to extract larger amounts of cancellous bone from the proximal base with manual

instruments. Then a final flushing is performed with sterile saline solution, which is suctioned from the inside of the proximal base of the tibia using suction. The wound is closed in three layers. The periosteum is sutured using 3-0 absorbable sutures, subcutaneous tissue is sutured with 4-0 absorbable sutures. Skin is sutured with continuous intradermal suture using 5-0 nylon thread (Fig. 8). A sterile lint dressing is applied directly on the wound.

Figure 8. The skin wound is closed with intradermal nylon sutures.

Considering the extent of the surgery in the oral cavity patients are often candidates for surgical treatment under general anesthesia with endotracheal intubation through the mouth. In each surgery two surgical teams take part and they consist of the lead surgeon and an assistant. The task of one team is to harvest cancellous bone from the tibia, while the other team performs the intraoral cyst enucleation (Fig. 9) and places the harvested cancellous bone from the tibia in the post-cystectomy cavity (Fig. 10).

The surface of the transplanted cancellous bone in patients should be covered via the mucoperiosteal flap without damaging the periosteum and the flap must not require elongation, should directly cover the flap and the wound must be completely sutured with nylon sutures. In patients, in whom the mucoperiosteal flap requires elongation by undercutting the periosteum, the surface of cancellous bone is additionally covered with a membrane treated by platelet-rich plasma-derived fibrin clot (PRF) according to the methodology described by Choucroun et al. [11] (Fig. 11).

7. Post-operative care

Directly after the surgery the shin from the foot to the knee is wrapped in an elastic bandage. An elastic pressure dressing is held on the shin for 7 days. Antibiotics and non-steroid

http://dx.doi.org/10.5772/53859

anti-inflammatory drugs are administered to patients, taking into consideration their general health and the extent of the surgery on the donor site. At afternoon hours on the day of the surgery patients are encouraged to walk. However, avoiding direct pressure on the operated limb, jumps, running the stairs, climbing a ladder, etc. is admissible 3 months after surgery. Control knee radiographs are taken after the surgery in order to confirm the accuracy of the opening in the cortical plate and to exclude possible fractures and infractions of the cortical plate (Fig. 12).

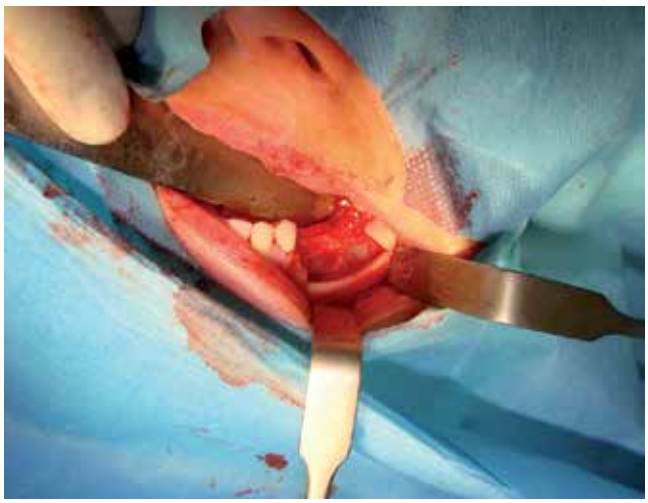

Figure 9. Cyst completely removed by an intraoral approach.

Figure 10. Bone cavity after cystectomy is filled with cancellous bone autograft.

Figure 11. The cancellous bone graft is covered with PRF membranes.

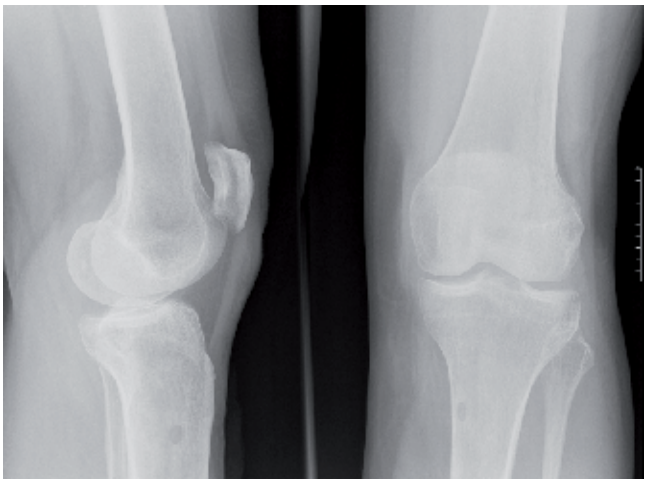

Figure 12. The P-A and lateral views of a knee joint taken after the harvesting procedure.

Sutures are removed between the 7th and 10th day after surgery. Hospitalization period depends on the extent of the surgery intraorally and healing of the recipient site. Considering the donor site, patients do not require post-operative hospitalization and they can be discharged on the day of the surgery.

Patients have out-patient control appointments after 7 days, 3 weeks, 3 months and 6 months after surgery. Besides clinical examinations, the appointment after 6 months includes the OPG X-ray in order to radiologically assess the healing of the bone cavity (Fig. 13).

http://dx.doi.org/10.5772/53859

Figure 13. The OPG of a grafted cavity after cystectomy taken 6 months postoperatively. Total regeneration of the grafted cavity can be observed.

8. Discussion

Numerous treatments in maxillofacial surgery require autogenous bone grafts in order to fill bone cavities of the jaws. These treatments include reconstructive surgeries of clefts, post-cancer defects and post-cystectomy defects. In the literature numerous donor sites are offered, including calvarium, symphysis of the mandible, ribs, iliac crest and tibia [12]. In clinical situations, in which it is necessary to use mechanical properties of cortical bone tissue, bone blocks which consist exclusively of cortical bone or cortical bone and cancellous bone are used. Plates of cortical bone undergo slower resorption than cancellous bone, however they include fewer cellular elements, and the process of osteogenesis shows slower dynamics [13]. Cancellous bone offers a significant pool of living pluripotent cells allowing osteogenesis, osteoinduction and osteoconduction [14]. Therefore in case of bone cavities with the geometry which allows filling with *inlay* techniques, surgeons prefer cancellous bone grafts. The majority of post-cystectomy cavities in the mandible belong to the category of such bone cavities. Choosing a donor site of the graft, expected amount and quality of harvested bone tissue should be taken into consideration, as well as the smallest possible post-operative discomfort for patients, difficulties in walking during the post-operative run, the length of necessary hospitalization period, possibility of early and late complications, as well as skills and preferences of the operator [12]. The area of the proximal base of the tibia has been used as a donor site in orthopedic surgery for many years [15, 16]. A while later attention was brought to the tibia as a donor site of cancellous bone for the needs of cranio-

maxillofacial surgery, especially in the case of palate clefts and filling osteotomy gaps [17]. Since then harvesting surgical technique has been undergoing constant development and its aim is the smallest possible loss of cortical bone plate of the tibia [18] and saving the zone of growth in children [19].Surgical access to cancellous bone in the proximal base of the tibia can be obtained from the lateral surface of the bone with vertical skin incision running along the medial edge of anterior tibialis muscle below the tibial tuberosity [20] and via medial access through a skin incision running 2cm below and 2cm medially from tibial tuberosity [11]. The author of this chapter prefers medial access due to a lower number of described complications of this procedure. The medial surface of the tibia is located in this area directly under the skin. Access to the bone is obtained by an incision conducted concomitantly through all layers – skin, poorly developed subcutaneous tissue and periosteum. This way the risk of damaging muscles and larger blood vessels or nerves is reduced.

Average volume of cancellous bone obtained by different authors ranges from 10-42 cc [15, 17, 19]. Our own experiences indicate that in operated patients it was possible to obtain slightly smaller volumes of cancellous bone – from 8 to 21 cc (Fig. 14). However, in all operated patients the volumes obtained allowed filling of post-cystectomy cavities to a satisfactory degree. It should be pointed out that while planning the surgical treatment it must be considered that the amount of harvested bone from one limb may be insufficient and not possible to foresee pre-operatively. Therefore it is recommended to obtain patient consent to harvest bone from both tibias before the surgery [20, 21].

In the literature a very small percentage of early complications at the donor site (from 0 to 1.9%) draws attention; the complications include mostly impaired cutaneous wound healing, bleeding, severe postoperative pain and difficulty in walking manifested as limping [15, 22]. In the group of patients operated by the author no early or late complications in the donor site were observed. There are a few reports regarding a possibility of fractures of the tibia in patients in whom cancellous bone of the proximal base was harvested [20, 23]. Hughes and Revington [20] report an occurrence of this complication in 2 of the 75 operated patients [2.7%). Even though we have not observed this complication in our own cases, it is possible that its occurrence is more frequent than it is shown by scientific reports, as many of such fractures can heal themselves without the need for surgical intervention, as suggested by Thor et al. [23]. Relatively short surgery time, short skin incision resulting in a small scar, a possibility to walk on the first day after surgery and short hospitalization period undoubtedly are advantages of cancellous bone graft from the base of the proximal tibia [17, 19-21, 24, 25]. All patients operated by the author are encouraged to walk in a few hours after the cystectomy which includes filling the cavity with cancellous bone from the base of the proximal tibia. The majority of the patients do not require any help in walking (crutches or walking stick) on the day of the surgery. However patients are recommended to avoid excessive pressure on the operated limb, such as running, jumping or climbing a ladder for 3 months. Contact sports are also discouraged in this period. [20, 21]. It should be pointed out that considering the process of wound healing in the donor site, patients could be released home on the first post-operative day. The hospitalization period of some patients lasts between 5-8 days dictated by the extent of the intraoral wound after the cystectomy. It should

http://dx.doi.org/10.5772/53859

be highlighted that at the donor site a good esthetic result in the form of a small linear scar visible on the shin is obtained (Fig. 15).



Figure 14. Harvested cancellous bone.

Figure 15. The skin scar 6 months postoperatively.

9. Summary

Previous experience and available literature allow it to be concluded that cancellous bone graft from the base of the proximal tibia via medial access is a relatively safe surgical technique which can be especially recommended when significant volumes of cancellous bone are needed to fill the recipient site. Relatively short surgery time, short skin incision resulting in an esthetically acceptable scar, a possibility to walk on the first day after surgery and short

hospitalization period make this surgical technique an attractive alternative for different donor sites. Using cancellous bone graft from the base of the proximal tibia in order to fill post-cystectomy cavities significantly contributes to the reduction of complications in treating large mandibular cysts with a method of complete enucleation and may lead to a significant acceleration of bone tissue regeneration at the recipient site.

Author details

Piotr Malara[1,2]

1 Department for Oral and Maxillofacial Surgery, DENTARIS Medical Centre, Ruda Slaska, Poland

2 Institute of Engineering Materials and Biomaterials, Silesian University of Technology, Gliwice, Poland

References

[1] Block M.S., Kent J. N.: Sinus augmentation for dental implants: The use of autogenous bone. J. Oral Maxillofac. Surg. 1997; 5: 1281-1286.

[2] Moy P.: Clinical experience with osseous site development using autogenous bone, bone substitutes and membrane barriers. Oral Maxillofac. Surg. Clin. North Am. 2001; 13: 493-509.

[3] Hollinger J. O., Wong M. E. K.: The integrated processes of hard tissue regeneration with special emphasis on fracture healing. Oral Surg. Oral Med. Oral Pathol. 1996; 82: 594-606.

[4] Fonseca R. J., Clark P. J., Burkes E. J., Baker R. D.: Revascularization and healing of onlay particulate autologous bone grafts in primates. J. Oral Maxillofac. Surg. 1980; 38: 572-577.

[5] Citardi M. J., Friedman C. D.: Nonvascularized autogenous bone grafts in the treatment of the resorbed maxillary anterior alveolar ridge: Rationale and approach. Implant Dent. 1998; 7: 169-176.

[6] Chiapasco M., Allessandro R., Motta J. J., Crescentini M.: Spontaneous bone regeneration after enucleation of large mandibular cysts: A radiographic computed analysis of 27 consecutive cases. J. Oral Maxillofac. Surg. 2000; 58: 942-948.

[7] Nakamura N., Mitsuyasu T., Mitsuyasu Y., Taketomi T., Higuchi Y., Ohishi M.: Marsupialization for odontogenic keratocyst: long-term follow-up of the effects and changes in growth characteristics. Oral Surg. Oral Med. Oral Pathol. Oral Radiol Endod. 2002; 94: 543-553.

[8] Enislidis G., Fock N., Sulzbacher I., Ewers R.: Conservative treatment of large cystic lesions of the mandible: a prospective study of the effect of decompression. Br. J. Oral Maxillofac. Surg. 2004; 42: 546-550.

[9] Etzias A., Sugar W.: Pathological fractures of the mandible: a diagnostic and treatment dilemma. Br. J. Oral Maxillofac. Surg. 1994; 32: 302-307.

[10] Herford A. S., Brett J. K., Audia F., Becktor J.: Medial approach for tibial bone graft: Anatomic study and clinical technique. J. Oral Maxillofac. Surg. 2003; 60: 358-363.

[11] Chounkroun J., Diss A., Simonpieria A., Girard M. O., Schoeffler C., Dohan S. L.: Platelet-rich fibrin (PRF): a second-generation platelet concentrate. Part IV: clinical effects on tissue healing. Oral Surg. Oral Med. Oral Pathol. Oral Radiol. Endod. 2006; 101: 56-60.

[12] Rawashdeh M. A., Telfah H.: Secondary alveolar bone grafting: the dilemma of donor site selection and morbidity. J. Oral Maxillofac. Surg. 2008; 46: 665-670.

[13] Ozaki W., Buchman S. R.: Volume maintenance of onlay bone grafts in the craniofacial skeleton: micro-architecture versus embryologic origin. Plast. Reconstr. Surg. 1998; 102: 291-299.

[14] Silva R. V., Camili J. A., Bertran C. A., Moreira N. H.: The use of hydroxyapatite and autogenous cancellous bone grafts to repair bone cavities in rats. Int. J. Oral Maxillofac. Surg. 2005; 34: 178-184.

[15] O'Keefe R. M., Reimer B. L., Butterfield S. L.: Harvesting of autogenous cancellous bone graft from the proximal tibial methaphysis: a review of 230 cases. J. Orthop. Trauma 1991; 5: 469-474.

[16] Alt V., Nawab A., Seligson D.: Bone grafting from the proximal tibia. Trauma 1999; 47: 555-557.

[17] Ilankovan V., Stronczek M., Telfer M., Peterson L. J., Stassen L. F. A., Ward-Booth P.: A prospective study of trephined bone grafts of the tibial shaft and iliac crest. Br. J. Oral Maxillofac. Surg. 1998; 36:434-439.

[18] Hashemi H. M.: Oblique use of a trephine bur for the harvesting of tibial bone grafts. Br. J. Oral Maxillofac. Surg. 2008; 46: 690-691.

[19] Belsy W., Ward-Booth P.: Technique for harvesting tibial cancellous bone modified for use in children. Br. J. Oral Maxillofac. Surg. 1999; 37: 129-133.

[20] Hughes C. W., Revington P. J.: The proximal tibia donor site in cleft alveolar bone grafting: experience of 75 consecutive cases. J. Cranio Maxillofac. Surg. 2002; 30: 12-16.

[21] Chen Y. C., Chen C. H., Chen P. L., Huang I. Y., Shen Y. S., Chen C. M.: Donor site morbidity after harvesting of proximal tibia bone. Head Neck 2006; 28: 496-500.

[22] Catone G. A., Reimer B. L., McNeir D., Ray R.: Tibial autogenous cancellous bone as an alternative donor site in maxillofacial surgery: a preliminary report. J. Oral Maxillofac Surg. 1992; 50: 1258-1263.

[23] Thor A., Farzad P., Larsson S.: Fracture of the tibia: Complication of bone grafting to the anterior maxilla. Br. J. Oral Maxillofac. Surg. 2006; 44: 46-48.

[24] Kalaaji A., Lilja J., Elander A., Friede H.: Tibia as donor site for alveolar bone grafting in patients with cleft lip and palate: long-term experience. Scand. J. Plast. Reconstr. Surg. Hand Surg. 2001; 35: 35-42.

[25] Walker T. M. W., Modayil P. C., Cascarini L., Williams L., Duncan S. M., Ward-Booth P.: Retrospective review of donor site complications after harvest of cancellous bone from the anteriomedial tibia. 2009; 47: 20-22.

Chapter 7

Keratocystic Odontogenic Tumors – Clinical and Molecular Features

Miroslav Andrić, Božidar Brković, Vladimir Jurišić, Milan Jurišić and Jelena Milašin

Additional information is available at the end of the chapter

http://dx.doi.org/10.5772/53855

1. Introduction

Keratocystic odontogenic tumors (KCOTs) are certainly among the most studied lesions in oral pathology, which is not a surprise considering their perplexing clinical behavior and complicated mechanism of pathogenesis. In fact, the specific KCOT features are the reason for numerous discussions regarding the true nature and classification of these lesions, which are still debated in the scientific community.Until recently these lesions were known as odontogenic keratocysts (OKCs), a term first used by Philipsen in 1956. In the beginning, the term was used to describe any jaw cyst in which keratin was formed. However, it became obvious that some other types of jaw cysts, such as radicular and residual cysts, may exhibit keratinization as well, leading to the conclusion that specific histological features of OKCs and not solely the presence of keratin, should be used to distinguish these lesions from other cysts of the jaws [1]. Researchers soon realized that OKCs show aggressive clinical behavior and high recurrence rates, features which are not typical for other odontogenic cysts [2]. Besides that, it has been noted that OKCs are among the most prominent feature of Nevoid Basal Cell Carcinoma Syndrome (NBCCS), also known as Gorlin-Goltz syndrome. Finally, numerous studies have shown that genetic factors are predominant in etiology of these lesions and that some mechanisms of pathogenesis, typical for neoplastic lesions, are also involved in formation of OKCs [3]. Therefore, in 2005 these lesions were reclassified as Keratocystic Odontogenic Tumors (KCOTs) and defined as benign, odontogenic, uni- or multicystic intraosseous tumors, with characteristic parakeratinized squamous epithelium lining, having a potential for aggressive and infiltrative growth [4]. However, since KCOTs also exhibit some cysts-like features, including response to decompression [5], the tumoral

INTECH
open science | open minds

© 2013 Andrić et al.; licensee InTech. This is a paper distributed under the terms of the Creative Commons Attribution License (http://creativecommons.org/licenses/by/3.0), which permits unrestricted use, distribution, and reproduction in any medium, provided the original work is properly cited.

nature of this lesion remains the subject of debate among investigators. Herein, we present the diagnosis and treatment modalities of this lesion.

2. Prevalence

In a broad range of scientific publications it has been stated that KCOTs represent about 10% of all jaw cysts [6]. As a matter of fact, scientific data on incidence of KCOTs are very heterogeneous, which actually reflect differences in diagnostic criteria and sample selection in individual studies. For example, in some studies distinction between ortho- and parakeratinized lesions has not been made, which is an important issue, since nowadays it is believed that orthokeratinized cysts do not exhibit features of KCOTs and should not be considered as a part of the KCOTs spectrum [6,7]. According to data from South Africa, the annual incidence in the Caucasian population is 4.86 per million for men and 3.5 per million for women [8].

Around 40% to 60% of all KCOTs are diagnosed in patients in their 2nd and 3rd decade of life. In some studies, bimodal age distribution has been noted, with highest number of cases in patients aging from 10 to 19 and from 20 to 29 years, just to be followed by another rise in a group of those from 50 to 64 years of life [6]. In an attempt to explain such data, it has been suggested that older population is more susceptible to two independent mutations which are necessary for KCOTs development [9], a view supported by the fact that in NBCC patients KCOTs occur in much younger age than in sporadic cases [10]. The youngest reported patient in the literature was a one and a half year-old girl in whom, during the observation period, no criteria for NBCCS diagnosis had been met [11].

KCOTs are more frequent in men compared to women (1.7:1) [6]. However, in NBCCS, the majority of patients are female (55%), compared to 38% in sporadic cases [10, 12]. Although KCOTs can occur in any part of the jaws, the vast majority of the lesions are located in the mandible, from 69% to 83% of all diagnosed cases [13, 14]. In addition, about half of all KCOTs arise in the region of mandibular angle [6]. However, in patients aging more than 50 years there is a tendency for growing number of KCOTs involving the upper jaw [15]. Also, sporadic lesions are more common in the angle of the mandible (60% of sporadic and 44% of syndromic lesions), while in the posterior parts of the upper jaw the majority of lesions are related to NBCCS (21% of syndromic vs. 11% of sporadic KCOTs) [10, 12].

3. Etiology and pathogenesis

It is widely accepted that KCOTs originate from odontogenic epithelium. Remnants of dental lamina, and also proliferations of the basal cell layer of oral epithelium, are considered as possible sources of epithelial cells which may proliferate to form a KCOT [6]. In a recent study on keratin profiling in KCOTs, it was demonstrated that similar keratins (17 and 19) are expressed both in KCOTs epithelial cells and in the cells of dental lamina in rats, sup-

http://dx.doi.org/10.5772/53855

porting the theory that KCOTs arise from its remnants [16]. On the other hand, there are opinions that the main source of epithelial cells required for KCOT formation is derived from basal cells of oral epithelium, which proliferate into the deeper tissues and form microcysts, suggesting that KCOTs should be considered as hamartomas [17]. Results of studies, showing that the highest number of microcysts and epithelial islands are located in parts of KCOTs walls which are in direct contact with oral mucosa are in agreement with such an opinion [18]. Also, proliferations of basal epithelial cells of oral mucosa into the subepithelial mucosal layer were identified in NBCCS patients, further supporting this possibility [17]. Still, since both types of epithelial cells share a common embryogenic origin and are subject to common inductive influences, it has been suggested that these two theories should not exclude one another [19].

3.1. Genetic factors in pathogenesis of KCOTs

Regardless of the source of epithelial cells, the etiology of KCOTs is strongly related to genetic factors, in particular to mutation of tumor-suppressor PTCH gene, which is an important part of Sonic hedgehog (SHH) signaling pathway. The PTCH gene encodes PTCH transmembrane protein, which, together with SMO (smoothened), forms a receptor for SHH ligands and suppresses SMO mediated transcription of cellular proliferation genes. Therefore, lack of PTCH function results in increased transcription of genes responsible for cell proliferation and, ultimately, in tumor formation.

Evidence of PTCH gene mutations in KCOTs came from studies of genetic basis of NBCC syndrome. Levanat and co-workers showed that frequency of allelic loss in 9q22 chromosome (where PTCH gene has been mapped) is significantly higher in syndromic compared to sporadic lesions and concluded that inactivation of NBCC syndrome gene represents an important step in pathogenesis of KCOTs [20]. However, mutations of PTCH gene were identified in samples of KCOTs from both syndromic and sporadic cases. In an analysis of expression of SHH pathway components in KCOTs, mutations of PTCH gene were detected in 3 out of 5 sporadic and 4 out of 4 recurrent KCOTs [21]. It is of interest that, in the study from Baretto and co-workers, mutation identified in sporadic KCOTs has not been present in constitutional DNA of the affected individual [22]. Such results supported opinions of Lench and colleagues that in NBCCS patients one mutation is already present in germ line and only one more mutation in somatic cells is required to cause homozygous inactivation of PTCH gene and KCOTs formation. In contrast to this, in sporadic cases two independent mutations in somatic cells are required [23]. Nevertheless, in subsequent studies it was suggested that KCOTs may also occur in cases of PTCH gene haploinsufficiency i.e. loss of only one allele. As a matter of fact, in samples of KCOTs in whom PTCH gene mutations were detected, immunohistochemical analysis revealed expression of PTCH protein, despite the fact that antibody used in this study could not detect mutant forms of this protein [24].

Once mutations in PTCH gene have occurred, KCOTs may become targets of additional genetic alterations, facilitating tumor progression. In an analysis of loss of heterozygosity (LOH) for several tumor-suppressor genes in sporadic KCOTs, frequency of allelic loss was 66% for p53 and 60% for PTCH gene. It is of particular interest that relationship between

these mutations and presence of satellite microcysts in KCOT walls was established [25]. In a similar fashion activation of *H-ras* oncogene in KCOTs was demonstrated [26]. Also, recent study indicated that alterations in *BIRC5* gene, encoding antiapoptotic protein survivin, may contribute to the pathogenesis of KCOTs. It was shown that GG homozygotes of 31G/C survivin promoter gene polymorphism are at significantly higher risk for development of KCOT compared to other genotypes of this polymorphism [27]. At this point, it may be appropriate to notice that the growing body of evidence for strong involvement of genetic defects in pathogenesis of KCOTs support the opinion of the tumoral nature of these lesions. According to Barreto and colleagues, as loss of function of tumor-suppressor gene (PTCH gene) is by definition characteristic of a neoplasm, KCOTs should be considered benign cystic tumors [22].

3.2. Cell proliferation and apoptosis

Besides genetic factors, numerous studies suggest that dysregulation of cell cycle and proliferation may be important for KCOT pathogenesis. It is believed that KCOTs show increased cell proliferation rates and that such a phenomenon may be related to its aggressive growth.

PCNA (*Proliferating Cell Nuclear Antigen*) is a protein which is expressed in the nucleus of replicating cells. It is considered to be a marker of cell replication, but also may be expressed during DNA repair process and under the influence of several growth factors [28]. In a sample of 11 OKCs and 10 periapical and dentigerous cysts, the highest number of PCNA positive cells was identified in the suprabasal epithelial layer of KCOTs, suggesting that these lesions have higher proliferative activity compared to periapical and dentigerous cysts [29]. In addition, it was demonstrated that PCNA expression was more pronounced in syndromic compared to sporadic KCOTs [28].

Similar to this, in the study of Li and colleagues, Ki-67, another marker of cell replication, was significantly more expressed in KCOTs compared to other types of odontogenic cysts, and again, its expression was stronger in syndromic vs. sporadic lesions [30]. It is of interest that correlation of PCNA and Ki-67 expression was observed, in particular regarding localization of positive cells and confirming that suprabasal epithelial layer contains the highest number of actively proliferating cells.

Another process, which plays a crucial role in maintaining tissue homeostasis, is apoptosis or "programmed cell death". This process is critically important for embryogenic development and aging, but also acts as a defense mechanism, once irreparable damage to the cell has occurred. Lack of apoptosis is a common feature of many tumors [31]. Therefore, it is not surprising that numerous studies investigated whether dysregulation of apoptosis may be implicated in pathogenesis of KCOTs.

Extensive research has focused on protein p53 and its role in these lesions (Figure 1).

It is a product of TP53 tumor-suppressor gene and is capable to arrest cell cycle and induce apoptosis. Mutations of TP53 gene were identified in more than a half of all human malignancies. Also, over expression of p53 protein is very typical for malignant tumors. As a matter of fact, increased p53 expression in KCOTs, compared to other jaw cysts, was

http://dx.doi.org/10.5772/53855

demonstrated in several studies [32-35], but also, it was shown that level of expression in KCOTs was lower than in squamous cell carcinomas of the oral cavity [32, 35]. Since they were unable to identify mutations of TP53 gene in their sample, Li and co-workers concluded that over expression of p53 in KCOTs is not a result of mutation, but overproduction and stabilization of "normal" p53 [32]. In contrast to this, in another study, loss of heterozygosity for TP53 was detected in 66% of KCOTs [25]. Also, using Pab 244 antibody, which selectively recognizes mutant p53 protein, p53 reactivity was detected in 12 out of 78 KCOTs (15.4%), suggesting that mutations of TP53 gene may be important for pathogenesis of KCOTs [36]. In the same study, correlation between expression of mutant p53 and epithelial dysplasia was established.

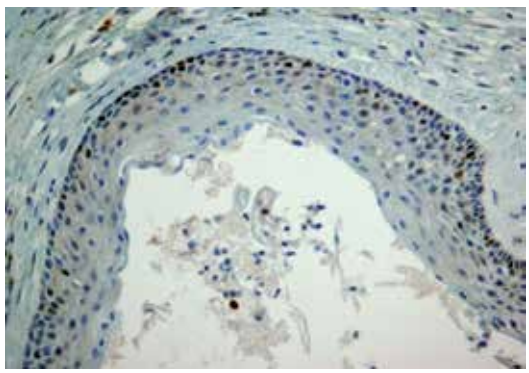

Figure 1. Immunohistochemical staining of KCOT wall for p53. Nuclear expression of p53, predominantly in the basal epithelial layer.

Antiapoptotic protein bcl-2, commonly detected in malignant tumors of the oral cavity [37], was also detected in KCOTs. Its expression was demonstrated in several studies, mostly in the cells of basal epithelial layers, indicating that inhibition of apoptosis may be implicated in development of KCOTs [38, 39]. In contrast to this, epithelial cells of dentigerous cysts have not showed bcl-2 positivity [40]. In the same study, expression of p53, Ki-67, bcl-2 and presence of TUNEL positive cells was investigated. TUNEL *(Terminal deoxynucleotidyl transferase dUTP nick end labeling)* positivity is typical for cells in which apoptotic process was initiated and may be considered as a marker of apoptotic activity. In agreement with previous studies, bcl-2 was expressed in basal cells of epithelial layers; suprabasal cells showed expression of p53 and Ki-67 and TUNEL positive cells were detected in superficial epithelial cells. Based on these results, authors concluded that there is relative balance between cell proliferation and apoptosis in KCOTs, which is the reason why they are formed as cystic instead of solid lesions, despite high proliferative activity of their cells [40]. Recently, expression of another apoptotic protein, survivin, was demonstrated in KCOTs [41, 42] (Figures 2 and 3).

This protein, product of *BIRC5* gene, acts as an inhibitor of apoptosis, but also stimulates cell proliferation and angiogenesis. Its over-expression is a common feature of many malignant neoplasms. It was shown that survivin expression is much more pronounced in KCOTs

compared to periapical cysts [41], but also that highest numbers of survivin-positive cells were detected in suprabasal epithelial layers [42], which may be expected, having in mind that this part of KCOTs epithelium shows the highest cell proliferation activity. Based on these findings, the authors suggested that inhibition of apoptosis may be important for KCOTs pathogenesis, reinforcing opinions on the tumoral nature of these lesions.

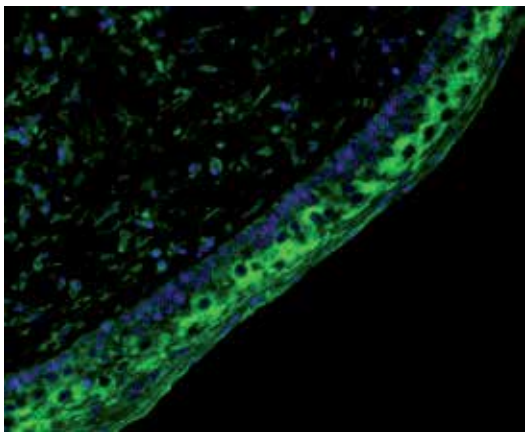

Figure 2. Confocal microscopy of KCOT specimen, exhibiting survivin immunoreactivity in suprabasal epithelial cells.

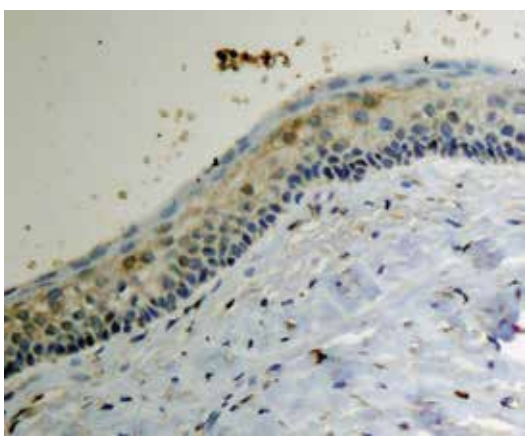

Figure 3. Immunohistochemical staining shows that survivin is expressed in the cytoplasm of suprabasal epithelial cells.

From available literature, it appears that several mechanisms of pathogenesis, otherwise typical for tumor development, are also implicated in formation of KCOTs, supporting re-classification of these lesions into benign odontogenic tumors. The etiology of some other types of odontogenic cystic lesions of the jaws, such are periapical cysts, is closely related to

http://dx.doi.org/10.5772/53855

infective agents [43, 44] and inflammatory stimuli, including production of pro- inflammatory cytokines, TNF-alpha and presence of inflammatory cells within the cystic wall [45]. In contrast, KCOTs show lower concentrations of pro-inflammatory cytokines, including TNF-alpha [46], which suggests that these types of reactions are not crucial for the development of KCOT.

4. Clinical features

KCOTs are benign but locally aggressive lesions with high propensity to recur following surgical treatment. Aggressive growth within the jaws, tendency to invade surrounding anatomical structures and occasional malignant alteration are features which distinguish KCOTs from other types of odontogenic tumors. Yet, the majority of KCOTs are asymptomatic until they reach a significant size. If symptoms are present, most of the patients will complain on swelling, pain and discharge of cystic fluid into the mouth (Figures 4 and 5).

Figure 4. Painless swelling of the left mandible in a patient with KCOT.

Figure 5. Panoramic radiograph of the same patient. Multilocular radiolucency of the left mandibular body.

Occasionally, involvement of the inferior alveolar nerve may result in paresthesia of the lower lip. Secondary infection of the lesion will result in signs of acute inflammation.

KCOTs tend to grow relatively fast within medullary bone, while bony expansion becomes clinically evident only when a lesion reaches large size, which is a fact that contributes to late diagnosis [47]. Still, aggressive growth of KCOTs is illustrated by numerous case reports of these lesions with unusual clinical presentation. Involvement of the maxillary sinus and floor of the orbit may result in proptosis as a first clinical sign indicating tumor presence [48, 49]. Also, penetration into surrounding soft tissues [50], orbit and infratemporal fossa [51, 52] and even involvement of the skull base [53] have been reported. In 7% to 12.5% of patients more than one KCOT are diagnosed [47]. Since multiple KCOTs are among the most constant features of NBCC syndrome, whether they occur in patients not affected by this syndrome remains the subject of debate. Woolgar and co-workers suggested that multiple OKCs should be considered as manifestation of the syndrome in which other features are so mild that diagnostic criteria cannot be met [10, 12].

While the vast majority of KCOTs occur within the jawbones, a peripheral variant of this lesion, occurring in gingiva, is a well recognized phenomenon. These lesions are termed *peripheral odontogenic keratocysts* [54]. Immunohistochemical analysis of peripheral OKCs linings showed same pattern of expression of cytokeratins, p53, PCNA and Ki-67 as in surrounding normal gingiva, but basal epithelial cells of cystic lining showed expression of antiapoptotic protein bcl-2 in contrast to healthy gingival tissue [55]. Although it is believed that peripheral OKCs do not show aggressive clinical behavior typical for central lesions, recurrent cases have been reported in the literature [56]. In addition, two cases of cystic lesions of the buccal mucosa, exhibiting histological features of OKCs, were recently reported, but their odontogenic origin has been questioned, having in mind atypical localization of the lesions. Again, immunohistochemical analysis of obtained samples showed the same pattern of expression of cytokeratins, bcl-2 and Ki-67 as in central and peripheral OKCs, indicating that all these lesions exhibit similar immunophenotypes [57].

Finally, reports on intraosseous solid lesions, exhibiting histological features of KCOTs but devoid of cystic cavity, added a new entity to the spectrum of KCOTs – *solid keratocystic odontogenic tumors.* First reports on this new entity were published in 2002 and 2004, describing a multilocular lesion of posterior maxilla which, on histological examination, revealed numerous microcysts with typical histological features of KCOTs, surrounded by supporting connective tissue [58, 59]. Even more intriguing was a report of an KCOTs which recurred several times, gradually changing its histological presentation from typical KCOTs to a solid tumoral lesion [60]. This kind of presentation completes the spectrum of KCOTs– from soft tissue lesions to cystic and solid intraosseous tumors, supporting opinions on its neoplastic nature, similar in fashion to dentinogenic ghost cell tumors and calcifying odontogenic cysts [61].

4.1. Recurrence

Besides aggressive growth within the jawbones, another astonishing feature of KCOTs is a remarkably high incidence of recurrence following surgical treatment. Reported recurrence rates vary from 3% up to 62% [62, 63]. Such discrepancies in reported results may be contributed to

http://dx.doi.org/10.5772/53855

different duration of follow-up periods and wide range of surgical techniques used to treat these patients. In a classic study from Browne, in a sample of 85 OKCs, recurrence occurred in 25%, most of them within five years following cyst removal [14]. The importance of adequate follow-up was demonstrated by Forssell and colleagues, by the fact that only 3% of KCOTs recurred within the first postoperative year, but after three years recurrence rate rose to 37% [64]. In another study from Korea, out of 132 lesions, treated by enucleation alone, recurrences were diagnosed in 58.3% of cases, including 11.7% multiple recurrences [65].

The fact is that the exact reason for this phenomenon is not completely understood. The most obvious explanation is that during enucleation parts of KCOTs lining are left in place, which may be expected for lesions with thin and vulnerable walls. As an argument for such a hypothesis, it was shown that recurrences are more common in KCOTs which are removed in several pieces, but also in multilocular lesions and lesions which had perforated the cortical bone [64]. Still, well-documented reports of recurrences occurring sixteen or even twenty years after the initial surgery [14, 18] suggest that this cannot be accepted as the only explanation for this phenomenon. Therefore, three possible mechanisms responsible for KCOTs recurrences were proposed: Incomplete removal of the lesions during the surgery, formation of satellite microcysts within the cystic lining and development of new lesions from epithelial off-shoots of the basal layer of the oral epithelium [62]. Several studies supported this opinion. In an analysis of 72 primary, 11 recurrent and 9 syndromic OKCs, proliferations of basal cells of cystic epithelium were recorded in 45% of recurrent and 44% of syndromic lesions, in contrast to only 8% of primary KCOTs. Satellite microcysts were noted in 78% of syndromic, 18% of recurrent and 4% of primary lesions [66]. Similarly, it has been shown that occurrence of microcysts and basal cells proliferations is significantly more common in syndromic (51%) and recurrent (53%), compared to primary KCOTs (17%) [67].The same fact was pointed out by Myoung and co-workers, who found that occurrence of so-called "daughter cysts" is significantly more common in recurrent KCOTs [65].

It is also possible that high recurrence rates are related to KCOTs mechanisms of pathogenesis and that formation of lesions *de novo*, from other remnants of dental lamina, may give rise to development of recurrences [6]. Also, continued proliferation of basal cells of oral epithelium may contribute to recurrence formation, even if entire tumoral lining was removed at initial surgery [17]. Indirect evidence to support this possibility was published describing recurrence of an KCOT in an autogenous bone graft used to reconstruct the mandible after removal of the lesion, indicating that the source of the recurrence was located not in the bone, but in the soft tissues covering the graft [68].

4.2. Malignant transformation

Despite aggressive growth and high recurrence rates, KCOTs are benign lesions. However, cases of malignant transformation and subsequent development of squamous cell carcinomas are documented in the literature [69-71]. These tumors are known as *primary intraosseous odontogenic carcinomas* (PIOC), referring to squamous cell carcinomas arising within the jaws, probably from remnants of odontogenic epithelium. To establish diagnosis of PIOC two principal criteria should be met: absence of initial connection with the overlying mucosa

or skin and exclusion of metastasis from a distant primary tumor during at least a 6-months follow-up period. The most widely used classification of PIOC is the one from Waldron and Mustoe (Table 1).

Type 1	PIOC arising from odontogenic cyst
Type 2	2A - Malignant ameloblastomas 2B - Ameloblastic carcinoma
Type 3	PIOC arising *de novo* a) Keratinizing type b) Nonkeratinizing type
Type 4	Intraosseous mucoepidermoid carcinoma

Table 1. Waldron and Mustoe's classification of odontogenic carcinoma.

Although several other types of odontogenic carcinomas were reported, including clear cell odontogenic carcinoma, odontogenic ghost cell carcinoma and the malignant variant of calcifying epithelial odontogenic tumor, term PIOC is most commonly used for carcinomas arising *de novo* or from odontogenic cysts. Following the recent reclassification of OKCs into odontogenic tumors, in a 2005 WHO classification of head and neck tumors a new entity was included – primary intraosseous squamous cell carcinoma derived from KCOT [4].Still, from available data it does not seem that, compared to other cystic lesions of the jaws, KCOTs have pronounced tendency to malignant alteration. As a matter of fact, in a recent literature review it was demonstrated that majority of PIOCs were related to residual inflammatory cysts. Out of 134 PIOC cases, 82 of type 1 (*ex* odontogenic cysts) and 52 of type III (PIOC *de novo*) were identified. Regarding type 1, as already mentioned, majority of cases arose from residual cysts, followed by dentigerous cysts and KCOTs being in third place [70]. Therefore, although clinicians should be aware of the possibility of malignant transformation of KCOTs, there is no evidence that these lesions should be considered as premalignant.

5. Nevoid basal cell carcinoma syndrome

This syndrome, also known as Gorlin or Gorlin-Goltz syndrome is an autosomal dominant inherited condition which exhibits high penetrance and variable expressivity. The principal genetic defect is mutation in the PTCH gene, which has been mapped to chromosome 9q22.3-q31. As already mentioned, this is a tumor-suppressor gene, which explains why occurrence of different types of tumors is the main clinical feature of this syndrome. This syndrome is diagnosed in 1 out of 60.000 newborns, but data from several studies suggest substantial geographic and demographic differences, with prevalence ranging from 1:56000 to 1:256000 [72]. Gender predilection has not been noted. The most prominent clinical manifestations of NBCCS are occurrence of multiple basal cell carcinomas (BCCs) and KCOTs.

http://dx.doi.org/10.5772/53855

These lesions tend to occur at a much younger age compared to patients with sporadic tumors. Therefore, it is not unusual to see patients with BCCs in their 2nd or 3rd decades or to diagnose multiple KCOTs in children under the age of ten (Figure 6).

Figure 6. Multiple KCOTs in the maxilla and mandible in a 9-year old girl with NBCC syndrome.

Besides these tumors, other common features of the syndrome are ectopic calcifications (e.g. those of falx cerebri), skeletal anomalies (most commonly of the ribs), and typical palmar and/or plantar pits. Some of the patients have characteristic facial features, with enlarged head circumference, frontal and temporal bossing and hypertelorism (Figure 7).

Figure 7. Hypertelorism (left) and frontal bossing (right) are typical facial features of NBCCS.

Diagnosis is based on so-called major and minor diagnostic criteria (Table 2).

Major	Minor
Multiple BCCs or one under the age of 20	Macrocephaly
KCOT (histological verification required)	Cleft lip or palate
Palmar or plantar pits	Frontal bossing
Bilamellar calcification of the falx cerebri	Hypertelorism
Bifid, fused or markedly splayed ribs	Pectus excavatum / carinatum
First degree relative with NBCCS	Syndactyly of the digits
	Radiological abnormalities: bridging of the sella turcica,vertebral anomalies
	Ovarian fibromas
	Medulloblastomas

Table 2. Diagnostic criteria for NBCC syndrome (adapted from ref. [73]).

It is believed that diagnosis of NBCCS may be established if two major or one major and two minor criteria are met. Since most of the lesions associated with the syndrome are not life-threatening prognosis is generally favorable. However, medulloblastomas, malignant tumors of posterior fossa, may occur in about 1% to 2% of the patients, typically during the first two years of life, again in an age significantly younger compared to cases not associated to NBCCS [72]. Although these tumors are usually of desmoplastic type, which is related to better outcomes, early deaths from this kind of malignancy are still possible. NBCCS patients are particularly sensitive to ionizing and UV radiation, so judicious usage of radiographic imaging techniques and constant UV protection of the skin are useful in reducing number of BCCs.

Multiple KCOTs are present in as much as 92% of NBCCS patients [72]. Although it was shown that syndromic KCOTs exhibit a higher number of epithelial proliferations and satellite microcysts within the fibrous wall [66, 12]; it is not possible to reliably differentiate syndromic from sporadic lesions on histological examination. Also, it is not clear whether higher recurrence rates of syndromic *vs.* sporadic KCOTs are truly related to their biological features or simply represent occurrence of new lesions in affected patients. As related to this, some data from the literature suggest that KCOTs in NBCCS patients may exhibit more aggressive phenotype then their sporadic counterparts. In an analysis of PCNA, bcl-2, p53 and bcl-1 (cyclin D1) in syndromic and sporadic KCOTs, Lo Muzio and colleagues observed that PCNA and bcl-2 were equally expressed in both groups, but p53 and bcl-1 expression was restricted solely to syndromic lesions. Based on these findings authors pointed out that KCOTs aggressive clinical behavior could be due to dysregulation of the expression of cyclin Dl and p53 proteins, involved in a check-point control of cellular proliferation [74]. Also, using several cell-cycle and apoptosis-related markers (cyclin D1, p16, Fas, Fas-L, single stranded ss DNA-positive nuclei) Kimi and co-workers concluded that NBCCS-associated KCOTs may be a distinguishable entity from solitary KCOTs [75]. In a similar fashion, it was demonstrated that mast cells values presented by syndromic KCOTs were significantly greater than those of the

http://dx.doi.org/10.5772/53855

sporadic lesions [76]. In conclusion, neither clinical nor histological criteria are reliable for differential diagnosis of syndromic and sporadic KCOTs. However, it was shown that KCOTs in NBCCS patients tend to occur more commonly in the upper jaw, in females and in younger age compared to sporadic cases [10, 12, 15], and diagnosis of KCOT in those groups should prompt the clinician to consider diagnosis of NBCC syndrome.

6. Radiographic features

KCOTs are typically presented as round or ovoid radiolucencies with smooth or scalloped margins. Therefore, three distinct radiographic types are recognized – unilocular, multilocular and multilobular lesions. It has been suggested that multilobular KCOTs with scalloped margins are a result of unequal growth activity in different parts of the tumoral wall [6], but this opinion requires further scientific support (Figure 8).

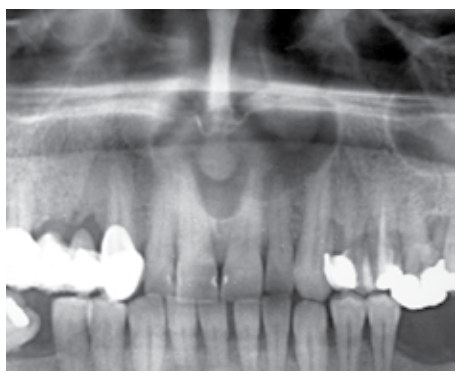

Figure 8. Multilobular KCOT of the anterior maxilla. Such presentation may be suggestive of a nasopalatine cyst.

About one quarter of all lesions exhibit multilocular appearance with bony septa within the lumen, the majority of them being located in the mandible (Figures 9 and 10).

Figure 9. Cone-beam CT of multilocular KCOT involving the right mandibular body and angle. Note lack of cortical expansion in the area of the base of the mandible.

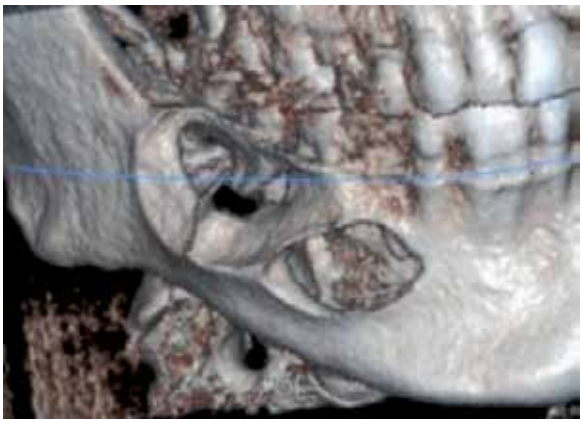

Figure 10. reconstruction of the same lesion in figure 9.

In a series of 135 KCOTs, 25% were of multilocular type [77], all of them in the lower jaw. Also, in 25 to 40% of cases, an impacted tooth is present within the KCOT lumen [7], and such lesions should be distinguished from dentigerous cysts. Actually, in many cases, impaction of neighboring teeth is a result of expansive growth of KCOT; a useful feature to clinically differentiate KCOT from a dentigerous cysts is whether radiolucency is attached to the cementoenamel junction (dentigerous cysts) or encircles entire tooth (KCOT). However, in unilocular variants it may be practically impossible to distinguish between these two types of lesions (Figure 11).

As already mentioned, KCOTs located in the mandibular body rarely result in significant expansion of cortical bone. However, this phenomenon may be very pronounced in the region of the mandibular ramus (Figure 12).

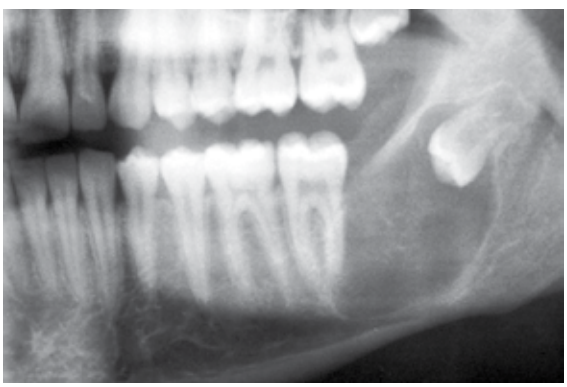

Figure 11. Unilocular radiolucency encircling the crown of impacted third molar. This lesion was beleived to be a dentigerous cyst but histological examination revealed a typical KCOT.

http://dx.doi.org/10.5772/53855

Figure 12. Panoramic radiograph of a KCOT involving left mandibular angle and ramus. Note significant expansion of cortical bone in the ramus region.

Also, it is not uncommon to observe destruction of cortical bone and invasive growth of the lesion into the surrounding soft tissues (Figure 13).

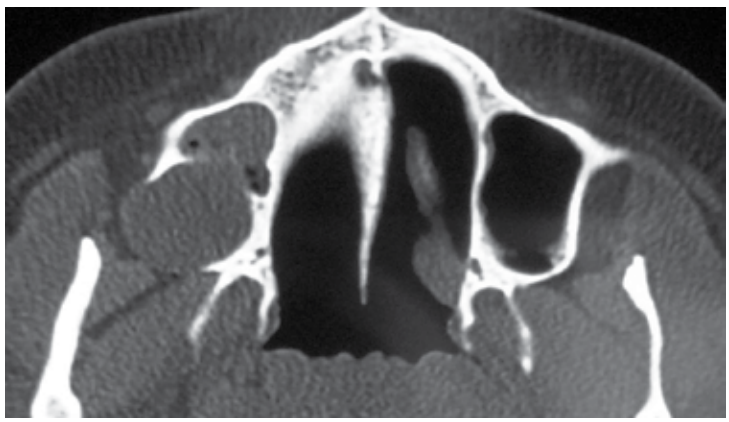

Figure 13. Axial CT scan of a KCOT of the right maxilla. The lesion has occupied the entire maxillary sinus and penetrated the surrounding soft tissues.

Finally, resorption of teeth roots might be observed, although less frequently compared to dentigerous cysts (Figure 14).

Despite the fact that some of described radiographic features may be highly suggestive of KCOT, it was shown that radiographic and histological diagnosis are in agreement in only 25.2% of the cases [65]. However, some of more sophisticated radiographic techniques, including computerized tomography (CT) and magnetic resonance imaging (MRI), may be useful for this purpose. It was shown that in CT scans an area of increased attenuation may be observed in the lumen of KCOTs, being the result of keratin accumulation and having a potential role in diagnosis of these lesions [78]. Also, in an analysis of 21 KCOTs, using T2 MRI sequence, van Rensburg and co-workers were able to establish correct diagnosis in 85% of the cases [79]. In agreement with this, it was shown that MRI may be useful in differentiating KCOTs from ameloblastomas, since T2 relaxation times of cystic components were sig-

nificantly shorter in KCOTs compared to ameloblastomas, and no overlap of these values were observed for these two lesions [80].

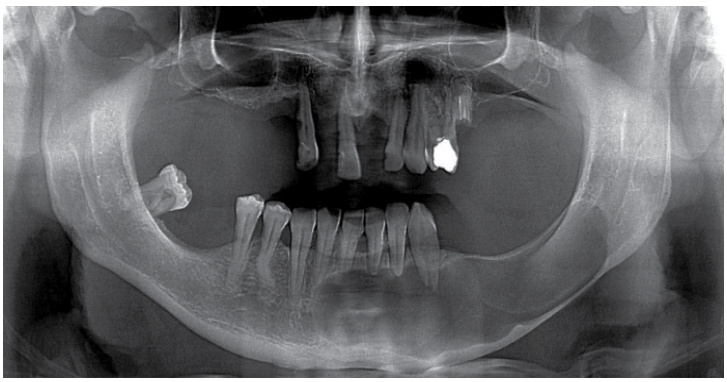

Figure 14. KCOT of left mandibular body causing resorption of the canine root.

Regarding radiographic differential diagnosis, in most of the cases KCOTs should be distinguished from dentigerous cysts and ameloblastomas (Figure 15).

Figure 15. Multilocular radiolucency of the left mandibular body and angle. Significant cortical expansion and extensive resorption of the roots are not typical for KCOT. Histological analysis of biopsy specimen revealed a plexiform ameloblastoma.

7. Histology

Typical KCOT exhibits a uniform layer of parakeratotic, stratified squamous epithelium. The epithelial lining is relatively thin, usually consisting of up to eight cell layers, with characteristic flat connective tissue interface [81]. It is not uncommon to observe detachment of the epithelial layer from the supportive fibrous wall. The basal epithelial layer consists of

http://dx.doi.org/10.5772/53855

palisaded cuboidal or columnar cells, which are frequently hyperchromatic [7]. The superficial layer is usually corrugated, consisting of flattened, parakeratotic cells. It has been demonstrated that the mitotic index in KCOTs' epithelial layer is higher compared to periapical cysts [48]; higher mitotic activity was also observed in syndromic compared to sporadic lesions [12]. The fibrous layer is thin and typically without inflammatory infiltrate. Within this part of KCOTs wall, proliferations of odontogenic epithelium and formation of microcysts may be observed (Figure 16).

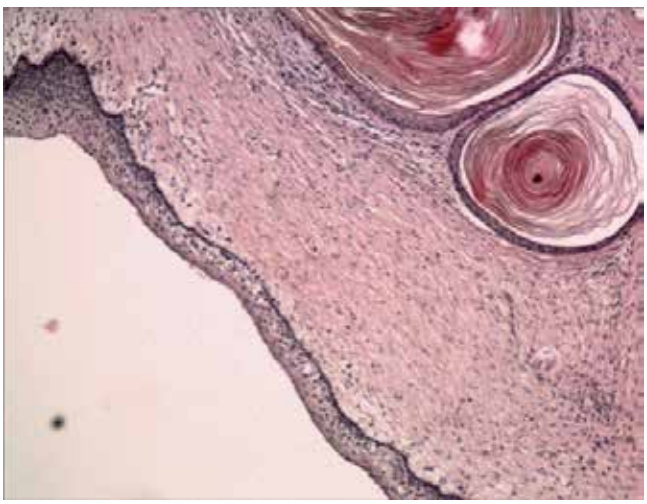

Figure 16. Photomicrograph of a KCOT specimen, exhibiting formation of satellite microcysts within the fibrous wall (courtesy of Prof. Zvezdana Tepavcevic).

Frequency of microcysts formation has been reported to be from 7% to 26% [7], although even higher values have been described. It is important that occurrence of microcysts is more common in syndromic and recurrent OKCs, compared to sporadic cases (78% *vs*. 18% and 4% of cases, respectively) [66].Although parakeratosis is a hallmark of KCOTs, occasionally lesions exhibiting orthokeratotic epithelial layer are encountered. These lesions are termed *orthokeratinized odontogenic cysts* (OOCs) [82] and nowadays they are considered to be a separate entity and not the part of the KCOTs spectrum. It is believed that these lesions do not exhibit aggressive clinical features typical of KCOTs, an opinion which is based predominantly on observation that OOCs recur significantly less frequently compared to KCOTs. In a series of 24 OOCs only one recurrent case was recorded [83] and, in another study, no recurrences were noted in 42 analyzed lesions [84]. However, it seems that, apart from clinical behavior, these two types of lesions differ in some molecular features as well. For example, glycoprotein gp38, which is considered to be a marker of basal cell carcinomas, was identified in parakeratotic KCOTs but not in orthokeratinized ones [85]. Furthermore, in several studies it was demonstrated that cytokeratin profiles of these two types of lesions are substantially different [82, 86, 87], supporting the opinion that KCOTs and OOCs should be considered as distinct entities.

8. Diagnosis

Diagnosis of KCOTs is largely based on histological examination of specimens obtained during the surgery. In fact, histological features of KCOTs are so characteristic that differential diagnosis should be relatively easy in most of the cases. However, in some cases, particularly if the fibrous wall of the lesion shows inflammatory changes, those typical features might be changed up to the level which makes reliable diagnosis impossible. Inflammation of the fibrous wall usually results in significant changes of KCOTs histological features. Proliferation of epithelial cells and loss of parakeratosis and palisaded basal layer result in a histological appearance of nonspecific inflamed odontogenic cyst [7]. If these changes affect larger parts of KCOT wall it may be very difficult to establish a definitive diagnosis. In a series of 112 OKCs, inflammation of the fibrous wall was recorded in as much as 76% of cases. While loss of typical histological features was evident in affected parts of the lesions walls, it was noticed that in 10 cases (8.9%) the characteristic KCOTs appearance was preserved, despite inflammatory changes in the supporting connective tissues [88]. It was also shown that inflammation of KCOTs results in significant increase in numbers of PCNA, Ki-67 and Ag-NOR (*Argyrophilic Nucleolar Organizer Region*) positive cells, reflecting higher proliferative activity of epithelial cells compared to non-inflamed lesions [89].

It is still not clear whether these histological changes affect biological behavior of KCOTs. As one may expect that transformation of typical microscopic features of KCOT into those of a nonspecific odontogenic cyst may result in loss of aggressive behaviour, data from the literature suggest the contrary. As a matter of fact, there are some studies which indicate that inflamed KCOTs may be even more aggressive (as measured by frequency of recurrences) compared to non-inflamed KCOTs. Although a relationship between inflammation and recurrence rates was observed [64, 88], possible reasons for this phenomenon remain unresolved.

Additional diagnostic techniques may be used for KCOTs diagnosis in doubtful cases; specimens should be obtained in a minimally invasive fashion. In an attempt to achieve such goals, several studies investigated if analysis of material obtained by aspiration of KCOT lumen has diagnostic value. Using FNAB (*Fine Needle Aspiration Biopsy*), August and co-workers analyzed immunocytochemical expression of cytokeratin 10 in a sample of 10 KCOTs and 4 periapical and 4 dentigerous cysts. Cytokeratin 10 was expressed in samples obtained by aspiration of KCOTs walls, but not in the samples of periapical and dentigerous cysts [90]. Although promising, these results have not been tested in a larger sample. Moreover, in subsequent research, the same authors showed that after KCOTs decompression and loss of typical histological features, cytokeratin 10 positivity was also diminished [91]; this fact may affect diagnostic reliability of this technique. In a similar study, consistent immunostaining for pan-cytokeratin and cytokeratin 19 was observed in samples of KCOTs obtained by FNAC (*Fine Needle Aspiration Cytology*) [92]. Finally, it is possible that simultaneous analysis of several markers is needed for reliable diagnosis of KCOTs. In a mixed sample of KCOTs, several types of odontogenic cysts and unicystic ameloblastomas, a panel of five immunohistochemical markers, namely keratin 10 and 17, perlecan, proliferating cell nuclear antigen (PCNA) and UEA-I lectin binding (UEA), showed distinct expression pattern in all types of the lesions, providing an effective method for differential diagnosis [93]. An issue which is

not yet resolved is whether or not inflammation of the KCOT wall affects expression of these markers, in a similar fashion as it affects histological features of these lesions.

Since histological diagnosis of KCOTs may be doubtful in inflamed specimens (and particularly if the pathologist examines only a limited amount of tissue obtained during the biopsy) there is an objective risk that, in some cases, definitive diagnosis cannot be established. This will result in a dilemma regarding the most appropriate type of treatment which should be rendered in the particular case. Having in mind such a problem, Stoelinga proposed that, if clinical data suggest a possibility that the lesion in question may be an OKC, but histological diagnosis cannot confirm such assumption, decision on definitive treatment should be based on location of the lesion. In the parts of the jaws which are accessible for surgical treatment and in which possible recurrences are easily diagnosed and treated (e.g. frontal segment of the upper jaw and mandibular body), lesion should be treated by simple enucleation. In contrast to this, if the lesion is located in posterior parts of the upper jaw and in mandibular angle and ramus region, it should be treated as an OKC, using additional techniques to minimize risk of recurrence [94].

9. Treatment

Difficulties in removal of thin and fragile walls, occurrence of multilocular lesions and high propensity for recurrence after the surgery are factors which make surgical treatment of KCOTs considerably more complicated compared to other cystic lesions of the jaws. Still, being a benign lesion without significant tendency for malignant transformation, routine use of radical surgery (such as resection of involved jaw) is questionable, both from medical and ethical point of view. Therefore, it is not surprising that numerous adjunctive techniques have been developed for treatment of KCOTs Establishing the balance between effective reduction of recurrence risk and selection of the least aggressive surgical procedure for each individual patient is a basic principle in treatment planning for these lesions [95].

9.1. Enucleation

Bearing in mind the high recurrence rates, it is accepted that the standard procedure of enucleation is not adequate for KCOT treatment [96]. In order to improve results of enucleation, peripheral ostectomy was introduced, aiming to eliminate remnants of tumoral tissue or satellite microcysts from the periphery of the defect, particularly in multilobular and multilocular cases. Although it may be effective in reduction of recurrence risk, lack of ability to control the amount of removed bone is considered to be a major disadvantage of this procedure [96].

9.2. Resection

In contrast to enucleation, resection of the affected jaw has proved to be very effective in prevention of recurrences. Actually, it is the only technique for which case series without recurrences were reported [97–100]. Besides resection of bone, excision of soft tissues in contact with the lesion is another important concept aimed to reduce risk of recurrence. In a

series of 31 mandibular KCOTs, marginal resection of affected jaw in conjunction with soft tissue excision resulted in complete elimination of recurrences during the follow-up period of up to eight years [98]. Still, having in mind high morbidity associated with this kind of surgery and necessity for additional reconstructive interventions, it was suggested that such a procedure should be reserved only for specific situations – large, recurrent lesions, lesions involving condylar process, and lesions with malignant alteration or pathological fracture of the jaw [96]. However, the concept of soft tissue excision is not restricted solely to resection of the jawbones. An opinion that such a procedure may reduce risk of KCOTs recurrence is based on observations that lesions which have perforated cortical bone show higher recurrence rates compared to non-perforating ones [64]. In addition, Stoelinga and co-workers suggested that some of the recurrences may be attributed to continuing proliferation of basal cells of oral epithelium into the deeper tissues, even after removal of the original lesion [94]. They believed that such a situation is particularly common in the mandibular retromolar region (Figure 17) and therefore proposed that any soft tissues which are in direct contact with the lesion wall should be excised (Figure 18).

Figure 17. Direct contact of retromolar soft tissues with a KCOT of left mandibular angle. Cone beam CT of the same lesion demonstrates cortical perforation.

Figure 18. Excision of soft tissues after removal of the lesion.

http://dx.doi.org/10.5772/53855

9.3. Decompression

Another option, which is widely used for treatment of large cystic lesions of the jaws is decompression, followed by enucleation in the second surgery. The principal goal of such a procedure is to reduce the size of the original lesion, which facilitates complete removal at the second-stage surgery and reduces the risk of injury to surrounding anatomical structures (e.g. inferior alveolar nerve, teeth etc.). Besides this, when used for KCOTs treatment, decompression usually leads to thickening of lesion wall, which also makes enucleation of remaining tumoral tissue easier (Figures 19 and 20).

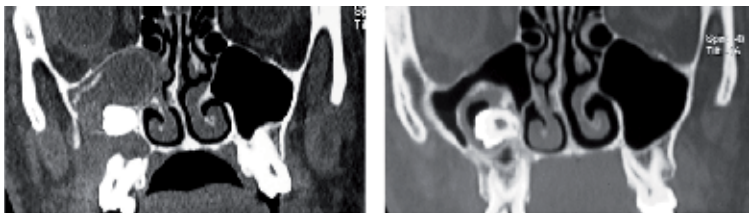

Figure 19. Coronal CT scans of KCOT of right maxilla, before and six months after the decompression. Significant reduction in size of the lesion is apparent.

Figure 20. Clinical photograph of the lesion in figure 19. A Caldwell-Luc approach was used for enucleation at the second stage surgery.

However, although it is clear that decompression facilitates enucleation of the lesion, it is more controversial whether such a procedure reduces risk of KCOTs recurrence. Brondum and Jensen reported no recurrences in a series of 12 KCOTs treated by decompression and subsequent enucleation in contrast to 8 out of 44 recurrent cases (18%) of KCOTs treated by one-stage enucleation [5]. In another study with follow-up period of up to sixteen years, no significant differences in recurrence rates were observed for KCOTs treated by decompression and enucleation compared to enucleation alone (26.1% *vs.* 20% of recurrent cases, respectively) [101]. Having in mind reclassification of KCOTs into odontogenic tumors, it is

particularly intriguing to seek which mechanisms are responsible for reduction of KCOT size after the decompression.

9.4. Marsupialization

It was shown that marsupialization of KCOTs results in significant reduction of Ki-67 and IL-1α mRNA expression in these lesions. As IL-1α exerts osteolytic activity, the authors concluded that decreased expression of this interleukin may contribute to the effects of marsupialization [102]. Lower expression of IL-1α receptor IL-1RI and KGF (keratinocyte growth factor) were also demonstrated in response to decompression [103, 104]. Finally, an experimental study showed that positive pressure of 80 mmHg enhanced the expression of IL-1α mRNA and protein in KCOTs epithelial cells, and increased the secretion of MMP-1, MMP-2, MMP-3, and PGE2 in a co-culture of KCOTs fibroblasts and the epithelial cells. Based on this, the authors pointed out that increased intracystic pressure may play a crucial role in OKCs growth via stimulating the expression of IL-1α in epithelial cells [105].

Similar to decompression, a fact that marsupialization may result in complete regression of KCOTs was used as an argument to question opinions on the tumoral nature of these lesions. Pogrel and Jordan presented ten cases of KCOTs which were treated by marsupialization as a definitive treatment method. In all cases complete resolution of the lesions, both clinically and radiographically, was observed. Histological examination revealed that in the area of previous KCOTs no remnants of cystic epithelium could be identified. Lack of immunohistochemical expression of bcl-2 in biopsy samples (a marker which is commonly detected in KCOTs epithelium) led to the same conclusion. Authors pointed out that the fate of the cystic epithelium remained unresolved. It may undergo metaplasia to normal mucosa, or a creeping substitution by normal mucosa from the edges of the lesion [106]. Shear commented that it is difficult to explain this unusual and important finding and raised a question what has happened to the KCOTs epithelium with all its potential for active and infiltrative growth [6]. However, in subsequent study, with increased number of cases (n=42) and with longer follow-up period (ranging from 1.5 to 4 years), same authors recorded 5 recurrences (12%) which resulted in partial retraction of previous papers [107]. A fact that recurrences were present despite apparently complete resolution of the lesions, reinforced opinions that KCOTs are actually benign odontogenic tumors, although responsive to decompression, a feature also demonstrated by unicystic ameloblastomas (which are widely accepted as tumoral lesions) [108].

In an attempt to overcome the problem of retention of parts of KCOTs lining and/or microcysts upon lesion removal, techniques of chemical and thermal fixation of surrounding tissues were developed. The most widely accepted is application of Carnoy's solution which acts as a chemical fixative and hemostatic agent. Several studies showed that usage of Carnoy's solution following enucleation significantly reduces number of recurrences compared to enucleation alone [62, 97]. Developing this method, Stoelinga and co-workers proposed a protocol of treatment consisting of enucleation, followed by application of Carnoy's solution and excision of soft tissues in contact with cystic lining. In this manner, frequency of recurrences was reduced to 6% compared to 18% in a group of lesions treated only by enucleation

http://dx.doi.org/10.5772/53855

[18]. Finally, for the same purpose of microcysts removal, liquid nitrogen has been used to treat surrounding tissues and it was shown that such a procedure may be useful even for recurrent cases [109].

Figure 21. Upon KCOT removal, Carnoy's solution was applied to the bony bed of the lesion and left in place for 3 minutes.

Figure 22. Surgical field after the application of Carnoy's solution.

Although all these techniques were assessed in numerous studies, currently available level of evidence is insufficient to recommend any of them as a standard procedure for KCOTs treatment. Until more prospective and randomized clinical trials are performed, selection of surgical treatment will be based on the surgeon's preference and institution-based protocols.

10. Conclusion

Due to their unique clinical and biological features, KCOTs still represent an important problem in oral and maxillofacial surgery and remain to be a subject of controversy among researchers and clinicians. Numerous aspects of KCOTs pathogenesis support opinions on their tumoral nature. However, response to decompression and importance of increased intracystic pressure for their growth indicate that the borderline between odontogenic tumors and cysts may not be as distinctive as we previously believed. As there is a consensus that

standard treatment options for cystic lesions of the jaws are not suitable for KCOTs, additional effort should be made to establish correct diagnosis in doubtful cases. Regarding selection of the most appropriate treatment modality, it is important to establish a balance between effective reduction of recurrence risk and selection of least aggressive surgical procedure for each individual patient. Finally, better understanding of KCOTs pathogenesis may provide clues for new treatment strategies, including use of survivin and Sonic hedgehog (Shh) signaling pathway inhibitors.

Acknowledgements

This work was supported by grant No. 175056 from the Ministry of Science of the Republic of Serbia.

Author details

Miroslav Andrić[1], Božidar Brković[1], Vladimir Jurišić[2], Milan Jurišić[1] and Jelena Milašin[3]

*Address all correspondence to: miroslav.andric@stomf.bg.ac.rs

1 University of Belgrade, School of Dental Medicine, Department of Oral Surgery, Belgrade, Serbia

2 University of Kragujevac, School of Medicine, Kragujevac, Serbia

3 University of Belgrade, School of Dental Medicine, Institute of Human Genetics, Belgrade, Serbia

References

[1] Browne RM. The odontogenic keratocyst. Histological features and their correlation with clinical behaviour. Br Dent J. 1971; 131: 249-259.

[2] Shear M. The aggressive nature of the odontogenic keratocyst: is it a benign cystic neoplasm? Part 1. Clinical and early experimental evidence of aggressive behaviour. Oral Oncol. 2002;38(3):219-226. A.

[3] Shear M. The aggressive nature of the odontogenic keratocyst: is it a benign cystic neoplasm? Part 2. Proliferation and genetic studies. Oral Oncol. 2002;38(4):323-331. B.

[4] Barnes L, Eveson JW, Reichart P, Sidransky D, editors. Pathology and genetics of head and neck tumours. Lyon: IARC Press; 2005. WHO classification of tumours series.

[5] Brondum N, Jensen VJ. Recurrence of keratocysts and decompression treatment. A long-term follow-up of forty-four cases. Oral Surg Oral Med Oral Pathol. 1991;72(3): 265-269.

[6] Shear M, Speight PM. Odontogenic keratocyst. In Shear M, Speight PM. Cysts of the Oral and Maxillofacial Regions, Oxford: Blackwell Munksgaard; 2007, p6–58.

[7] Neville BW, Damm DD, Allen CM, Bouquot JE. Oral & Maxillofacial Pathology. 2nd ed, Philadelphia: WB Saunders Company; 2002

[8] Rachanis CC, Shear M. Age-standardized incidence rates of primordial cyst (keratocyst) on the Witwatersrand. Community Dent Oral Epidemiol. 1978;6(6):296-299.

[9] Lench NJ, Telford EA, High AS, Markham AF, Wicking C, Wainwright BJ. Characterisation of human patched germ line mutations in naevoid basal cell carcinoma syndrome. Hum Genet. 1997;100(5-6):497-502.

[10] Woolgar JA, Rippin JW, Browne RM. The odontogenic keratocyst and its occurrence in the nevoid basal cell carcinoma syndrome. Oral Surg Oral Med Oral Pathol. 1987;64(6):727-730. C

[11] Chiang ML, Huang WH. Odontogenic keratocyst clinically mimicking an eruption cyst: report of a case. J Oral Pathol Med. 2004;33(6):373-375.

[12] Woolgar JA, Rippin JW, Browne RM. A comparative histological study of odontogenic keratocysts in basal cell naevus syndrome and control patients. J Oral Pathol. 1987;16(2):75-80. A

[13] Brannon RB. The odontogenic keratocyst. A clinicopathologic study of 312 cases. Part I. Clinical features. Oral Surg Oral Med Oral Pathol. 1976;42(1):54-72.

[14] Browne RM. The odontogenic keratocyst. Clinical aspects. Br Dent J. 1970;128(5): 225-231.

[15] Woolgar JA, Rippin JW, Browne RM. A comparative study of the clinical and histological features of recurrent and non-recurrent odontogenic keratocysts. J Oral Pathol. 1987;16(3):124-128. B

[16] Aragaki T, Michi Y, Katsube K, Uzawa N, Okada N, Akashi T et al. Comprehensive keratin profiling reveals different histopathogenesis of keratocystic odontogenic tumor and orthokeratinized odontogenic cyst. Hum Pathol. 2010;41(12):1718-1725.

[17] Stoelinga PJ. (A) Etiology and pathogenesis of keratocysts. Oral Maxillofacial Surg Clin N Am. 2003; 15(3):316-324.

[18] Stoelinga PJ. Long-term follow-up on keratocysts treated according to a defined protocol. Int J Oral Maxillofac Surg. 2001;30(1):14-25.

[19] Shear M. Odontogenic keratocyst: natural history and immunohistochemistry. Oral Maxillofacial Surg Clin N Am. 2003 B; 15(3):347-362.

[20] Levanat S, Gorlin RJ, Fallet S, Johnson DR, Fantasia JE, Bale AE. A two-hit model for developmental defects in Gorlin syndrome. Nat Genet. 1996;12(1):85-87.

[21] Ohki K, Kumamoto H, Ichinohasama R, Sato T, Takahashi N, Ooya K. PTC gene mutations and expression of SHH, PTC, SMO, and GLI-1 in odontogenic keratocysts. Int J Oral Maxillofac Surg. 2004;33(6):584-592.

[22] Barreto DC, Gomez RS, Bale AE, Boson WL, De Marco L. PTCH gene mutations in odontogenic keratocysts. J Dent Res. 2000; 79(6):1418-1422.

[23] Lench NJ, High AS, Markham AF, Hume WJ, Robinson PA. Investigation of chromosome 9q22.3-q31 DNA marker loss in odontogenic keratocysts. Eur J Cancer B Oral Oncol. 1996;32B(3):202-206.

[24] Barreto DC, Bale AE, De Marco L, Gomez RS. Immunolocalization of PTCH protein in odontogenic cysts and tumors. J Dent Res. 2002;81(11):757-760.

[25] Agaram NP, Collins BM, Barnes L, Lomago D, Aldeeb D, Swalsky P et al. Molecular analysis to demonstrate that odontogenic keratocysts are neoplastic. Arch Pathol Lab Med. 2004;128(3):313-317.

[26] Milašin J, Dedović N, Šekarić P, Jurišić M, Petrović V, Dimitrijević B. H-ras oncogene activation in a reccurent odontogenic keratocyst. Balk J Stom,1997: 1;105-106.

[27] Andric M, Nikolic N, Boskovic M, Milicic B, Skodric S, Basta Jovanovic G, Milasin J. Survivin gene promoter polymorphism -31G/C as a risk factor for keratocystic odontogenic tumor development. Eur J Oral Sci. 2012 Feb;120(1):9-13.

[28] el Murtadi A, Grehan D, Toner M, McCartan BE. Proliferating cell nuclear antigen staining in syndrome and nonsyndrome odontogenic keratocysts. Oral Surg Oral Med Oral Pathol Oral Radiol Endod. 1996;81(2):217-220.

[29] Li TJ, Browne RM, Matthews JB. Quantification of PCNA+ cells within odontogenic jaw cyst epithelium. J Oral Pathol Med. 1994;23(4):184-189.

[30] Li TJ, Browne RM, Matthews JB. Epithelial cell proliferation in odontogenic keratocysts: a comparative immunocytochemical study of Ki67 in simple, recurrent and basal cell naevus syndrome (BCNS)-associated lesions. J Oral Pathol Med. 1995;24(5): 221-226.

[31] Jurisic V, Srdic-Rajic T, Konjevic G, Bogdanovic G, Colic M. TNF-α induced apoptosis is accompanied with rapid CD30 and slower CD45 shedding from K-562 cells. J Membr Biol. 2011;239(3):115-122.

[32] Li TJ, Browne RM, Prime SS, Paterson IC, Matthews JB. p53 expression in odontogenic keratocyst epithelium. J Oral Pathol Med. 1996;25(5):249-255.

[33] Piattelli A, Fioroni M, Santinelli A, Rubini C. P53 protein expression in odontogenic cysts. J Endod. 2001;27(7):459-461.

[34] Slootweg PJ. p53 protein and Ki-67 reactivity in epithelial odontogenic lesions. An immunohistochemical study. J Oral Pathol Med. 1995;24:393-397.

[35] Ogden GR, Chisholm DM, Kiddie RA, Lane DP. p53 protein in odontogenic cysts: increased expression in some odontogenic keratocysts. J Clin Pathol. 1992;45(11): 1007-1010.

[36] González-Moles MA, Mosqueda-Taylor A, Delgado-Rodríguez M, Martínez-Mata G, Gil-Montoya JA, Díaz-Franco MA et al. Analysis of p53 protein by PAb240, Ki-67 expression and human papillomavirus DNA detection in different types of odontogenic keratocyst. Anticancer Res. 2006;26(1A):175-181.

[37] Popović B, Jekić B, Novaković I, Luković LJ, Tepavcević Z, Jurisić V, Vukadinović M, Milasin J. Bcl-2 expression in oral squamous cell carcinoma. Ann N Y Acad Sci. 2007;1095:19-25

[38] Kolár Z, Geierová M, Bouchal J, Pazdera J, Zboril V, Tvrdý P. Immunohistochemical analysis of the biological potential of odontogenic keratocysts. J Oral Pathol Med. 2006;35(2):75-80.

[39] Lo Muzio L, Staibano S, Pannone G, Bucci P, Nocini PF, Bucci E et al. Expression of cell cycle and apoptosis-related proteins in sporadic odontogenic keratocysts and odontogenic keratocysts associated with the nevoid basal cell carcinoma syndrome. J Dent Res. 1999;78(7):1345-1353.

[40] Kichi E, Enokiya Y, Muramatsu T, Hashimoto S, Inoue T, Abiko Y, Shimono M. Cell proliferation, apoptosis and apoptosis-related factors in odontogenic keratocysts and in dentigerous cysts. J Oral Pathol Med. 2005;34(5):280-286.

[41] Andric M, Dozic B, Popovic B, Stefanovic D, Basta-Jovanovic G, Djogo N, Andjus P, Milasin J. Survivin expression in odontogenic keratocysts and correlation with cytomegalovirus infection. Oral Dis. 2010;16(2):156-159.

[42] de Oliveira MG, da Silva Lauxen I, Chaves AC, Rados PV, Sant'ana Filho M. Odontogenic Epithelium: Immunolabeling of Ki-67, EGFR and Survivin in Pericoronal Follicles, Dentigerous Cysts and Keratocystic Odontogenic Tumors. Head Neck Pathol. 2011;5(1):1-7.

[43] Jacinto RC, Gomes BP, Ferraz CC, Zaia AA, Filho FJ. Microbiological analysis of infected root canals from symptomatic and asymptomatic teeth with periapical periodontitis and the antimicrobial susceptibility of some isolated anaerobic bacteria. Oral Microbiol Immunol. 2003;18(5):285-292.

[44] Andric M, Milasin J, Jovanovic T, Todorovic L. Human cytomegalovirus is present in odontogenic cysts. Oral Microbiol Immunol. 2007;22(5):347-351.

[45] Jurisic V, Terzic T, Colic S, Jurisic M. The concentration of TNF-alpha correlate with number of inflammatory cells and degree of vascularization in radicular cysts. Oral Dis. 2008;14(7):600-605.

[46] Jurisic V, Colic S, Jurisic M. The inflammatory radicular cysts have higher concentration of tnf-alpha in comparison to odontogenic keratocysts (odontogenic tumour). Acta Medica (Hradec Kralove). 2007;50(4):233-238.

[47] Shear M. Odontogenic keratocysts: clinical features. Oral Maxillofacial Surg Clin N Am. 2003 A; 15(3):335-345.

[48] Main DM. Epithelial jaw cysts: a clinicopathological reappraisal. Br J Oral Surg. 1970;8(2):114-125.

[49] Lund VJ. Odontogenic keratocyst of the maxilla: a case report. Br J Oral Maxillofac Surg. 1985;23(3):210-215.

[50] Emerson TG, Whitlock RI, Jones JH. Involvement of soft tissue by odontogenic keratocysts (primordial cysts). Br J Oral Surg. 1972;9(3):181-185.

[51] Chuong R, Donoff RB, Guralnick W. The odontogenic keratocyst. J Oral Maxillofac Surg. 1982;40(12):797-802.

[52] Worrall SF. Recurrent odontogenic keratocyst within the temporalis muscle. Br J Oral Maxillofac Surg. 1992;30(1):59-62.

[53] Jackson IT, Potparic Z, Fasching M, Schievink WI, Tidstrom K, Hussain K. Penetration of the skull base by dissecting keratocyst. J Craniomaxillofac Surg. 1993;21(8): 319-325.

[54] Dayan D, Buchner A, Gorsky M, Harel-Raviv M. The peripheral odontogenic keratocyst. Int J Oral Maxillofac Surg. 1988;17(2):81-83.

[55] Ide F, Mishima K, Saito I, Kusama K. Rare peripheral odontogenic tumors: report of 5 cases and comprehensive review of the literature. Oral Surg Oral Med Oral Pathol Oral Radiol Endod. 2008;106:e22-28.

[56] Faustino SE, Pereira MC, Rossetto AC, Oliveira DT. Recurrent peripheral odontogenic keratocyst: a case report. Dentomaxillofac Radiol. 2008;37(7):412-414.

[57] Ide F, Kikuchi K, Miyazaki Y, Mishima K, Saito I, Kusama K. Keratocyst of the buccal mucosa: is it odontogenic? Oral Surg Oral Med Oral Pathol Oral Radiol Endod. 2010;110(5):e42-47.

[58] Vered M, Dayan D, Buchner A. Multicystic (solid) variant of keratocyst (abstract). J Oral Pathol Med 2002;31:312–313.

[59] Vered M, Buchner A, Dayan D, Shteif M, Laurian A. Solid variant of odontogenic keratocyst. J Oral Pathol Med. 2004;33(2):125-128.

[60] Ide F, Mishima K, Saito I. Solid-cystic tumor variant of odontogenic keratocyst: an aggressive but benign lesion simulating keratoameloblastoma. Virchows Arch. 2003;442(5):501-503.

[61] Daley TD, Multari J, Darling MR. A case report of a solid keratocystic odontogenic tumor: is it the missing link? Oral Surg Oral Med Oral Pathol Oral Radiol Endod. 2007;103(4):512-515.

[62] Voorsmit RA, Stoelinga PJ, van Haelst UJ. The management of keratocysts. J Maxillofac Surg. 1981;9(4):228-236.

[63] Pindborg JJ, Hansen J. Studies on odontogenic cyst epithelium. 2. clinical and roentgenologic aspects of odontogenic keratocysts. Acta Pathol Microbiol Scand. 1963; 58: 283-294.

[64] Forssell K, Forssell H, Kahnberg KE. Recurrence of keratocysts. A long-term follow-up study. Int J Oral Maxillofac Surg. 1988;17(1):25-28.

[65] Myoung H, Hong SP, Hong SD, Lee JI, Lim CY, Choung PH et al. Odontogenic keratocyst: Review of 256 cases for recurrence and clinicopathologic parameters. Oral Surg Oral Med Oral Pathol Oral Radiol Endod. 2001;91(3):328-333.

[66] Payne TF. An analysis of the clinical and histopathologic parameters of the odontogenic keratocyst. Oral Surg Oral Med Oral Pathol. 1972;33(4):538-546.

[67] Donatsky O, Hjörting-Hansen E, Philipsen HP, Fejerskov O. Clinical, radiologic, and histopathologic aspects of 13 cases of nevoid basal cell carcinoma syndrome. Int J Oral Surg. 1976;5(1):19-28.

[68] DeGould MD, Goldberg JS. Recurrence of an odontogenic keratocyst in a bone graft. Report of a case. Int J Oral Maxillofac Surg. 1991;20(1):9-11

[69] Makowski GJ, McGuff S, Van Sickels JE. Squamous cell carcinoma in a maxillary odontogenic keratocyst. J Oral Maxillofac Surg. 2001;59(1):76-80.

[70] Chaisuparat R, Coletti D, Kolokythas A, Ord RA, Nikitakis NG. Primary intraosseous odontogenic carcinoma arising in an odontogenic cyst or de novo: a clinicopathologic study of six new cases. Oral Surg Oral Med Oral Pathol Oral Radiol Endod. 2006 Feb; 101(2):194-200.

[71] Falaki F, Delavarian Z, Salehinejad J, Saghafi S. Squamous cell carcinoma arising from an odontogenic keratocyst: a case report. Med Oral Patol Oral Cir Bucal. 2009;14(4):E171-174.

[72] Lo Muzio L. Nevoid basal cell carcinoma syndrome (Gorlin syndrome). Orphanet J Rare Dis. 2008;3:32. doi:10.1186/1750-1172-3-32

[73] Kimonis VE, Goldstein AM, Pastakia B, Yang ML, Kase R, DiGiovanna JJ, Bale AE, Bale SJ. Clinical manifestations in 105 persons with nevoid basal cell carcinoma syndrome. Am J Med Genet. 1997;69(3):299-308.

[74] Lo Muzio L, Staibano S, Pannone G, Bucci P, Nocini PF, Bucci E et al. Expression of cell cycle and apoptosis-related proteins in sporadic odontogenic keratocysts and odontogenic keratocysts associated with the nevoid basal cell carcinoma syndrome. J Dent Res. 1999;78(7):1345-1353.

[75] Kimi K, Kumamoto H, Ooya K, Motegi K. Immunohistochemical analysis of cell-cycle- and apoptosis-related factors in lining epithelium of odontogenic keratocysts. J Oral Pathol Med. 2001;30(7):434-442.

[76] de Assis Caldas Pereira F, Gurgel CA, Ramos EA, Vidal MT, Pinheiro AL, Jurisic V, Sales CB, Cury PR, dos Santos JN. Distribution of mast cells in benign odontogenic tumors. Tumour Biol. 2012;33(2):455-461.

[77] Forssell K. The primordial cyst. A clinical and radiographic study. Proc Finn Dent Soc. 1980;76(3):129-174.

[78] Yoshiura K, Higuchi Y, Ariji Y, Shinohara M, Yuasa K, Nakayama E, Ban S, Kanda S. Increased attenuation in odontogenic keratocysts with computed tomography: a new finding. Dentomaxillofac Radiol. 1994;23(3):138-142.

[79] van Rensburg LJ, Paquette M, Morkel JA, Nortje CJ. Correlative MRI and CT imaging of the odontogenic keratocyst: a review of tweny-one cases. Oral Maxillofacial Surg Clin N Am. 2003; 15(3):363-382.

[80] Minami M, Kaneda T, Ozawa K, Yamamoto H, Itai Y, Ozawa M et al. Cystic lesions of the maxillomandibular region: MR imaging distinction of odontogenic keratocysts and ameloblastomas from other cysts. AJR Am J Roentgenol. 1996;166(4):943-949.

[81] Jordan RCK. Histology and ultrastructural features of the odontogenic keratocyst. Oral Maxillofacial Surg Clin N Am. 2003; 15(3):325-333.

[82] Li TJ, Kitano M, Chen XM, Itoh T, Kawashima K, Sugihara K et al. Orthokeratinized odontogenic cyst: a clinicopathological and immunocytochemical study of 15 cases. Histopathology. 1998;32(3):242-251.

[83] Wright JM. The odontogenic keratocyst: orthokeratinized variant. Oral Surg Oral Med Oral Pathol. 1981;51(6):609-618.

[84] Dong Q, Pan S, Sun LS, Li TJ. Orthokeratinized odontogenic cyst: a clinicopathologic study of 61 cases. Arch Pathol Lab Med. 2010;134(2):271-275.

[85] High AS, Robinson PA, Klein CE. Discrimination of parakeratinised odontogenic keratocysts from other odontogenic and non-odontogenic cyst types by expression of a 38kd cell-surface glycoprotein. J Oral Pathol Med. 1993;22(8):363-367.

[86] Aragaki T, Michi Y, Katsube K, Uzawa N, Okada N, Akashi T et al. Comprehensive keratin profiling reveals different histopathogenesis of keratocystic odontogenic tumor and orthokeratinized odontogenic cyst. Hum Pathol. 2010;41(12):1718-1725.

[87] da Silva MJ, de Sousa SO, Corrêa L, Carvalhosa AA, De Araújo VC. Immunohistochemical study of the orthokeratinized odontogenic cyst: a comparison with the odontogenic keratocyst. Oral Surg Oral Med Oral Pathol Oral Radiol Endod. 2002;94(6):732-737.

[88] Rodu B, Tate AL, Martinez MG Jr. The implications of inflammation in odontogenic keratocysts. J Oral Pathol. 1987;16(10):518-521.

[89] de Paula AM, Carvalhais JN, Domingues MG, Barreto DC, Mesquita RA. Cell proliferation markers in the odontogenic keratocyst: effect of inflammation. J Oral Pathol Med. 2000;29(10):477-482.

[90] August M, Faquin WC, Troulis M, Kaban LB. Differentiation of odontogenic keratocysts from nonkeratinizing cysts by use of fine-needle aspiration biopsy and cytokeratin-10 staining. J Oral Maxillofac Surg. 2000; 58(9):935-940.

[91] August M, Faquin WC, Troulis MJ, Kaban LB. Dedifferentiation of odontogenic keratocyst epithelium after cyst decompression. J Oral Maxillofac Surg. 2003;61(6): 678-683.

[92] Vargas PA, da Cruz Perez DE, Mata GM, de Almeida OP, Jones AV, Gerhard R. Fine needle aspiration cytology as an additional tool in the diagnosis of odontogenic keratocyst. Cytopathology. 2007;18(6):361-366.

[93] Tsuneki M, Yamazaki M, Cheng J, Maruyama S, Kobayashi T, Saku T. Combined immunohistochemistry for the differential diagnosis of cystic jaw lesions: its practical use in surgical pathology. Histopathology. 2010;57(6):806-813.

[94] Stoelinga PJ. (B) Excision of the overlying attached mucosa, in conjuction with cyst enucleation and treatment of the bony defect with carnoy solution. Oral Maxillofacial Surg Clin N Am. 2003; 15(3):407-414.

[95] Jurisic M, Andric M, dos Santos JM, Jurisic V. Clinical, diagnostic and therapeutic features of keratocystic odontogenic tumors: a review. J BUON. 2012;17(2):237-244.

[96] Ghali GE, Connor MS. Surgical menagement of the odontogenic keratocyst. Oral Maxillofacial Surg Clin N Am. 2003; 15(3):383-392.

[97] Zhao YF, Wei JX, Wang SP. Treatment of odontogenic keratocysts: a follow-up of 255 Chinese patients. Oral Surg Oral Med Oral Pathol Oral Radiol Endod. 2002;94(2): 151-156.

[98] Bataineh AB, al Qudah M. Treatment of mandibular odontogenic keratocysts. Oral Surg Oral Med Oral Pathol Oral Radiol Endod. 1998; 86(1):42-47.

[99] Partridge M, Towers JF. The primordial cyst (odontogenic keratocyst): its tumour-like characteristics and behaviour. Br J Oral Maxillofac Surg. 1987;25(4):271-279.

[100] Hodgkinson DJ, Woods JE, Dahlin DC, Tolman DE. Keratocysts of the jaw. Clinicopathologic study of 79 patients. Cancer. 1978;41(3):803-813.

[101] Nakamura N, Mitsuyasu T, Mitsuyasu Y, Taketomi T, Higuchi Y, Ohishi M. Marsupialization for odontogenic keratocysts: long-term follow-up analysis of the effects and changes in growth characteristics. Oral Surg Oral Med Oral Pathol Oral Radiol Endod. 2002;94(5):543-553.

[102] Ninomiya T, Kubota Y, Koji T, Shirasuna K. Marsupialization inhibits interleukin-1alpha expression and epithelial cell proliferation in odontogenic keratocysts. J Oral Pathol Med. 2002;31(9):526-533.

[103] Suyama Y, Kubota Y, Ninomiya T, Shirasuna K. Immunohistochemical analysis of interleukin-1 alpha, its type I receptor and antagonist in keratocystic odontogenic tumors. J Oral Pathol Med. 2008;37(9):560-564.

[104] Suyama Y, Kubota Y, Yamashiro T, Ninomiya T, Koji T, Shirasuna K. Expression of keratinocyte growth factor and its receptor in odontogenic keratocysts. J Oral Pathol Med. 2009;38(5):476-480.

[105] Oka S, Kubota Y, Yamashiro T, Ogata S, Ninomiya T, Ito S, Shirasuna K. Effects of positive pressure in odontogenic keratocysts. J Dent Res. 2005;84(10):913-918.

[106] Pogrel MA, Jordan RC. Marsupialization as a definitive treatment for the odontogenic keratocyst. J Oral Maxillofac Surg. 2004;62(6):651-655.

[107] Pogrel MA. Decompression and marsupialization as definitive treatment for keratocysts--a partial retraction. J Oral Maxillofac Surg. 2007;65(2):362-363.

[108] Nakamura N, Higuchi Y, Tashiro H, Ohishi M. Marsupialization of cystic ameloblastoma: a clinical and histopathologic study of the growth characteristics before and after marsupialization. J Oral Maxillofac Surg. 1995;53(7):748-754.

[109] Schmidt BL, Pogrel MA. The use of enucleation and liquid nitrogen cryotherapy in the management of odontogenic keratocysts. J Oral Maxillofac Surg. 2001;59(7):720-725.

Chapter 8

Marsupialization of Keratocystic Odontogenic Tumors of the Mandible: Longitudinal Image Analysis of Tumor Size via 3D Visualized CT Scans

Hajime Shudou, Masanori Sasaki,
Takahiro Yamashiro, Shizuo Tsunomachi,
Yasuharu Takenoshita, Yasutaka Kubota,
Tomohiro Ninomiya, Toshiyuki Kawazu and
Yoshihide Mori

Additional information is available at the end of the chapter

http://dx.doi.org/10.5772/52432

1. Introduction

The odontogenic keratocyst (OKC) was designated by the World Health Organization (WHO) as a keratocystic odontogenic tumor (KCOT) in 2005. KCOT has been defined as a benign uni- or multicystic, intraosseous tumor of odontogenic origin, with a characteristic lining of parakeratinized stratified squamous epithelium and potential for aggressive, infiltrative behavior. Additionally, these tumors have been characterized by a high recurrence rate [1, 2]. Because the recurrence rate of KCOTs ranges from 13.1% [2] to 62.5% [3, 4, 5, 6], many attempts have been made to reduce the high recurrence rate with improved surgical techniques. Recommended techniques have included tanning the cystic cavity with Carnoy's solution before enucleation [7, 8], or using a combination of enucleation and liquid nitrogen cryotherapy [9], whereas others recommend techniques such as marsupialization or decompression of the cysts followed by secondary enucleation [10, 11, 12]. Specifically, Bramley [13] recommended the use of radical surgery with resection and bone transplantation, whereas Ephros and Lee [14] advocated the removal of the lateral cortical plate and enucleation of the cyst. Bataineh and al Qudah [15] advocated resection without continuity defects as a standard treatment for preoperatively diagnosed KCOTs. To reduce the high recurrence rate of KCOTs, it is essential to completely eradicate the epithelial components of the cyst [16]. However, radical treatment

INTECH
open science | open minds

© 2013 Shudou et al.; licensee InTech. This is a paper distributed under the terms of the Creative Commons Attribution License (http://creativecommons.org/licenses/by/3.0), which permits unrestricted use, distribution, and reproduction in any medium, provided the original work is properly cited.

has been associated with numerous complications, including facial deformity, missing teeth, infection of transplanted bone, and / or permanent numbness of the region innervated by the mental nerve when the KCOTs involved the inferior alveolar nerve. Therefore, considering the benign characteristics of KCOTs, the first priority of the treatment method should be discussed from the perspective of morbidity and the quality of life of the patients; the recurrence rate should not always be the primary factor.

1.1. Marsupialization

Marsupialization or decompression has been used in the past as a conservative treatment modality for large KCOTs, minimizing the tumor size and limiting the extent of surgery [10, 11, 12, 17-19, 20]. Nakamura et al. [19] reported that marsupialization did not affect the recurrence rate of KCOTs. Marker et al. [11] reported long-term results after decompression for 23 KCOTs, and they concluded that these cysts could be treated successfully by marsupialization and secondary enucleation. However, there were some disadvantages in marsupialization, and one of the disadvantages was that, when considering other treatment methods, the time necessary for this treatment was comparatively long [21].

This chapter determines how KCOTs in the mandible are reduced in size by marsupialization and predicts the best time for secondary enucleation by means of analyzing computerized tomography (CT) images. Fifteen patients with KCOTs were treated with marsupialization surgery, and 42 series of CT data taken during the marsupialization process were analyzed. CT data were reconstructed in 3-dimensional (3D) images. The 3D images were used to measure the diameter and volume, and to analyze the changes that occurred after marsupialization. Marsupialized KCOTs tended to be equally reduced towards the window in the tumor. The amount of volume reduction per day (V_r) was reduced in proportion to the volume (V) with the formula:

$V_r = -0.0029 \times V$. The formula manipulation for V was $V = V_1 \times e^{-0.0029\ t}$ (t = duration after marsupialization in days). The volume of marsupialized KCOTs was reduced by half over a 239 day period. These results demonstrate that the future shape of marsupialized mandibular KCOTs, under good control, can be predicted with significant accuracy using CT data. This prediction can decrease the prolonged marsupialization period in patients with KCOTs. Herein we clarify how KCOTs are reduced in size during the marsupialization and to predict the best time for secondary enucleation by means of analyzing computerized tomography (CT) images.

1.2. Treatment

Our series of 15 patients with histologically proven KCOTs of the mandible were treated by marsupialization surgery from 2000 to 2010. Of the 15 patients, 9 were male (60.0%) and 6 were female (40.0%). The mean age was 35.9 years (range: 16 to 57). The tumors were located in the posterior molar to mandibular ramus in 5, in the angle to mandibular ramus in 7, and in the anterior molar region in 3 patients. Using X-ray images, the tumors were classified; 10 were unilocular lesions and 5 were multilocular lesions (Table1).

http://dx.doi.org/10.5772/52432

Postoperative follow-up consisted of clinical and radiographic examinations. Cases of recurrent tumors or cases associated with basal cell nevus syndrome were excluded from this study. Clinical information and CT images were obtained from the records of the Section of Oral and Maxillofacial Surgery, Kyushu University Hospital.

	Total	Male	Female
	15	9	6
Age(yr)			
Range	16 - 57	17 - 57	16 - 52
Mean	35.9	39.4	30.5
The duration from day of marsupialisation to day of having taken CT before surgery			
Range	136 - 1150	196 - 1150	136 - 535
Mean	413	467.2	331.7
Location of the tumours			
Molar region - Mandibular ramus	5	3	2
Angular region - Mandibular ramus	7	4	3
Anterior region - Molar region	3	2	1
Radiographic features			
Unilocular	10	6	4
Multilocular	5	3	2
Impacted teeth			
(+)	7	4	3
(-)	8	5	3

Table 1. Distribution of patients treated by marsupialisation for KCOT.

1.3. Marsupialization and secondary enucleation technique

Marsupialization has been used to relieve the pressure within the cystic cavity and allow new bone to fill the defect [22] (Fig. 1). This surgical technique usually involves making a bone window or opening in the wall of the tumor, partially debriding with an excision on the top portion of the tumor, and suturing the edges of the remaining cyst to the surrounding soft tissue. At the beginning of each treatment, marsupialization was performed simultaneously with a biopsy. In multilocular lesions, the intracystic partitions were removed to make a single cavity. After marsupialization, an obturator, made of acrylic resin, was used to keep the window open. The purpose of the obturator was to maintain continuity between the marsupialized tumor and the oral environment during the treatment process. The marsupialized window was kept open until the patients could withstand less aggressive treatment, such as enucleation and curettage. The inner volume of the tumor was estimated by filling the intracavity with saline [23] and measuring the distance between the inferior alveolar nerve and the tumor as well as the thickness of the peritumoral bone. Thus, the duration of marsupialization was different for each case.

The secondary surgery after marsupialization, was enucleation and curettage in which the KCOTs were enucleated, and the overlying mucosa was excised and subsequently curetted to adjacent healthy bone. Using a large round bur, curettage usually extended 1 to 2 mm in depth. This procedure was performed to ensure the removal of the epithelial remnants.

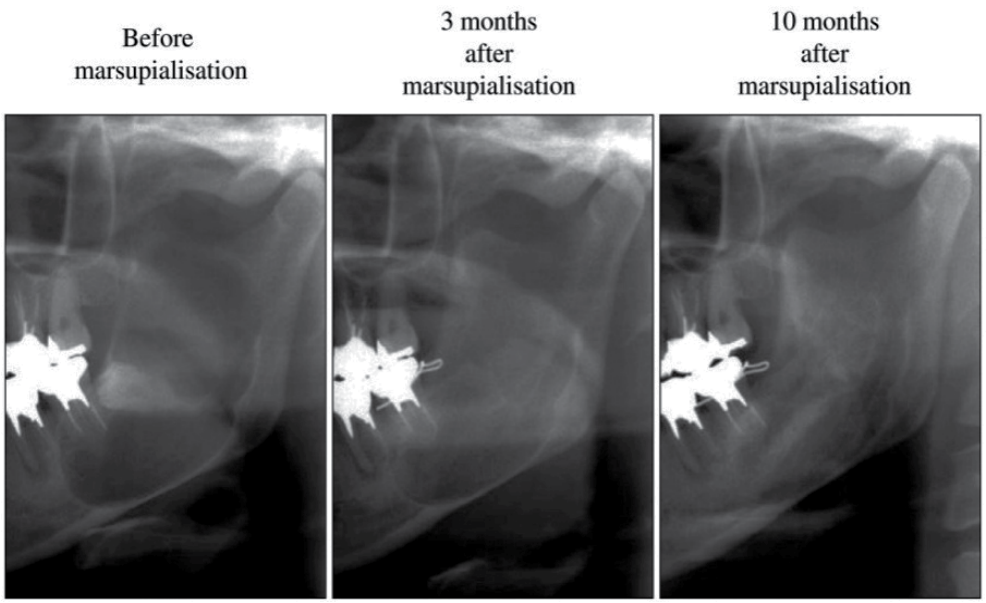

Figure 1. Panoramic radiographs of a typical case of marsupialisation and extraction of mandibular third molar associated witho KCOT; Marsupialised window was opened with extraction cavity. KCOT had been reduce successfully.

1.4. The effect of marsupialization by visual analysis

Fifteen KCOTs with 42 series of CT data taken during the marsupialization process were analyzed. Images were made with 1 or 2 mm thick contiguous axial scans (Aquilion®, Toshiba, Japan: 120 kV, 250 mA). All of the CT data taken before the secondary enucleation were segmented between the bone and tumor, and reconstructed in 3 dimensional (3D) images. The position adjustment was performed on each patient. The extraction and the position adjustments of the KCOTs were performed with 3D rendering software (VG-STUDIO-MAX 1.2®, Volume Graphics, Heidelberg, Germany) to examine the reduced focus of KCOTs visually.

1.5. The effect of marsupialization on diameter

The width (mm), depth (mm), and height (mm) were measured for each position adjustment with 3D shape analysis software (Rugle5®, Medic Engineering, Kyoto, Japan)(Fig. 2). For each patient, the change in diameter before and after marsupialization was measured.

To investigate correlations between the change in diameter and the duration after marsupialization, all measurements before marsupialization were converted to 100. The measurements after marsupialization were adjusted to the primary rate. The width, depth, height and diameters that were converted were statistically analyzed.

http://dx.doi.org/10.5772/52432

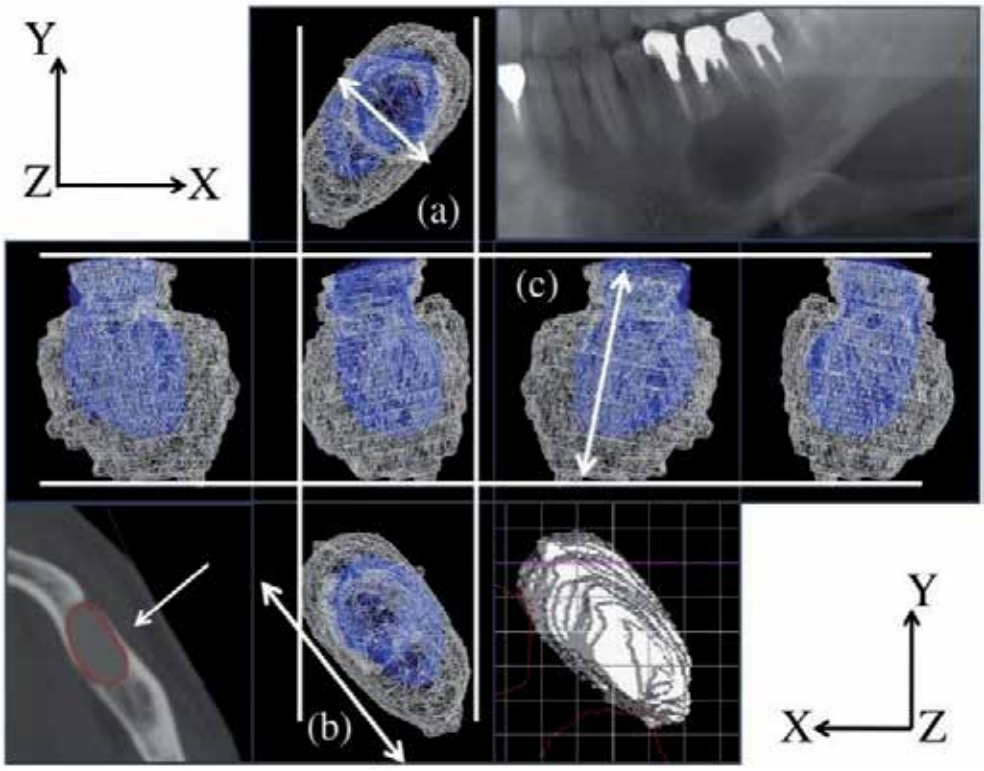

* 3-D visualised CT showed that all of the marsupialised KCOTs were visually reduced towards the window.
** (A) The width (B) The depth (C) The height

Figure 2. Overlaid 3-D images in the marsupialised period

1.6. The effect of marsupialization on the volume

The 3D data were used to measure the volume (mm^3) with Rugle5® and to determine the change in volume before and after marsupialization, similar to the observation on diameter.

The amount of volume reduction (mm^3) per day (V_r) was calculated using the formula (Fig. 3). V_r was defined as the quotient of the difference of the volume divided by the duration after marsupialization. To investigate correlations between the volume and V_r, these data were statistically analyzed. The regression formula obtained from former analysis of the volume was calculated using differential equations.

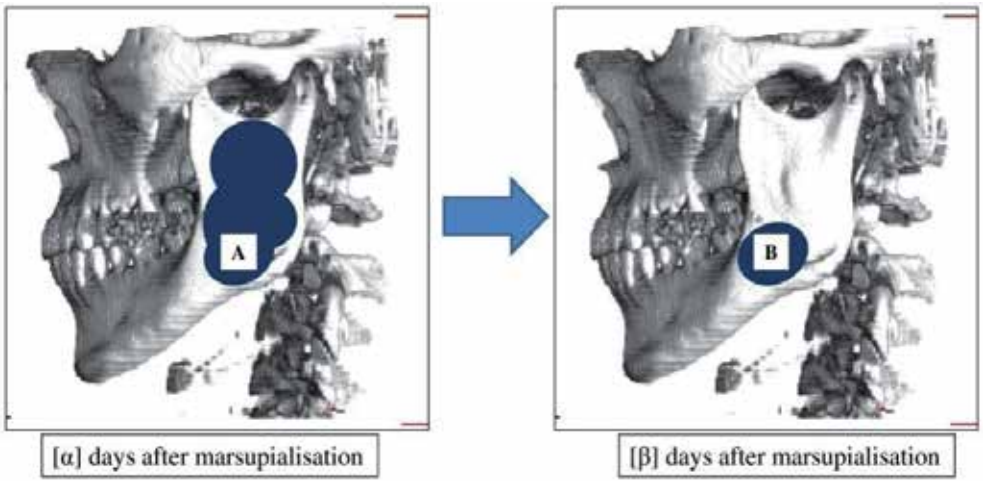

* The amount of the volume reduction per day (Vr) = [B] - [A] / [β] - [α]

Figure 3. Measurment of Vr of KCOTs after marsupialisation. Volume value was calculated on the CT images with Rugle5®. Vr = volume value [B] - volume value [A]/duration [β] - duration [α].The regression formula between Vr and volume value [A].The duration before marsupialisation was defined as 0.

1.7. Statistical analysis

Calculation of the polynomial regression analysis is based on the determination coefficient adjusted for the degrees of freedom with statistical software (Microsoft Office Excel 2007®, Microsoft Corporation, USA) and (Statcel 2®, Hisae YANAI, Saitama, Japan). The figure of the formula showing the volume (mm^3) and the duration after marsupialization (Fig. 8) was drawn with graph drawing software (GRAPES®, Katsuhisa TOMODA, Osaka, Japan).

1.8. Approximating the reduction and the change in diameter of KCOTs in the marsupialization period

All of the marsupialized tumors were reduced towards the window (Fig. 2). The width, depth, and height of the tumors were negatively correlated with the duration after marsupialization (Fig. 4). In the converted data, the regression analysis was performed using each diameter as an outcome variable D_x (D_w = width, D_d= depth, and D_h = height), and the duration after marsupialization was calculated as the predictor variable t. Statistically significant correlations (D_w, R = 0.88;D_d, R = 0.94; D_h, R = 0.89) were found between D_x and t (P<0.001). Thus, the results are as follows:

- $D_w = -7.3 \times 10^{-8} \times t^3 + 0.000162 \times t^2 - 0.12941 \times t + 100.1359$ (P<0.001, R = 0.88, adjusted $R^2 = 0.76$) …(Fig. 5)
- $D_d = 5.39 \times 10^{-5} \times t^2 - 0.0938 \times t + 99.53288$ (P<0.001, R = 0.94, adjusted $R^2 = 0.87$)…(Fig. 5)
- $D_h = -5.0 \times 10^{-8} \times t^3 + 0.000135 \times t^2 - 0.13246 \times t + 100.1141$ (P<0.001, R = 0.89, adjusted $R^2 = 0.78$) …(Fig. 5)

http://dx.doi.org/10.5772/52432

As shown in these results, each diameter had similar curves (Figs. 4 and5). The regression analysis was performed in the same way, using all diameters as outcome variable D_a and duration after marsupialization as the predictor variable t.

- $D_a = -4.9 \times 10^{-8} \times t^3 + 0.00013 \times t^2 - 0.12273 \times t + 100.0652$ ($P<0.001$, $R = 0.90$, adjusted $R^2 = 0.80$) …(Fig. 5)

Strong correlations were found between D_a and t.

Therefore, based on these results, marsupialized KCOTs tended to be reduced towards the window equally.

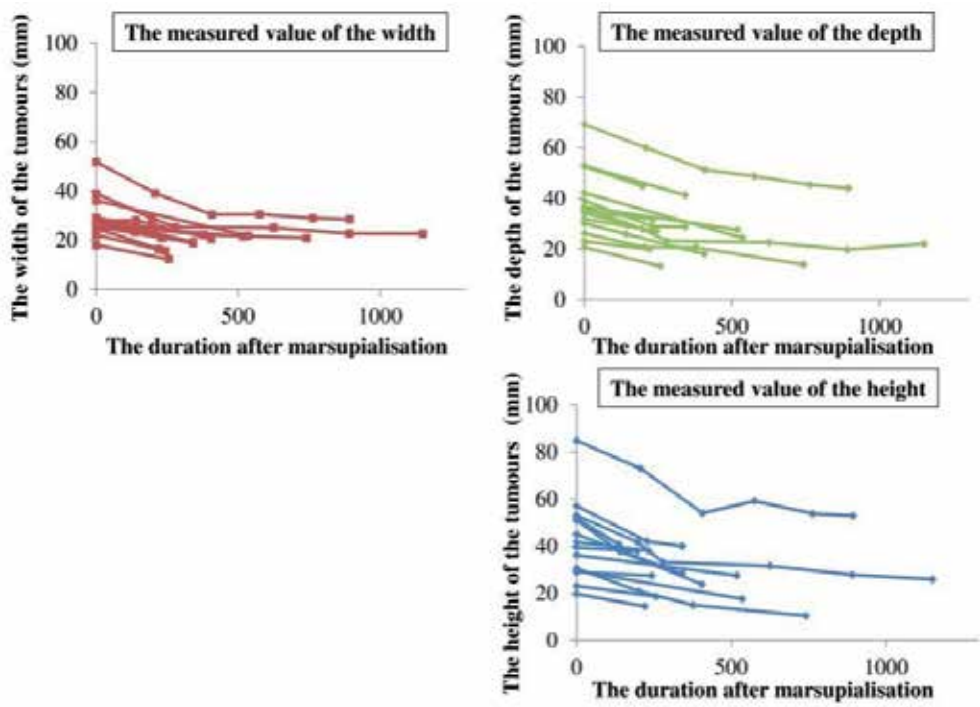

Figure 4. The width (mm), the depth (mm), and the height (mm) of KCOTs were negatively-correlated to the duration after marsupialisation.

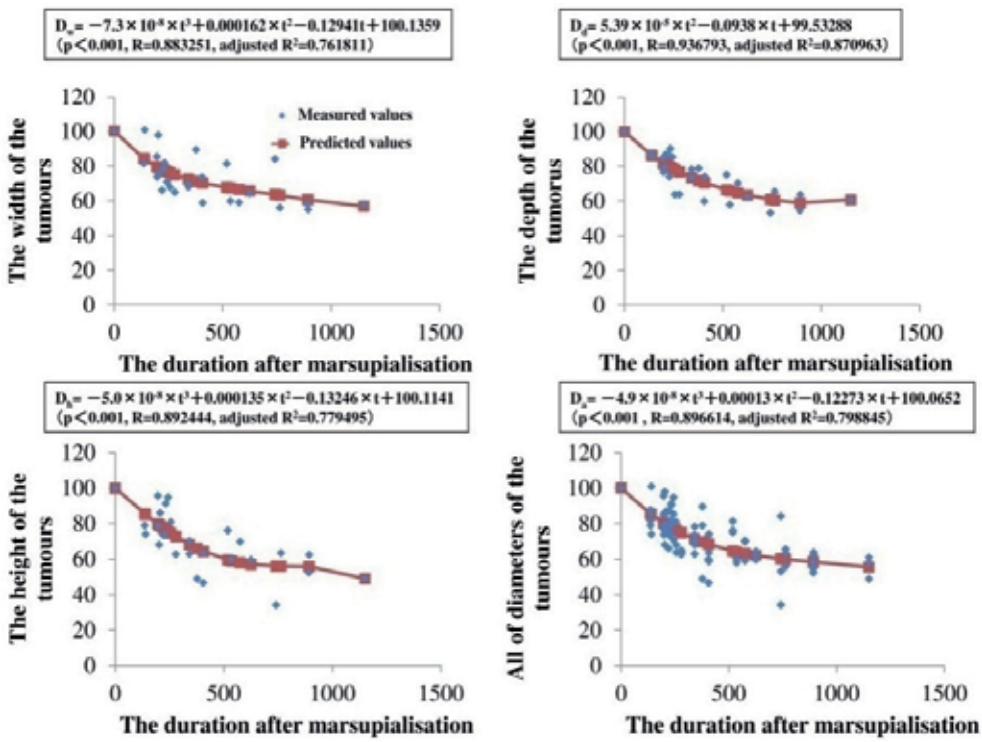

Figure 5. The regression formula of the width, depth, height and diameters ok KCOTs (mm) and the duration after marsupialisation (day)

1.9. Change of the volume of KCOTs in the marsupialization period

The volume of KCOTs was negatively correlated with the duration after marsupialization. The tumor seemed to reduce more quickly the larger they were (Fig. 6). Therefore, the V_r was calculated, and the regression analysis was performed using V_r as outcome variable V_r and the volume as predictor variable V. Statistically significant correlations were found between V_r and V.

- $V_r = -0.002915 \times V + 1.23595$ ($P<0.001$, $R = 0.92$, adjusted $R^2 = 0.85$)

Then y-intercept of the regression formula was converted to 0. There was almost no variation in the coefficient of correlation, and strong correlations were maintained between V_r and V.

- $V_r = -0.0029 \times V$…(Fig. 7) ($P<0.001$, $R = 0.92$)

Formula manipulation was performed (Fig. 8).

- $V = V_1 \times e^{-0.0029\,t}$…(Fig. 8) ($V_1$ means the volume before marsupialization)

http://dx.doi.org/10.5772/52432

Using the above formula (Fig. 8), the half-life and one-quarter-life of the volume of KCOTs were calculated. The half-life of the KCOT volume after marsupialization was 239.0 days, and the one-quarter-life was 478.0 days.

Based on the characteristics of Napier's constant (e), the volume half-life was approximately 240 days.

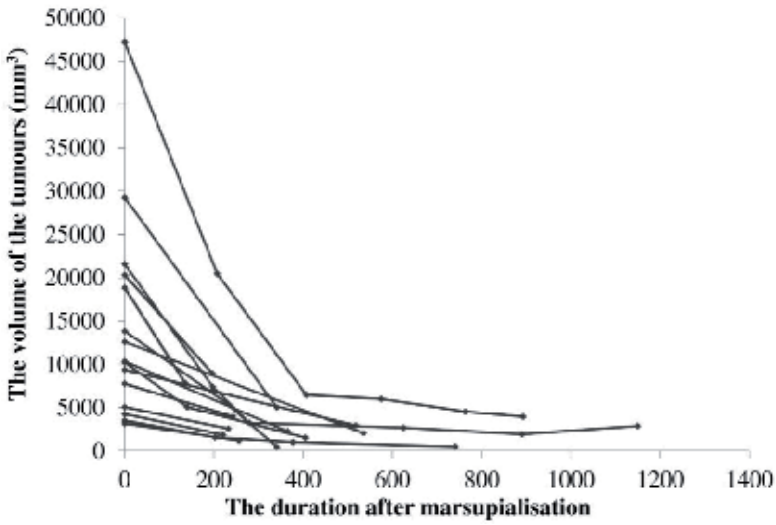

Figure 6. The measured value of the volume. The volumes of KCOTs (mm³) were negatively-correlated with the duration after marsupialisation.

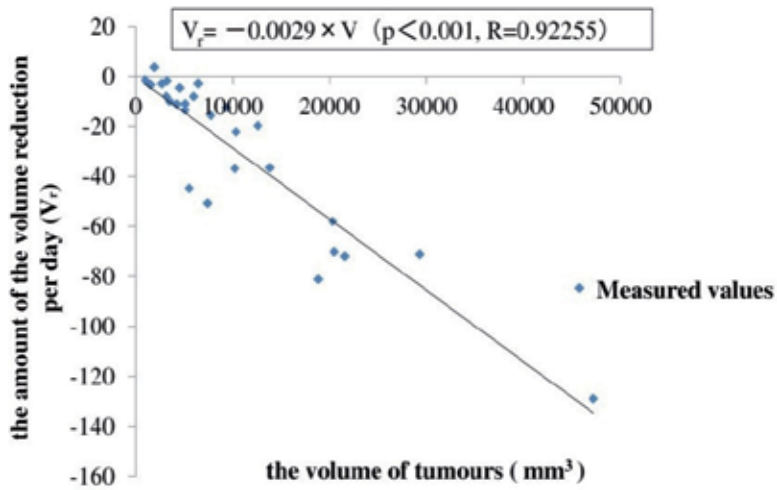

Figure 7. The regression formula of VR and the volume (mm³)

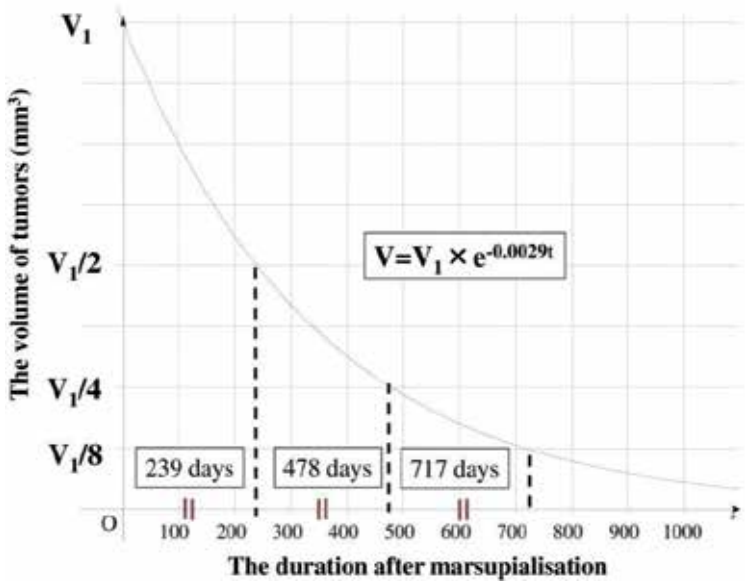

Figure 8. The formula of the volume in the KCOT (mm^3) and the duration after masupialisation (day).

2. Discussion

A number of studies have described that marsupialization surgery enables patients with KCOTs to experience less damage to important structures with secondary enucleation. Marsupialization also allows substantial improvements in the symptoms and quality of life of the patients [10-12, 17, 19-21]. However, the exact mechanism that promotes the reduction of KCOTs after marsupialization is unclear. We examined the morphologic characteristics of KCOTs to predict the prognosis after marsupialization. Important aspects on the effect of marsupialization on KCOTs were uncovered.

We have shown that marsupialized KCOTs were reduced equally towards the window, as has previously been reported. This reduction form of tumors resembled those of a balloon, and this concept may be significant considering the morbidity and quality of life of the patients. It seemed that it was better to open the window against the thin peritumoral bone or inferior alveolar nerve because marsupialization tended to be the most effective in the farthest region from the window.

Furthermore, we found that there was a linear relationship between the amount of the volume reduction per day (V_r) and the volume (V_r =-0.0029 × V). When we treated the effect of marsupialization as V_r, the result demonstrated that the effect of marsupialization was not the same in all cases and was affected by the duration after marsupialization. Larger tumors showed a stronger effect on marsupialization. Accordingly, it could be possible to enucleate the tumor only one month after marsupialization. V_r was proportional to the volume; therefore,

http://dx.doi.org/10.5772/52432

the differential equation and the formula between the volume and the duration after marsupialization ($V = V_1 \times e^{-0.0029\ t}$) was applied. The volume showed the exponential decay in the duration after marsupialization, and the V-t formula indicated that the characteristics or the speed of the reduction in postmarsupialized KCOTs was dependent on the premarsupialized volume (V_1). We felt that the marsupialized tumor was not significantly reduced when it was of small size.The marsupialized tumor was reduced in the half life of 240 days, according to Napier's constant e and the exponential function. When we focused on the cyclic nature and the regression coefficient of V_r-V formula (- 0.0029), we recognized that the reduction percentage in the volume tended to be unchanged for the same duration. This result was expected based on the hypothesis that the number of cells per unit volume was not based on the surrounding tumor, and that there was no significant change in pressure in the cavity and at the molecular level after marsupialization. However, the regulatory mechanisms of how tumors are reduced or the repair mechanisms of the normal bone are unclear. Many factors must be considered, including the elasticity of the wall, and a comparison between the maxilla and mandible, with or without impacted teeth, must be made. Further studies will be required to clarify these factors.

In addition, when the KCOTs were spherical, a 50% reduction in volume resulted in a 21% reduction in the radius of the sphere. Marsupialized KCOTs tended to be equally reduced towards the window in the tumor. Therefore, a 50% reduction in volume of KCOTs resulted in a 21% reduction in diameter as well as the sphere(Fig. 9).

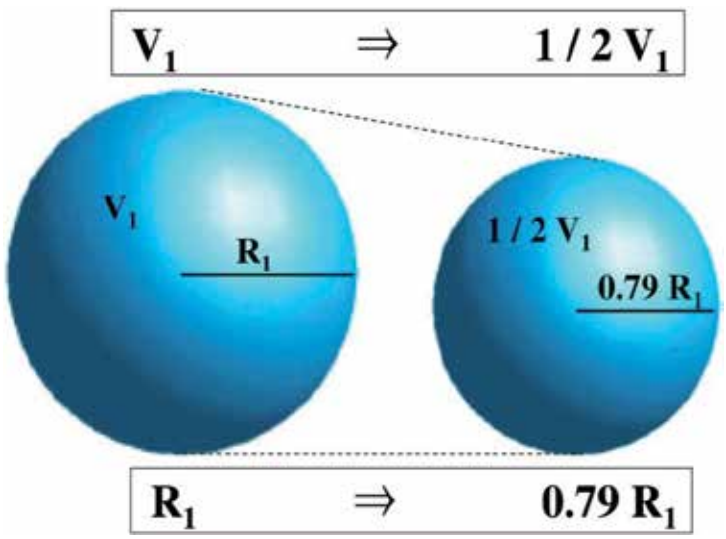

Figure 9. Differences between solid and plane in the reduction ratio. 50% of reduction in three-dimensional volume means 21% of reduction in the profile diameter or radius.

Although the data are not shown, there was no difference in the effect of treatment based on the size of opening window. The pressure within the cavity seemed to be sufficiently released when the window was opened to the degree that the biopsy results could be obtained.

We only referred to the evaluation of CT images, but we also needed follow-up with 2D images, such as a panoramic radiograph. Panoramic radiographs were easy to measure the tumor, and superior for grasping a whole image. Panoramic radiographs and intracystic cavities with sterile physiological saline were important to use as simple diagnostic methods for estimating the size of the cyst because there was a good correlation between the volume and the radiolucent area [23].

The well-controlled cases of marsupialized mandibular KCOTs could predict the future shape of the tumor with significant accuracy. Considering these features, the primary location of the mental nerve, and the thickness of the peritumoral bone, secondary operative planning before marsupialization could be carried out using CT,which would therefore decrease the mental burden on patients. Finally, there have been various types of treatments for KCOTs. Therefore, the choice of therapy was very important because marsupialization required a long period for treatment, and the patients may not have had a medical examination before treatment was completed.

Author details

Hajime Shudou[1*], Masanori Sasaki[2], Takahiro Yamashiro[1], Shizuo Tsunomachi[1], Yasuharu Takenoshita[3], Yasutaka Kubota[4], Tomohiro Ninomiya[2], Toshiyuki Kawazu[5] and Yoshihide Mori[6]

*Address all correspondence to: shudouh@yahoo.co.jp

1 Clinical Fellow, Section of Oral and Maxillofacial Surgery, Division of Maxillofacial Diagnostic and Surgical Sciences, Graduate school of Dental Science, Kyushu University, Fukuoka, Japan

2 Assistant Professor, Section of Oral and Maxillofacial Surgery, Division of Maxillofacial Diagnostic and Surgical Sciences, Graduate school of Dental Science, Kyushu University, Fukuoka, Japan

3 Associate Professor, Section of Oral and Maxillofacial Surgery, Division of Maxillofacial Diagnostic and Surgical Sciences, Graduate school of Dental Science, Kyushu University, Fukuoka, Japan

4 Lecturer, Section of Oral and Maxillofacial Surgery, Division of Maxillofacial Diagnostic and Surgical Sciences, Graduate school of Dental Science, Kyushu University, Fukuoka, Japan

5 Assistant Professor, Department of Oral and Maxillofacial Radiology, Graduate School of Dental Science, Kyushu University, Fukuoka, Japan

6 Professor, Section of Oral and Maxillofacial Surgery, Division of Maxillofacial Diagnostic and Surgical Sciences, Graduate school of Dental Science, Kyushu University, Fukuoka, Japan

http://dx.doi.org/10.5772/52432

References

[1] Brannon RB: The odontogenic keratocystA clinicopathologic study of 312 cases. part I. clinical features. Oral Surg Oral Med and Oral Pathol(1976). , 42, 54-72.

[2] Gonzalez-alva, P, Tanaka, A, Oku, Y, Yoshizawa, D, Itoh, S, Sakashita, H, Ide, F, & Tajima, Y. Kusama K: Keratocysticodontogenic tumor: A retrospective study of 183 cases. J Oral Sci(2008). , 50, 205-212.

[3] Browne RM: The odontogenickeratocystClinical aspects. Br Dent J(1970). , 128, 225-231.

[4] Payne TF: An analysis of the clinical and histopathologic parameters of the odontogenickeratocystOral Surg Oral Med and Oral Pathol(1972). , 33, 538-546.

[5] Pindborg, J. J. Hansen J: Studies on odontogenic cyst epithelium. 2. clinical and roentgenologic aspects of odontogenickeratocysts.ActaPatholMicrobiolScand (1963). , 58, 283-294.

[6] Toller P: Origin and growth of cysts of the jawsAnn R CollSurgEngl(1967). , 40, 306-336.

[7] Voorsmit, R. A, & Stoelinga, P. J. van Haelst UJ: The management of keratocysts. J MaxillofacSurg (1981). , 9, 228-236.

[8] Williams, T. P. Connor FA Jr: Surgical management of the odontogenickeratocyst: Aggressive approach. J Oral and MaxillofacSurg (1994). , 52, 964-966.

[9] Schmidt, B. L. Pogrel MA: The use of enucleation and liquid nitrogen cryotherapy in the management of odontogenickeratocysts. J Oral and MaxillofacSurg (2001). , 59, 720-725.

[10] Brondum, N. Jensen VJ: Recurrence of keratocysts and decompression treatment. A long-term follow-up of forty-four cases. Oral Surg Oral Med and Oral Pathol (1991). , 72, 265-269.

[11] Marker, P, Brondum, N, & Clausen, P. P. Bastian HL: Treatment of large odontogenickeratocysts by decompression and later cystectomy: A long-term follow-up and a histologic study of 23 cases. Oral Surg Oral Med Oral Pathol Oral RadiolEndod(1996). , 82, 122-131.

[12] Tucker, W. M, & Pleasants, J. E. MacComb WS: Decompression and secondary enucleation of a mandibular cyst: Report of case. J Oral Surg (1972). , 30, 669-673.

[13] Bramley P: The odontogenickeratocyst--an approach to treatmentInt J Oral Surg(1974). , 3, 337-341.

[14] Ephros, H. Lee HY: Treatment of a large odontogenickeratocyst using the brosch procedure. J Oral and MaxillofacSurg(1991). , 49, 871-874.

[15] Bataineh, A. B. al Qudah M: Treatment of mandibular odontogenickeratocysts. Oral Surg Oral Med Oral Pathol Oral RadiolEndod (1998). , 86, 42-47.

[16] Forssell, K, & Forssell, H. Kahnberg KE: Recurrence of keratocysts. A long-term follow-up study.Int J Oral and MaxillofacSurg (1988). , 17, 25-28.

[17] Cranin, A. N, & Madan, S. Fayans E: Novel method of treating large cysts of jaws in children. N Y State Dent J (1994). , 60, 41-44.

[18] Maurette, P. E, & Jorge, J. de Moraes M: Conservative treatment protocol of odontogenickeratocyst: A preliminary study. J Oral and MaxillofacSurg (2006). , 64, 379-383.

[19] Nakamura, N, Mitsuyasu, T, Mitsuyasu, Y, Taketomi, T, & Higuchi, Y. Ohishi M: Marsupialization for odontogenickeratocysts: Long-term follow-up analysis of the effects and changes in growth characteristics. Oral Surg Oral Med Oral Pathol Oral RadiolEndod (2002). , 94, 543-553.

[20] Pogrel MA: Treatment of keratocysts: The case for decompression and marsupializationJ Oral and MaxillofacSurg (2005). , 63, 1667-1673.

[21] Zhao, Y. F, & Wei, J. X. Wang SP: Treatment of odontogenickeratocysts: A follow-up of 255 chinese patients. Oral Surg Oral Med Oral Pathol Oral RadiolEndod (2002). , 94, 151-156.

[22] Giuliani, M, Grossi, G. B, Lajolo, C, & Bisceglia, M. Herb KE: Conservative management of a large odontogenickeratocyst: Report of a case and review of the literature. J Oral and MaxillofacSurg (2006). , 64, 308-316.

[23] Kubota, Y, Yamashiro, T, Oka, S, Ninomiya, T, & Ogata, S. Shirasuna K: Relation between size of odontogenic jaw cysts and the pressure of fluid within. Br J Oral MaxillofacSurg (2004). , 42, 391-395.

Section 5

Considerations in Radiotherapy and Chemotherapy: Current Treatment Guidelines

Chapter 9

Radiation and Chemotherapy in Oral and Maxillofacial Surgery

Orett E. Ogle and Levon Nikoyan

Additional information is available at the end of the chapter

http://dx.doi.org/10.5772/53402

1. Introduction

Oral cavity cancer is the sixth most prevalent cancer worldwide(1]and comprise about 85% of all head and neck cancers. Regions with a high incidence of oral cancer (> 6.9/100,000] are : North America, Brazil, Europe, South Africa, the Indian Subcontinent, and Australia Areas with low incidence (< 3.2/100.000] are Central America, Chile, West Africa, Middle East and China. [2]The higher incidence of oral cancer in high income countries, and increasingly in middle-income countries, is thought to be due to tobacco usage, unhealthy diets, alcohol consumption, inactive lifestyles and infection. The use of tobacco, including smokeless tobacco, and excessive consumption of alcohol are regarded as the major risk factors for oral cancer. [1]Although oral cancer originates from different types of tissues that are present in the mouth, around 85 - 90% are squamous cell carcinomas originating in the oral epithelium.The treatment of oral cancers is ideally a multidisciplinary approach involving the efforts of surgeons, radiation oncologists, chemotherapy oncologists, dental practitioners, nutritionists, and rehabilitation and restorative specialists. Curative treatment modalities are usually surgery and radiation, with chemotherapy added to sensitize the malignant cells to radiation, to decrease the possibility of metastasis, or as curative treatment for those patients who have confirmed distant metastasis. The factors that influence the choice of treatment modality are related to the tumor and the desires of the patient. Primary site, size of the tumor, lymph node involvement and the presence or absence of distant metastasis are factors which will affect a particular treatment option. Surgery is the most common treatment for mouth cancer, while oropharyngial cancer is usually treated with radiation, with or without chemotherapy. Most oncologist consider radiotherapy or chemoradiotherapy (CRT) as first-line therapy in oropharynx cancer due to the equivalent response rates compared with surgery. Salivary gland tumors are commonly treated with surgery initially. In general, Stage I and Stage II oral cancers may be treated successfully with either surgery or radiation therapy. Advanced Stage III and Stage IV cancers are typically treated by surgical resection followed by radiotherapy (RT) or CRT

INTECH
open science | open minds

© 2013 Ogle and Nikoyan; licensee InTech. This is a paper distributed under the terms of the Creative Commons Attribution License (http://creativecommons.org/licenses/by/3.0), which permits unrestricted use, distribution, and reproduction in any medium, provided the original work is properly cited.

2. Radiotherapy

Technological improvements in machines and techniques used for radiation therapy has given radiotherapy an advantage as the primary modality for treating oral cancer by having less patient morbidity and being well tolerated. Radiation therapy for oral cancer will be delivered either by external beam therapy (EBT) or by intensity-modulated radiation therapy (IMRT). EBT is administered with machines called linear accelerators, which produce high-energy external radiation beams. This beam or beams of radiation penetrates the tumor delivering tumorcidal doses. The newer linear accelerators have enabled radiation oncologists to significantly reduce side effects while improving the capacity to deliver radiation to the cancer with better cure rates. IMRT is an advanced mode of high-precision radiation therapy that utilizes computer-controlled x-ray accelerators to deliver controlled radiation doses to a malignant tumor or specific areas within the tumor. IMRT allows the precise delivery of high doses of radiation to the tumor while minimizing damage to adjacent tissues due to the sharp dose falloff gradient between the gross tumor and the surrounding normal tissue. IMRT can conform to the irregular shape of a tumor, delivering higher doses directly to the tumor cells with the added potential of also destroying more radioresistant cells. Numerous data have suggested that IMRT provides locoregional control in 90% of cases and is well tolerated by patients. (3]

2.1. Radiation protocols

A large number of radiotherapy techniques and protocols exist for the treatment of head and neck cancers. Deciding which technique to use is generally a complex one as it depends on the size, location and cellular components of the tumor.[4] As mentioned earlier, treatment modalities can be broadly classified into external beam therapy and intensity-modulated radiation therapy with few other techniques that have recently gained popularity in treatment of the head and neck cancer (Table 1). [5]

Radiation Therapy		
Technique	Description	Cancers Used
Brachytherapy	Radiation source is placed inside or near the tumor.	Many, including head and neck
Intensity-modulated Radiation Therapy	High-precision radiotherapy that uses accelerators to deliver precise radiation doses to the tumor	Head and Neck, Prostate, Lung, Brain
Gamma Knife	Radiosurgery, selective ionization of tissue, by means of high-energy beams of radiation. Production of ions and free radicals which are deleterious to the target cells.	Brain, prostate
Total Body Irradiation	Total Body Irradiation to suppress host's immune response.	Leukemia, Myelomas, Bone Marrow transplant
Charged Particle Radiotherapy	External beam radiation that uses protons and heavy particles as opposed to photons to deliver radiation.	Nasopharyngeal tumors. Sarcomas, Melanomas
Neutron Radiotherapy	Use of high energy, fast neutrons to delivery energy.	Salivary gland, prostate
Targeted Radionuclide Therapy	Use of Antibodies as carriers of radio nucleotides. Radioimmunotherapy	Many types based on antibodies

Table 1. List of commonly utilized radiation techniques. Modified from Clinical Radiation Oncology. 3rd ed. Leonard L. Gunderson JET, editor. Philadelphia: Saunders; 2012

http://dx.doi.org/10.5772/53402

External Beam, IMRT and brachytherapy are most commonly used in the head and neck region. Table 2 presents the list of most commonly occurring head a neck tumors and their general treatment rational and radiation sensitivity. [6]

Treatment of Selected Head and Neck Tumors			
Tumor	Radiotherapy	Chemotherapy	Surgery
Squamous Cell Carcinoma	+	+	+
Basal Cell Carcinoma	+		+
Kaposi's Sarcoma	+	+	+
Melanoma	+	+	+
Leiomyoma and Leiomyosarcoma			+
Rhabdomyoma and Rhabdomyosarcoma	+	+	+
Mucoepidermoid Carcinoma	+		+
Polymorphous Low-Grade Adenocarcinoma	+		+
Adenoid Cystic Carcinoma	+		+
Actinic Cell Carcinoma	+		+
Clear Cell Carcinoma			+
Hodgkin's Lymphoma	+	+	
Non Hodgkin's Lymphoma		+	
Multiple Myeloma		+	
Solitary Plasmocytoma of Bone	+		+
Leukemia		+	
Osteosarcoma	+	+	+
Chondrosarcoma			+
Ewing's Sarcoma	+	+	+
Burkitt's Lymphoma		+	
Granular Cell Tumor			+
Schwannoma			+
Neurofibroma			+

Table 2. Treatment of selected tumors. Modified from Ang KK. Advances in the Treatment of Head and Neck Cancer. In: James D. Cox KKA, editor. Radiation Oncology, Treatment, Technique Rationale. 9th ed. Philadelphia, PA: Mosby, Elsevier; 2010. p. 161-353

External beam radiotherapy depends on photons, moving packets of energy that deliver radiation to the tissues. When photons interact with matter, electrons are displaced from their orbits around the nucleus of the atoms in the irradiated tissue. The atom is left with a positive charge, and thus becomes an ion/'free radical', (hence the term "ionizing radiation").[7] The process continues with ionized particles transferring energy and setting more particles in motion. As the particles travel through the matter, however they continuously loose energy with the maximum loss occurring just before they come to rest. (Bragg's peak)[8] The depth in the tissue that the Bragg's peak occurs is dependent on the source of photons, and this is selected by the oncologist when determining what X-ray energy to prescribe. Radiation in the external beam therapy

is generated by linear accelerators. These are complex units that accelerate electrons by providing alternating microwave fields and are capable of focusing energy to accommodate target size. [9] These accelerators are capable of producing a large range of X-ray energy from 50kV to 20MV. For head neck cancers however the most useful range lies in 50-150 kV, the so-called superficial X-rays. This range is useful for most skin and mucosal cancers. At times when a larger radiation is required, orthovoltage X-rays can be utilized. This is radiation in the range of 200-300 kV and can penetrate tumors as deep as 3 cm. Intensity modulated radiotherapy (IMRT) is part of conformal therapy which as an advanced radiotherapy modality that relies on computerized tomography to calculate and recreate tumor's exact volume. Intensity modulation refers to the X-ray's beams variable strength to deliver exact radiation to the tumor proving maximum sparing to adjacent tissues. The overall process is outlined in Figure 1.

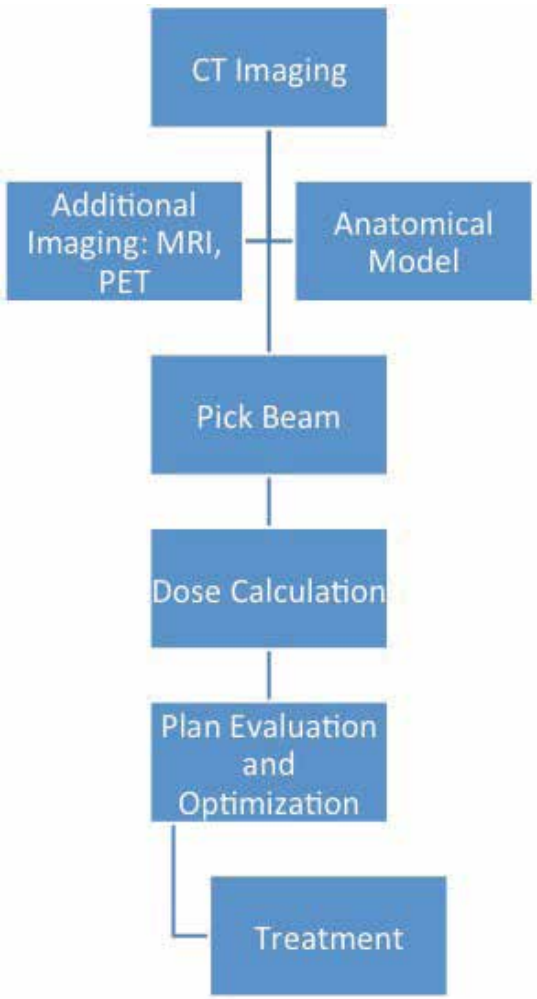

Figure 1. Intensity modulated radiotherapy treatment planning. Modified from Clinical Radiation Oncology. 3rd ed. Leonard L. Gunderson JET, editor. Philadelphia: Saunders; 2012

http://dx.doi.org/10.5772/53402

The treatment planning begins after obtaining an appropriate CT scans of the tumor area as well any other studies that will facilitate creation of a complete volumetric analysis (including soft tissue) as well as functional imaging of the tumor area. Three-dimensional model of the tumor area is then created inside a wide variety of specialized planning software. If needed 4-D imaging can also be utilized to accommodate motion (i.e. when lungs/ cardiac tissue is examined). Once the model is completed gross target volume is defined from the CT image and the radiation oncologist defines the clinical target volume. This is the volume of the tumor plus any additional area that should be treated.

2.2. Dental preparation of the patient for radiation

The status of the dentition has a significant effect on post-treatment quality of life among patients with head and neck cancer that will undergo radiation. A dentition in poor repair will increase the risk of post-radiation complications, particularly dentoalveolar infections that could lead to osteoradionecrosis. All patients who will be treated with RT for oral/head and neck cancer should undergo a comprehensive dental evaluation prior to treatment.Carious teeth, teeth with deep restorations or in poor periodontal health, along with partial bony impacted third molars should be extracted prior to RT if in an area that is expected to receive a dose of at least 50 Gy. Teeth that are out of the radiation treatment field, but have a hopeless prognosis or is symptomatic should also be extracted. Extraction of healthy teeth does not appear to prevent the development of osteoradionecrosis.[10]All indicated extractions should be completed prior to RT and primary closure over the extraction sites is preferred if possible. An adequate alveoloplasty should be performed to eliminated the possibility of bone edges ulcerating the mucosa as well as to make the mandible/maxilla ready for dentures. Ideally, all extractions should be completed approximately two weeks before the commencement of RT to permit proper healing. If the extracted teeth are outside of the treatment areas, however, radiation may be started sooner. The oral surgeon should attempt to do all the extractions within the portals of radiation at one sitting so as not to delay the cancer treatment. Postponing needed extractions of teeth that will be within the treatment area until after radiation is associated with an increased risk of non-healing and osteoradionecrosis.

2.3. Management of radiation associated problems

Radiotherapy in the upper aerodigestive tract can cause a wide spectrum of toxicities. The most basic toxicities are the impairment in the ability to breathe, communicate, and maintain an adequate oral intake. Oral intake is compromised by swallowing problems (dysphagia and odynophagia), poor taste (dysgeusia),trismus, xerostomia, and mucositis. In addition, there may be added dental complications from the effects of radiation dose to the mandible/maxilla and salivary glands. Acute toxicity is defined as events that occur during radiation therapy or within 90 days after the commencement of treatment and are largely unavoidable but transient. Late toxicity, can be minimized but is generally long-lasting and in some instances permanent.

2.4. Salivary gland damage and xerostomia

Decreased saliva production becomes evident within one to two weeks after the initiation of RT, and permanent reduction can be noted with cumulative radiation doses as low as 10 to 15 Gy to the parotid gland. [11] Doses greater than 24 to 26 Gy will cause permanent damage to the parotid glands. This can decrease the production of saliva from 40-80%. During and immediately after treatment, patients should be instructed to drink adequate fluids and to rinse and gargle with either a dilute solution of 25 percent hydrogen peroxide and 75 percent water or a weak solution of salt and baking soda (one-half teaspoon of salt and one teaspoon of baking soda added to one quart of water) several times daily. This regimen can loosen thick, tenacious oral secretions, and alleviate pain due to mild mucositis.[12] Amifostine is a drug that can reduce the incidence of xerostomia in patients undergoing radiotherapy for head and neck cancer. Although it is the only pharmacologic agent with established efficacy in the prevention of xerostomia, its role in patient management is uncertain and the use of amifostine is not standard. For patients that have lasting post-radiation xerostomia, pilocarpine may be used to stimulate saliva production from residual salivary gland tissue. However, pilocarpine is not recommended to prevent xerostomia in patients receiving RT for head and neck cancer.

2.5. Mucositis

From the second or third weeks onwards, almost all patients undergoing head and neck cancer RT will experience mucositis. Radiation-induced loss of stem cells in the basal layer interferes with the replacement of cells in the superficial mucosal layers when they are lost through normal physiologic sloughing. The subsequent denuding of the epithelium results in mucositis, which is painful and will interfere with oral intake and nutrition. Mucositis is managed symptomatically. Good oral hygiene is imperative. Dietary modification will be necessary, and topical agents for superinfections and pain may be required. The patient should avoid acidic or spicy foods, sharp foods (eg, chips), caffeine, alcoholic beverages and alcohol-containing mouthwashes. Secondary bacterial, fungal (oral candidiasis), and viral (herpes) infections should be treated with appropriate agents. Localized mouth pain can be treated with topical anesthetics (example 2 % viscous lidocaine). This may be combined with an antacid suspension (Mylana,Maalox, Gelusil) and/or diphenhydramine (for local drying effect). Dexamethasone solution (an anti-inflammatory), tetracycline suspension (antibiotic) or nystatin (antifungal) may also be added to the mixture.

2.6. Dysgeusia

An abnormal or impaired sense of taste (the sense of taste may also be affected by impaired olfaction). An altered sense of taste and/or smell may contribute to nutritional difficulties and weight loss; 67% of patients treated by RT have dysgeusia. There is no successful treatment for this problem and dietary counseling should be instituted to counteract a lack of appetite.

http://dx.doi.org/10.5772/53402

2.7. Orofacial pain

Long-acting opiates (oxycontin, levorphanol, oxymorphone) should be used as needed during the treatment period. For patients who cannot swallow oral medication, transdermal fentanyl may provide good pain relief. Short-acting opiates (morphine, codeine, oxycodone) should be used for breakthrough pain.

2.8. Trismus

Limited jaw opening during therapy is typically secondary to pain. For that reason, passive motion devices are generally not used during radiotherapy. By contrast, passive motion devices (TheraBite, E-Z Flex) can generally be instituted early in the postoperative period. Adequate pain control will be necessary.

3. Osteoradionecrosis

One of the most serious complications of radiation therapy is postradiation treatment necrosis-osteoradionecrosis. This is generally a delayed onset disease that usually takes significant radiation to develop and manifests itself after the irradiated area is subjected to dental surgery, trauma and ongoing periodontal infection. [13-15] Although osteoradionecrosis is closely associated with above mentioned factors, spontaneous appearance of the disease is not unusual with documented incidence in the literature.[16] The incidence of osteoradionecrosis is variable with 2.6% to 22% for the mandible with significantly lower incidence in the maxilla. [17, 18] The precise mechanism of injury is still unknown but the progression the disease begins with a slow change in the matrix of bone after irradiation. The initial changes result from injury to the remodeling system, i.e. the osteocytes, osteoblasts, and osteoclasts. Osteoblasts tend to be more radiosensitive than osteoclasts, leading to increase in the initial destruction of bone. [19, 20]The later changes result from alterations of the vascular system itself; causing fundamental damage to bone architecture. Radiation injury to the fine vasculature of the bone first leads to hyperemia, followed by endarteritis, thrombosis, and progressive occlusion and obliteration of the small vessels. This results in a further reduction of the number of cells and progressive fibrosis within the bone. With time, the marrow exhibits marked acellularity, hypo- or avascularity, and significant fatty degeneration and fibrosis. The endosteum atrophies with significant loss of active osteoblasts and osteoclasts. The periosteum demonstrates remodeling with significant overall loss of blood supply.[21] Although in the past osteoradionecrosis was mainly considered an infectious entity[22, 23], it is currently accepted to be a problem of wound healing with infecting organisms being mostly contaminants. [16] According to this model the hypoxic, hypovascular, hypocellular tissues have reduced ability to replace normal cellular and collagen loss, which eventually results in tissue breakdown. The weakened tissues have reduced ability to heal relevant wounds, since the metabolic demands exceed the vascular supply. The signs and symptoms of osteoradionecrosis will usually begin sometime after the radiation therapy. First as an exposed, non-healing area of the bone that progressively enlarges and becomes painful. The area can show evidence of secondary

infection with progression to sequestrate formation, cutaneous fistulae and even pathologic fractures. [18, 24] The diagnosis of osteoradionecrosis is established on a combination of clinical features and radiological features. Plain dental radiographs show decreased bone density. Computed tomography scans show bone abnormalities, such as focal lytic areas and cortical breaks. MRI and as well as bone scans can also be helpful in diagnosis. [25, 26]

Prevention of osteoradionecrosis is centered on patient education and reduction of risks factors. All carious and non-restorable teeth should be extracted prior to the beginning of the radiation therapy. Periodontal concerns should be addressed and any teeth with questionable prognosis should be strongly considered for extractions. If the oral hygiene is controlled and considered dental surgery is completed 14-21 days prior to beginning of the radiotherapy the risk of developing osteoradionecrosis becomes insignificant. [27]Extraction of teeth during and after radiation therapy posses a significant risks for osteoradionecrosis. [28, 29] If extractions are required in post-radiation therapy then atraumatic surgery is indicated with tension free primary closure. Antibiotic coverage is also advised with either penicillin or clindamycin. [18, 30]Hyperbarric oxygen therapy should be strongly considered for prevention and treatment of osteoradionecrosis (see next section).

The mainstay of treatment of osteoradionecrosis remains antibiotic treatment with limited curettage, debridement and removal ofsequestrae. More extensive surgical therapies are indicated for refractory lesions [31]. The first step is debridement of all bone that is no longer vascularized; as this dead bone, if not removed, will continue to promote further bacterial growth. Further and more invasive surgical techniques include extensive sequestrectomy combined with marginal or complete resection of affected parts of the mandible (and stabilization of the continuity defect). Hyperbaric oxygen therapy should be strongly considered as it has been shown to improve healing. [32]

4. Hyperbaric oxygen

Hyperbaric oxygen is defined as administration of 100% oxygen under pressure that is significantly higher than the ambient pressure. For patients receiving hyperbaric oxygen it is possible to administer nearly fifteen times more oxygen. [33] The use of hyperbaric oxygen (HBO) therapy in osteoradionecrosis is based on the principle that oxygen stimulates collagen synthesis, matrix deposition, angiogenesis, epithelialization, and the eradication of bacteria. [34]The immediate effects of breathing high concentrations of oxygen in increased pressure causes an increase in the tissue's internal oxygen pressure, leading to vasoconstriction, enhanced oxygen delivery, edema reduction, phagocytosis activation, and an antiinflammatory effect. The long-term effects are neovascularization, osteogenesis, and a stimulation of collagen production by fibroblasts, all promote wound healing. Generally, two types of chambers exist: monoplace and multiplace. The monoplace chamber is a HBO chamber that is suited for only one patient with no direct access to the patient while he or she is receiving the therapy. Multiplace, ICU compatible chambers on the other hand are able to accommodate multiple patients and even nursing staff. Although the exact mechanism of HBO therapy is

http://dx.doi.org/10.5772/53402

not understood, what is known is that HBO appears to reverse some of the deleterious effects of radiation on bone. Several studies that focused on HBO's effects on osteoblast proliferation have concluded that HBO has an effect in increasing osteoblasts differentiation into osteogenic phenotype but not necessarily overall increase in cellularity of the bone.[35]. Use of HBO in treatment of osteoradionecrosis was discussed as early as 1983, when Marx proposed staging based on disease progression and response. [16] This was later addressed by Kagan and Schwartz when they proposed a three-stage system where the disease is classified based on clinical and radiologic findings and treatment is determined based on the stage, similar to the approach for malignancies of the head and neck.[36] Figure 2 summarizes treatment proposed by Marx that is dependent on disease response to HBO therapy.

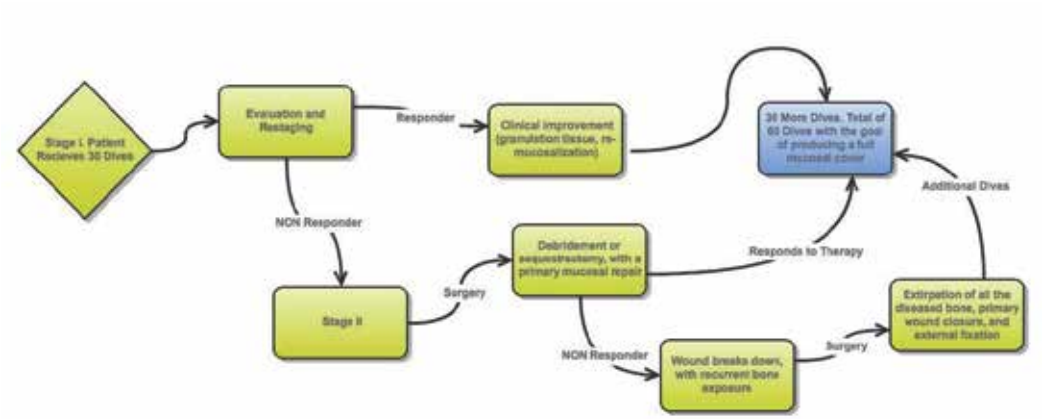

Figure 2. HBO Treatment protocol based on response to HBO, modified from Marx RE. A new concept in the treatment of osteoradionecrosis. J Oral Maxillofac Surg. 1983 Jun;41[6]:351-7.

Current treatment protocols vary considerably but they include utilization of panoramic imaging and CT findings in conjunction with clinical findings to determine if a patient has early, intermediate, or advanced stage disease. [37]Table 3 summarizes currently accepted treatment protocols.

	Current Concept in management of osteoradionecrosis with HBO Therapy		
	Stage I Disease	Stage II Disease	Stage III Disease
Definition	Small, superficial, localized bone resorption with cutaneous or mucosal dehiscence.	Larger and deeper areas of bone resorption. Cortical and medullary bone are involved and the mucosal or cutaneous areas of breakdown are moderate in size.	Full thickness devitalization of bone, resorption of the inferior border of the mandible, fistula or a pathological fracture
Initial Therapy	Conservatively with local wound care (oral rinses), HBO therapy for 20 dives and antibiotic therapy to cover the super-infection	Antibiotics, trans-oral debridement or sequestrectomy, and HBO therapy (20 dives pre-operatively). All necrotic bone is debrided to a base of bleeding bone and a primary mucosal closure is performed	Aggressive surgical extirpation of all diseased hard and soft tissue, and then immediate reconstruction is performed using a free tissue transfer. NO HBO
Further Treatment	If patients show definitive improvement, an additional 10 dives of HBO is given to allow for additional healing of the surrounding soft tissue	All patients receive an additional 10 dives of HBO post-operatively	Bony continuity is re-established immediately and patients can undergo a functional dental rehabilitation in a timely manner. NO HBO
If no Response	Patients that do not show signs of healing undergo a trans-oral debridement and additional HBO therapy	Aggressive surgical extirpation of all diseased hard and soft tissue and an immediate reconstruction with a well-vascularized free tissue transfer	Maintaining primary closure, rehabilitation with dental implants. NO HBO

Table 3. Summary of Current HBO use in Osteoradionecrosis. Modified from Jacobson AS, Buchbinder D, Hu K, Urken ML. Paradigm shifts in the management of osteoradionecrosis of the mandible. Oral Oncol. 2010 Nov;46[11]:795-801

5. Surgery in the post-irradiated patient

Dental extractions or minor oral surgery in patients who have undergone radiation therapy for cancer in the head and neck carry the risk of one of the most serious and devastating complications of head and neck radiotherapy, that of osteoradionecrosis (ORN). Elective oral surgery on irradiated bone should therefore be avoided. The risk of ORN does not decrease with time. When contemplating exodontia or minor oral surgery in the irradiated patient, special consideration should be given to issues such as radiotherapy history, surgical assessment, surgical procedure and the role of antibiotics and hyperbaric oxygen.

The actual field of radiation should be noted as extractions performed outside the area of radiation do not constitute a risk factor to the development of ORN. Ionizing radiation causes irreversible cellular and vascular damage resulting in hypoxic, hypocellular and hypovascular tissue. This fact greatly affects the reparation process and there is a consensus that extractions in irradiated fields must be executed with as little trauma as possible. Sectioning multi-rooted teeth, gentle elevation of roots, alveolectomy with careful bone trimming, conservative flaps, primary closure without tension and removal of few teeth per session minimize postoperative complications and are associated with lower ORN rates.[38] Prophylactic antibiotics should be used as adjuvant therapy and the antibiotics continued for 10 – 14 days post-extraction. There is no consensus about the employment of antibiotics to prevent ORN however, and some authors have expressed the opinion that an antibiotic as a sole agent is not sufficient to reducing the risk of ORN. Once dental extractions become unavoidable after radiotherapy, it should be done with adjuvant therapies – hyperbaric oxygen (HBO) with or without antibiotics- and rigorous follow-up after the surgical procedures.

The subject of placing dental implants in irradiated bone is not clear. Some papers have shown that implants can be successfully oseointegrated if HBO is used as an adjuvant therapy. [39] On the other hand, Franzen et al reported a 95 % (19/20 implants) successful osseointegration with Brånemark implants placed in irradiated mandibles with stability of the implants after 3 to 6 years of observation. Their oral surgical procedures were carried out without adjunct hyperbaric oxygen therapy, and their successful results demonstrates that adjunctive measures are not always necessary in the oral rehabilitation after radiotherapy.

Soft tissue radionecrosis results from damage done to non-osseous tissues by ionizing radiation during the course of radiotherapy. Once the patient is exposed to the radiation beam, the soft tissue will begin to manifest ischemic changes. Ischemic tissue may survive without adequate blood supply for a long period of time, until a traumatic or infectious incident triggers the events leading to extensive tissue death – soft tissue radionecrosis. Surgeons attempting maxillofacial surgery in or adjacent to the radiated area will confront numerous complications. Oozing of blood during the procedure is common and difficult to control. Incisions made through irradiated tissue may not heal and the risk of infection is increased.

After the first post-irradiation year the most significant problems arising during this period result from chronic deterioration of the microvasculature with resulting hypoperfusion and tissue hypoxia. Such developments trigger an increasing tissue fibrosis,

http://dx.doi.org/10.5772/53402

parenchymal degeneration, and lower resistance to micro-organisms and trauma. The situation can be optimized by bringing additional blood supply to the area via a vascularized flap or by using HBO. Treatment with hyperbaric oxygen therapy has remarkably changed the treatment of soft tissue necrosis disease. HBO allow tissues and vessels to be hyperoxygenated and promotes healing.

6. Role of chemotherapy in head and neck cancer

The use of chemotherapy in head and neck cancer has evolved greatly over the last three decades. While it was initially confined to patients with recurrent or metastatic disease, it is now frequently used as an initial curative component of combined modality therapy. When combined with radiation therapy,chemotherapy has been shown to enhance the effectiveness of the radiation making it more active against tumor cells. Chemotherapy by itself, however, has not changed the recurrence rate of oral squamous cell carcinoma but it has increased the rates of organ preservation and decreased the rates of distant metastasis when combined with radiotherapy. Chemotherapeutic agents also have a role in the palliative treatment of squamous cell cancer of the head and neck. To date, the agents found to be most effective for treating oral cancer include cisplatinum, carboplatinum, taxanes, 5-fluorouracil, methotrexate, and ifosphamide. These agents have been used alone or in combination in a variety or regimens. The agents vary in their single agent response rate and toxicity.

Outside of the head and neck, chemotherapy is used for cancer patients that are not curable by regional modalities (surgery and/or radiation) and is, at this time, the best adjuvant to local therapy in a wide range of human malignancies. Although some tumors are treated with a single medication, chemotherapy regimens most often involve the use of several antineoplastic drugs (combination therapy).

All chemotherapeutic agents act by interfering with cell division and are most active against rapidly dividing cells. Malignant tissues are made up of rapidly dividing cells characterized by rapid synthesis of DNA, and non-dividing cells with slower DNA synthesis. Most of the drugs used in chemotherapy work by affecting either enzymes or substrates acted upon by enzyme systems which relate to DNA synthesis or function. For treating cancer the majority of the agents exploit kinetic differences between normal and malignant cells by acting preferentially on the cells that are dividing at a faster rate. Consequently, malignant cells will be destroyed faster than normal cells at the tumor site. However, normal cells that have a high proliferative capacity rivaling malignant cells (bone marrow, gastrointestinal mucosa, oral mucosa, skin and hair follicles) will also be severely affected. The side effects of chemotherapeutic agents, therefore, include: myelosuppression (leukopenia, thrombocytopenia and anemia), nausea, vomiting, diarrhea, mucosal ulceration, dermatitides and alopecia.

Oral and maxillofacial surgeons will generally not be treating oral cancer patients with chemotherapy. They may, however, need to manage these patients for oral surgical procedures.

The surgical and anesthetic considerations of patients on cancer chemotherapy will be related primarily to an awareness of the multiplicity of noxious side effects presented by the various

drugs. Preoperative evaluation will consist of a thorough history and physical exam, with focus on the clinical effects of the negative side effects which could increase morbidity and mortality. Routine laboratory test should include: CBC, serum electrolytes and urinalysis. Depending on the drug, and other findings a LFT, chest X-ray, EKG and platelet function tests may be required.

6.1. Chemotherapeutic drugs

Chemotherapy drugs are classified according to how they work. The main types of chemotherapy drugs are described below along with their noxious effects.

6.1.1. Alkylating agents

Alkylating drugs undergo electrophilic chemical reactions that result in the formation of covalent links (alkylation) with DNA. The 7-nitrogen atom of guanine residues in DNA is particularly susceptible to formation of a covalent bond which results in a miscoding of DNA information or opening of the purine ring with damage to the DNA molecule. The alkylating agent can act on the DNA molecule at any stage of cell division.

Side effects: Bone marrow suppression is the most important- lymphocytopenia is usually present within 24 hours. Hemolytic anemia, alopecia, nausea and vomiting occurs commonly. Inhibition of plasma cholinesterase activity can cause prolonged skeletal muscle paralysis after administration of succinylcholine. Pneumonitis and pulmonary fibrosis may also occur.

Plant alkaloids: Referred to as "Vinca alkaloids" arrest cells in the metaphase of mitosis by binding to tubulin and thereby inhibiting microtubular function. Useful Vinca alkaloids derived from the periwinkle plant are Vinblastine and Vincristine. Paclitaxel is an extract of the bark of the Pacific yew. Despite their structural similarity, there is a not cross tolerance between them.

Side effects: Myelosuppression (leukopenia, thrombocytopenia and anemia) is the most common and appears 7 - 10 days after the start of therapy. Other commonly occuring side effects are: symmetric peripheral sensory-motor neuropathy, ataxia and transient depression. Autonomic neuropathy with orthostatic hypotension, bowel motility dysfunction, and cranial nerve involvement {weakness of extraocular muscles and laryngeal nerve paralysis with hoarseness) are seen in 10% of patients. SIADH occurs with vincristine.

6.1.2. Antimetabolites

Antimetabolites act as fraudulent analogues of vital physiological substrates that inhibit the synthesis of DNA or its nucleotide building blocks. They include analogues of folic acid (methotrexate), pyrimidine (cytosine arabinoside) and purine (6-mercaptopurine). These drugs interact directly with specific enzymes, leading to inhibition of that enzyme and subsequent synthesis of an aberrant molecule that functions abnormally. These drugs are immunosuppressants.

http://dx.doi.org/10.5772/53402

Note: Methotrexate is sometimes used for the treatment of some nonmalignant disorders: psoriasis and rheumatoid arthritis.

Side effects: Depends on the analogue that is used..

Methotrexate: GI (ulcerative stomatitis and diarrhea) and bone marrow (leukopenia and thrombocytopenia) side effects are most common. Hemorrhagic enteritis and death from intestinal perforation are other common side effects. Renal toxicity (10%) and pulmonary toxicity (8%) may also occur.

Cytosine arabinoside:Myelosuporession (leukopenia, thrombocytopenia and anemia) is the most common, GI disturbance, stomatitis and hepatic dysfunction also occurs less frequently.

Mercaptopurine: The principal side effect is a gradual development of bone marrow depression resulting in thrombocytopenia, granulocytopenia and anemia. Anorexia, nausea and vomiting are also common. Jaundice associated with bile stasis, and occasionally hepatic necrosis, occurs in 30% of patients.

6.1.3. Antitumor antibiotics

Antitumor antibiotics are natural products of certain soil fungi. Their effects are produced by the formation of relatively stable complexes with DNA, thereby inhibiting DNA synthesis, RNA synthesis, or both. Like antibiotics used for their antimicrobial activities these antitumor antibiotics all act differently. Some commonly used antibiotics are:

Acinomycin D (Dactinomycin): Binds to DNA in rapidly proliferating cells blocking RNA polymerase and thus the transcription of DNA.

Bleomycin: Water solubleglycopeptides that differ from one another in their terminal amine moiety (there are more than 200 congeners). They cause fragmentation of DNA..

6.1.4. Enzymes

L-asparaginase is an enzyme with useful chemotherapeutic effects. It depletes cells of the non-essential amino acid asparagine. Most human tissue have the capacity to synthesize asparagine by the action of L-asparagine synthetase. Some tumor cells, particularly those of T-cell lineage, lack asparagine synthesis capability and require exogenous asparagine to proliferate. As a result, depletion of circulating pools of asparagine by L-asparaginase results in inhibition of protein synthesis and ultimately cell death.

Side effects: In contrast to other chemotherapeutic drugs, asparaginase has minmal effects on bone marrow, oral and GI mucosa,or hair follicle. However, it carries the risk of coagulopathy. Hepatotoxicity is clinically evident in 10 - 20% of patients (increased P/T) and 50% have biochemical evidence of liver dysfunction.

6.1.5. Random synthetics

Examples of synthetic chemotherapeutic drugs are: Cisplatin, hydroxyurea, procarbazine, and mitotane.

Cisplatin: An inorganic platinum-containing complex (a heavy metal) that enters cells by diffusion and disrupts the DNA helix. Its action is to cause DNA breaks and cross- link complimentary DNA strands that prevent replication. Renal toxicity is prominent and can lead to renal failure. Myelosuppression is also seen, along with ototoxicity (manifested by tinnitus), nausea, vomiting and peripheral sensory neuropathies.

Hydroxyurea: Acts on the enzyme ribonucleosidediphosphatereductase to interfere with the synthesis of DNA. Myelosuppression, nausea and vomiting are the major side effects.

Procarbazine: Inhibits DNA synthesis. Myelosuppression, nausea and vomiting are the major side effects. Sedative effects and depression are prominent. This drug is a weak MAO inhibitor so tricyclic anidepressant should be used with caution. Synergism occurs with barbiturates, narcotics, phenothiazines and sedatives.

6.1.6. Hormones

Hormones - corticosteroids, progestin, antiestrogens and antiandrogens - slow the growth of some cancers that depend on hormones.

Corticosteroids: Possess lympholytic effects and suppress mitosis in lymphocytes. They are used to treat acute lymphoma in children (not adults) and malignant lymphoma.

Progestins: Used for endometrial carcinoma because it slows the overstimulation of the endometrium which cause the neoplastic changes.

Estrogens and Androgens: Malignant changes in the breast and prostate often depend on hormones for their continued growth. For example, prostatic cancer is stimulated by androgens, so giving estrogen (diethylstilbestrol) will slow the growth of the tumor cells. Estrogens and androgens are valuable in the treatment of advanced breast cancer. Malignant tissues that are responsive to estrogens contain receptors for that hormone, whereas malignant tumors lacking these receptors are unlikely to respond hormonal manipulation. Hypercalcemia is often associated with androgen or estrogen therapy.

Antiestrogens: Tamoxifen binds to estrogen receptors and inhibits continued growth of estrogen-dependet tumors. It is used for palliative treatment of advanced cancer of the breast in postmenopausal females. Side effects are hot flashes, nausea and vomiting.

Antiandrogens: Flutamide is a nonsteroidal antiandrogenic drug used for prostate cancer. It prevents androgen binding to androgen receptors. Side effects are skeletal muscle weakness, osteoporosis and methemaglobinemia (at levels > 35% pulse oximetry readings will approach 85%)

7. Oral and maxillofacial surgery considerations

The bone marrow suppression caused by the chemotherapeutic agents will pose the greatest concerns to the oral and maxillofacial surgeon. Bone marrow suppression is a major side effect

http://dx.doi.org/10.5772/53402

of nearly all of the widely used agents. It manifests as neutropenia, anemia and thrombocytopenia. The decreases in WBCs and platelets will be the major issues that the surgeon will need to manage.

Myelosuppression: Caused by nearly all of the chemotherapeutic agents, is reversible and should be close to normal within 6 – 8 weeks after the drugs have been stopped. The surgeon should therefore allow about 2 months after chemotherapy for bone marrow to regrow. Neutropenia and thrombocytopenia will be the major concerns to the surgeon.

Neutropenia: An absolute neutrophil count (ANC) of less than 1500/mm^3 The risk for infection is related to the severity and duration of the neutropenia

Categorization of neutropenia:

1,000 - 1,500 mild

500 – 1000 moderate

< 500 severe

Patients with mild neutropenia do not require prophylactic antibiotic for routine oral surgery. The authors believe that patients with moderate neutropenia should be given prophylactic antibiotic for invasive procedures such as tooth extraction, followed by a 7 day course of antimicrobials to prevent secondary infection. Severe neutropenia cases must be given prophylactic antibiotic for any oral surgical procedure. Ciprofloxacin plus amoxicillin are recommended for adult patients who are at low risk for complications. Patients who have higher risk should receive vancomycin. This should also be followed by a 7 day course of antimicrobials to prevent secondary infection. The antibiotic should cover the normal oral flora.

Thrombocytopenia: Chemotherapy induced thrombocytopenia typically occurs 6 – 10 days after administration of the drug. The risk of for excessive bleeding with invasive procedures occur at counts below 50,000/mm^3 Platelet transfusion is the primary method of managing thrombocytopenia. The usual therapeutic dose for transfusion is one platelet concentrate (1 unit) per 10 kg of body weight. It is expected that one unit will increase the platelet count 5000 – 7000/mm^3.Coagulation defects, not caused by thrombocytopenia, may be caused by mechlorethamine, mithramycin and L-asparaginase. Patients who have had these drugs should be screened by a coagulation profile and abnormalities corrected appropriately. Other noxious side effects can be managed palliatively.

8. Bisphosphonate related osteonecrosis of the jaw (BRONJ)

In the modern day medicine bisphosphonates are used for management of many conditions such as osteoporosis, Paget's disease, breast cancer, prostate cancer and multiple myeloma. [40]Bisphosphonate related osteonecrosis of the jaw is a pathologic condition resulting in a non-healing, necrotic sequestrate of bone in patients on past or current bisphosphonate

therapy. The natural progression of the disease is probably similar with many patients (dental extraction in a patient with poor oral hygiene who has been on bisphosphonate therapy for a long period of time). The extraction socket does not heal, or heals but becomes covered with ulcerated overlying epithelium. Multiple exposed sites of painful bony spicules are present with occasional purulent exudate. The development of BRONJ appears to depend on the route and dose of administration of the drug as well as several other risks factors. New clinical treatments are however, being constantly discovered and it is likely that the uses of bisphosphonates will only increase in the future.

The mode of action of bisphosphonates revolves around the drug's intricate interaction with osteoclasts. [41] Once bisphosphonates are circulating in the bloodstream, they are taken up by osteoclasts, which subsequently undergo physical changes and lose their ruffled borders. [42] These structural changes in the osteoclasts alone appear to be sufficient to inhibit their bone resorptive activity. Bisphosphonates also, however, appear to directly cause apoptosis of osteoclasts and hence decrease overall number of available and viable cells. [43] Lastly bisphosphonates also inhibit the important osteoclast-osteoblast interaction, disrupting the important resorption and new deposition pattern. [44] Figure 3 summarizes relative risks of developing BRONJ.

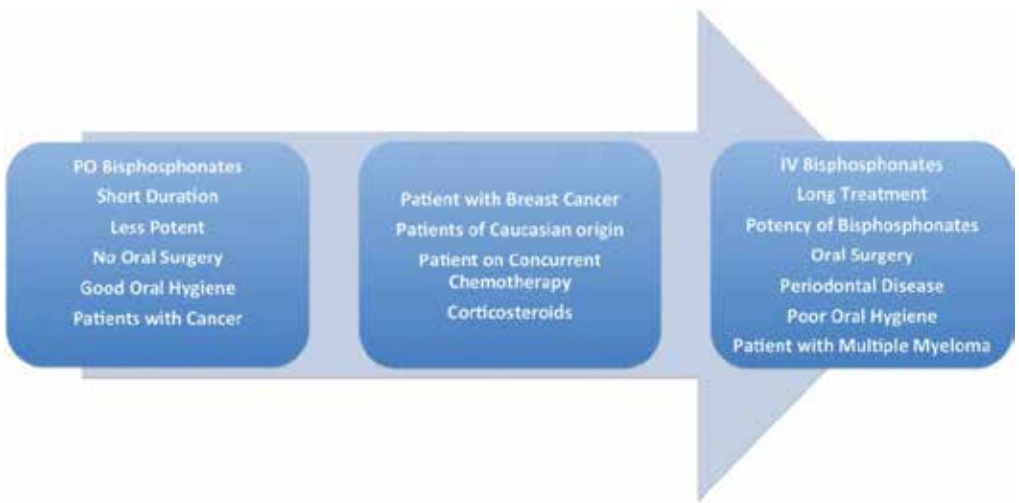

Figure 3. Risks factors for BRONJ. Modified from Bisphosphonate-related osteonecrosis of the jaws. In: Davies JEA, ed. Oral Complications of Cancer and Its Management[49]

Route of administration as well as duration appears to be the most important risks factors for developing BRONJ. [45] Most of the literature reports that there are usually triggering events (i.e. dental extractions, soft tissue trauma) before the disease makes itself visible, others suggest that disease is present long before clinical signs and symptoms become noticeable. [46, 47]Regardless of the etiology, once the disease entity is suspected appropriate staging and management options should be considered. Many clinical associations as well as American Association of Oral and Maxillofacial Surgeons have adopted

http://dx.doi.org/10.5772/53402

concise definitions to facilitate staging and management of the disease. [48] Table 4 summarizes these diagnostic considerations.

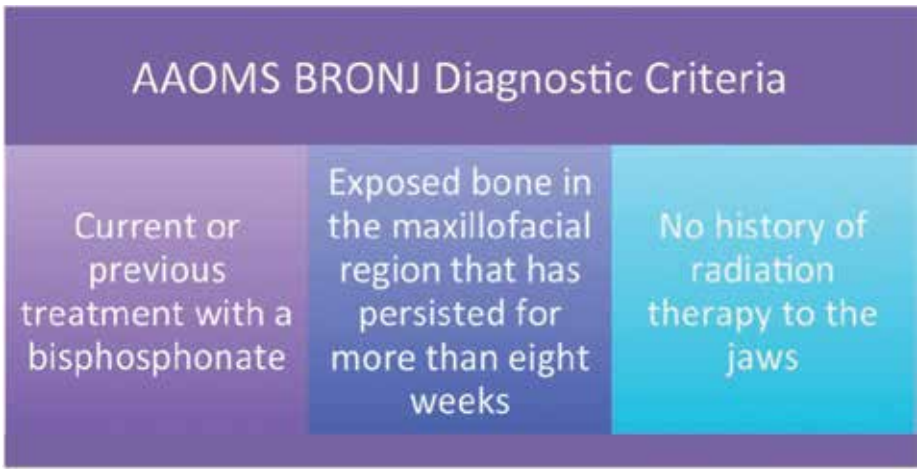

Table 4. BRONJ diagnostic criteria. Modified from BRONJ Diagnosis adopted from American Association of Oral and Maxillofacial Surgeons position paper on bisphosphonate-related osteonecrosis of the jaw. - 2009 update. Aust Endod J 2009;35[3]:119-130.

The treatment objectives for patients with an established diagnosis of BRONJ are to eliminate pain, control infection of the soft and hard tissue, and minimize the progression or occurrence of bone necrosis (see Table 5).[48]

BRONJ	
Stage	Management
At risk category: No apparent necrotic bone in patients who have been treated with either oral or IV bisphosphonates	No treatment indicated. Patient education
Stage 0: No clinical evidence of necrotic bone, but non-specific clinical findings and symptoms	Systemic management, including the use of pain medication and antibiotics
Stage 1: Exposed and necrotic bone in patients who are asymptomatic and have no evidence of infection	Antibacterial mouth rinse. Clinical follow-up on a quarterly basis. Patient education and review of indications for continued bisphosphonate therapy
Stage 2: Exposed and necrotic bone associated with infection as evidenced by pain and erythema in the region of the exposed bone with or without purulent drainage	Symptomatic treatment with oral antibiotics Oral antibacterial mouth rinse. Pain control. Superficial debridement to relieve soft tissue irritation
Stage 3: Exposed and necrotic bone in patients with pain, infection and one or more of the following: exposed and necrotic bone extending beyond the region of alveolar bone (i.e. inferior boeder and ramus in the mandible, maxillary sinus and zygoma in the maxilla) resulting in pathologic fracture, extra-oral fistula, oral antral/oral nasal communication, or osteolysis extending to the inferior border of the mandible of sinus floor	Antibacterial mouth rinse Antibiotic therapy and pain control Surgical debridement,/resection for longer term palliation of infection and pain

Table 5. BRONJ Management Recommendations. Modified from BRONJ Diagnosis adopted from American Association of Oral and Maxillofacial Surgeons position paper on bisphosphonate-related osteonecrosis of the jaw. - 2009 update. Aust Endod J 2009;35[3]:119-130.

9. Summary

Treatment of oral cancer presents a challenge to not only Oral and Maxillofacial surgeons but also to auxiliary staff, oncologists and certainly patients and their family. Treatment is usually complex, multidisciplinary and very expensive. The chapter above presents an overview of types of oral cancers in the mouth and their treatment. The position of an oral and maxillofacial surgeon remains pivotal; first to perform definitive diagnosis and provide appropriate referral. This is a rather rapidly changing field in medicine and new advanced treatment modalities continue to emerge. So it is extremely important to remain current with the most up-to-date treatment options to better serve the needs of our patients.

Author details

Orett E. Ogle* and Levon Nikoyan

*Address all correspondence to: Oeogle@aol.com

Department of Oral and Maxillofacial Surgery, Woodhull Medical and Mental Center, Brooklyn, NY, USA

References

[1] Shah, J. P, & Gil, Z. Current concepts in management of oral cancer--surgery. Oral Oncol. (2009). Epub 2008/08/05.

[2] Organization, W. H. Global data on incidence of oral cancer. In: Petersen PE, editor.: World Health Organization; (2005).

[3] Lee, N, Puri, D. R, Blanco, A. I, & Chao, K. S. Intensity-modulated radiation therapy in head and neck cancers: an update. Head Neck. (2007). Epub 2005/12/17., 29(4), 387-400.

[4] Corvo, R. Evidence-based radiation oncology in head and neck squamous cell carcinoma. Radiother Oncol. (2007). Epub 2007/05/08., 85(1), 156-70.

[5] Clinical Radiation Oncologyrd ed. Leonard L. Gunderson JET, editor. Philadelphia: Saunders; (2012).

[6] Ang, K. K. Advances in the Treatment of Head and Neck Cancer. In: James D. Cox KKA, editor. Radiation Oncology, Treatment, Technique Rationale. 9th ed. Philadelphia, PA: Mosby, Elsevier; (2010). , 161-353.

[7] Kate Newbold KHOverview of complications of radiotherapy. In: Andrew Davies JE, editor. Oral Complications of Cancer and its Management. Oxford: Oxford University Press; (2010). , 90-97.

[8] Levy, R. P, Fabrikant, J. I, Frankel, K. A, Phillips, M. H, & Lyman, J. T. Charged-particle radiosurgery of the brain. Neurosurg Clin N Am. (1990). Epub 1990/10/01., 1(4), 955-90.

[9] Karzmark, C. J M. R. A Primer on theory and operation of linear accelerators in radiation therapy. 2nd ed. Madison: Medical Physics Publishing; (1996).

[10] Chang, D. T, Sandow, P. R, Morris, C. G, Hollander, R, Scarborough, L, Amdur, R. J, et al. Do pre-irradiation dental extractions reduce the risk of osteoradionecrosis of the mandible? Head Neck. (2007). Epub 2007/01/19., 29(6), 528-36.

[11] Deasy, J. O, Moiseenko, V, Marks, L, Chao, K. S, Nam, J, & Eisbruch, A. Radiotherapy dose-volume effects on salivary gland function. Int J Radiat Oncol Biol Phys. (2010). Suppl):SEpub 2010/03/05., 58-63.

[12] Thomas Galloway MRobert J Amdur M. Management and prevention of complications of head and neck cancer during initial treatment. In: Marshall R Posner M, Bruce E Brockstein M, David M Brizel M, Daniel G Deschler M, FACS, editors.: UpToDate; 07/03/(2012).

[13] Koga, D. H, Salvajoli, J. V, & Alves, F. A. Dental extractions and radiotherapy in head and neck oncology: review of the literature. Oral Dis. (2008). Epub 2008/01/05., 14(1), 40-4.

[14] Murray, C. G, Daly, T. E, & Zimmerman, S. O. The relationship between dental disease and radiation necrosis of the mandible. Oral Surg Oral Med Oral Pathol. (1980). Epub 1980/02/01., 49(2), 99-104.

[15] Thorn, J. J, Hansen, H. S, Specht, L, & Bastholt, L. Osteoradionecrosis of the jaws: clinical characteristics and relation to the field of irradiation. J Oral Maxillofac Surg. (2000). discussion 93-5. Epub 2000/10/06., 58(10), 1088-93.

[16] Marx, R. E. A new concept in the treatment of osteoradionecrosis. J Oral Maxillofac Surg. (1983). Epub 1983/06/01., 41(6), 351-7.

[17] Sciubba, J. J, & Goldenberg, D. Oral complications of radiotherapy. Lancet Oncol. (2006). Epub 2006/02/04., 7(2), 175-83.

[18] Tong, A. C, Leung, A. C, Cheng, J. C, & Sham, J. Incidence of complicated healing and osteoradionecrosis following tooth extraction in patients receiving radiotherapy for treatment of nasopharyngeal carcinoma. Aust Dent J. (1999). Epub 1999/12/11., 44(3), 187-94.

[19] Assael, L. A. New foundations in understanding osteonecrosis of the jaws. J Oral Maxillofac Surg. (2004). Epub 2004/02/06., 62(2), 125-6.

[20] Al-nawas, B, Duschner, H, & Grotz, K. A. Early cellular alterations in bone after radiation therapy and its relation to osteoradionecrosis. J Oral Maxillofac Surg. (2004). Epub 2004/07/28.

[21] Costantino, P. D, Friedman, C. D, & Steinberg, M. J. Irradiated bone and its management. Otolaryngol Clin North Am. (1995). Epub 1995/10/01., 28(5), 1021-38.

[22] Beumer, J. rd, Curtis T, Harrison RE. Radiation therapy of the oral cavity: sequelae and management, part 1. Head Neck Surg. (1979). Epub 1979/03/01., 1(4), 301-12.

[23] Beumer, J. rd, Curtis T, Harrison RE. Radiation therapy of the oral cavity: sequelae and management, part 2. Head Neck Surg. (1979). Epub 1979/05/01., 1(5), 392-408.

[24] Epstein, J, Van Der Meij, E, Mckenzie, M, Wong, F, Lepawsky, M, & Stevenson-moore, P. Postradiation osteonecrosis of the mandible: a long-term follow-up study. Oral Surg Oral Med Oral Pathol Oral Radiol Endod. (1997). Epub 1997/06/01., 83(6), 657-62.

[25] Kampen, W. U, Brenner, W, Terheyden, H, Bohuslavizki, K. H, & Henze, E. Decisive diagnosis of infected mandibular osteoradionecrosis with a Tc-99m-labelled anti-granulocyte Fab'-fragment. Nuklearmedizin. (1999). Epub 1999/12/22., 38(7), 309-11.

[26] Mansberg, V. J, & Frater, C. J. Development of osteoradionecrosis demonstrated on bone scintigraphy. Clin Nucl Med. (2003). Epub 2003/06/24., 28(7), 587-8.

[27] Goldwaser, B. R, Chuang, S. K, Kaban, L. B, & August, M. Risk factor assessment for the development of osteoradionecrosis. J Oral Maxillofac Surg. (2007). Epub 2007/10/24., 65(11), 2311-6.

[28] Friedman, R. B. Osteoradionecrosis: causes and prevention. NCI Monogr. (1990). Epub 1990/01/01., 1990(9), 145-9.

[29] Epstein, J. B, Rea, G, Wong, F. L, Spinelli, J, & Stevenson-moore, P. Osteonecrosis: study of the relationship of dental extractions in patients receiving radiotherapy. Head Neck Surg. (1987). Epub 1987/09/01., 10(1), 48-54.

[30] Jansma, J, Vissink, A, Spijkervet, F. K, Roodenburg, J. L, Panders, A. K, Vermey, A, et al. Protocol for the prevention and treatment of oral sequelae resulting from head and neck radiation therapy. Cancer. (1992). Epub 1992/10/15., 70(8), 2171-80.

[31] Pitak-arnnop, P, Sader, R, Dhanuthai, K, Masaratana, P, Bertolus, C, Chaine, A, et al. Management of osteoradionecrosis of the jaws: an analysis of evidence. Eur J Surg Oncol. (2008). Epub 2008/05/06., 34(10), 1123-34.

[32] Bennett, M. H, Feldmeier, J, Hampson, N, Smee, R, & Milross, C. Hyperbaric oxygen therapy for late radiation tissue injury. Cochrane Database Syst Rev. (2012). CD005005. Epub 2012/05/18.

[33] What is HBO Therapy [database on the Internet)oxynet. (2003). cited 08/01/2012). Available from: http://www.oxynet.org/HBOInfo.htm.

[34] Tompach, P. C, Lew, D, & Stoll, J. L. Cell response to hyperbaric oxygen treatment. Int J Oral Maxillofac Surg. (1997). Epub 1997/04/01., 26(2), 82-6.

[35] Tuncay, O. C, Ho, D, & Barker, M. K. Oxygen tension regulates osteoblast function. Am J Orthod Dentofacial Orthop. (1994). Epub 1994/05/01., 105(5), 457-63.

[36] Schwartz, H. C, & Kagan, A. R. Osteoradionecrosis of the mandible: scientific basis for clinical staging. Am J Clin Oncol. (2002). Epub 2002/04/11., 25(2), 168-71.

[37] Jacobson, A. S, Buchbinder, D, Hu, K, & Urken, M. L. Paradigm shifts in the management of osteoradionecrosis of the mandible. Oral Oncol. (2010). Epub 2010/09/17., 46(11), 795-801.

[38] Oh, H. K, Chambers, M. S, Garden, A. S, Wong, P. F, & Martin, J. W. Risk of osteoradionecrosis after extraction of impacted third molars in irradiated head and neck cancer patients. J Oral Maxillofac Surg. (2004). Epub 2004/02/06., 62(2), 139-44.

[39] Ueda, M, Kaneda, T, & Takahashi, H. Effect of hyperbaric oxygen therapy on osseointegration of titanium implants in irradiated bone: a preliminary report. Int J Oral Maxillofac Implants. (1993). Epub 1993/01/01., 8(1), 41-4.

[40] Drake, M. T, Clarke, B. L, & Khosla, S. Bisphosphonates: mechanism of action and role in clinical practice. Mayo Clin Proc. (2008). Epub 2008/09/09., 83(9), 1032-45.

[41] Santini, D. Vespasiani Gentilucci U, Vincenzi B, Picardi A, Vasaturo F, La Cesa A, et al. The antineoplastic role of bisphosphonates: from basic research to clinical evidence. Ann Oncol. (2003). Epub 2003/09/25., 14(10), 1468-76.

[42] Murakami, H, Takahashi, N, Sasaki, T, Udagawa, N, Tanaka, S, Nakamura, I, et al. A possible mechanism of the specific action of bisphosphonates on osteoclasts: tiludronate preferentially affects polarized osteoclasts having ruffled borders. Bone. (1995). Epub 1995/08/01., 17(2), 137-44.

[43] Ito, M, Amizuka, N, Nakajima, T, & Ozawa, H. Ultrastructural and cytochemical studies on cell death of osteoclasts induced by bisphosphonate treatment. Bone. (1999). Epub 1999/10/08., 25(4), 447-52.

[44] Hughes, D. E. MacDonald BR, Russell RG, Gowen M. Inhibition of osteoclast-like cell formation by bisphosphonates in long-term cultures of human bone marrow. J Clin Invest. (1989). Epub 1989/06/01., 83(6), 1930-5.

[45] Bamias, A, Kastritis, E, Bamia, C, Moulopoulos, L. A, Melakopoulos, I, Bozas, G, et al. Osteonecrosis of the jaw in cancer after treatment with bisphosphonates: incidence and risk factors. J Clin Oncol. (2005). Epub 2005/11/30., 23(34), 8580-7.

[46] Ruggiero, S. L, Mehrotra, B, Rosenberg, T. J, & Engroff, S. L. Osteonecrosis of the jaws associated with the use of bisphosphonates: a review of 63 cases. J Oral Maxillofac Surg. (2004). Epub 2004/05/04., 62(5), 527-34.

[47] Migliorati, C. A, Schubert, M. M, Peterson, D. E, & Seneda, L. M. Bisphosphonate-associated osteonecrosis of mandibular and maxillary bone: an emerging oral com-

plication of supportive cancer therapy. Cancer. (2005). Epub 2005/06/02., 104(1), 83-93.

[48] Ruggiero, S. L, Dodson, T. B, Assael, L. A, Landesberg, R, Marx, R. E, & Mehrotra, B. American Association of Oral and Maxillofacial Surgeons position paper on bisphosphonate-related osteonecrosis of the jaw- 2009 update. Aust Endod J. (2009). Epub 2009/12/08., 35(3), 119-30.

[49] James Sciubba JEBisphosphonate-related osteonecrosis of the jaws. In: Davies JEA, editor. Oral Complications of Cancer and Its Management. Oxford: Oxford University Press; (2010). , 151-163.

Chapter 10

Bisphosphonate-Related Osteonecrosis of the Jaws – Diagnosis and Management

Petia F. Pechalova, Elena G. Poriazova,
Nikolai V. Pavlov and Angel G. Bakardjiev

Additional information is available at the end of the chapter

http://dx.doi.org/10.5772/53858

1. Introduction

The literature is replete with evidence of a new complication associated with the use of bisphosphonates defined as avascular osteonecrosis of the jaw. This chapter discusses this issue and its diagnosis and management.

2. Background

According to Danneman et al. [1], all cases of osteonecrosis of the jaw described until 2006 were associated with the use of the amino-group containing bisphosphonates only. Isolated reports of osteonecrosis of the jaw caused by prolonged oral administration of alendronate (Fosamax) for established osteoporosis can be found in the literature, including our previous publication. [2] Most published cases were caused by intravenous administration of a bisphosphonate. Sook-Bin Woo et al. reported that 94% of patients were treated with intravenous pamidronate or zoledronic acid, and 6% received oral bisphosphonates for oseoporosis or for Paget's disease. [3]

Marx in 2003 was the first to report 36 cases of "painful bone exposure of the lower and upper jaw in patients treated with bisphosphonates pamidronate and zoledronate". [4] That same year, Migliorati reported five cases [5], Carter and Gross reported four [6] and Wang reported three patients with this condition[7]. In 2004, Ruggierro et al. published 63 cases of osteonecrosis of jaw bones in patients treated with bisphosphonates. [8] In 2005, Novartis (the manufacturer of Aredia and Zometa) officially announced 475 cases of bisphosphonate–related osteonecrosis of the jaw (BRONJ). [1] To date, numerous authors have reported cases of osteonecrosis of the jaw bones associated with the use of bisphosphonates (Table 1). [9 – 15] The global number of cases of osteonecrosis of the jaw is unknown.

INTECH
open science | open minds

© 2013 Pechalova et al.; licensee InTech. This is a paper distributed under the terms of the Creative Commons Attribution License (http://creativecommons.org/licenses/by/3.0), which permits unrestricted use, distribution, and reproduction in any medium, provided the original work is properly cited.

Authors	Number of cases	Disease treated with bisphosphonates	Kind of bisphosphonate	Time period from start of bisphosphonate therapy to appearance of BRONJ	Site of BRONJ
Marx [16]	119	Multiple myeloma – 62 Lung cancer with bone metastasis – 50 Prostate cancer with bone metastasis – 4 Osteoporosis - 3	Pamidronate – 32 Zolendronate – 48 Pamidronate и Zolendronate – 36 Alendronate - 3	14,3 months for Pamidronate 9,4 months for Zolendronate 12,1 months for Pamidronate и Zolendronate 3 years for Alendronate	-
Ruggiero[8]	63 (18 males and 45 females)	Multiple myeloma – 29 Lung cancer with bone metastasis – 21 Prostate cancer with bone metastasis – 3 Kidney cancer with bone metastasis – 1 Leiomyosarcoma – 1 Leukemia - 1 Osteoporosis - 7	Pamidronate – 34 Zolendronate – 9 Pamidronate и Zolendronate – 13 Alendronate – 5 Risedronate – 1 Alendronate и Zolendronate - 1	-	Mandible – 39 Maxilla – 23 Mandible plus maxilla – 1
Dannemann[1]	14 (8 males and 6 females)	Multiple myeloma – 7 Lung cancer with bone metastasis – 6 Prostate cancer with bone metastasis – 1	Zolendronate – 8 Zolendronate и Aredia - 6	Avg. 38,7 months from the beginning of bisphosphonate medication (12 – 71 months)	Mandible – 9 Maxilla – 2 Mandible plus maxilla – 3
Mavrokokki [17]	158	Multiple myeloma – 31 Bone metastasis – 51 Puget's disease – 6 Osteoporosis - 26	Pamidronate – 20 Zolendronate – 43 Pamidronate и Zolendronate – 13 Alendronate – 30 Risedronate – 2 Clodronate – 2 Alendronate и Risedronate – 2 Alendronate и Pamidronate – 1 Zolendronate и Ibandronate - 1	26 doses of 62 mg Zolendronate 19 doses of 9060 mg Alendronate 14 doses of 3285 mg Pamidronate	Mandible – 57 Maxilla – 24 Mandible plus maxilla - 8

Table 1. Several case-series of BRONJ in the literature.

http://dx.doi.org/10.5772/53858

3. Definition of BRONJ

Bisphosphonate–related osteonecrosis of the jaw is necrosis of the jaw bone, related or unrelated to dental procedures, persisting for more than 6 to 8 weeks, refractory to conservative treatment, in patients having no history of prior radiotherapy in the affected area, treated intravenously with amino-containing bisphosphonates for at least one year, or orally for a much longer period, for a general disease causing bone resorption.

4. Bisphosphonates

Bisphosphonates are a class of drugs influencing bone metabolism discovered in the late 1960's. They are used to treat diseases that feature high bone resorption (multiple myeloma, osteolytic bone metastases, Paget's disease of bone [1], fibrous dysplasia [18, 19, 20], McCune-Albright syndrome [21], hypocalcaemia of malignancy) and are most commonly administered by intravenous infusion.

4.1. Mechanism of action

Bisphosphonates are synthetic analogues of inorganic pyrophosphates, which exert a potent inhibitory effect on osteoclast activity. They feature slow intestinal absorption; they are excreted by the kidneys without metabolic alteration and have high affinity to hydroxyapatite crystals. [22, 23] They incorporate into skeletal bones without being degraded. [24] Bisphosphonates attach to Ca^{2+} in areas of high bone resorption and remain integrated into the bone for more than 10 years [25] ; for example, half-life of Alendronate is 12 years [24]. They incorporate partially by pino- or phagocytosis into osteoclasts, osteoclast precursors, and also into macrophages, osteoblasts and chondroblasts. [26] Once taken, they trigger a cascade of biochemical processes leading to loss of the ability of osteoclasts to resorb bone, or even to their apoptosis. [27, 28]

4.2. Types of bisphosphonates

Bisphosphonates are classified based on their chemical structure (Table 2) [16, 29]

Aminobisphosphonates contain nitrogen in the side atomic chain of their molecule, with a much stronger effect. Newer aminobisphosphonates have two actions; they induce other adenosine triphosphate-analogues that cause apoptosis; and they inhibit farnesyl diphosphate synthetase, which is part of the pathological cycle of cholesterol synthesis. [30] Thus, osteoclast function is inhibited. Some authors suggest that aminobisphosphonates reduce recruitment of osteoclasts, and induce the production of osteoclast-inhibiting factors by osteoblasts. [31, 32] The chemical structure of an aminobisphosphonate is shown below [33]:

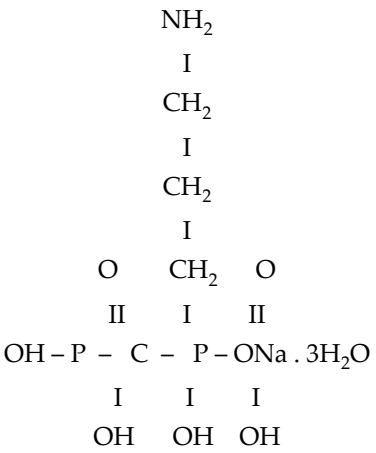

Generic name	Trade name	Administration	Type
Zoledronate	Zometa Aclasta	IV	aminobisphosphonate
Pamidronate	Aredia Pamiton	IV/ Oral	aminobisphosphonate
Alendronate	Fosamax Fosamax plus D_3 Lindron	Oral	aminobisphosphonate
Ibadronate	Boniva Bondronate	IV/ Oral	aminobisphosphonate
Risedronate	Actonel Actonel with Calcium	Oral	aminobisphosphonate
Tiludronate	Skelid	Oral	non-aminobisphosphonate
Etidronate	Didronel	Oral	non-aminobisphosphonate
Clodronate	Bonefos Ostac Sindronat Clodron	IV/ Oral	non-aminobisphosphonate

Table 2. Types of bisphosphonates.

Non-aminobisphosphonates - metabolized by osteoclasts to inactivate non-hydroxylysine adenosine triphosphate-analogues that have a direct cytotoxic effect and lead to apoptosis. [3] The chemical structure is shown below [33]:

http://dx.doi.org/10.5772/53858

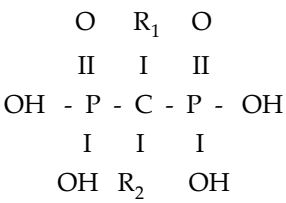

Until recently, bisphosphonates were administered predominantly as an intravenous infusion. Now, bisphosphonates in the form of tablets for oral administration are recommended for patients with osteoporosis. The management strategy for osteoporosis is to prevent osteoclast-mediated resorption of trabecular bone, and thus, maintain its density.

4.3. Bisphosphonate use

More than 2.5 million patients worldwide have been treated with bisphosphonates. [34] Almost 2 million people receive treatment with bisphosphonates as part of their anticancer therapy. [1] The number of patients treated with oral bisphosphonates for osteoporosis has also been growing. In 2003 Alendronate was the 19th most commonly prescribed drug in the world (17 million prescriptions), Risedronate was the 72nd with 6 million prescriptions, and Zolendronate was taken by over 300,000 patients. [35, 36]

4.5. Adverse effects

Bisphosphonate therapy can lead to some adverse effects i.e. kidney failure [37], arthralgia, fever, muscle pain and [38] hypocalcaemia [39]. In vitro and in vivo tests reported antiangiogenic (hence antitumour) effect of Zoledronic acid by inhibiting endothelial cell proliferation and induction of apoptosis. [23, 40]

4.6. Possible mechanism leading to BRONJ

BRONJ probably results from suppression of bone metabolism established after bisphosphonate treatment and from accumulation of physiologic microtraumas to the jaw bones, compromising biomechanical properties. Trauma and infection increase the need for bone recovery, which exceeds the capacity of hypodynamic bone, thus resulting in localized bone necrosis. Antiangiogenic properties of bisphosphonates and other medications taken by patients, and the presence of other comorbid factors may promote the risk of development, persistence or progression of this condition. [3]

5. BRONJ

Sook-Bin Woo et al. assume that bisphosphonate-associated osteonecrosis develops only in the jaw bones because they, unlike other bones in the body, are not sufficiently protected. On one hand, an important fact is that they are protected from possible intraoral trauma only by thin mucosa and periosteum. On the other hand, the presence of teeth in the jaw bone

is a prerequisite which facilitates penetration of microorganisms and development of intraosseous infections via deep caries complications and the periodontium. [3] In fact, one case of bisphosphonate-associated osteonecrosis of the auditory canal in a patient treated with Zoledronic acid in relation to multiple myeloma, published by Polizzotto et al. can be found in literature; the lesion appeared after removal of exostoses in the external auditory canal, but even in this case the patient had a concurrent osteonecrosis of the maxilla. [41]

5.1. Incidence of BRONJ

Reports on the incidence of the disease are variable. Most authors present statistical studies of patients with multiple myeloma and lung cancer; the largest groups treated with bisphosphonates was a study of 1203 cases, of which 904 patients with multiple myeloma and 299 with lung cancer. Development of osteonecrosis of the jaw bones was found in 7% and 4%, respectively. [3] Bamias et al. studied 252 patients receiving intravenous bisphosphonate therapy; 10% of patients with multiple myeloma and 3% of patients with lung cancer developed osteonecrosis of the jaw bones. [39] Estilo et al. studied 124 patients with multiple myeloma and lung cancer treated with intravenous bisphosphonates and found that osteonecrosis of the jaw bones developed in 4 patients with myeloma and in 9 patients with lung cancer. [42] Bilezian stated that the incidence of BRONJ is 1.3%. [33]

5.2. Clinical presentation

Clinically intraoral lesions in BRONJ look like zones of yellow-white hard bone, with soft or indurated borders (Figs. 1-3).

Figure 1. BRONJ of the mandible.

http://dx.doi.org/10.5772/53858

Figure 2. BRONJ of the maxilla.

Figure 3. Multiple lesions of the mandible

Extra-or intraoral fistulas may be found. Painful lesions may develop in the soft tissues; they may conflux with the exposed bone and may involve large regions of the mouth. Some cases of pathological fracture of the mandible as the first manifestation of the disease have been described. [40] Danneman et al. suggest that unlike osteoradionecrosis, osteonecrosis of the jaw has no preference for the mandible and it affects both mandible and maxilla. [1] Sook-Bin Woo et al. in an overview of 368 cases, reported involvement of the mandible in 65% of the cases, the maxilla in 26% and in both jaws in 9%. The ratio of women to men was 3:2. The same author reported that most of the lesions were in the posterior regions of the mandible, near the mylohyoid ridge. According to him, multifocal/ bilateral lesions were slightly more frequent in the maxilla (31% compared to the mandible which was 23%). [3]

5.3. Paraclinical tests

In the early stages of the disease there may be no radiological changes. [3] Some authors recommend performing computed tomography. [33] Chiandussi et al. suggest that later

changes in jaw bones in bisphosphonate-associated osteonecrosis can be visualized by radiography, and for early detection of lesions it is necessary to perform computed tomography examination or MRI. [43] Dunstan et al. recommend jaw bone scintigraphy with Tc-99m methylene diphosphonate. [44] In advanced cases, the bone shows a moth-eaten appearance [41] clearly identifiable radiologically with or without X-ray positive sequestra. Danneman et al. argue that the sequestra typical of chronic osteomyelitis are not found in BRONJ. [45]

Microbiological testing most commonly finds actinomycete druses. [1, 46]

Histopathological analysis shows presence of necrotic bone surrounded by bacteria that do not enter into it. [40] Three main histological patterns have been identified in BRONJ patients [47] (Fig. 4):

1. Areas with active acute inflammation, characterized by predominance of soft tissues, inflammatory infiltrate, acellular necrotic debris, thin-walled and dilated blood vessels, and intensely basophilic bone spiculae with scalloped borders showing prominent bone resorption.

2. Areas characterized by predominance of bony structures showing wide acellular necrotic sequestra and large, scalloped Haversian canals containing inflammatory cells.

3. Non-necrotic areas containing larger amounts of bone, showing increased trabecular thickness, inter-osteonic bone deposition and smaller and fewer Haversian canals. Also, lamellar bone from treated patients was composed of bigger osteones containing larger osteocytes. Two different types of newly-formed woven bone, mainly showing centrifugal spatial orientation, were easily detectable in these areas. Osteoclast-like cells detected in inflammatory areas from treated patients were small and contained few nuclei, but they were rare to absent in non-necrotic bone from the same patients.

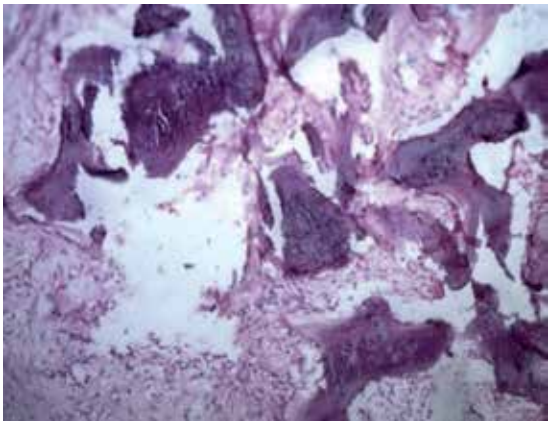

Figure 4. Microscopic view of necrotic bone in BRONJ.

http://dx.doi.org/10.5772/53858

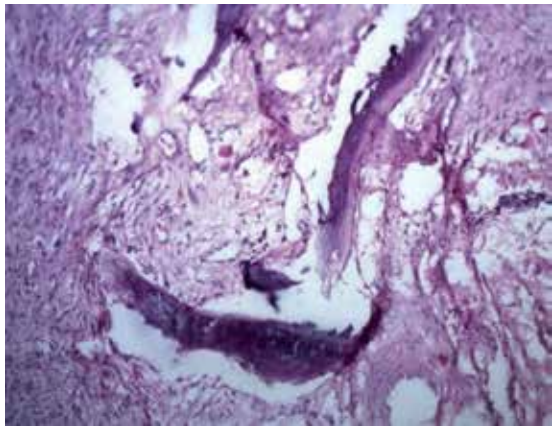

Figure 5. Another microscopic view of necrotic bone in BRONJ

6. Differential diagnosis

Differential diagnosis of ONJ includes [48]:

- Malignancies - differentiation is through histopathological analysis;
- Osteoradionecrosis if jaws were exposed to prior radiation;
- Osteomyelitis in which, unlike bisphosphonate-associated osteonecrosis, necrotic bone is surrounded by vital bone, which reacts with a violent inflammatory reaction, thus limiting necrosis;
- Osteopetrosis - an extremely rare congenital condition;
- Bone necrosis in HIV-positive patients.

7. Risk factors for development of BRONJ

Mainly two groups of factors responsible for the development of jaw necrosis may be found in literature – the first one investigates the bisphosphonate administered (type, regimen and period of treatment), and the other one investigates the dental diseases and procedures that are likely to mediate the onset of the condition.

7.1. Risk factors associated with bisphosphonates

- Kind of bisphosphonate that induces BRONJ more often

According Danneman et al., all cases of osteonecrosis of the jaw described until 2006 were associated with the use of the amino-group containing bisphosphonates only. In literature

there is no consensus on the question which amino-bisphosphonates cause more frequent development of BRONJ (Table 3), but scientific evidence supports the predominant view that the use of Zoledronic acid is the most risky. [39, 45, 49, 50]

	Dannemann et al. [45]	Badros et al. [51]	Clarke et al. [52]	Durie et al. [50]
Total number of patients undergoing bisphosphonate treatment		*90*	*497*	*1203*
Number of cases with BRONJ	*23*	*22*	*25*	*75*
Number of patients that received Zolendronate	*14*	*2*	*5*	*21*
Number of patients that received Pamidronate and Zolendronate	*5*	*17*	*8*	-
Number of patients that received Pamidronate	*1*	*3*	*10*	*17*
Number of patients that received Alendronate	*3*	-	*2*	-

Table 3. Development of BRONJ in patients receiving different types of bisphosphonates.

- Regimen

A safer regimen for bisphosphonate treatment in terms of developing BRONJ

Corso et al. published a study of multiple myeloma patients, divided into two groups; the first group received bisphosphonate treatment under the standard regimen, i.e. monthly; while the patients in the second group received bisphosphonates monthly in the first year, and then at every third month. They found, with statistical reliability, fewer cases of BRONJ in patients from the second group, while in the first group they found cases of jaw necrosis after the first year of the initiation of treatment. The authors reported that the Skeletal-Related Events (SRE) index, which takes into account the condition of the bone system as a whole, was comparable in both groups. [49]

- Duration of treatment

Relationship between the period of use of bisphosphonates and the risk of developing bronj

Bamias A et al. suggest there is a strong correlation between the duration of treatment with bisphosphonates and manifestation of jaw necrosis; they found that the average period of exposure to drugs in patients with BRONJ was 39.3 months (from 11 to 86 months) and in patients without BRONJ was 19 months (from 4 to 84.7 months); and they defined the risk of developing the condition to be from 1% at 12 months after the start of treatment to 11% in the fourth year. The authors reported that these figures vary depending on the type of bisphosphonate administered (in patients treated with Zoledronic acid only it was from 1% in

http://dx.doi.org/10.5772/53858

the first year to 21% in the third year since initiating the treatment, while in patients treated with Pamidronate with or without Zoledronic acid it was 0% in the first two years of treatment and up to only 7% after four years of treatment). [39] Corso A. et al. determined the following periods for the development of BRONJ depending on the bisphosphonate administered; in case of treatment with Pamidronate, necrosis was observed no earlier than 23 months after initiation of therapy; in case of administration of Zoledronic acid this period is no shorter than 28 months; in concomitant use of Pamidronate and Zoledronic acid necrosis can be observed no sooner than 43 months. [49] Badros et al. suggest that with each year after diagnosing multiple myeloma and its treatment, the risk of developing BRONJ is increases by 57%. [4]

7.2. Risk factors related to the dento-alveolar system

- Anatomical comorbidity

This group of predisposing factors considers the presence of mandibular tori, palatal tori, and bone exostoses as sites more easily subject to local traumatization during daily activities. Marx et al. reported BRONJ in 9.2% on mandibular tori. [16]

- Diseases of dental hard tissues and supporting apparatus

Marx et al. found that the most frequent dental disorder concomitant with BRONJ is symptomatic or radiologically diagnosed periodontitis in 84% of patients. Caries in necrotic areas was registered in 28.6%. [16]

- Dental procedures:

Literature is replete with the incidence of bisphosphonate-associated osteonecrosis of the jaw associated with previous dental procedures compared to cases of the so-called spontaneous BRONJ. [4, 18, 27, 28, 35, 39, 53] Woo Sook-Bin et al. [3] found that 33% - 86% of cases of BRONJ reported in the literature occurred after different dental procedures (Table 4).

	Marx [16]	Dannemann [1]	Bamias [39]
Total number of cases with BRONJ	119	23	17
Number of cases with BRONJ after tooth extraction	45	18	13
Number of cases with BRONJ after endodontic treatment	34	2	
Number of cases with BRONJ after new or uncomfortable denture		2	
Number of cases with BRONJ after periodontal surgery	5	1	
Number of cases with BRONJ after apecoectomia	1		
Number of cases with BRONJ after dental implants	4		

Table 4. Dental procedures as a risk factor to development of BRONJ

7.3. Other risk factors

The literature discusses the role of therapy concomitant with bisphosphonate treatment. Immunosuppressive effects of chemotherapy, impaired bone remodelling during treatment with glucocorticoids, antiangiogenesis properties of Thalidomide slow down the reparative processes in the oral cavity, and are a predisposing factors for the manifestation of BRONJ. [54]

Each decade of age passed increases the risk of developing BRONJ by 9%. [4]

8. Where to refer the patient if BRONJ is suspected

If development of BRONJ is suspected, the patient should be referred to an oral or a maxillofacial surgeon. Nastro et al. [55] emphasize the important role of these specialists and emphasize that their intervention should not be underestimated. However, in all cases, treatment should be conducted jointly with the specialist who prescribed the bisphosphonates (the oncologist, haematologist, endocrinologist, etc.).

9. Termination of bisphosphonate therapy after diagnosis of BRONJ

There is no consensus on the need for discontinuation of bisphosphonate treatment after diagnosing osteonecrosis of the jaw. Marx suggests that behaviour in terms of bisphosphonate therapy in cancer patients shall be discussed with the oncologist on the purpose of determining the benefit to risk ratio, in view of the long half-life (10 years) of bisphosphonates. [16] Other authors share the same opinion. [48, 55] Dunstan et al. suggest that bisphosphonate therapy be discontinued. [44]

10. Algorithm of actions following development of BRONJ

By summarizing the evidence found in literature, the following algorithm for treatment of patients suspected to have BRONJ can be derived:

1. A careful clinical examination to find the location and volume of exposed necrotic bone
2. Imaging diagnostics of the affected jaw - X-rays, CT scans, MRI, bone scintigraphy
3. Providing material for histopathological analysis to exclude the presence of a systematic process in the jaw (in case of multiple myeloma, a metastasis in case of oncological diseases or a primary neoplasm)
4. Providing material for microbiological examination with emphasis on fungal or other pathological bacterial infections

http://dx.doi.org/10.5772/53858

5. Treatment - It is assumed that BRONJ is an irreversible condition. [55, 56] Medical treatments are aimed at elimination or control of pain and at prevention of progression of jawbone exposure. Necrotic bone itself is not painful - pain, cellulitis and cutaneous fistulas occur in case of secondary infection. Thus, a long-term and sometimes permanent antibiotic treatment is recommended.

   - Drug therapy - systematic medication treatment includes the triad:
   - antibiotic
   - antifungal agent
   - antiviral agent

The first choice antibiotic is oral penicillin (Table 5).

Clinical condition	Administer	Antibiotic drugs and doses	In cases of penicillin allergy
Slight	Orally	Penicillin (500 mg every 6 hours)	Ciprofloxacin (500 mg every 12 hours) or Erythromycin ethylsuccinate (400 mg every 8 hours)
Moderate	Orally	Penicillin (500 mg every 6 hours) and Metronidazole (500 mg every 8 hours)	Ciprofloxacin (500 mg every 12 hours) or Erythromycin ethylsuccinate (400 mg every 8 hours) and Metronidazole (500 mg every 8 hours)
Severe cellulitis	IV	Unasyn (1500 mg every 6 hours) and Metronidazole (500 mg every 8 hours)	

Table 5. Antibiotic treatment for control of diagnostic BRONJ by Marx et al. [16]

It is advisable that the therapy also include 0.12% chlorhexidine mouth rinse solution. [16] Penicillin may be replaced with Dalacin C (600 mg at every 8 hours) or Doxycyclin (100 mg every 12 hours for the first 24 hours, and 100 mg for every 24 hours after that). The American Dental Association recommends the following oral antibiotics: Amoxicillin with or without Metronidazole, and in case of penicillin allergy Clindamycin or Azithromycin (Table 6).

Drugs	Doses	Duration of treatment
AMOXICILLIN	500 mg every 8 hours	14 days
METRONIDAZOLE	250 mg every 8 hours	14 days
CLINDAMYCIN	300 mg every 8 hours	14 days
AZITROMYCIN	250 mg daily	10 days

Table 6. Antibiotics for oral use in BRONJ recommended by the American Dental Association [53]

Dunstan et al. [44] identified Penicillin, Clindamycin, Erythromycin, Nystatin, Fluconazole, Acyclovir, Valocyclovir (for systemic use) and 0.12% chlorhexidine gluconate, minocycline hydrochloride (mouth rinse) as typical drugs for treatment of osteonecrosis of the jaw. Marx et al. suggest that the administration of Clindamycin only is not recommended because of its ineffectiveness in terms of most frequently detected microorganisms in the exposed bones, namely actinomycetes, *Eikenella corrodens* and other similar types. [16] Nastro et al. emphasize that antibiotics cannot penetrate into necrotic tissue, so they are used only for treatment of cellulitis of the tissue adjacent to bone necrosis. [55]

- Surgery (debridement of the wound and covering it with an adjacent flap) - a method of choice which most authors do not recommend [5, 8], because of the danger of involving new bone sections in the process. Marx et al. [16] reports that pathological fractures in bisphosphonate-associated osteonecrosis of the jaw are extremely rare, except in cases where debridement had been performed, thus weakening the bone. That is why he recommends only smoothening of sharp bone edges that contribute to inflammation and pain in the affected area. Dunstan et al. [44] recommends avoiding surgery when the process starts, but argues that in some cases partial mandibulectomy or maxillectomy is required, emphasizing the idea of sparing debridement. Nastro et al. [55] also are not supporters of surgery – they published a series of 12 cases, only one of which was treated surgically, and subsequently a recurrence developed in the same location of the jaw. Graziani et al. recommended performing sequestrectomy and resection in certain cases but the treatment protocol to which they adhered to included primarily antibiotic treatment, combined with periodic debridement to remove necrotic areas aimed at reduction of symptoms. [57] In the literature, there is an underlying view that aggressive surgical treatment is counterproductive and leads to deterioration and therefore should be avoided. [5, 8, 16, 44]

- Hyperbaric oxygenation (the evidence for its efficacy is controversial) application result rather from the analogy with the treatment of osteoradionecrosis, in which stabilization of the oxygen gradient is used. The mechanism of development of osteoradionecrosis and BRONJ, however, is fundamentally different. [16] The prevailing opinion in the literature is that hyperbaric oxygenation has no definite effect on the response of osteonecrosis of the jaw, and its use is not recommended. [8, 44, 55, 56]

http://dx.doi.org/10.5772/53858

- Ozone therapy, an experimental method of treatment, studied by Agrillo et al. [38], published a series of cases treated by the following regimen:
  - Minimally invasive surgical curettage under local anaesthesia - the authors reported the removal of necrotic bone in search of vascularized tissue, and limited deperiostealization to mobilize the mucosal flap covering the bone wound;
  - Medical treatment, including the antibiotic triad (amoxicillin with clavulanic acid, 1000 mg at every 12 hours) antifungal agents (250 mg at every 8 hours) and antiviral agents (800 mg daily) for 20 days, and also vitamin C (3000 mg per day) for 20 to 30 days, local antiphlogistic agents and 0.2% chlorhexidine mouth rinse.
  - Ozone therapy with Ozonytron - pre-, intra-and postoperatively (2 applications, each lasting for 5 minutes, per week, for 20 days) and repeating the course at the onset of pain or a diagnosed infection.

Ozone has a positive effect on the bone defect by oxidation and stimulation and/or preservation of endogenous antioxidant systems, and by blocking the xanthine/xanthine oxidase pathological cycle. Ozone has a beneficial effect on blood circulation, it increases the number of red blood cells and hemoglobin levels, accelerates diapedesis and phagocytosis and stimulates the reticulohistiocytic system. The described effects are most pronounced in small diameter vessels, such as the jaw vessels and capillaries. [9] Clavo et al. reported that ozone is harmless to living tissue, and at certain concentrations it has analgesic effects. [58] Agrillo et al. made the conclusion that ozone can be used in the treatment of patients with avascular necrosis of the jaw due to its stimulating effects on the metabolism of oxygen, calcium, phosphorus and iron. [38]

11. Prevention of BRONJ

At this stage there is no evidence-based therapeutic strategy for BRONJ and the condition is considered to be irreversible, and therefore the attention of medical community focuses on the possibilities of its prevention. [3, 53, 59, 60, 61, 62]

11.1. Before the start of bisphosphonate therapy

After establishing diagnosis requiring treatment with bisphosphonates, but before initiating the therapy, the patient should be referred to a dentist and an oral or a maxillofacial surgeon. The following plan for behaviour is recommended:

1. A thorough clinical examination of the dentition and oral cavity, panoramic radiograph and, by the discretion of the doctor, targeted periapical radiographs as a mandatory required minimum.
2. Conducting dental treatment aimed at elimination of infection and the need for invasive procedures in the short- and mid-term future (Table 7).

Procedure	Interventions	Antibiotic prophylaxis	Standard drugs	Drugs in cases of penicillin allergy
Invasive dental procedures	• Tooth extractions • Periodontal surgery • Endodontic treatment • Excision of tori and exostosis • Extraction of impacted teeth	Recommended	Penicillin	Ciprofloxacin and Metronidazole or Erythromycin and Metronidazole
Non-invasive dental procedures	• Prophylaxis • Flouridization • Filling caries	Not recommended		

Table 7. Antibiotic prophylactic in cases of dental procedures preceding bisphosphonate treatment

It is appropriate that the specialized surgery in the oral cavity be in compliance with the following recommendations:

- In terms of mandibular and palatal tori and exostoses, their removal is recommended only in case of large and lobed structures covered with thin overlying mucosa.
- In terms of impacted teeth, surgical removal is recommended only for those which are not fully covered by bone, communicating with the oral cavity, because of the danger of onset of an inflammatory process in the future.
- Patients subject to bisphosphonate treatment are not eligible for restoration with dental implants.

All invasive dental procedures should be performed at least one month before initiating bisphosphonate therapy in order to allow sufficient time for recovery of the jawbone.

11.2. After the start of bisphosphonate therapy

After the start of bisphosphonate therapy patients are subject to preventive check-ups at every four months, with radiographic examination, which should seek vigilantly for the presence of osteolysis, osteosclerosis, and expansion of periodontium and involvement of furcations. If additional treatment is required, non-invasive dental procedures are preferred. Elective surgery does not lead to encouraging results. Placing dental crowns is permissible. Removable dentures should be carefully planned in areas of expected excessive pressure, giving preference to soft plastic structures. [16]

12. Conclusion

Bisphosphonate-associated osteonecrosis of the jaw bones is a newly discovered entity that should be taken into account by dentists, hematologists, oncologists, endocrinologists and

http://dx.doi.org/10.5772/53858

other medical professionals in their daily practice. At this stage, it is assumed that the condition is irreversible. Therefore, efforts are focused on prevention and early diagnosis through various paraclinical methods, if possible before clinical manifestation.This condition is subject to further study. [63]

Author details

Petia F. Pechalova[1*], Elena G. Poriazova[2], Nikolai V. Pavlov[3] and Angel G. Bakardjiev[4]

*Address all correspondence to: pechalova@yahoo.com

1 Department of Maxillo-Facial Surgery, Faculty of Dental Medicine, Medical University, Plovdiv, Bulgaria

2 Department of Pathology, Medical University, Plovdiv, Bulgaria

3 Private Practice of Oral Surgery, Plovdiv, Bulgaria

4 Department of Oral Surgery, Faculty of Dental Medicine, Medical University, Plovdiv, Bulgaria

References

[1] Dannemann C. Gratz KW, Zwablen R. Clinical experiences with bisphosphonates – induced osteochemonecrosis of the jaws. Swiss Medical Weekly 2006; 136: 504 – 509.

[2] Pechalova P, Bakardjiev A, Vladimirov B, Poriazova E, Zaprianov Z, Angelova I, Zheleva A. Osteonecrosis of lower jaw, associated with the application of oral bisphosphonates – case report. Journal of Clinical Medicine 2009; 2(2): 61 – 66.

[3] Woo Sook-Bin, Hellstein JW, Kalmar JR. Systematic Review: Bisphosphonates and Osteonecrosis of the Jaws. Ann Intern Med. 2006; 144: 753 – 761.

[4] Marx RE. Pamidronate (Aredia) and Zoledronate (Zometa) induced avascular necrosis of the jaws: A growing epidemic. J Oral Maxillofac Surg. 2003; 61: 1115.

[5] Migliorati CA. Bisphosphonates and oral cavity avascular bone necrosis: J Clin Oncol. 2003; 21: 4253.

[6] Carter GD, Gross AN. Bisphosphonates and avascular necrosis of the jaw. Aust Dent J. 2003; 48: 268.

[7] Wang J, Pogrel MA. Osreonecrosis of the jaws associated with cancer chemotherapy. J Oral Maxillofac Surg. 2003; 61: 1104 – 1107.

[8] Ruggiero SL, Mehrotra B, Rossenberg TJ, et al. Osreonecrosis of the jaws associated with the use of Bisphosphonates: a review of 63 cases. J Oral Maxillofac Surg. 2004; 62: 527 – 534.

[9] Bagan JV, Murillo J, Jimenez Y, et al. Avascular jaw osteonecrosis in association with cancer chemotherapy: series of 10 cases. J Oral Pathol Med 2005; 34: 120 – 3.

[10] Hoefert S. Kieferknochennekrosen als mogliche unerwunschte Wirkung von Bisphosphonaten. Mund Kiefler Gesichtschirurg 2005; 9: 233 – 238.

[11] Lugassey G, Rea S. Severe osteomyelitis of the jaw in long term survivors of multiple myelome: anew clinical entity. Am J Med 2004; 117: 440 – 1.

[12] Melo M. Osteonecrosis of the maxilla in a patient with a history of bisphosphonate therapy. J Canadian Dental Association 2005; 71: 11 – 3.

[13] Migliorati C, Douglas E, Seneda L. Bisphosphonate-associated osteonecrosis of mandibular and maxillary bone. An emerging oral complication of supportive cancer therapy. Am Cancer Soc 2005; 104: 83 – 93.

[14] Schirmer I, Reochart PA, Durcop H. Bisphosphonate und Osteonecrosen im Kieferberiech. Mund Kiefler Gesichtschirurg 2005; 9: 239 – 45.

[15] Schwartz HC. Osteonecrosis and bisphosphonates: correlation versus causation (comment). J Oral Maxillofac Surg. 2004; 62: 763 – 4.

[16] Marx RE, Sawatari Y, Fortin, et al. Bisphosphonate-Induced Exposed Bone (Osteonecrosis/ Osteopetrosis) of the Jaws: Risk Factors, Recognition, Prevention and Treatment. J Oral Maxillofac Surg. 2005; 63: 1567 – 1575.

[17] Mavrokokki T, Cheng A, Stein B. Nature and Frequency of Bisphosphonate-Associated Osteonecrosis of the Jaws in Australia. J Oral Maxillofac Surg. 2007; 65: 415 – 423.

[18] Chapurlat RD, Delmas PD, Liens D, et al. Long-term effects of intravenous pamidronate in fibrous dysplasia of bone. J Bone Miner Res 1997; 10: 1746 - 1752

[19] Chapurlat RD, Hugueny P, Delmas PD, et al. Treatment of fibrous dysplasiaof bone with intravenous pamidronate: long-term effectiveness and evaluation of predictors of response to treatment. Bone 2004; 35: 235 – 242.

[20] Liens D, Delmas PD, Meunier PJ, et al. Long-term effects of intravenous pamidronate in fibrous dysplasia of bone. Lancet 1994; 343: 953 – 954.

[21] Lara R, Matarazzo P, Bertelloni Sq et al. Pamidronate treatment of bone fibrous dysplasia in nine children with McCune-Albright syndrome. Acta Paediatr 2000; 89: 188 - 193.

[22] Fleisch H. Bisphosphonates: mechanisms of action. Endocr. Rev. 1998; 19: 80 – 100

[23] Fournier P, Boissier S, Filleur S, et al. Bisphosphonate inhibit angiogenesis in vitro and testosterone-stimulated vascular regrowth in the ventral prostate in castrated rabs. Cancer Res. 2002; 15: 6538 – 6544.

[24] Lin JH, Russel G, Gertz B. Pharmacokinetics of alendronate: an overview. Int J Clin Pract Suppl. 1999; 101: 18 – 26.

[25] Rogers MJ, Russel RG. Overview of bisphosphonates. Cancer 1997; 80: 1652 – 60

[26] Hughes DE, Uy HL, Sasaki A, et al. Bisphosphonates promote apoptosis in murin osteoclasts in vitro and in vivo. J Bone Miner Res. 1995; 10.

[27] Bartl R. Bisphosphonate. Manual Supportive Massnahmen und symptomorien tierte Therapie. Munchen, 2001; 184 – 90.

[28] Carano A, Konsek JD, Schlesinger PH, et al. Bisphosphonates directly inhibit the bone resorption activity of isolated avian osteoclasts in vitro. J Clin Invest 1990; 85: 456 – 61.

[29] American Assosiation of Oral and Maxillofacial Surgeons. American Assosiation of Oral and Maxillofacial Surgeons Position Paper on Bisphosphonate-Related Osteonecrosis of The Jaws; J Oral Maxillofac Surg. 2007; 65: 369 – 76.

[30] Green JR. Bisphosphonates: preclinical review. Oncologist. 2004; 9 Suppl 4: 3 – 13.

[31] Hughes DE, Mcdonald BR, Russel RG, et al. Inhibition of osteoclast-like cell formation by bisphosphonates in long-term cultures of human bone marrow. J Clin Invest. 1989; 83: 1930 – 5.

[32] Vitee` C, Fleisch H, Guenther HL. Bisphosphonates induce osteoblasts-mediated resorption. Endocrinology. 1996; 137: 2324 – 33.

[33] Bilezikian JP. Osteonecrosis of the jaw – Do Bisphosphonates Pose a Risk? N Engl J Med 2006; 2278 – 81.

[34] Tarasoff P, Csermak K. Avascular necrosis of the jaws: risk factor in metastatic cancer patients J Oral Maxillofac Surg. 2003; 61: 1238-1239.

[35] Berenson J, Hirschberg R. Safety and convenience of a 15-minute infusion of zolendronic acid. Oncologist 2004; 9: 319 – 329.

[36] Marketos M. The top 200 brand drugs in 2003 (by units). Drug Topics 2004; 148: 76 – 86.

[37] Mehrotra B, Ruggiero S. Bisphosphonate complications including Osteonecrosis of the Jaw. American Society of Hematology, 356 – 360.

[38] Agrillo A, Petrucci MT, Mustazza MC, et al. New Therapeutic Protocol in the Treatment of Avascular Necrosis of the Jaws. Mutaz B. Habal 2006; 1080 – 1083.

[39] Bamias A, Kastritis E, Bamia C, et al. Osteonecrosis of the jaw in cancer after treatment with bisphosphonates: Incidence and risk factors. J Clin Oncol 2005; 23: 8580 – 8587.

[40] Rossi D, D'orto O, Pagani D, et al. Bisphosphonate-associated osteonecrosis of the jaws: a therapeutic dilemma. OOOOE; 103: 1 – 5.

[41] Polizzotto MN, Cousins V, Schwarer AP. Bisphosphonate-associated osteonecrosis of the auditory canal [Letter]. Br J Haematol 2006; 132: 114.

[42] Estilo CS, Van Poznak CH, Williams T, et al. Osteonecrosis of the maxilla and mandible in patients treated with bisphosphonates: a retrospective study. Proc Am Soc Clin Oncol. 2004; 22: 750.

[43] Chiandussi S, Biasotto M, Dore F, et al. Clinical and diagnostic imaging of bisphosphonate-associated osteonecrosis of the jaws. Dento-maxillofacial Radiol 2006; 35: 236 – 43.

[44] Dunstan CR, Felsenberg D, Seibel M. Therapy Insight: the risk and benefits of bisphosphonates for the treatment of tumor-induced bone disease. Nature Clinical Practice Oncology, January 2007, vol. 4, №1, 42 – 55.

[45] Dannemann C, Gratz KW, Riener MO, et al. Jaw osteonecrosis related to bisphosphonate therapy. A severe secondary disorder. Bone 2007; 40: 828 – 834.

[46] Pozzi S, Marcheselli R, Sacchi S, et al. Bisphosphonate-associated osteonecrosis of the jaws: a review of 35 cases and an evaluation of its frequency in multiple mieloma patients. Leukemia and Lymphoma, 2007; 48 (1): 56 – 64.

[47] Favia G, Pilolli GP, Maiorano E. Histologic and histomorphometric features of bisphosphonate-related osteonecrosis of the jaws: An analysis of 31 cases with confocal laser scanning microscopy. Bone 2009; 45 (3): 406 -413.

[48] Goss AN. Bisphosphonate-associated osteonecrosis of the jaws. Climacteric 2007; 10: 5 – 8.

[49] Corso A, Varettoni M, Zappasodi P, et al. A different schedule of zoledronic acid can reduce the risk of the osteonecrosis of the jaw in patients with multiple myeloma. Leukemia 2007; 1 – 4.

[50] Durie BG, Katz M, Crowley J. Osteonecrosis of the jaw and bisphosphonates. N Engl J Med 2005; 353: 99 – 102.

[51] Badros A, Weikkel D, Salama A, et al. Osteonecrosis of the jaw in Multiple Myeloma Patients: Clinical Features and Risk Factors. J Clin Oncol 2006; 24: 945 – 952.

[52] Clarke B, Boyette J, Vural E, et al. Bisphosphonates and jaw osteonecrosis. The UAMS experience. Otolaryngology – Head and Neck Surgery 2007; 136: 396 – 400.

[53] American Dental Association Council on Scientific Affairs: Expert panel recommendations: Dental menagement of patients receiving oral bisphosphonate therapy. J Am Dental Assoc 2006; 137: 1144 – 1150.

[54] Tosi P. Osteonecrosis of the jaw in patients with multiple mieloma, treated with bisphosphonates: Evidence of increasing risk after treatment with zolendronic acid. Haematologica 2006; 91: 968 – 971

[55] Nastro E, Musolin C, Allegra A, et al. Bisphosphonate-Associated Osteonecrosis of the Jaw in Patients with Multiple Myeloma and Breast Cancer. Acta Haematol 2007; 117: 181 – 187

[56] Update Recommendation of the Prevention, Diagnosis, and Treatment of Osteonecrosis of the Jaw in cancer patients. Basel, Novartis, May 2006

[57] Graziani F, Cei S, La Ferla F, et al. Association Between Osteonecrosis of the Jaws and Chronic High-Dosage Intravenous Bisphosphonate therapy. The Journal of Craniofacial Surgery 2006; 17: 876 – 879.

[58] Clavo B, Catala L, Perez JL, et al. Ozozne therapy on cerebral blood flow& a preliminary report. Evidence-based Comlementary and Alternative Medicine 2004; 1: 315 – 319.

[59] Hellstein JW, Marek CL. Bisphosphonate induced osteochemonecrosis of the jaws: an ounce of prevention may be worth a pound of cure. Spec Care Dentist 2006; 26: 8 – 12

[60] Landis BN, Richter M, Dojcinovic I. Osteonecrosis of the jaw after treatment with bisphosphonate. BMJ 2006; 333: 982 – 983.

[61] Migliorati C, Casiglia J, Epstein J, et al. Managing the care of patients with bisphosphonate-associated osteonecrosis: an American Academy of Oral Medicine position paper. J Am Dent Assoc 2005; 136: 1658 – 1668.

[62] Package Insert Revisions re: Osteonecrosis of the jaw: Zometa (zoledronic acid) injection and Aredia (pamidronate disodium) injection. Oncologic Drugs Advisory Committee Meeting, March 4, 2005.

[63] Shane E, Goldring S, Christakos S, et al. Osteonecrosis of the jaw: more research needed. J Bone Miner Res 2006; 21: 1503 – 1505

Section 6

Oral and Maxillofacial Vascular Anomalies: Diagnosis and Treatment

Chapter 11

Vascular Anomalies of the Maxillofacial Region: Diagnosis and Management

Faris Fočo and Amila Brkić

Additional information is available at the end of the chapter

http://dx.doi.org/10.5772/53853

1. Introduction

Vascular anomalies are heterogeneous group of congenital lesions of abnormal vascular development and may occur anywhere on the body. There is a primary distinction between a vascular tumor, which grows by cellular hyperplasia, and a vascular malformation, which represents a localized defect in vascular morphogenesis. Due to the differences in biologic behavior and radiographic features, malformations are further subdivided into low-flow and high-flow lesions [1]. The common characteristic feature of all vascular anomalies is extreme bleeding during surgical excision. Clinicians throughout the world use the classification by Mulliken and Glowacki (1982) to classify these lesions. This classification is based on the vascular lesion's histology, biological behavior and clinical findings [2]. Some of the lesions cause esthetic problems, while some of them are malignant; thus, the therapeutic approach is variable.

Vascular tumors	Vascular malformations
	Slow-flow
Infantile hemangioma	Capillary malformations
Congenital hemangioma	Venous malformations
Tufted angioma	Lymphatic malformations
Kaposiform hemangioendothelioma	Fast-flow
	Arteriovenous malformations

Table 1. Classification of vascular anomalies by Mulliken and Glowacki.

One of the most seen vascular tumors involving the head and neck region are hemangiomas. These benign, generally painless lesions, are a proliferating mass of blood vessels that do not

INTECH
open science | open minds

© 2013 Fočo and Brkić; licensee InTech. This is a paper distributed under the terms of the Creative Commons Attribution License (http://creativecommons.org/licenses/by/3.0), which permits unrestricted use, distribution, and reproduction in any medium, provided the original work is properly cited.

undergo malignant transformation; 60% percent of cases are localized in the head and neck region. The rest are located in the trunk area (5%) and the extremities (15%)[3,4]. Hemangiomas are mostly seen on the surface of the skin, although internal organs such as the liver, larynx, lung or gastrointestinal tract may be also be affected. In the oral cavity, they may occur on the tongue, lips, buccal mucosa, gingiva, palatal mucosa, salivary glands, alveolar ridge and jaw bones [5,6]. In the majority of patients hemangiomas occure as a single lesion, however 20% of patients may have more than one hemangioma [7].

In the literature, multiple hemangiomas are described as one of the components of so called „PHACES“ syndrome. The syndrome includes: Posterior fossa defects, Hemangiomas, Arterial abnormalities, Coarctation of the aorta and cardiac malformations, Eye anomalies, and Sternal defects [8].

In this chapter we will try to describe and document the clinical features and management of the head and neck hemangiomas.

2. Hemangiomas

The term *hemangioma* was originally used to describe any vascular tumor-like structure, whether it was present at or around birth or appeared later in life. The term is comprised of the Greek words *“haema” which means blood*, *“angeio” meaning* vessel and *“oma”* meaning tumor. Histologically hemangiomas are composed of hyperplastic endothelial cells, which are line the inner surface of the blood vessels in the human body, with the capacity for intensive proliferation. The diameter of the blood vesels is important in classification of hemangiomas to capillary and cavernous types [9]. The capillary type, also known as the strawberry hemangioma is composed of small thin-walled vessels of capillary size that are lined by a single layer of flattened or plump endothelial cells and surrounded by a discontinuous layer of pericytes and reticular fibers [9,10] (Figures 1and 2). It was first described in the literature in 1973 by Sznajder et al.[11], under the term "Hemorrhagic hemangioma" [10].

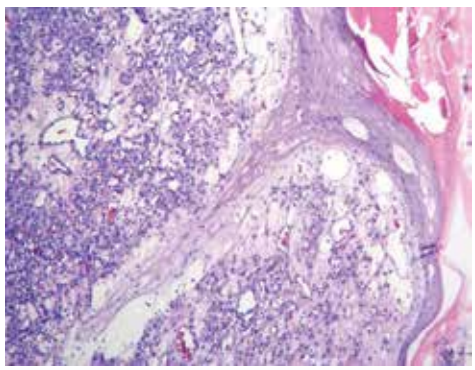

Figure 1. Capillary lip hemangioma

http://dx.doi.org/10.5772/53853

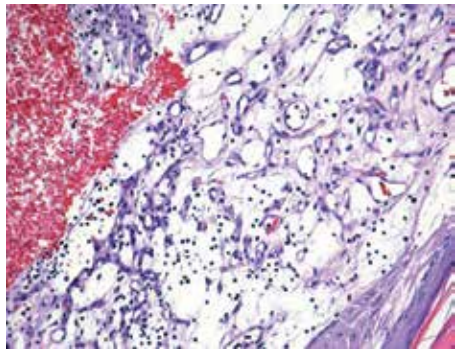

Figure 2. Capillary lip hemangioma 20X

The cavernous type is characterized by large blood-filled spaces, so called cavities, that are separated by a scanty connective tissue stroma [9]. Some lesions of hemangiomas are mixed, which means that they have histologic components of both types [10] (Figures 3 and 4).

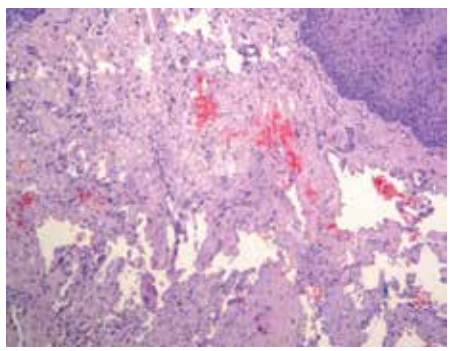

Figure 3. Cavernous lip hemangioma

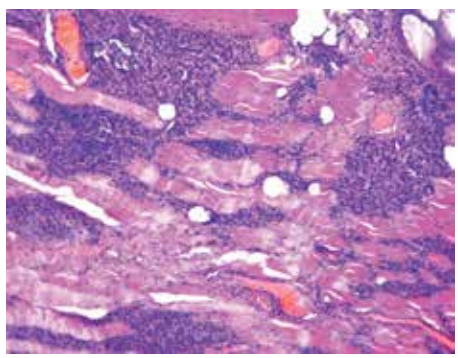

Figure 4. Capillary hemangioma of lips 20X

Clinically, hemangiomas are characterized as a soft, smooth or lobulated, sessile or pedunculated mass and may be seen in any size from a few millimeters to several centimeters [12]. The color of the lesion ranges from pink to red or purple and blanches on the application of pressure; hemorrhage may occur either spontaneously or after minor trauma [3]. Hemangiomas are subdivided into two types: "infantile" and "congenital"[1,13]. However, there is a hypothesis that these two entities are the variations of a single entity ab initio [14].

2.1. Infantile hemangiomas

Infantile hemangiomas are the most common tumors of infancy and occur in approximately 10% of infants by the age of 1 year, with a female predominance [15]. Studies suggest that the ratio between female-male is 3-5 : 1, and a higher prevalence is seen in cases of premature neonates especially when their weight at birth is less than 1500 g. [4,10]. As we mentioned before, the most common localization of hemangiomas is the surface of the skin; thus, hemangiomas usually appear as a barely visible pale, spot, red stain macula, telangiectatic or pseudoecchymotic patch, 2-4 weeks after birth. Massive life threatening lesions usually occur in the liver or central nervous system [16].

Infantile hemangiomas consist of rapidly dividing endothelial cells [13]. Chang et al. [10] state that growth of infantile hemangiomas pass through 3 phases; Proliferation, involuting and involuted phases. The proliferative phase is characterized by rapid growth of the hemangioma during the first year of life. A cellular mass without a defined vascular architecture and nascent blood vessels with red blood cells are evident within the lumen [17]. This phase is the most pronounced during the first 3 - 6 months. However, it may be followed by a phase of slower growth. Regardless of subtype or depth, hemangiomas reach an average of 80% of their final size during the early proliferation stage, a stage that ends at a mean age of 3.2 months. Infantile hemangiomas at the beginning of the proliferation phase, can show an early or late proliferation growth pattern.This means that in cases with an early proliferation growth pattern proliferation starts earlier and essentially is complete after 5 months of age. While In cases of late proliferation growth, proliferation starts later and lasts longer [10] (Figures 5A and 5B).

(A) (B)

Figure 5. A) Infantile hemangioma of the cheek. (B) Frontal view

http://dx.doi.org/10.5772/53853

The involuting phase follows the previous phase; thus in some cases it starts in a few months, while in most cases by 12-18 months of age [10] and continues for 3 to 5 years [17]. Proliferation slows or stops in this phase, and histologic examination shows that the blood vessel architecture becomes more obvious and vessel size enlarges [17]. It is important to mention that in some cases different parts of the hemangioma may be under proliferation and involuting at the same time [10]. Clinical signs of involution are characterized by a color change from bright red to dull red to gray and usually begins centrally and spreads out over the lesion with time. Generally, involution takes place at an estimated rate of 10% per year, so that approximately 50% have involuted by 5 years of age, 70% by 7 years, and 90% by 9 years [10]. The involuted phase is the third phase in the hemangiomas and occurs at 5 to 8 years of age, at which point blood vessels are replaced with a fibrofatty residuum and capillary-sized channels [17]. In this phase depending on the size of the hemangiomas the form changes and may include restoration to normal skin (in 50%) or fibro-fatty form of hemangioma residuum and redundant skin. The later a hemangioma starts to involute, the higher is their risk for residual changes after involution is completed. An involuted hemangioma will never start to grow again; tumor growth in the completed involution phase is always finished [10]. Glucose transporter-1 (GLUT-1) has been shown to be a specific marker for endothelium in all phases of infantile hemangioma, comparing with congenital hemangiomas, in which this marker has not been detected [18,19].

2.2. Congenital hemangiomas

Congenital hemangiomas are fully developed at birth which do not exhibit accelerated postnatal growth. They may be diagnosed on a prenatal ultrasound. In 2000, congenital hemangiomas were identified as rapidly involuting congenital hemangiomas (RICH) and noninvoluting congenital hemangiomas (NICH) [10,13]. Both subtypes have many similarities, such as appearance, location, size, and sex distribution [14,18]. Also they have some overlapping histologic features with infantile hemangioma [18].

2.2.1. Rapidly involuting congenital hemangiomas

Rapidly involuting congenital hemangiomas (RICH) are also present at birth as protuberant, hemispherical, violaceous tumors with an average diameter of 5–6 centimeters, that often have a central depression, scar or ulceration [18]. Histologic features are variable including large and small lobules separated by dense fibrous tissue, and in some lesions there is a sponge-like network of large capillaries [18]. RICH goes through a rapid regression phase and may be completely gone by the time the child is 12 to 18 months old, leaving a mark as some degree of atrothic or redundant skin [20]. In some cases rapidly involuting congenital hemangiomas can undergo rapid but incomplete involution, with a resulting clinical appearance and histology similar to noninvoluting congenital hemangiomas. Because of this, it has been suggested that RICH and NICH may lie within the same spectrum of vascular tumors [14,18,20]. Rapidly involuting congenital hemangiomas are usually located on the limb, head and neck regions and may be associated with decreased gioplatelets, thought to be due to localized intravascular coagulation [21].

2.2.2. Non-involuting congenital hemangiomas

Noninvoluting congenital hemangioma (NICH) is present at birth, grows proportionately with the child, exhibits persistent fast-flow and does not regress [18]. This lesion occurrs more often in male patients. Usually it is a single lesion with an average diameter of 5 cm. Shapes may vary from round-to-ovoid or plaque-like, while the color may also be a variable from pink to purple [18,22]. The overlying skin is frequently punctuated by coarse telangiectasia, often with central or peripheral pallor [22] (Figures 6A and 6B).

(A) (B)

Figure 6. A) Congenital hemangioma. (B) Frontal view

Histologically, NICH is characterized by lobules with high cellular density: each lobule contains one or more large, irregular intralobular vessels surrounded by multiple small vessels with indistinct lumens [18].

Congenital hemangioma	**Infantile hemangioma**
Present at birth.	Visible between 2 weeks and 4 months of age.
Growth is complete at birth or may grow proportionately as the child grows.	Grows rapidly for about 6 to 12 months (average is around 8 months).
Males : females = 1:1	Males : females=1: 3-5
Less common but not rare.	Common [4-5 percent incidence in newborns).
Rapid or no involution (shrinking).	Slow shrinking that takes months or years.
GLUT-1 negative	GLUT-1 positive
Proliferating phase characterized by large and irregularly shaped vessels	Proliferating phase characterized by small regular capillaries

Table 2. Differences between congenital hemangioma and infantile hemangioma

http://dx.doi.org/10.5772/53853

3. Etiology

Hemangioma development is also known as hemangiomagenesis [23]. Although pathogenesis and origin of hemangioma remains incompletely understood, medical literature describes different hypothesis for its development in which extrinsic and intrinsic factors play an important role of endothelial cell proliferation. Placental, estrogen signaling, genetic theory, theory of hypoxia and role of the growth factors involved in angiogenesis such as vascular endothelial growth factor (VEGF), tissue growth factor beta (TGF-beta) and insulin-like growth factor-2 (IGF-2), are just some of theories of hemangioma development.

3.1. Placental origin theory

In the placental theory, there is an opinion that the infantile hemangioma originated from placental trophoblast [23-25]. The hypothesis is based on shared expression of distinct endothelial markers such as GLUT1, Fcγ RII, α2-laminin, Lewis Y antigen, type III iodothyronine deiodinase, indoleamine 2,3-deoxygenase, and insulin-like growth factor 2 in the placenta and hemangioma [22]. Also an incidence of hemangiomas occurrence is more common in infants born to mothers with placental abnormalities, such as preeclampsia and placenta previa, as well as those exposed to chorionic villous sampling (CVS)[26,27], which once more contribute to the placental theory of hemangioma development.

3.2. Estrogen signaling theory

Estrogen signaling theory suggests that because of increased incidence in females, evidence of estrogen receptor (ER) positivity in endothelian cells of proliferating hemangiomas, and elevated levels of circulating 17-β estradiol (which is known to be protective for hypoxia-induced apoptosis) in affected children, the estrogen may be involved in the growth of infantile hemangioma [16,28]. In the perinatal period free estrogen increases, which may stimulate areas of hypoxic endothelium to induce hemangioma formation [16,29].

3.3. Hypoxia theory

In the hypoxia theory, the hypoxic environment leads to an upregulation of factors that promote the recruitment and proliferation of endothelial progenitor cells. These factors include; hypoxia inducible factor-1alpha (HIF-1alpha), stromal cell derived factor-1alpha (SDF-1alpha) and vascular endothelial growth factor (VEGF) [18,27].However,in this theory there is link between hypoxia and estrogen contribution in hemangioma formation. In explanation, increased estrogen hormone levels in the postpartum period create a milieu that promotes new blood vessel development and growth of the lesion [27,29].

3.4. Theory of angiogenesis involved growth factors

Growth factors specifically involved in angiogenesis such as vascular endothelial growth factor(VEGF), insulin-like growth factor-2 (IGF-2) and tissue growth factor beta (TGF-beta) are often increased during the proliferation phases of hemangioma growth; while

during the involution phase of hemangioma, they decrease [30].Vascular endothelial growth factor (VEGF) was originally identified as an endothelial cell specific growth factor stimulating angiogenesis and vascular permeability [18,29]. Studies suggest that in the patients with proliferating hemangiomas, the serum vascular endothelial growth factor concentrations are significantly higher than in patients with involuting hemangiomas, vascular malformations and healthy patients [18,31,32]. Insulin-like growth factor-2 (IGF-2) is known to be highly expressed in infantile and congenital hemangiomas[19]. Links between this factor and angiogenesis would be that IGF-2 induce hypoxia-inducible factor 1-α (HIF-1α), and HIF-1α is known to up-regulate glucose transporter-1 (GLUT-1) [18]. However, GLUT-1 is specific only for infantile hemangiomas [19]. An expression of tissue growth factor beta (TGF-beta) in proliferative hemangioma is significantly higher comparing with the other stages of hemangiomas [33,34].

3.5. Genetic theory

In the genetic theory, a hereditary component is presumed to be the cause of hemangiomas [34,35]. Hemangioma may be passed from parent to child as an autosomal dominant trait with incomplete penetrance [35]. Although the gene responsible for hemangioma/malformation development is not identified, there is an opinion that the gene locus could be on chromosome 5q [34]. Genetics and race may play an important role in hemangiomas occurrence, due to the fact that the majority of hemangiomas occur in infants of Caucasian descent, rarely in Asian and almost never occur in infants of African-American descent [4,36].

4. Clinical findings

The majority of hemangiomas are located on the skin as a soft, smooth or lobulated, sessile or pedunculated masse. Their size may vary from several millimeters to several centimeters [1,3]. The color of the lesions range from pink to red purple and tumors blanch on the application of pressure [3]. Hemangiomas can be superficial, deep, or compound [1]. The superficial hemangioma (affecting only the superficial skin) is red and nodular with no subcutaneous component. A deep hemangioma (affecting only the deep skin) presents as a protrusion with an overlying bluish tint or telangectasia. Compound (mixed) hemangioma has both deep and superficial components [1,10]. By statistics, 60% of hemangiomas are superficial, 15% are deep, and 25% are compound [10].

More than 80% of hemangiomas are solitary lesions [7]. Hemangiomas may be further subdivided into focal, multifocal and segmental hemangiomas. Focal hemangiomas are localized, unilocular lesions which adhere to the phases of growth and involution. Multifocal hemangiomas usually involve a visceral organs, while segmental hemangiomas are more diffuse plaque-like and can lead to untoward functional and esthetic outcomes [1]. Deep segmental hemangiomas proliferate longer, while superficial and focal hemangiomas start to involute earlier [10].

http://dx.doi.org/10.5772/53853

In 60% percent of cases hemangiomas are localized in the head and neck region with the distribution of the trigeminal nerve [1,3,4]. They can be localized even in the infraorbital nerve canal [37].A beard-like distribution is associated with a subglottic hemangioma [1]. In cases of deeply located hemangiomas such as those in eye, symptoms might be amblyopia (lazy eyes) and distortion of the cornea. Hemangiomas in the respiratory system can block breathing, while those located in the liver may be asymptomatic, unless due to huge size stresses the heart. In the oral region, hemangiomas are not that common. If they are present, they may occur on tongue (Figure 7), lips, buccal mucosa, gingiva, palatal mucosa, salivary glands, alveolar ridge and jaw bones [3,5,6].

Figure 7. Hemangioma of the tongue.

In cases of gingival hemangiomas, the lesions often appear to arise from the interdental gingival papilla and spread laterally to involve adjacent teeth [3]. Masticatory trauma plays an important role in development of symptoms such as bleeding of the gingiva or tongue. In hemangiomas of the jaw, clinical signs usually develop after extraction of tooth associated with the lesion. Oral bleeding may be spontaneous in cases that violate the epithelial basement membrane by penetration of the hemangioma [38].

4.1. Diagnosis

The diagnosis of a hemangioma is based on clinical history, physical, radiographic, laboratory and pathohistological examinations. In previous parts of the chapter we have described clinical and histological findings of hemangiomas.

Radiographic examinations are usually performed in cases of deeply positioned hemangiomas. The examinations include conventional radiography with panoramic radiographs, angiography, computed tomography (CT), magnetic resonance imaging (MRI) and Doppler ultrasonography. Conventional radiography is used mostly for diagnosis of bone hemangiomas. Findings are multicystic "soap bubble" appearances. On CT the changes are in bone trabeculae. In diagnosis of soft tissue hemangiomas CT, MRI and Doppler ultrasonography are performed. MR imaging can be used to classify vascular malformations as either low-flow or high-flow lesions, especially when combined with dynamic contrast-enhanced MR angiography. Also, evaluation of extraosseous extension can be diagnosed by MRI [39]. Doppler ultrasonography is the least invasive and most cost-effective imaging to document blood flow in hemangiomas.

Pathohistological examinations for diagnosis and distinguishing hemangiomas from other lesions sometimes do not offer a proper diagnosis. For example in the differential diagnosis from oral pyogenic granuloma, both lesions share the histologic designation "capillary hemangioma" [38].

Laboratory examinations are important in differential diagnosis of hemangiomas to the other arteriovenous malformations and pathologies. Glucose transporter-1 (GLUT-1), vascular endothelial growth factor (VEGF), insulin-like growth factor-2 (IGF-2) and tissue growth factor beta (TGF-beta) are just some of the examinated factors. For example, as we mentioned before, positive staining for GLUT-1 is considered highly specific and diagnostic for hemangioma, and it is useful for making differential diagnosis between hemangioma and other vascular lesions clinically related to it [12].

4.2. Differential diagnosis

Differential diagnosis of the head and neck hemangiomas include several lesions such as pyogenic granuloma, chronic inflammatory gingival hyperplasia, epulis granulomatosa, telangiectasia, angiosarcoma, squamous cell carcinoma, and other vascular appearing lesions such as Sturge Weber syndrome.

Rapidly involuting congenital hemangioma (RICH) as single large tumor associated with lesional ulceration and congestive heart failure, can easily be confused with congenital infantile fibrosarcoma and arteriovenous malformation [19]. Because of this, arteriography in order to exclude infantile fibrosarcoma and arteriovenous malformation play an important role in proper diagnosis. In these cases biopsy is not advantageous because of the high risk of bleeding. It may be reasonable only in cases of previously reported congenital infantile fibrosarcoma [19].

Noninvoluting congenital hemangioma (NICH) may vary from plaque-like with a pink or purple color, to prominent overlying coarse telangiectasias, and be difficult to diagnosed or distinguish from the other, even malignant pathologic lesions [20].

The differentiation between hemangioma and vascular malformations is made on the basis of clinical appearance, histopathology, and biological behaviour [12].

http://dx.doi.org/10.5772/53853

5. Complications

Complications associated with hemangiomas may include;bleeding, ulceration, infection, airway obstruction or visual complications. The incidence of complications such as ulceration is between 5-13% [3]. Ulceration usually occurs in the proliferative phase because the growth of the lesion surpasses epidermal elasticity and blood supply. Large lesions and lesions in the area of the skin flexion such as intertriginous, perineal, and perioral are more prone to develop ulcerations [8,26]. Bleeding and infection development are in many cases just sequels of ulceration [8]. In the oral region bleeding and infection may develop after masticatory minor trauma. Airway obstruction is caused by hemangiomas located in the respiratory system. Infantile hemangioma lesions in a “beard-like” distribution along the jaw are at increased risk of airway involvement. These infants, therefore, need to be monitored frequently for signs of respiratory distress, including a barking cough and/or progressive stridor, especially during the first several months of life [8]. Amblyopia "lazy eyes“ and distortion of the cornea are complications associated with periocular-located hemangiomas [8,26]. Strabismus, myopia, tear duct obstruction, proptosis, and ptosis are other complications associated with the ocular hemangiomas [8].

6. Management

Management of hemangiomas include sevaral factors including age of the patient, type, size, dissemination and depth of penetration [3,12]. There is an opinion that only 10–20% of hemangiomas due to the size, location, stages of growth or regeneration, functional compromise and behaviour, require treatment [12]. For example a large lesions prone to ulceration, bleeding, infection, vital and functional compromises must be treated. Treatment options include: surgery, laser surgery, local and systemic use of corticosteroids, Interferon alfa, Imiquimod, Propranolol, Pingyangmycin. Each treatment modality has its own risks and benefits [12].

6.1. Surgery

Surgical approach to hemangiomas is still the most performed procedure, isolated or in combination with another treatment modalities. Although in more than 80% of hemangiomas the observation is suggested, due to spontaneous involution of the lesions, in some cases such as lip hemangiomas the " wait and see“ approach [40] is not welcome. Lip hemangiomas are highly visibile, prone to ulcerations and have a tendency to a leave residual deformity even after resolution [40,41]. Ulcerations are mostly seen during the proliferative period and can lead to increased scarring, loss of lip contour, and disfigurement [41]. The mentioned authors [40,41] stated benefits of early surgical excision of lip hemangiomas. Even lip hemangiomas that cross the vermiliocutaneous junction can be excised and lip contour achieved without the need to extend scars beyond the junction [41]. It is worth mention that in a study by Chang et al. [41], a higher incidence of lower lip hemangiomas, comparing with hemangiomas located in the upper lip was reported. In cases of localized cutaneous infantile hemangiomas, surgical excision is also

suggested to be performed to minimize the scar after the involuted hemangioma [42,43]. As we know, in proliferative phase, the hemangioma acts like a tissue expander, destroying elastic fibers or causing ulceration resulting in telangiectases, cutaneous laxity, scarring, and fibrofatty residuum [42]. Two types of surgical excisions named lenticular and circular, may be performed in therapy of hemangiomas [42-44]. Lenticular excision of hemangiomas results in increased scar length as compared with the original lesion [43], while circular excision and purse-string closure reduces both the longitudinal and transverse dimensions and converts a large circular lesion into a small ellipsoid scar [42-44]. Also another advantage of the circular excision is minimal distortion of surrounding structures [42]. Vlahović et al. concluded that the circular excision and purse-string suture technique are applicable for hemangioma at any stage [44]. In 1985, Popescu [45], presented a new approach to cavernous haemangioma in different sites, which included an intratumoral ligation. The technique completely interrupted the intratumoral blood flow, resulting in obstruction of vascular lumina, endothelial atrophy, blood clot organization in the small diverticula between them and also subsequent fibrous hyperplasia. In this way the hemangioma mass was split into segments, thus the blood flow was eliminated (Figures 8A and 8B).

(A) (B)

Figure 8. A) Preoperative view of the patient with diagnosed congenital hemangioma.(B) Postoperative view.

High vascularization of hemangiomas is one of reasons why these lesions are prone to bleeding spontaneously or during the trauma. In the case of head and neck hemangiomas, ligations of the external carotid, facial artery and afferent vessels of the tumour with the aim of decreasing blood supply to the vascular dilatations and channels are performed. However, the results are not so good. In the 1990's a new method of coagulation in cavernous hemangiomas was presented [46]. The use of percutaneous copper needles to induce therapeutic coagulation in cavernous hemangiomas, followed by surgery was effective in cases of facial, cervical and oral hemangiomas [47]. The method [46] was presented as a simple, safe and effective treatment for cavernous hemangiomas.

6.2. Laser surgery

From the last few decades, laser surgery has emerged as one of the most performed therapeutic approaches for vascular lesions and hemangiomas. During the 1980's, lasers such as

http://dx.doi.org/10.5772/53853

argon and carbon dioxide were mostly used for the excision of capillary / cavernous hemangiomas because of the low incidence of bleeding [48]. From 1990's the neodymium: ytrium-aluminum-garnet (Nd:YAG) laser started to be in used as a new and effective mode of treatment for vascular lesions [49,50]. Intralesional photocoagulation is the base of the Nd:YAG laser efficacy. Many studies [49-53] evaluated hemangioma outcomes after laser treatment. After a follow up of at least 6 months, reduction in lesion size was noted, especially in cases of large lesions. The authors concluded that the Nd:YAG laser is a safe and effective tool for the treatment of large lesions [49,50]. However, complications such as superficial ulceration or scarring, may be expected [51]. In some cases due to the fact that hemangioma formations do not involute completely, surgical resection or treatment of local steroid injections due to lesion fibrosis may be performed [53].

6.3. Cryotherapy

Superficial cryotherapy with carbon dioxide snow may be effective in the case of facial hemangioma, but this method is completely ineffective in the management of tuberous or cavernous haemangiomas [46].

6.4. Corticosteroids

In conservative therapy of hemangiomas, the corticosteroids are the first choice. They can be used systemic or locally. Growth disturbance and risk of malformation in children is associated with the use of corticosteroids [46].

6.4.1. Systemic corticosteroids

Prednisone as the representative of systemic corticosteroids has found its place in hemangioma treatment. Although the mechanism of action is unknown, there are suggestions that corticosteroids inhibit the expression of VEGF-A by hemangioma-derived stem cells and silencing of VEGF-A expression in these cells inhibited vasculogenesis in vivo [54]. Also they may be responsible for vasoconstriction of arterioles and precapillaries [55]. Daily doses are usually 2-4 mg/kg [56,57] and it is mostly in use for treatment of cutaneous infantile hemangiomas. Parotid hemangiomas for example may be resistant to this therapy [56]. Reasons for this may be differences in drug metabolism, caliber of blood vessels, and/or blood flow in the parotid gland [56].Benett et al. [57] in their study revealed that the dose of the drug plays an important role in the lesional response, thus higher doses show significantly higher responses and results are more visible, if initiated during the initial proliferative phase. Systemic corticosteroids are mostly in use for treatment of large and aggressive lesions.

The long duration of therapy made it difficult to determine the effect the corticosteroid therapy had on the hemangiomas vs spontaneous involution [57]. Systemic corticosteroids carry well-documented risks, such as disseminated varicella and herpes infections, and some authors have questioned their efficacy [47].

6.4.2. Local corticosteroids

Local corticosteroids in the form of intralesional corticosteroid injections are in use for treatment of small, bossed, facial hemangiomas. The response to the therapy is equal to response to systemic therapy. The dose of local corticosteroids is 20mg/ml in the form of triamcinolone acetonide [58,59]. In 6-8 week intervals, 3-5 injections are needed and during application, surrounding areas must be compressed [59]. Contraindications for local corticosteroids are necrosis and secondary infection of the lesion. Local corticosteroids may be responsible for embolization of small arteries, such as retinal artery, thus their use in cases of eye hemangiomas must be limited [59].

6.5. Interferons ALFA-2a, ALFA 2-b

Interferon alfa inhibits the development of new blood vessels from preexisting vessels. Usually therapy with interferon is used when hemangiomas do not respond to the coricosteroid therapy. Daily doses of interferon are 3 million U/m^2 in the form of subcutaneous injections [56,58]. Interferon is not a very safe drug. It was shown that it is neurotoxic, thus neurologic follow up is necessary [58]. Also as in the case of systemic corticosteroids, parotic hemangiomas do not respond to their effects [56]. Complications associated with interferon therapy include neutropenia, abnormalities in liver enzymes and spastic diplegia [58].

6.6. Sclerotherapy

Sclerotherapy is a procedure in combination with surgery, by which application of some chemicals such as hypertonic saline, sodium tetradecyl sulfate, 5% ethanolamine oleate, 5% sodium morrhuate, sodium psylliate, pyngyangmycin, quinine urethrone, 5% and 1% polidocanol solutions produce thrombosis of the vessels and an indurated mass [60-62]. The procedure is most effective when the vascular spaces are small or when blood flow is slow [62]. Hemangioma size after sclerotherapy is decreased and its nature changes to a more fibrous consistency, thus surgical resection of the lesion is easily performed with minimal bleeding [61,62]. Complications of sclerotherapy may include ulceration, inflammatory reaction, necrosis and scar, mostly when the sclerosing agent is applied directly to connective tissue or when a vascular leak caused by excessive injection pressure is identified [61].

6.7. Propranolol

In 2008. Leaute-Labreze et al.[63] presented efficacy of sympatholytic non-selective beta blocker known as propranolol, in therapy of infantile hemangiomas. The mechanism of action is unknown, but there are reports that suggest that within 24-48 hours, hemangiomas respond to therapy by size reduction and changes in color [64]. Although authors report that the drug is most effective in cases of proliferative hemangiomas, results of some cases have shown that hemangiomas in the post-proliferative stage respond well [64,65]. A daily dose of propranolol is 2mg/kg and it is given in three equally doses [65]. Taking in consider that propranolol is a relatively new drug for treatment of infantile hemangiomas, there is little known of its side effects. For example, while Zvulunov et al.

[66] report no significant side effects, some other authors suggest that propranolol may mask the clinical signs of early cardiac failure and diminish cardiac performance. Also it may blunt the clinical features of hypoglycemia[67].

6.8. Imiquimod

Imiquimod is a drug with ability to induce the production of interferon, tumor necrosis factor-alpha and the antiangiogenesis factor tissue inhibitor of matrix metalloproteinase [68]. In topical form as Imiquimod 5% cream may be effective in therapy of superficial infantile hemangiomas [69-71]. Some authors suggest that the Imiquimod should be avoided in those hemangiomas located around the cavities and skin folds [69]. The most common side effects of topical Imiquimod are slight skin erythema and crusting [69,70]. Post-treatment skin reactions are texture changes, which in cases without crusting involuted to almost normal skin [70].

6.9. Bleomycin

Bleomycin is an antibiotic from the culture medium of streptomyces verticullust, with properties of an anticancer agent [72]. In treatment of infantile hemangiomas, bleomycin in the form of bleomycin A5 may be used isolated [73] or in combination with prednisone [72,73]. As intralesional injection its efficacy is based on a high sclerosing effect on vascular endothelium [74], thus it is most effective in cases of proliferating infantile hemangiomas, inhibiting the proliferation [72]. The results of studies have show a high incidence of complete hemangioma involutions, better recovery of skin color and less scar forming in small hemangiomas, after bleomycin therapy [72-74]. Side effects of therapy include edema, ulceration, gastrointestinal symptoms such as nausea and lack of appetite [72,74], cellulitis and transient hair loss [73].

7. Conclusion

Each treatment modality of head and neck located hemangiomas has its own risks and benefits. In cases of infantile hamangiomas, oral propranolol is very useful and well tolerated, having minimal side-effects in the resolution of the hemangiomas. In adult patients surgical treatment including intratumoral ligation, isolated or in combination with laser or sclerotherapy is the most performed therapeutic option.

Acknowledgements

The authors thank pharmaceutical company Roche d.o.o.-Roche Ltd for article processing charge's support.

Author details

Faris Fočo[1] and Amila Brkić[2]

1 Department of Maxillofacial surgery, Clinical center of University in Sarajevo, Sarajevo, Bosnia and Herzegovina

2 Department of Oral surgery, Faculty of Dentistry, Sarajevo University, Sarajevo, Bosnia and Herzegovina

References

[1] Richter GT, Friedman AB. Hemangiomas and vascular malformations: current theory and management. Int J Pediatr. 2012;2012:645678. Epub 2012 May 7.

[2] Mulliken JB, Glowacki J. Hemangiomas and vascular malformations in infants and children: a classification based on endothelial characteristics. *Plastic and Reconstructive Surgery*. 1982;69(3):412–422.

[3] Dilsiz A, Aydin T, Gursan N. Capillary hemangioma as a rare benign tumor of the oral cavity: a case report. *Cases Journal* 2009, 2:8622 doi:10.4076/1757-1626-2-8622.

[4] Mulliken JB, Fishman SJ, Burrows PE. Vascular anomalies. Curr Probl Surg 2000;37:517-84.

[5] Kocer U, Ozdemir R, Tiftikcioglu YO, Karaaslan O: Soft tissue hemangioma formation within a previously excised intraosseous hemangioma site. *J CraniofacSurg 2004;* 15:82-83.

[6] Açikgöz A, Sakallioglu U, Ozdamar S, Uysal A: Rare benign tumours of oral cavity--capillary haemangioma of palatal mucosa: a case report. *Int J Paediatr Dent 2000,* 10:*161-165.*

[7] Margileth AM, Museles M. Cutaneous hemangiomas in children: Diagnosis and conservative management. JAMA 1965;194:523.8.

[8] Schlosser KA. Infantile hemangioma: how to treat this benign neoplasm of childhood. JAAPA. 2009 May;22(5):46-9.

[9] Neville BW, Damm DD, Allen CM, Bouquot JE: *Oral and Maxillofacial Pathology*. 2nd edition. WB Saunders; 2002:447-449.

[10] Chang LC, Haggstrom AN, Drolet BA, et al. Growth characteristics of infantile hemangiomas: implications for management. Pediatrics 2008;122:360-7.

[11] Sznajder N, Dominguez FV, Carraro JJ, Lis G: Hemorrhagic hemangioma of gingiva: report of a case. *J Periodontol* 1973, 44:579-582.

[12] Gill JS, Gill S, Bhardwaj A, Grover HS. Oral Haemangioma. Case Report Med. 2012; 2012: 347939.

[13] Mulliken JB, Enjolras O. Congenital hemangiomas and infantile hemangioma: missing links. J Am Acad Dermatol. 2004 Jun;50(6):875-82.

[14] Berenguer B, Mulliken JB, Enjolras O, Boon LM, Wassef M, Josset P, Kozakewich HP. Rapidly involuting congenital hemangioma: clinical and histopathologic features. Pediatr Develop Pathol 2003;6:495-510.

[15] Gorincour G, Kokta V, Rypens F, Garel L, Powell J, Dubois J. Imaging characteristics of two subtypes of congenital hemangiomas: rapidly involuting congenital hemangiomas and non-involuting congenital hemangiomas. Pediatr Radiol. 2005 Dec; 35(12):1178-85.

[16] Kleinman ME, Greives MR, Churgin SS, Blechman KM, Chang EI, Ceradini DJ, Tepper OM, Gurtner GC. Hypoxia-induced mediators of stem/progenitor cell trafficking are increased in children with hemangioma. Arterioscler Thromb Vasc Biol. 2007 Dec;27(12):2664-70.

[17] Bischoff J. Progenitor cells in infantile hemangioma. J Craniofac Surg. 2009 Mar;20 Suppl 1:695-7.

[18] Picard A, Boscolo E, Khan ZA, Bartch TC, Mulliken JB, Vazquez MP, Bischoff J. IGF-2 and FLT-1/VEGF-R1 mRNA levels reveal distinctions and similarities between congenital and common infantile hemangioma. Pediatr Res. 2008 Mar;63(3):263-7.

[19] Konez O, Burrows PE, Mulliken JB, Fishman SJ, Kozakewich HPV. Angiographic features of rapidly involuting congenital hemangioma (RICH). Pediatr Radiol (2003) 33: 15–19.

[20] Browning JC, Metry DW. Rapidly involuting congenital hemangioma: case report and review of the literature. Dermatol Online J. 2008 Apr 15;14(4):11.

[21] Krol A, MacArthur CJ. Congenital hemangiomas: rapidly involuting and non-involuting congenital hemangiomas. BArch Facial Plast Surg 2005;7:307-311.

[22] Enjolras O, Mulliken JB, Boon LM, Wassef M, Kozakewich HP, Burrows PE. Noninvoluting congenital hemangioma: a rare cutaneous vascular anomaly. Plast Reconstr Surg. 2001 Jun;107(7):1647-54.

[23] Barnés CM, Huang S, Kaipainen A, Sanoudou D, Chen EJ, Eichler GS, Guo Y, Yu Y, Ingber DE, Mulliken JB, Beggs AH, Folkman J, Fishman SJ. Evidence by molecular profiling for a placental origin of infantile hemangioma. Proc Natl Acad Sci U S A. 2005 Dec 27;102(52):19097-102.

[24] Pittman KM, Losken HW, Kleinman ME, Marcus JR, Blei F, Gurtner GC, Marchuk DA. No evidence for maternal-fetal microchimerism in infantile hemangioma: a molecular genetic investigation. J Invest Dermatol. 2006 Nov;126(11):2533-8.

[25] Sun ZY, Yi CG, Zhao H, Yin GQ, Gao M, Liu YB, Qin JD, Wang SF, Guo SZ. Infantile hemangioma is originated from placental trophoblast, fact or fiction? Med Hypotheses. 2008 Sep;71(3):444-8.

[26] Ritter MR, Butschek RA, Friedlander M, Friedlander SF. Pathogenesis of infantile haemangioma: new molecular and cellular insights. *Expert Rev Mol Med*. 2007;9(32): 1-19.

[27] Chang EI, Chang EI, Thangarajah H, Hamou C, Gurtner GC. Hypoxia, hormones, and endothelial progenitor cells in hemangioma. Lymphat Res Biol. 2007;5(4):237-43.

[28] Sasaki GH, Pang CY, Wittliff JL. Pathogenesis and treatment of infant skin strawberry hemangiomas: clinical and in vitro studies of hormonal effects. Plast Reconstr Surg. 1984; 73: 359–370.

[29] Kleinman ME, Greives MR, Churgin SS, Blechman KM, Chang EI, Ceradini DJ, Tepper OM, Gurtner GC. Hypoxia-induced mediators of stem/progenitor cell trafficking are increased in children with hemangioma. Arterioscler Thromb Vasc Biol. 2007 Dec;27(12):2664-70.

[30] Byrne AM, Bouchier-Hayes DJ, Harmey JH. Angiogenic and cell survival functions of vascular endothelial growth factor (VEGF). J Cell Mol Med. 2005 Oct-Dec;9(4): 777-94.

[31] Przewratil P, Sitkiewicz A, Wyka K, Andrzejewska E. Serum levels of vascular endothelial growth factor and basic fibroblastic growth factor in children with hemangiomas and vascular malformations--preliminary report. Pediatr Dermatol. 2009 Jul-Aug;26(4):399-404.

[32] Przewratil P, Sitkiewicz A, Andrzejewska E. Serum levels of basic fibroblastic growth factor (bFGF) in children with vascular anomalies: Another insight into endothelial growth. Clin Biochem. 2010 Jul;43(10-11):863-7.

[33] Yuan WL, Qin XJ, Wang XK. Expression and correlation of mast cell, Clusterin/apoJ and transforming growth factor-beta in the different stages of human dermal hemangioma. Hua Xi Kou Qiang Yi Xue Za Zhi. 2009 Aug;27(4):361-5.

[34] Walter, JW, et al. Genetic mapping of a novel familial form of infantile hemangioma. *Am J Med Genet* 1999. 82:77-83.

[35] Blei, F, Walter, J, Orlow, SJ, Marchuk, DA. Familial segregation of hemangiomas and vascular malformations as an autosomal dominant trait: a rare genetic disorder. *Arch Dermatol* 1998. 134:718-722.

[36] Song JK, Niimi Y, Berenstein A. Endovascular treatment of hemangiomas. Neuroimaging Clin N Am. 2007 May;17(2):165-73.

[37] Walch C, Anderhuber W, Luxenberger W, Humer-Fuchs U Cavernous haemangioma in the infraorbital nerve canal--an unusual expansion in the maxillary sinus J Laryngol Otol. 1998 Sep;112(9):872-4.

[38] Rachappa MM, Triveni MN. Capillary hemangioma or pyogenic granuloma: A diagnostic dilemma. Contemp Clin Dent. 2010 Apr;1(2):119-22.

[39] Donnelly LF, Adams DM, Bisset GS 3rd. Vascular malformations and hemangiomas: a practical approach in a multidisciplinary clinic. AJR Am J Roentgenol. 2000 Mar; 174(3):597-608.

[40] Li WY, Chaudhry O, Reinisch JF. Guide to early surgical management of lip hemangiomas based on our experience of 214 cases. Plast Reconstr Surg. 2011 Nov;128(5): 1117-24.

[41] Chang CS, Wong A, Rohde CH, Ascherman JA, Wu JK. Management of lip hemangiomas: Minimizing peri-oral scars. J Plast Reconstr Aesthet Surg. 2012 Feb;65(2): 163-8.

[42] Mulliken JB, Rogers GF, Marler JJ. Circular excision of hemangioma and purse-string closure: the smallest possible scar. Plast Reconstr Surg. 2002 Apr 15;109(5):1544-54.

[43] Wu JK, Rohde CH. Purse-string closure of hemangiomas: early results of a follow-up study. Ann Plast Surg. 2009 May;62(5):581-5.

[44] Vlahovic A, Simic R, Kravljanac D Circular excision and purse-string suture technique in the management of facial hemangiomas. Int J Pediatr Otorhinolaryngol. 2007 Aug;71(8):1311-5.

[45] Popescu V. Intratumoral ligation in the management of orofacial cavernous haemangiomas. J Maxillofac Surg. 1985 Jun;13(3):99-107

[46] Li ZP. Therapeutic coagulation induced in cavernous hemangioma by use of percutaneous copper needles. Plast Reconstr Surg. 1992 Apr;89(4):613-22.

[47] Ogunsalu C, Fray D, Lewis A. Surgery combined with copper wire implantation in the management of cavernous orofacial haemangiomas. Aust Dent J. 2000 Mar;45(1): 55-60

[48] Apfelberg DB, Maser MR, Lash HReview of usage of argon and carbon dioxide lasers for pediatric hemangiomas. Ann Plast Surg. 1984 Apr;12(4):353-60.

[49] Vesnaver A, Dovsak DA. Treatment of large vascular lesions in the orofacial region with the Nd:YAG laser. J Craniomaxillofac Surg. 2009 Jun;37(4):191-5.

[50] Vesnaver A, Dovsak DA. Treatment of vascular lesions in the head and neck using Nd:YAG laser. J Craniomaxillofac Surg. 2006 Jan;34(1):17-24.

[51] Chang CJ, Fisher DM, Chen YR. Intralesional photocoagulation of vascular anomalies of the tongue. Br J Plast Surg. 1999 Apr;52(3):178-81.

[52] Clymer MA, Fortune DS, Reinisch L, Toriumi DM, Werkhaven JA, Ries WR Interstitial Nd:YAG photocoagulation for vascular malformations and hemangiomas in childhood. Arch Otolaryngol Head Neck Surg. 1998 Apr;124(4):431-6.

[53] Burstein FD, Simms C, Cohen SR, Williams JK, Paschal M. Intralesional laser therapy of extensive hemangiomas in 100 consecutive pediatric patients. Ann Plast Surg. 2000 Feb;44(2):188-94.

[54] Greenberger S, Boscolo E, Adini I, Mulliken JB, Bischoff J. Corticosteroid Suppression of VEGF-A in Infantile Hemangioma-Derived Stem Cells.N Engl J Med 2010; 362:1005-1013.

[55] Sadan N, Wolach B. Treatment of hemangiomas of infants with high doses of prednisone. J Pediatr 1996; 128(1):141-6.

[56] Blei F, Isakoff M, Deb G. The Response of Parotid Hemangiomas to the Use of Systemic Interferon Alfa-2a or Corticosteroids. *Arch Otolaryngol Head Neck Surg*. 1997;123(8):841-844.

[57] Bennett M, Fleischer, Jr AB, Chamlin SL, Frieden IJ. Oral Corticosteroid Use Is Effective for Cutaneous Hemangiomas: An Evidence-Based Evaluation. *Arch Dermatol*. 2001;137(9):1208-1213.

[58] Drolet BA, Esterly NB, Frieden IJ. Hemangiomas in children. N Engl J Med 1999; 341(3):173-81.

[59] Roberts LJ. Management of hemangiomas. Pediatr Dermatol 1997; 14(1):57-83.

[60] Levy C, Mandel L. Sclerotherapy of intraoral hemangioma. N Y State Dent J. 2012 Apr;78(3):19-21.

[61] Selim H, Selim A, Khachemoune A, Metwally SA. Use of sclerosing agent in the management of oral and perioral hemangiomas: review and case reports. Med Sci Monit. 2007 Sep;13(9):CS114-119.

[62] Choi YH, Han MH, O-Ki K et al: Craniofacial cavernous venous malformations: percutaneous sclerotherapy with use of ethanolamine oleate. J Vasc Interv Radiol, 2002; 13: 475–82.

[63] Leaute-Labreze C, Dumas de la Roque E, Hubiche T, Boralevi F, Thambo J-B, Taieb A. Propranolol for severe hemangiomas of infancy. N Engl J Med 2008;358:2649-51.

[64] Bertrand J, Sammour R, McCuaig C, Dubois J, Hatami A, Ondrejchak S, Boutin C, Bortoluzzi P, Laberge LC, Powell J. Propranolol in the treatment of problematic infantile hemangioma: review of 35 consecutive patients from a vascular anomalies clinic. J Cutan Med Surg. 2012 Mar-Apr;16(2):115-21.

[65] Guldbakke KK, Rørdam OM, Huldt-Nystrøm T, Hanssen HK, Høivik F. Propanolol used in treatment of infantile hemangioma. Tidsskr Nor Laegeforen. 2010 Sep 23;130(18):1822-4.

[66] Zvulunov A, McCuaig C, Frieden IJ, Mancini AJ, Puttgen KB, Dohil M, Fischer G, Powell J, Cohen B, Ben Amitai D. Oral propranolol therapy for infantile hemangiomas beyond the proliferation phase: a multicenter retrospective study. Pediatr Dermatol. 2011 Mar-Apr;28(2):94-8.

[67] Siegfried EC, Keenan WJ, Al-Jureidini S. More on propranolol for hemangiomas of infancy. N Engl J Med. 2008 Dec 25;359(26):2846; author reply 2846-7.

[68] Ho NT, Lansang P, Pope E. Topical imiquimod in the treatment of infantile hemangiomas: a retrospective study. J Am Acad Dermatol. 2007 Jan;56(1):63-8.

[69] Ma G, Lin XX, Jiang CH, Chen H, Li W, Hu XJ, Jin YB, Chen D, Chen XD, Ye XX. Clinical application of imiquimod for the treatment of infantile hemangiomas. Zhonghua Zheng Xing Wai Ke Za Zhi. 2011 Nov;27(6):411-4.

[70] Jiang C, Hu X, Ma G, Chen D, Jin Y, Chen H, Chen X, Lin X. A prospective self-controlled phase II study of imiquimod 5% cream in the treatment of infantile hemangioma. Pediatr Dermatol. 2011 May-Jun;28(3):259-66.

[71] Barry RB, Hughes BR, Cook LJ. Involution of infantile haemangiomas after imiquimod 5% cream. Clin Exp Dermatol. 2008 Jul;33(4):446-9.

[72] Luo QF, Zhao FY. The effects of Bleomycin A5 on infantile maxillofacial haemangioma. Head Face Med. 2011 Jul 7;7:11.

[73] Luo Q, Zhao F. How to use bleomycin A5 for infantile maxillofacial haemangiomas: clinical evaluation of 82 consecutive cases. J Craniomaxillofac Surg. 2011 Oct;39(7): 482-6.

[74] Muir T, Kirsten M, Fourie P, Dippenaar N, Ionescu GO. Intralesional bleomycin injection (IBI) treatment for haemangiomas and congenital vascular malformations. Pediatr Surg Int. 2004 Jan;19(12):766-73.

Section 7

Laser Applications in Oral and Maxillofacial Surgery

Chapter 12

Applications of Low Level Laser Therapy

Vanja Vučićević Boras, Danica Vidović Juras,
Ana Andabak Rogulj, Dragana Gabrić Pandurić,
Željko Verzak and Vlaho Brailo

Additional information is available at the end of the chapter

http://dx.doi.org/10.5772/52678

1. Introduction

1.1. Characteristics of the low level laser therapy (LLLT)

Laser is an acronym for 'Light Amplification by Stimulated Emission of Radiation'. The name of the low level laser is an abbreviation of its active medium such as GaAlAs (Gallium, Aluminum and Arsenide) or He-Ne laser (Helium and Neon).

1.2. Designation

LLLT are designated by several parameters. The first is laser power which ranges from 10^{-3} to 10^{-1} W followed by wavelength which ranges from 300 to 10.600 nm. Pulse rate can range from 0 (continuous) to 5000 Hz, the duration of pulse can range from 1-500 milliseconds with an interpulse interval of 1-500 milliseconds with a total irradiation time of 10-3000 seconds and with intensity (power x irradiation time/irradiated area) ranging from 10^{-2} to 10^{2} J/cm^2 [1].Therapeutic lasers are within visible red to near visible red electromagnetic spectrum ranging from 630 to 980 nm. The simplest way to categorize these lasers is according to their wavelength. The depth of laser penetration varies, and oral mucosa is quite transparent on the wavelengths (it does not absorb light well), bone and skin are quite transparent, whereas muscles absorb the most light [1].

1.3. Exposure

The greatest problem in the use of LLLT is finding the optimal dose of exposure. The tissue dose is expressed by energy density measured in joules per cm² (J/cm²). Produced energy is obtained by multiplying the laser output power in milliwatts by exposition time in seconds

INTECH
open science | open minds

© 2013 Vučićević Boras et al.; licensee InTech. This is a paper distributed under the terms of the Creative Commons Attribution License (http://creativecommons.org/licenses/by/3.0), which permits unrestricted use, distribution, and reproduction in any medium, provided the original work is properly cited.

(for example 50 mW x 40 seconds=2000 mJ or 2J). For example, the area which is irradiated is 2 cm^2 which is multiplied by 2 J and the fluence of 2/2 is obtained (surface tissue dose is 1 J/cm^2). By decreasing the irradiated area, an increase in intensity is obtained. For example, the irradiated area is 0.5 cm^2, 2J are divided by 0.5 and the dose becomes 4 J/cm^2 since the energy is emitted through smaller area which increases local intensity. Since the dose is most affected by the size of the laser probe, a slim probe will result in high doses of joules per cm^2. However, this does not imply that energy applied on the tissue is high, although the intensity of the light energy emitted at the end of the slim probe was high [1]. Joules per square centimeter (J/cm^2, dose, fluence) denotes the irradiation intensity on the surface of the tissues, but not the dose in the depth. It is much easier to use the term 'energy on the spot' (only the number of joules is calculated at each spot) which is acceptable for clinical but not for scientific purposes. The spot denotes the size of the tip of the laser probe (spot size). A small tip of the laser probe produces a higher concentration of power per square millimeter, while a wider tip of the laser probe dissolves the same energy over a larger area [1]. The main absorption of wavelength occurs in the pigmented chromophores such as hemoglobin in the blood; therefore cardiovascular tissues absorb these wavelengths quite well. Another important factor is melanin quantity in the target tissues which absorbs large amounts of these wavelengths. More energy is absorbed on the surface in comparison to deeper tissues which can lead to local tissue overheating and pain [1].

1.4. Basic principles of LLLT effects

Principles of biostimulation via therapeutic lasers was introduced more than 20 years ago when they were used in dermatology for wound healing. According to Genovese, biological effects caused by low level lasers are due to low energy deposited into tissues where deposited energy results in primary, secondary and general therapeutic effects. This results in the analgesic and anti-inflammatory effects as well as in improvement in healing [2]. LLLT acts according to the Arndt-Schulz principle which states that if the stimulus is too weak, no effect is seen. Increased stimulation and optimal dose leads to the optimal effect; while, further dose increase leads to a decreased effect. Additional stimulation leads to the inhibition of stimulation [1]. It seems that LLLT act analgesically since they improve endorphin release and therefore inhibit nociceptive signals and control pain mediators [3]. They can also act analgesically by inhibiting pain signals which partially leads to the transient varicosities along the neurons which decrease impulse transmission. These lasers act on cellular reduction-oxidative potential. Cells are acidic in a lowered redox state, but after laser irradiation they become alkaline and afterwards they can act in an optimal way. In healthy cells, irradiation with this laser does not lead to the increase in redox potential; therefore, the laser does not affect healthy cells. It is well known that LLLT stimulate lymphocytes, activate mast cells, and increase production of adenosine-triphosphate in the mitochondria and proliferation of various cell types therefore acting as anti-inflammatory [3]. Furthermore, these lasers stimulate microcirculation which results in the change of capillary hydrostatic pressure which in turn results in edema absorption and elimination of intermediary metabolites [3]. Studies show that laser therapy leads to the increase in ascorbic acid in the fibroblasts, which increases hydroxyproline production and consequently, collagen production. Fur-

thermore, these lasers lead to the increase in mitotic activity of epithelial cells and fibroblasts [3]. On the vascular level, lasers improve proliferation of the epithelial cells, which results in the increased number of blood vessels as well as increased production of granulation tissue. LLLT lead to the relaxation of the smooth muscles which decreases pain [3]. Gallium-Aluminum-Arsenide laser (BTL-5000, www.btl.hr) was used at the Department of Oral Medicine, School of Dental Medicine, University of Zagreb. Results of some studies have already been reported while some studies are still in progress. The results of our studies have shown that this type of laser is quite useful in patients with hyposalivation. Also, it has been shown to be successful in treatment of patients with recurrent herpes infection since the lesions heal more rapidly. The best results are seen in patients who had lower alveolar nerve damage usually after the third molar surgery. The patients were suffering from paresthesia and neuropathic pain which subsided in a significant number of patients after therapy. It has also been noticed that 20 laser therapy sessions are needed instead of the usual ten. Chronic states (pain, paresthesia and wounds) are treated once or twice a week since there is a cumulative laser effect. Patients suffering from pain might experience even stronger pain after laser therapy. This condition is temporary and reflects actual improvement of the patient's condition. The pain level decreases within 24 hours. It is of utmost importance to inform the patient about this transient side effect before initiating therapy.

1.5. General contraindications for LLLT

Therapeutic lasers weaker than 500 mW are considered to be devices of low risk according to the USA Food and Drug Administration. Naturally, the use of protective glasses both for the patient and the clinician is a must. In patients with coagulation disorders the use of LLLT should be avoided since they interfere with blood circulation in a way still unknown. Presences of malignant disease as well as precancerous lesions are also contraindications since LLLT stimulates cell growth. Irradiation of all endocrine glands, especially the thyroid gland should be avoided. During pregnancy, menstrual cycle, febrile conditions, in epileptic patients and those who have cochlear implants the use of lasers is not indicated [1,2].

1.6. Laser hygiene

If the laser probe is inseparable from the device, it can be disinfected with disinfectants for surfaces and then it can be covered with sterile transparent materials or other disposable barrier protections. If the probe can be separated from the device, it can be sterilized [1].

2. Applications of LLLT

2.1. Recurrent aphthous ulcers (RAU)

Tezel et al. [4] investigated the use of NdYAG laser on 20 patients with recurrent aphthous ulcerations. The patients reported significantly less pain as well as functional complications after laser therapy. Also, they stated that they experienced faster healing compared to the usual medication therapy.

Zand et al. [5] have investigated the use of CO_2 laser (1W of defocused continuous mode) in 15 patients with recurrent aphthous ulcerations in comparison to the placebo (recurrent aphthous ulcerations which were not treated). Both ulcerations were covered with transparent gel without the use of anesthetics. The power of CO_2 laser was 2-5mW after passing through gel which did not significantly increase the temperature. The results of the same study [5] show that one treatment with use of CO_2 laser of low intensity instantly reduces pain in patients with recurrent aphthous ulcerations without any adverse effects.

2.2. Oral lichen planus (OLP)

Jajarm et al. [6] investigated the use of 630 nm laser in 15 patients with erosive-atrophic lichen planus twice a week. The same authors (6) concluded that the laser was equally effective in the treatment of oral lichen planus as was topically applied corticosteroids and without any side effects.

Cafaro et al. [7] treated 13 patients with OLP using the pulsed diode laser (GaAs). The patients were exposed to the pulsed infrared laser (4J/cm² for one minute); the irradiated area was 0.8 cm. The same authors [7] concluded that there was a significant decrease in the lesions and decreased pain without any side effects.

Trehan and Taylor [8] used a 308 nm laser on nine patients with OLP with the first dose of 100 mJ/cm² once a week. The same authors [8] reported that treatments were pain-free and well tolerated. Five patients experienced improvement after seven therapy sessions with this laser and the authors concluded that the therapy was successful. In our opinion, the use of LLLT should be avoided in patients with oral lichen planus because OLP is a precancerous lesion and therefore additional stimulation of cell growth may be dangerous.

2.3. Herpes simplex infections

Schindl and Neumann [9] evaluated the effect of low level laser therapy (wavelength 690 nm, intensity 80 mW/cm², dose 48J/cm²) in 50 patients with recurrent perioral herpes (at least once a month during six months). Patients were given therapy every day for two weeks; the control group was given placebo therapy with laser as well. The average interval without herpes lesions was 37.5 weeks in patients who received laser therapy and 3 weeks in patients who received placebo and the difference was significant. The same authors [9] concluded that ten treatments with laser significantly decreased incidence of local recurrent herpes infection. De Carvalho et al. [10] used a laser of 780 nm wavelength, 60mW; 3 J/cm² or 4.5J/cm² once a week during ten weeks. In patients treated with laser (in comparison to the patients who were given medications), a significant decrease in herpes lesions and inflammatory edema was seen; however there was no significant decrease in pain or monthly recurrences.

Munoz Sanchez et al. [11] used a 670 nm wavelength laser, power output of 40 mW; 1.6J; 2.04J7cm², 51 mW/cm² applied to the each vesicle in the prodromal stage and 4.8J on the crust together with 1.2J on the cervical vertebra C2-C3. The same authors [11] concluded

that laser therapy improves healing in the beginning and prolongs the intervals between recurrences, that is, those patients have fewer recurrences.

Marrotti et al. [12] used a 660 nm wavelength laser, energy density of 120 J/cm², output power of 40 mW, during two minutes on spot and 4.8J of energy per spot on four spots. After 24 hours, the patients returned and then 3.8J/cm² and 15mW were applied to their lesions (the total dose was 0.6J). The same procedure was repeated after 72 hours and one week after. There were no significant side effects and herpetic lesions healed faster. Carvalho-Ferreira et al. [13] described two patients with herpetic infection who were treated five times with laser (660 nm wavelength, 30J/cm² of continuous mode and power density of 100mW which was applied for 8 seconds). Remission occurred after five days without reoccurrences during the next 17 months in both patients.

2.4. Xerostomia

Vidović-Juras et al. [14] treated 17 patients with xerostomia and reported a significant increase in salivary flow rate. The same authors (14) used the BTL-5000 laser with use of infrared laser with a density of 1.8 J/cm², frequency 5.2Hz, output power 30 mV during ten treatments. Salivary flow rate was initially 0.6±0.3 ml/5 min which increased to 1.1±0.8 ml/5 min. Lončar et al. [15] concluded that pulsed GaAlAs laser, wavelength 904 nm applied to the both parotid and submandibular glands was efficient in reducing xerostomia. The distance of laser probe was 0.5 cm whereas the irradiation was 246 mW/cm². Exposition time was 120 seconds a day during ten days. Average density of energy was 29.5 J/cm². Salivary flow rate increased to 0.13 mL/min from initial 0.05 mL/min and the result was significant. Simoes et al. [16] treated a 60-year-old person suffering from Sjogren's syndrome by use of laser with a wavelength of 780 nm and average density of energy 3.8 J/cm² and output power of 15 mW at the area of parotid, submandibular and sublingual glands, three times a week for 8 months. The same authors [16] concluded that this therapy was effective for xerostomia. Simoes et al. [17] also reported that diode laser was beneficial in patients after therapeutic head and neck irradiation (660 nm, 6J/cm2, 0.24 J, 40 mW). One group of 12 patients was given laser therapy three times a week, while the other group received laser therapy once a week. The same authors concluded that laser therapy is beneficial to patients with xerostomia.

2.5. Burning mouth syndrome (BMS)

Yang and Huang [18] treated 17 patients with burning mouth syndrome by use of laser with the wavelength of 880 nm, output power 3W, 50 msec of intermittent pulse and frequency of 10 Hz which was equivalent to 1.5 W/cm² (3Wx0.05 msecx10 Hz=1,5W/cm²). Depending on the involved area, laser was applied to the area 1cm² for 70 seconds. All the patients received therapy between one and seven times. The average pain score before treatment was 6.7 and the results showed average pain decrease of 47.6%. Kato et al. [19] treated 11 patients with BMS once a week during three weeks with wavelengths of 790 nm. Exposition time was calculated on the energy density of 6J/cm², output power of 120 mW. Burning

symptoms were significantly decreased (80% less) when compared to symptoms before treatment.

Dos Santos et al. [20] reported that 10 BMS patients were treated once a week during ten weeks by use of continuous wavelength of 660 nm, power 40 mW, 20 J/cm², 0.8 J/spot. All the patients reported improvement which was seen on visual analogue scale up to 58% after the tenth session. Vukoja et al. [21] applied the diode laser (800 nm, 3W, 50 msec, 50 Hz which is equivalent to average power of 1.5 W/cm²) to patients with BMS which was beneficial even when the laser was switched off which correlates with a placebo effect.

2.6. Mucositis

Cowen et al. [22] treated 30 patients who were exposed to chemotherapy and radiotherapy after transplantation of peripheral cells or bone marrow with LLLT in order to eliminate symptoms of mucositis. He-Ne laser (632.8 nm, 60 mW) was applied daily on five spots within the oral cavity. Cumulative findings of oral mucositis as well as daily mucositis index were significantly decreased in patients who were treated with laser. Furthermore, patients treated with laser had decreased pain scores and decreased xerostomia symptoms whereas their swallowing abilities were increased compared to the ones who did not receive laser therapy.

Campos et al. [23] directed continuous laser diode (660nm, 40 mW, 6 J/cm2) to the entire oral cavity while laser diode of greater power (1W, 10 seconds applied to 1 cm of mucositis, i.e 10 J/cm²) was used defocused only on ulcerative lesions. After the first application of laser therapy, patients reported decreased pain and xerostomia levels and significant improvement occurred after five laser therapy sessions. In the end, seventeen laser irradiations were needed in order to eliminate all lesions of oral mucositis. De Castro et al. [24] treated 75 patients by use of He-Ne laser after they had finished chemotherapy and radiotherapy due to head and neck carcinomas. They used laser of 2.5 J/cm² or placebo laser. The number of patients who had stage 3 and 4 mucositis and who were treated with laser was significantly lower compared to the ones treated with placebo laser. De Lima et al. [25] found out that low level laser therapy (GaAlAs; 2.5 J/cm2, 600 nm, 10mW) was not efficient in reducing stage 3 or 4 of mucositis, although marginal benefits could not be excluded in terms of reducing unplanned pauses in radiotherapy.

2.7. Paresthesia

During the surgical procedures in oral surgery, various nerve disturbances may develop that usually affect the inferior alveolar nerve. During sagittal osteotomy in order to extract third molars, in 5.5% to 100% of cases the lower alveolar nerve may be damaged.

Miloro and Repasky [26] found that LLLT has significant influence on neurosensory recovery after sagittal osteotomy in the region of the mandibular ramus. The same authors applied a dose of 4-6 J during seven treatments. This was also confirmed by Khullar et al. [27] as well as by other authors. Khullar et al. [27] treated 13 patients with damaged lower alveolar nerves with the GaAlAs laser of 820 nm wavelength (4-6 J applied in every treatment

along the distribution of the nerve in 20 treatments). The same authors reported significant improvement in mechanoreceptive perception of the inferior alveolar nerve; however, there were no significant differences in thermal sensitivity of the nerve between the study and control groups. Ozen et al. [28] successfully treated four patients who had paresthesia one year after surgical procedures on the third molars. They used the GaAlAs diode laser of wavelength 820-830 nm, 6 J during every treatment for 90 seconds in 20 laser applications. In all patients, neurosensory improvement was seen which was shown in objective tests (visual analogue scale, two point discrimination test).

2.8. Implants

The efficacy of laser is highest immediately after implant placement and during the next two weeks. After implant placement in order to reduce postoperative pain and edema, one dose of infrared laser may be applied. If the patient is eager to attend laser therapy a few times, osseointegration will be enhanced [29].

2.9. Pain from orthodontic treatment

LLLT may be used during orthodontic treatment in order to reduce pain and also for the stimulation of tooth movement since it has been reported that a dose of 5.25 J/cm² leads to the increased orthodontic mobility. Higher doses of 35J/cm² lead to the decreased orthodontic mobility [30]. Soussa et al. [31] retracted 13 teeth by use of force of 150 g on each side using coil spring for three days and after diode laser once a month. They reported significant increase in tooth movement in comparison with teeth which were not treated with laser. Also, there were no significant differences in bone resorption or canine roots whether the laser was used or not. Therefore, the same authors suggested that the use of lasers together with orthodontic treatment might shorten orthodontic treatment. Altan et al. [32] also reported that LLLT (diode laser, 780 nm, 20 mW, 10 sec., 5J/cm^2) enhances the process of bone remodeling by stimulating osteoblastic and osteoclastic cell proliferation. On the other hand, Marquezan et al. [33] could not confirm the efficacy of the GaAlAs laser of 830 nm and power output of 100 mW on orthodontic tooth movement in rats. However, the number of osteoclasts increased when the laser was used every day. Xiaoting et al. [34] reported that LLLT was efficient in patients who received orthodontic appliances. However, analgesics were more efficient regardless of the type used (ibuprofen, acetaminophen, and aspirin). Tortamano et al. [35] concluded that lasers (GaAlAs, 830 nm, output power 30 mW) were efficient during the arch insertion, because patients reported lower pain scores and pain intensity during the most painful day. Also, their pain subsided earlier in comparison to the ones who were not treated by laser. The patients were given a dose of 2.5 J/cm² on both sides of the tooth (buccal and lingual). Turhani et al. [36] used mini laser of 670 nm wavelenght and output power of 75 mW during 30 seconds on each tooth. After bracket placement, the perception of pain was decreased after six and 30 hours. The same authors (36) concluded that LLLT may have positive effects on patients not only immediately after bracket placement but also during orthodontic treatment.

2.10. Periodontology

Obradović et al. [37] treated patients with diabetes mellitus and periodontal disease by use of LLLT (670 nm, 5 mW, 2 J/cm², 16 minutes for five days) together with conventional periodontal treatment and concluded that healing was improved as well as collagenization and homogenization in gingival lamina propria on the basis of histopathological findings. Igić et al. [38] treated 140 adolescents with chronic gingivitis by use of laser and conventional therapy and concluded that there was a significant difference in plaque and bleeding indices before and after therapy. The result was more pronounced in the group which was treated with laser. Theodoro et al. [39] used photodynamic therapy by use of LLLT in patients with chronic periodontal disease. The control group consisted of patients with periodontal disease who were subjected only to conventional periodontal therapy. After 180 days, there was a significant difference based on the finding of periodontal pathogens in patients treated with conventional periodontal therapy as well as with laser. However, there were no significant differences in the clinical outcome of both therapies. Aykol et al. [40] used the GaAlAs diode laser of 808 nm wavelength, power output 4J/cm² on the gingiva of the first, second and seventh day. On each evaluation, every day patients who were subjected to laser therapy had better scores in bleeding sulcus indices, depth of clinical attachment and probing depth in comparison to the control group. The same authors concluded that LLLT is a potent additional therapy to non-surgical periodontal treatments since it hastens periodontal healing. Lui et al. [41] found out that there were no differences in periodontal parameters after 3 months of therapy between persons who had laser therapy and those who had not. There was a significant difference after a week and month in those treated with laser; therefore the same authors concluded that laser therapy is effective only for a short period of time. However, Pejčić et al. [42] concluded that laser therapy was beneficial to patients with periodontal disease since there was a significant difference after six months in plaque index, gingival index and bleeding on probing. Rotundo et al. [43] reported that there were no differences in clinical attachment gain after 6 months of ErYAG laser therapy in comparison to the control group which was subjected only to supragingival scaling.

2.11. Dentin hypersensitivity

There are a few theories claiming that the use of LLLT decreases dentin hypersensitivity by decreasing the adhesion of dentin tubuli, by dissolution or dentin recrystallization, evaporation of dentin fluid, or analgesic effect which is connected with depressed nerve transmission or by obliteration of dentin tubuli with tertiary dentin [44]. Irradiation with the GaAlAs laser with maximal dose of 60 mW does not affect enamel or dentin surface morphologically. However, a small amount of laser energy of 830 nm wavelength passes through hard tissues in the pulp and therefore immediate analgesic effect is seen as a consequence of depressed transmission through nerves, probably by blocking afferent C fibers [44]. Yilmaz et al. [44] reported that one dose of irradiation with Cr YSGG (30 seconds, 0.25 W, 20 Hz, =% water and 10% air) or with GaAlAs laser (60 seconds, 8.5 J/cm²) was efficient in decreasing dentin hypersensitivity, which was confirmed in other studies (Kimura et al. [45], Corona et al. [46] as well as Sicilie et al. [47]. Sgolastra et al. [48] concluded that treatment of dentin

hypersensitivity by use of LLLT should be considered experimental since there are only three studies which might be considered as controlled randomized trials and all of them have serious drawbacks which lead to the conclusion that LLLT might be pure placebo effect in patients with dentin hypersensitivity. It seems that this treatment of dentin hypersensitivity would be too simple since dentists use multi-interventional measures to control dentin hypersensitivity (reduction of corrosive food and drinks, change in the brushing techniques, disuse of chewing gums, change of toothpaste, etc). Tanboga et al. [49] evaluated the efficacy of LLLT (Er:YAG) on pain before cavity preparation in children. They found out that the use of LLLT significantly decreased pain in comparison to the children who did not receive laser therapy before cavity preparation.

2.12. Temporomandibular disorders

Oz et al. [50] applied LLLT in twenty persons who suffered from myofascial pain dysfunction syndrome during ten treatments (820 nm, 3 J/cm², 300 mW) and concluded that LLLT was as efficient as the use of occlusal splint in pain management and improvement of mandibular movement in patients with myofascial pain. Marini et al. [51] reported that mandibular function was improved in patients treated by laser (superpulsed GaAs, 900 nm); ten treatments measured by use of visual analogue scale. Also, active and passive mouth opening as well as right and left lateral movements were improved after LLLT in comparison to the given parameters in patients treated by use of non-steroid anti-inflammatory medications. Fikackova et al. [52] treated patients with myofascial pain as well as patients with arthralgias of temporomandibular joint by use of LLLT. They used the GaAlAs laser of 10 J/cm² and 15 J/cm² and concluded that this is an effective therapy for patients with temporomandibular joint pain.

Acknowledgements

The authors wish to thank to the Ministry of Science and Technology in Croatia for kind support of this work (project number 065-0650445-0485).

Author details

Vanja Vučićević Boras[1*], Danica Vidović Juras[1], Ana Andabak Rogulj[1],
Dragana Gabrić Pandurić[2], Željko Verzak[3] and Vlaho Brailo[1]

1 Department of Oral Medicine, School of Dental medicine, University of Zagreb, Croatia

2 Department of Oral Surgery, School of Dental medicine, University of Zagreb, Croatia

3 Department of Pediatric dentistry, School of Dental medicine, University of Zagreb, Croatia

References

[1] Tunér J, Christensen PH. Low level lasers in dentistry. Available at: http://www.laser.nu/lllt/Laser_therapy_%20in_dentistry.htm.2002, pp263-283.

[2] Posten W, Wrone DA, Dover JS, Arndt KA, Silapunt S, Alam M. Low-level laser therapy for wound healing: mechanism and efficacy. Dermatol Surg. 2005;31(3):334-40.

[3] Tezel A, Kara C, Balkaya V, Orbak R. An evaluation of different treatment for recurrent aphthous stomatitis and patient perceptions: Nd:YAG laser versus medication. Photomed Laser Surg. 2009; 27: 101-6.

[4] Lins RD, Dantas EM, Lucena KC, Catão MH, Granville-Garcia AF, Carvalho Neto LG. Biostimulation effects of low-power laser in the repair process. Ann Bras Dermatol. 2010 ;85(6):849-55.

[5] Zand N, Ataie-Fashtami L, Djavid GE, Fateh M, Alinaghizadeh MR, Fatemi SM, Arbabi-Kalati F. Relieving pain in minor aphthous stomatitis by a single session of nonthermal carbon dioxide laser irradiation. Lasers Med Sci. 2009; 24: 515-20.

[6] Jajarm HH, Falaki F, Mahdavi O. A comparative pilot study of low intensity laser versus topical corticosteroids in the treatment of erosive-atrophic oral lichen planus. Photomed Laser Surg. 2011; 29: 421-5.

[7] Cafaro A, Albanese G, Arduino PG, Mario C, Massolini G, Mozzati M, Broccoletti R. Effect of low-level laser irradiation on unresponsive oral lichen planus: early preliminary results in 13 patients. Photomed Laser Surg. 2010; 28 suppl 2: S99-103.

[8] Trehan M, Taylor CR. Low-dose excimer 308-nm laser for the treatment of oral lichen planus. Arch Dermatol. 2004; 140: 415-20.

[9] Schindl A, Neumann R. Low-intensity laser therapy is an effective treatment for recurrent herpes simplex infection. Results from a randomized double-blind placebo-controlled study. J Invest Dermatol. 1999;113(2):221-3.

[10] de Carvalho RR, de Paula Eduardo F, Ramalho KM, Antunes JL, Bezinelli LM, de Magalhães MH, Pegoretti T, de Freitas PM, de Paula Eduardo C. Effect of laser phototherapy on recurring herpes labialis prevention: an in vivo study. Lasers Med Sci. 2010;25(3):397-402.

[11] Muñoz Sanchez PJ, Capote Femenías JL, Díaz Tejeda A, Tunér J. The effect of 670-nm low laser therapy on herpes simplex type 1. Photomed Laser Surg. 2012;30(1):37-40.

[12] Marotti J, Aranha AC, Eduardo Cde P, Ribeiro MS.Photodynamic therapy can be effective as a treatment for herpes simplex labialis. Photomed Laser Surg. 2009;27(2): 357-63.

[13] Carvalho Ferreira D, Barroso Reis HL, Cavalcante FS, dos Santos KRN, Leal Passos MR. Recurrent herpes simplex infections: laser therapy as a potential tool for long-term successful treatment. Rev Soc Bras Med Trop. 2011; 44: 397-99.

[14] Vidović Juras D, Lukač J, Cekić-Arambašin A, Vidović A, Canjuga I, Sikora M, Carek A, Ledinsky M. Effects of low-level laser treatment on mouth dryness. Coll Antropol. 2010;34:1039-43.

[15] Lončar B, Stipetić MM, Baričević M, Risović D. The effect of low-level laser therapy on salivary glands in patients with xerostomia. Photomed Laser Surg. 2011; 29:171-5.

[16] Simões A, de Campos L, de Souza DN, de Matos JA, Freitas PM, Nicolau J. Laser phototherapy as topical prophylaxis against radiation-induced xerostomia. Photomed Laser Surg.2010; 28:357-63.

[17] Simões A, Platero MD, Campos L, Aranha AC, Eduardo Cde P, Nicolau J. Laser as a therapy for dry mouth symptoms in a patient with Sjögren's syndrome: a case report. Spec Care Dentist. 2009; 29:134-7.

[18] Yang HW, Huang YF. Treatment of burning mouth syndrome with a low-level energy diode laser. Photomed Laser Surg. 2011; 29: 123-5.

[19] Kato IT, Pellegrini VD, Prates RA, Ribeiro MS, Wetter NU, Sugaya NN. Low-level laser therapy in burning mouth syndrome patients: a pilot study. Photomed Laser Surg. 2010; 28: 835-9.

[20] Dos Santos Lde F, Carvalho Ade A, Leao JC, Cruz Perez DE, Castro JF. Effect of low-level laser therapy in the treatment of burning mouth syndrome: a case series. Photomed Laser Surg. 2011; 29: 793-6.

[21] Vukoja D, Alajbeg I, Vučićević Boras V, Brailo V, Alajbeg IZ, Andabak Rogulj A. Is effect of low-level laser therapy in patients with burning mouth syndrome result of a placebo? Photomed Laser Surg. 2011;29(9):647-8; discussion 648, 651.

[22] Cowen D, Tardieu C, Schubert M, Peterson D, Resbeut M, Faucher C, Franquin JC. Low energy Helium-Neon laser in the prevention of oral mucositis in patients undergoing bone marrow transplant: results of a double blind randomized trial. Int J Radiat Oncol Biol Phys. 1997; 38(4):697-703.

[23] Campos L, Simões A, Sá PH, Eduardo Cde P. Improvement in quality of life of an oncological patient by laser phototherapy. Photomed Laser Surg. 2009;27(2):371-4.

[24] de Castro G Jr, Guindalini RS. Supportive care in head and neck oncology. Curr Opin Oncol. 2010; 22(3):221-5.

[25] de Lima AG, Villar RC, de Castro G Jr, Antequera R, Gil E, Rosalmeida MC, Federico MH, Snitcovsky IM. Oral mucositis prevention by low-level laser therapy in head-and-neck cancer patients undergoing concurrent chemoradiotherapy: a phase III randomized study.Int J Radiat Oncol Biol Phys. 2012; 82(1):270-5.

[26] Miloro M, Repasky M. Low-level laser effect on neurosensory recovery after sagittal ramus osteotomy. Oral Surg Oral Med Oral Pathol Oral Radiol Endod. 2000; 89(1): 12-8.

[27] Khullar SM, Brodin P, Barkvoll P, Haanaes HR. Preliminary study of low-level laser for treatment of long-standing sensory aberrations in the inferior alveolar nerve. J Oral Maxillofac Surg. 1996; 54(1):2-7; discussion 7-8.

[28] Ozen T, Orhan K, Gorur I, Ozturk A. Efficacy of low level laser therapy on neurosensory recovery after injury to the inferior alveolar nerve. Head&Face Medicine. 2006; 2: 3.

[29] Khadra M.The effect of low level laser irradiation on implant-tissue interaction. In vivo and in vitro studies. Swed Dent J Suppl. 2005;(172):1-63.

[30] Goulart CS, Nouer PR, Mouramartins L, Garbin IU, de Fátima Zanirato Lizarelli R. Photoradiation and orthodontic movement: experimental study with canines. Photomed Laser Surg. 2006 Apr;24(2):192-6.

[31] Sousa MV, Scanavini MA, Sannomiya EK, Velasco LG, Angelieri F. Influence of low-level laser on the speed of orthodontic movement. Photomed Laser Surg. 2011; 29(3): 191-6.

[32] Altan BA, Sokucu O, Ozkut MM, Inan S. Metrical and histological investigation of the effects of low-level laser therapy on orthodontic tooth movement. Lasers Med Sci. 2012; 27(1):131-40.

[33] Marquezan M, Bolognese AM, Araújo MT. Effects of two low-intensity laser therapy protocols on experimental tooth movement. Photomed Laser Surg. 2010;28(6):757-62.

[34] Xiaoting L, Yin T, Yangxi C. Interventions for pain during fixed orthodontic appliance therapy. A systematic review. Angle Orthod. 2010;80(5):925-32.

[35] Tortamano A, Lenzi DC, Haddad AC, Bottino MC, Dominguez GC, Vigorito JW. Low-level laser therapy for pain caused by placement of the first orthodontic archwire: a randomized clinical trial. Am J Orthod Dentofacial Orthop. 2009; 136(5):662-7.

[36] Turhani D, Scheriau M, Kapral D, Benesch T, Jonke E, Bantleon HP. Pain relief by single low-level laser irradiation in orthodontic patients undergoing fixed appliance therapy. Am J Orthod Dentofacial Orthop. 2006; 130(3):371-7.

[37] Obradović R, Kesić L, Mihailović D, Antić S, Jovanović G, Petrović A, Peševska S. A histological evaluation of a low-level laser therapy as an adjunct to periodontal therapy in patients with diabetes mellitus. Lasers Med Sci. 2012 Feb 5. [Epub ahead of print]

[38] Igić M, Kesić L, Leković V, Apostolović M, Mihailović D, Kostadinović L, Milašin J. Chronic gingivitis: the prevalence of periodontopathogens and therapy efficiency. Eur J Clin Microbiol Infect Dis. 2012 Jan 6. [Epub ahead of print]

[39] Theodoro LH, Silva SP, Pires JR, Soares GH, Pontes AE, Zuza EP, Spolidório DM, de Toledo BE, Garcia VG. Clinical and microbiological effects of photodynamic therapy associated with nonsurgical periodontal treatment. A 6-month follow-up. Lasers Med Sci. 2011 Jun 18. [Epub ahead of print]

[40] Aykol G, Baser U, Maden I, Kazak Z, Onan U, Tanrikulu-Kucuk S, Ademoglu E, Issever H, Yalcin F. The effect of low-level laser therapy as an adjunct to non-surgical periodontal treatment. J Periodontol. 2011;82(3):481-8.

[41] Lui J, Corbet EF, Jin L. Combined photodynamic and low-level laser therapies as an adjunct to nonsurgical treatment of chronic periodontitis. J Periodontal Res. 2011 Feb; 46(1):89-96.

[42] Rotundo R, Nieri M, Cairo F, Franceschi D, Mervelt J, Bonaccini D, Esposito M, Pini-Prato G. Lack of adjunctive benefit of Er:YAG laser in non-surgical periodontal treatment: a randomized split-mouth clinical trial. J Clin Periodontol. 2010;37(6):526-33.

[43] Pejčić A, Kojović D, Kesić L, Obradović R. The effects of low level laser irradiation on gingival inflammation. Photomed Laser Surg. 2010;28(1):69-74.

[44] Yilmaz HG, Kurtulmus-Yilmaz S, Cengiz E, Bayindir H, Aykac Y. Clinical evaluation of Er, Cr:YSGG and GaAlAs laser therapy for treating dentine hypersensitivity: a randomized controlled clinical trial. J Dent. 2011; 39: 249-54.

[45] Kimura Y, Wilder-Smith P, Yonaga K, Matsumoto K. Treatment of dentine hypersensitivity by lasers: a review. J Clin Periodontol. 2000;27:715–21.

[46] Corona SA, Nascimento TN, Catirse AB, Lizarelli RF, Dinelli, W, Palma-Dibb RG. Clinical evaluation of low-level laser therapy and fluoride varnish for treating cervical dentinal hypersensitivity. J Oral Rehab. 2003;30:1183–9.

[47] Sicilia A, Cuesta-Frechoso S, Suarez A, Angulo J, Pordomingo A, De Juan P. Immediate efficacy of diode laser application in the treatment of dentine hypersensitivity in periodontal maintenance patients: a randomized clinical trial. J Clin Periodontol. 2009;36:650–60.

[48] Sgolastra F, Petrucci A, Gatto R, Monaco A. The effectiveness of lasers to reduce dentinal hypersensitivity remains unclear. J Evid Base Dent Pract. 2011; 11: 178-9.

[49] Tanboga I, Eren F, Altinok B, Peker S, Ertugral F. The effect of low level laser therapy on pain during dental tooth-cavity preparation in children. Eur Arch Paediatr Dent. 2011; 12(2):93-5.

[50] Öz S, Gökçen-Röhlig B, Saruhanoglu A, Tuncer EB. Management of myofascial pain: low-level laser therapy versus occlusal splints. J Craniofac Surg. 2010;21(6):1722-8.

[51] Marini I, Gatto MR, Bonetti GA. Effects of superpulsed low-level laser therapy on temporomandibular joint pain. Clin J Pain. 2010;26(7):611-6.

[52] Fikackova H, Dostalova T, Navratil L, Klaschka J. Effectivness of low-level laser therapy in temporomandibular joint disorders: a placebo-controlled study. Photomed Laser Surg. 2007; 25(4): 297-303

Chapter 13

Application of Diode Laser in Oral and Maxillofacial Surgery

Dragana Gabrić Pandurić, Ivona Bago,
Irina Filipović Zore, Mato Sušić, Davor Katanec,
Aleksandar Milenović and Vanja Vučićević Boras

Additional information is available at the end of the chapter

http://dx.doi.org/10.5772/52404

1. Introduction

The application of light for processing materials was first described by Arristophanes in his comedy "The clouds“ 423 B.C. In the 2500 years that passed until the laser was invented, light had been used both for processing material and for medical purposes in various ways. But only the laser has paved the path for widespread therapeutic use of optical radiation [1]. In 1917, Albert Einstein put forward a theory of "stimulated emission" stating that photons could "stimulate" the emission of another photon that would possess identical properties to the first [2]. The early developments of laser research started from the USA and Soviet Union in 1958. Townes and Schawlow worked to establish the principles that led to the development of the LASER (Light Amplification by Stimulated Emission of Radiation) [3, 4]. In 1960, Theodore Maiman demonstrated the first practical laser with a ruby crystal stimulated by a flashlamp and mirrors to amplify the lasing action. The beam had a deep red colour with a wavelength of 694nm [5]. When Maiman discovered the laser effect it was very difficult for him to have this discovery published in a renowned journal because no one seemed to be aware of its significance. Since the presentation of the first laser, many more materials have been discovered that are capable of producing laser light. Due to the physical particularities of the laser effect, it was not long until the wide array of possible applications were realized. It took several decades to develop reliable, appropriately designed lasers for routine use in medicine and as well as other applications [1, 6]. To understand the applications of laser surgery, it is necessary to know the fundamental principles of laser light. Laser is a special light source because in general it has higher power and a better beam quality and coherency in comparison with the other light sources. Unlike other light sources, lasers emit

INTECH
open science | open minds

© 2013 Gabrić Pandurić et al.; licensee InTech. This is a paper distributed under the terms of the Creative Commons Attribution License (http://creativecommons.org/licenses/by/3.0), which permits unrestricted use, distribution, and reproduction in any medium, provided the original work is properly cited.

coherent, monochromatic, and collimated electromagnetic radiation, with high intensity, displaying a high optical power per unit area for a given amount of energy as compared to broadband light sources. These characteristics endow the laser with unique applications. Of course, there are specific features inherent to each type of a particular laser such as the spot size, wavelength, or radiance that is important to the specific kind of application intended [4, 7]. The most common surgical lasers emit wavelengths in the infrared (IR) part of the spectrum: the Nd:YAG (λ=1,064nm), the Er:YAG (λ=2.94μm), and the CO_2 laser (λ=10.6 and 9.6μm). Within the visible portion of the electromagnetic spectrum, argon lasers emit light between 458 and 515nm, and excimer lasers are located in the ultraviolet part of the spectrum (100 to 400nm). Diode lasers emit wavelengths of 670 to 1551nm. For surgical indications, the later seem to be of increasing interest [7]. Up until now, most of the high-power lasers operated in the near IR or far IR range and there are excimer lasers that have considerable power in the UV range. Thus, there is still a gap in the middle range of the spectrum which motivated development of laser systems for the UV/VIS region of the electromagnetic spectrum [4].

For therapeutic purposes, the laser-tissue interaction mechanisms are mainly determined by two parameters, namely the laser exposure time on the tissue and the effective power density taking into account the tissue-specific absorption [1]. Whether a particular laser source is suited for biomedical purposes, either diagnostic and/or therapeutic, depends on the indication, the aforementioned excitation and de-excitation mechanisms and the extent of laser-tissue interactions. In short, laser-tissue effects and interactions depend on the interplay of irradiation parameters such as wavelength or wavelength band of the particular laser source, physical properties of the tissue irradiated with the particular wavelength, irradiance or pulse energy, continuous wave (cw) or pulsed irradiation, laser beam size on the tissue, irradiation duration or laser pulse length, repetition rate and any changes in the physical properties of the tissue as a result of laser irradiation with the parameters mentioned above [8]. Monochromaticity and high optical power are the most important properties when considering the interaction of laser light with tissue for medical applications [9]. When laser light is delivered to the tissues, or any surface, a number of specific interactions can occur. When laser energy hits a target tissue, it may be transmitted, reflected, absorbed or scattered. If a laser beam can be transmitted through a material there will be little or no absorption and therefore little or no thermal effects. The depth of transmission into tissues depends upon the tissue type, laser wavelength and laser fluence. A laser beam that is not transmitted through a material is absorbed, and as the tissue or materials absorb the laser beam, heat energy is produced which can cause thermal damage to the tissue. In order to achieve a biologic effect, the energy must be absorbed. Selective absorption is the key to the majority of laser treatments, which "target" a particular wavelength for a particular site. By choosing a wavelength of light that is preferentially absorbed by the component of tissue, it is possible to target only the chosen structure and leave surrounding tissues relatively unaffected [6, 9]. Each tissue has specific absorption characteristics based on its composition and chromophore content. The principal chromophores present in mammalian tissue are haemoglobin, melanin, wa-

http://dx.doi.org/10.5772/52404

ter and protein. Infrared light is absorbed primarily by water, while visible and ultraviolet light are primarily absorbed by hemoglobin and melanin, respectively. As wavelength decreases toward the violet and ultraviolet part of the spectrum, scatter or absorption from covalent bonds in protein limits penetration depth in this range. In order to target a specific tissue, one should select a wavelength which is strongly absorbed by chromophores present in that tissue. Most medical laser applications depend on the absorption of laser light to heat the target tissue. To prevent undesirable thermal injury to adjacent tissue, light can be applied in suitably timed pulses related to the size of the target structure according to the principle of selective photothermolysis. The proper pulse width for targeting a structure will be in this range; larger structures will be best treated with a longer pulse, and smaller structures by shorter pulses. Too long a pulse may cause adjacent structures to sustain thermal injuries; too short a pulse may cause insufficient energy to be delivered to the tissue in order to elicit a biologic effect on the target [9]. It can be concluded that with proper selection of the wavelength, exposure time and intensity of the laser, the biologic effect on the target tissue can be optimized and undesirable collateral effects on adjacent tissues can be minimized. By selecting the appropriate wavelength and pulse width, and properly delivering the applied energy, one can achieve a selective effect on the target tissue. There are five interaction mechanisms associated with the use of lasers in biomedicine:

1. *Optical effect* i.e. fluorescence spectroscopy for cancer screening, optical coherence tomography (OCT) for high-resolution imaging
2. *Photomechanical effect* (photoacustic) ie. for laser lithotripsy, removal of tattoos and certain pigmented lesions
3. *Photochemical effect* i.e. photodynamic therapy (PDT), chemical reaction stimulation, composite resin polymerization
4. *Photothermal effect* i.e. laser resurfacing, treatment of vascular lesions, laser hair removal
5. *Photobiostimulative and photobiomodulative effect* i.e. low level laser therapy (LLLT), laser acupuncture, collagen remodeling for aged skin, anti-inflammatory treatments, blue light therapy for acne treatments, accelerated wound healing [8-12].

Whether a laser system is suitable for incisions, vaporization, or coagulation is determined by the wavelength, the energy fluence, the optical characteristics of the tissues, and how the laser is operated. In continuous mode, the laser provides a constant and stable delivery of energy. Lasers within the ultraviolet region (100 to 380nm) are able to ionize tissues, a process known as photochemical desorption. Lasers of longer wavelengths, especially those within the infrared part of the spectrum (700 to 10,000nm), cause significant tissue heating. Most of the surgical lasers are embedded in this group and comprise thermal lasers. The light of these lasers is rapidly converted to thermal energy causing denaturation of proteins, decomposition of tissue, microexplosion of cell water and charring [1, 5, 7, 13-15].

2. Laser applications in OMF surgery

More than in any other dental specialty, lasers have played an integral role in the practice of OMF surgery. Lasers and rapidly becoming the standard of care for many procedures performed by oral and maxillofacial surgeons. The reason for this transition is due to the fact that many procedures can be executed more efficiently and with less morbidity using lasers as compared to a scalpel, electrocautery or high frequency devices. Because many of these procedures are routine for the practicing surgeon, the laser is merely used as a better tool to facilitate the same goals; the transition to laser surgery by most OMF surgeons has been gradual and relatively simple. Many new procedures have been developed specifically to take advantage of the unique properties of the laser or can be done only via a laser; because there is no analogous procedure using conventional surgical instruments. On the other hand, there are procedures that although possible with other modalities, have become popular to perform using the laser because of its inherent advantages. Early lasers were bulky and historically used for major cases in operating theaters; but today, access to small, portable, office-based lasers with improved intraoral delivery systems have made it possible to treat even minor routine procedures in the clinic [13-16].

2.1. Advantages

There are many advantages to the use of lasers in OMF surgery. The advantages of laser surgery include: hemostasis and excellent field visibility, precision, enhanced infection control and elimination of bacteremia, lack of mechanical tissue trauma, reduced postoperative pain and edema, reduced scarring and tissue shrinkage, microsurgical capabilities, less instruments at the site of operation, asepsis due to non-contact tissue ablation and prevention of tumor seeding [1, 15]. The hemostatic nature of the laser is of great value in OMF surgery. It allows surgery to be performed more precisely and accurately because of increased visibility of the surgical site. This characteristic is particulary useful in cases of hemangioma or removal of inflamed epulis fissurata, or any procedure involving incision of the tongue, soft palate, or tonsillar pillars. Decreased postoperative swelling is characteristic of lasers and allows increased safety when performing surgery within the airway and increases the range of surgery that can be performed safely without fear of airway compromise. This effect allows the surgeon to perform many procedures in an office or outpatient facility that previously would have required hospitalization for airway observation, postoperative nursing care, and parenteral pain management. The improvement of tissue healing and scarring is due to a combination of decreased collateral tissue damage, less traumatic surgery, more precise control of the depth of tissue damage, and fewer myofibroblasts in laser wounds [13, 15]. When lasers are used intraorally, wounds generally heal with minimal scar formation and soft, pliable residual tissue. Because of this improved healing (along with the hemostasis), intraoral wounds can often be left unsutured (another distinct advantage). Decreased postoperative pain is often noted with the use of lasers for surgery. The physiology of this effect is still unknown but probably relates to decreased tissue trauma and an alteration of neural transmission. This aspect has enabled surgeons to perform many procedures on an outpatient basis, with patients returning to work within 1 day or even immediately in many

http://dx.doi.org/10.5772/52404

cases. Hollow wave-guide technology and fiberoptics make the laser accessible to almost any area in the oral cavity, even those that would be difficult or impossible to reach with other therapeutical modalities [15]. Despite many advantages, there are disadvantages that must be carefully weighed before choosing the laser for patient treatment. As mentioned previously, healing from laser surgery is usually excellent, with decreased scarring and increased function; however, the speed of healing is usually prolonged when compared with other types of wounds. This healing delay is undoubtedly due to the sealing of blood vessels and lymphatics. Typical intraoral healing takes 2 to 3 weeks for wounds that would normally take 7 to 10 days, and this must be taken into account when considering suture removal (when used) and obtaining informed patient consent [13-15]. None of the lasers can treat all tissue conditions (due to different wavelengths), but a variety of lasers can be useful for various conditions. Different wavelength lasers are used for various indications by taking advantage of their physical properties.

2.2. Laser types

Carbon dioxide (CO_2) lasers continue to be a major instrument for soft tissue surgery for excellent affinity to water-based tissues. The wavelength of 10,600nm is readily absorbed by water thus, it will not penetrate far into tissues (0.1-0.23mm) without repeated or prolonged use making it ideal for superficial lesions and resurfacing of the skin. It is also used for removal of the sialoliths.

Nd:YAG lasers (1064nm) are used for hair removal, in addition for removal of tattoos and pigmented lesions if q-switched. Nd:YAG and Ho:YAG (2.12μm) are frequently used in bone and cartilage ablation.

Ho:YAG lasers are used for adhesions and foreign body removal while treating joint irregularities and performing discectomy of the perforated disk.

Er:YAG lasers (2.94μm) have become the most popular lasers for treatment of hard tissues, teeth and bone. Frequency doubled Nd:YAG or KTP laser (532nm) is strongly absorbed by haemoglobin, melanin and other similar pigments being used for treatment of telangiectasia and keloid scars if q-switched.

Alexandrite lasers (720-800nm) are used for hair removal and tattoo removal, if q-switched, as are the ruby laser (694nm) and dye laser (400-1000nm).

Argon (488, 514nm) and krypton lasers (531nm) are readily absorbed by hemoglobin, melanin and other similar pigmentation and are useful in the treatment of the port-wine stains. Argon, KTP, Nd:YAG and diode lasers are used to treat oral soft and/or vascular lesions by ablation, incision, excision or coagulation. The excimer laser (UV outputs) are absorbed by proteins, and mostly used in ophthalmic surgery [6, 15-17].

2.3. Laser osteotomy

Experimental laser osteotomies were performed *in vitro* and *in vivo* with use of different wavelengths including excimer lasers, Er:YAG, CO_2 and Ho:YAG lasers. The laser light

emitted by Er:YAG and CO_2 lasers are well absorbed by water. The wavelength of the Er:YAG laser, moreover, is also well absorbed by hydroxyapatite, and of the CO_2 laser is highly absorbed by collagen. Therefore, these wavelengths seem to play an increasingly important role in OMF surgery [7]. Light microscopy, histologic sections and SEM revealed no charring, but a very thin basophilic zone next to the cut surface, while cutting the trabecular structures resulted in coagulation zone [17-22].

2.4. Benigin oral lesions

For soft tissue surgery several wavelengths including Er:YAG, CO_2, Nd:YAG and diode lasers were investigated over the past years. Excision of benign lesions, such as fibroma, papilloma, mucocele, gingival lesions, benign salivary glands lesions, salivary stones, epulis fissurata, tongue lesions and hyperplastic tissue excisions, are well documented in the literature. Removal of these lesions using lasers is minimally invasive and can make the surgery less extensive, and may reduce the need for general anesthesia or in-patient hospital care, resulting in the lowered overall costs [4, 5, 15, 23].

2.5. Premalignant lesions of the oral mucosa

According to the literature, malignant transformation of premalignancies such as oral leukoplakia and oral lichen planus occurs in up to 28% of these lesions. Surgery of these lesions is mostly performed conventionally, but using laser for the removal of the premalignancies has been proven very effective being associated with recurrence rates of less then 20%. It allows precise excision, together with some of the underlying connective tissue. The heat generated reaches the deeper-lying cells and, consequently, renders very low recurrence rates. However, a delay in healing caused by the thermal laser energy is an encumbrance for the patient. As an alternative to the scalpel, the CO_2 laser has been used for more then 25 years. In recent studies, very low recurrence rates were observed with the Nd:YAG and diode lasers when treating above mentioned lesions, probably due their deep penetration of the light through the tissue [4-7, 13-16].

2.6. Selected malignant lesions

In selected patients with oral squamous cell carcinoma, as part of overall oncological management, lasers play a role in excision of the lesion, while thermal laser energy was supposed to be of value in cancer surgery, as it was assumed that thermal laser energy may seal arteries, veins and lymphatic vessels. However, advantages of laser surgery seem to be more attributable to technical handling during surgery than to oncologic parameters [4, 5, 13].

2.7. Fluorescence spectroscopy and photodynamic therapy (PDT)

Laser-induced fluorescence (LIF) spectroscopy is a non-invasive technique that has been used in various fields to differentiate tissues, and therefore might be an important tool for cancer diagnostics. Differentiation of benign and malignant tissues using this method is possible with a sensitivity above 80%. It has been shown that PDT can optimize conventional

surgery in cases of squamous cell carcinoma using a new photosensitizer meta-tetrahydroxyphenylchlorine (m-THPC). Intraoperative fluorescence-guided resection followed by PDT seem to be highly promising in improving the radicality of tumor resection combined with a conventional therapeutic approach [7, 24].

2.8. Esthetic and plastic indications

Lasers have been used for more than 25 years in cosmetic surgery of the face. Superficial vascular and pigmented lesions are most commonly treated with use of argon laser. Nd:YAG laser is used for treatment of deep vascular lesions and tumors. CO_2 laser is indicated for vaporization of exophytic lesions. One of the more common procedures performed with laser is cosmetic skin resurfacing by removing the surface layer of the epidermis and superficial papillary dermis, conctracting the dermal collagen, and allowing the skin to reepithelialize in a more uniform manner. The advantage of the laser surgery in cases of esthetic and plastic surgery is based on hemostasis, decreased scarring and decreased postoperative disability [13, 15, 24].

2.9. Surgical indications in children

In cranio-maxillofacial surgery, laser therapy is indicated in the treatment of congenital vascular malformations, such as hemangiomas or naevi flammei which are treated by argon, Nd:YAG or dye lasers. Moreover, use of the CO_2 laser was shown to be effective in cleft surgery of infants [13, 24].

2.10. Temporomandibular joint laser-assisted surgery

Arthroscopic surgery has become the treatment of choice for internal derangements of the temporomandibular joint using Er:YAG, CO_2 and Ho:YAG lasers. Using this technique procedures such as discectomy, discoplasty, synovectomy, hemostasis, posterior attachment contraction, and eminectomy can be performed on an outpatient basis through two incisions less than 2mm each [13, 15].

2.11. Dental implantology

The clinical use of lasers in modern oral implantology may be indicated in the different phases of the treatment. Lasers may be useful in pre-implant treatments when mucogingival surgery is required [24]. The most important indication of laser treatment in implantology is application in the peri-implant soft tissues, as well as decontamination of the implant surfaces in order to treat peri-implant bony defects and rehabilitate failing implants [7, 24-29]. However, apparently not all laser systems available in dentistry are of value in this regard. Nd:YAG laser can dramatically change the implant surfaces and cause melting of the implant microdesign. Better results were seen with the use of a CO_2 laser, which is not able to modify the implant surface, the temperature changes are clinically acceptable and the bacteria reduction is significant. Moreover, of potential interest is the clinical use of the diode laser, which is not able to change the implant surface and has excellent properties for incision,

excision and coagulation of the soft tissues. Recently, PDT with toluidine blue plus diode laser light was used for treatment of peri-implant diseases [24-31]. There are several confirming reports in the literature in which lasers have been used for implant site preparation [32-35]. Lasers are useful tool in the second phase of implant surgery [25, 36]. Laser irradiation has a biostimulating effect on osteoblasts, which may be used for promoting the osseointegration process of dental implants and healing of the bone defect after augmentation procedures [37-39].

2.12. Laser hemostasis

In modern societies, there is an increasing number of older patients, especially who take anticoagulant drugs. Over the past years, lasers haemostatic properties have been established. Due to deeper penetration in soft tissues, Nd:YAG and diode laser have been very effective. To reduce the thermal effect, pulsed lasers are used. Optical characteristics of blood result in scaterring and dispersion of laser light, thereby reducing the adverse effects on bony tissue [7, 31]. There are basically three photothermal techniques for laser use within the oral cavity and on the face: incisional and excisional procedures, ablation and vaporization procedures, and hemostasis. Incisional and excisional procedures are common in cases of soft tissue laser surgery using the laser device essentially as a light scalpel to make relatively deep, thin cuts such as one would do with a scalpel blade. This technique allows the surgeon to perform almost any intraoral procedure that would normally be done with conventional technique, such as incisional and excisional biopsy, lesion removal, or incision for flap access. The main advantages are bloodless surgical field and the reduced need for suturing. Tissue ablation or vaporization is used for removal of the superficial part of the tissue but generally over a fairly large area, as well as for the bone removal. The most common examples are leukoplakias, dysplasias, papillary hyperplasia, and osteotomies. In contrast to incisional procedures in which is spot size is kept small by locating the laser at its focal length; vaporization is accomplished by using larger spot sizes. This technique allows removal of a surface lesion in layers of a few hundred microns to 1-2mm at a time. Visualization of tissue anatomy is excellent, owing to the hemostasis, and the layers are identified easiliy. By removing only the epithelium less damage is done to the underlying tissues, and the risk of inadvertent damage to an underlying nerve, duct, or blood vessel is minimal. Any superficial tissue removal without the need for histologic examination can be treated using this technique. Finally, even in cases in which other modalities of treatment have been used, the laser can be used as a hemostatic tool to stop bleeding in the field and to allow for similar postoperative wound management. The cause of this effect is not coagulation of blood, but rather the contraction of the vascular wall collagen. The contraction results in constriction of the vessels and hemostasis. The technique is very useful for removal of vascular lesions in the oral and maxillofacial region [13-15]. Once these three techniques are understood, the surgeon has to decide which technique would be best for treatment of the lesion most appropriately, taking into account the laser parameters, such as power, time, and spot size to best affect the target with the least collateral damage.

http://dx.doi.org/10.5772/52404

3. Application of diode laser for soft tissue surgery

Diode lasers have a diversity of applications in the medical field. Small and compact, they can be "stacked" to produce considerable output powers. The active material is a semi-conducting crystal, usually gallium arsenide (GaAs) or similar compounds. The precise wavelength depends upon the material used in the semiconductor layers. The beam from the diode laser is usually more divergent than that of the other lasers, requiring additional optics to produce a collimated output beam. Beams can be in continuous wave or pulsed. The advantage of diode systems is their compactness, high efficiency and reliability. Some lasers devices use low power visible diode lasers instead of helium-neon (HeNe) lasers for aiming beams [6]. The diode laser is good for excising benign soft tissue lesions. Blood vessels smaller than 0.5mm in diameter are sealed spontaneously, allowing excellent visibility and precision when dissecting through the tissue planes. There is minimal cellular damage adjacent to the plane of excision. This facilitates good wound healing, and it also means that the specimen can be removed without distorsion, enabling the pathologist to provide an accurate histological diagnosis. Even large laser wounds heal with good functional results and minimal scar [15, 40]. Because of the many uncontrollable factors that determine the depth of effect of the laser into any particular tissue and the three clinician-controlled parameters (power, time and spot size), it is impossible to generalize specific laser parameters for any individual lesion. It is more important to consider each use as a unique circumstance and to adjust the parameters to provide the best results on the target, in the most controllable manner, with the least lateral thermal damage. Using typical spot sizes of 0.1 to 0.5mm, a power of 4 to 10W, is usually a good level to initiate treatment for most intraoral lesions [15]. Where the target tissue can tolerate a wider zone of coagulation necrosis, such as incisions in oral mucosa, a continuous wave may be used. At higher power densities the surgeon will have to work rapidly to minimize unwanted thermal damage. Charring will inevitably occur in inverse relationship to incisional speed [13]. Laser excision is most desirable for any solid, exophytic-type lesion because of the improved visibility and precise control of tissue removal. The laser surgery technique is lesion independent, but any lesion or tissue requiring excision and incision treated use the same basic method. It is important for the surgeon to choose when to use this technique appropriately. Once the appropriate depth has been reached, excision can be performed by grasping the tissue with the forceps, applying slight traction, and horizontally undermining the tissue in the same fashion with the laser still in focused mode [15]. Traction and countertraction of tissue with sponges, forceps, or sutures will facilitate precise surgery just as it does for conventional techniques. The target tissue should be examined to see if the desired depth is reached. As with a scalpel, several passes may be necessary to achieve this [13]. The pathologist should be informed of the use of the laser for the surgery. Wounds produced by the diode laser behave in a different manner than those produced by the scalpel. Closure of incisions and excisions performed with the laser is often at the discretion of the surgeon. Because bleeding and scarring usually are minimized, and postoperative pain does not seem to be related to closure, sutures are absolutely required only for cosmetics, when leaving the wound to granulate slowly would present an unacceptable cosmetic situation [15]. There is minimal damage to adjacent tissue and a coagulum of denatured protein forms on the surface. No dressing is required, and the

lasered area can be left exsposed in the mouth. Skin grafting is not necessary, even for large areas. The acute inflammatory reaction is delayed and minimal; few myofibroblasts are present, and there is little wound contraction. Only small amounts of collagen are laid down, resulting in little scarring or restriction in movement of the soft tissues. However, epithelial regeneration is delayed, and the wounds take a longer time to re-epithelialize [13, 40]. The diode laser offers a minimally invasive technique and can make the surgery less extensive, reduce the need for general anesthesia or hospital stay and lower the overall costs. For these reasons, it is becoming more widely popular [13, 15, 40].

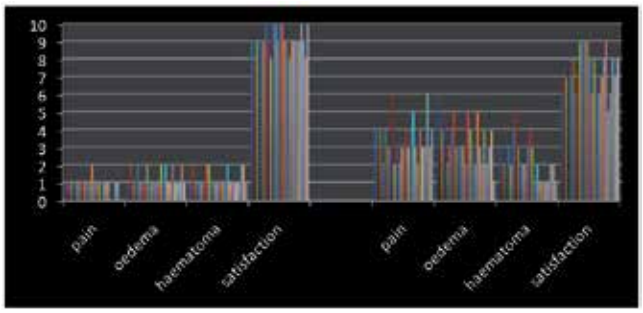

Figure 1. Comparative postoperative differences between diode laser (left) and conventional oral soft tissue surgery (right).

At the Department of Oral Surgery, School of Dental Medicine, University of Zagreb, a clinical study was performed. The aim was to compare diode laser and conventional scalpel surgery for the treatment of oral soft tissue lesions with regard to edema, hematoma, postoperative pain and patient satisfaction. The study group consisted of 7 men and 18 women, (age range 12-80, mean 44.9 ±20.8). The control group consisted of 13 men and 12 women, (age range 15-67, mean 42.4 ± 17.8). Local anesthetic (Ubistesin™, 3M ESPE, Espe Plazt, D-82229 Seefeld, Germany) was administered to all patients before the procedure. Soft tissue lesions in the control group were treated with conventional scalpel excision and silk sutures (0,3 mm, Mersillk 3.0, Ethicon, New Jersey, USA), while in the study group a diode laser (LaserHF, Hager&Werken, Duisburg, Germany, 2008.), without sutures or intraoral bandage was used. For the laser group, fibroma removal programme was used (wavelength of 975nm, power of 5W, CW). None of the soft tissue lesions, either in the study or control group, were larger than 1 cm in diameter before treatment. Three days after the surgical procedure edema, hematoma, postoperative pain and patient satisfaction were assessed by a single examiner and the patient himself. Edema was assessed as the presence of swollen tissue around incision lines and was measured in millimetres. Hematoma was defined as the presence of blood extravasation around the incision line and was measured in millimetres as well; both measurements were performed with a digital calliper. Postoperative pain was assessed via visual analogue scale (VAS, 0 – no pain at all; 10 worst possible pain). Patient satisfaction with the procedure

http://dx.doi.org/10.5772/52404

was also assessed on VAS (0 – dissatisfied; 10 - fully satisfied). Statistical analysis was performed with $\chi 2$ test and t-test for independent samples. P-values lower than 0.05 were considered as significant. No significant differences regarding age, gender of the participants and diagnosis were observed between the groups. Results are shown in Figure 1. Patients in the study group had significantly less edema and hematoma compared to the patients in the control group ($P<0.05$). Patients in the study group reported significantly less pain and higher satisfaction compared to the patients in the control group ($P<0.05$).

D'Arcangelo et al [41] reported that diode lasers tend to produce more changes with regard to the degree of inflammatory response and delay in tissue organization than a scalpel but only at the initial stage. Long-term results of the diode laser on the tissue histology are not known. Histological analysis on rats performed by D'Arcangelo et al showed that healing after laser surgery is not compromised; although rather slower it is satisfactory when higher output power (6W) is used. Therefore, the same authors concluded that lasers at lower output (4W) reduce the effectiveness of the incision, but minimize thermal damage of the tissues. The same authors concluded that use of diode lasers should be further investigated as they are good alternatives to the scalpel. Bryant et al [42] evaluated wound healing of oral soft tissues after diode laser irradiation and concluded that their clinical application in oral surgical procedures has beneficial effects. The absence of bleeding significantly reduces postoperative swelling and discomfort and obviates the need for sutures. There are only two studies in humans so far in the published literature which compare healing effects after carbon dioxide laser surgery and scalpel surgery [43, 44]. Jin et al [46] reported that the diode laser is a good cutting device for oral mucosa; however, more tissue damage occurs than with the use of a scalpel or an Er,Cr:YSGG laser producing more pronounced tissue change. Such changes are associated with an increased inflammatory response and an initial delay in healing. Romanos and Nentwig [47] reported that the diode laser (980 nm) was beneficial in 22 patients when treating soft tissue tumors, gingival hyperplasia, frenectomy, removal of hemangioma, vestibuloplasty and peri-implant tissue surgery. The same authors concluded that the diode laser has postoperative advantages, i.e. lack of swelling, bleeding, pain, scar formation and good wound healing. However, their results were not compared to the other surgical procedures. Furthermore, Stübinger et al [48] investigated usefulness of the diode laser in 40 patients. The same authors concluded that postoperative clinical findings were excellent due to the sufficient cutting abilities, good coagulation effect and extremely small zone of thermal necrosis to the nearby tissues. Based on the results of our study and other studies, we can conclude that diode lasers provide better outcomes for the treatment of oral soft tissue lesions when compared to the scalpel surgery; therefore laser can be employed in oral surgical procedures for coagulation effects, sterilization of the surgical site, minimizing or obviating swelling and significantly reducing postoperative pain.

3.1. Fibromas

Fibromas are often due to lip biting. The soft tissue surgery can be performed using Laser HF using the fibroma removal mode (975nm, 5W, CW) without side effects or complications after surgery (Figures. 2-6).

Figure 2. Clinical appearance of a lower lip fibroma.

Figure 3. Use of Laser HF for soft tissue surgery.

Figure 4. Postsurgical view.

Figure 5. Follow up three days after surgery.

http://dx.doi.org/10.5772/52404

Figure 6. Follow up two weeks after surgery.

3.2. Mucoceles

Mucoceles of the lip can be unroofed, then excised with gland tissue using Laser HF, again using fibroma removal mode (975nm, 5W, CW). The wound margins may be sealed with a defocused beam without side effects or complications. Re-epithelization takes about three weeks (Figures 7-11).

Figure 7. Clinical appearance of the mucocele.

Figure 8. Unroofed lesion after first laser use.

Figure 9. Excision of the lesion together with adjacent salivary gland using diode laser.

Figure 10. Final postoperative view.

Figure 11. Sealing the wound margins with a defocused beam.

3.3. Palatal lesions

Lesions of the soft palate such as traumatic fibromas in the soft palate can be treated using Laser HF, fibroma removal mode (975nm, 5W, CW). Application of LLLT immediately after surgery may expedite healing (Acupuncture mode, 660nm, 90mW, 90s interval) without side effects or complications (Figures 12-17).

http://dx.doi.org/10.5772/52404

Figure 12. Clinical appearance of the fibroma of the soft palate.

Figure 13. Usage of diode laser for soft tissue surgical procedure.

Figure 14. Application of LLLT immediately after surgery.

Figure 15. Follow up three days after surgery.

Figure 16. Follow up ten days after surgery.

Figure 17. Follow up three weeks after surgery.

Fibroepithelial polyps of the hard palate may be treated via Laser HF (Fibroma removal mode, 975nm, 5W, CW). Application of LLLT immediately after surgery may be performed (Acupuncture mode, 660nm, 90mW, 90s interval) without complications (Figures 18-22).

http://dx.doi.org/10.5772/52404

Figure 18. Clinical appearance of the palatal fibroepithelial polyp.

Figure 19. a. Surgical procedure performed using diode laser. b. Surgical specimen removed using diode laser.

Figure 20. Follow up three days after surgery.

Figure 21. Follow up seven days after surgery.

Figure 22. Follow up two weeks after surgery.

3.4. Epulis fissuratum

Epulis fissuratum of the jaws can be removed using Laser HF, via a combination of Fibroma removal (975nm, 5W, CW) and Gingivectomy modes (975nm, 3W, 10ms, 1:2), followed by LLLT application immediately after the surgical procedure (Acupuncture mode, 660nm, 90mW, 90s interval). The aPDT may also be performed (660nm, 50mW, 30s interval) without complications (Figures 23-30).

Figure 23. Clinical appearance of a maxillary epulis fissuratum.

Figure 24. Surgical procedure performed using diode laser.

http://dx.doi.org/10.5772/52404

Figure 25. Immediate postsurgical view.

Figure 26. Follow up three days after surgery.

Figure 27. Application of the ''photosensitizer'', a coloring solution for aPDT, and photodynamic therapy using diode laser. b. Application of the diode laser.

Figure 28. Follow up one week after surgery.

Figure 29. Follow up two weeks after surgery.

Figure 30. Follow up five weeks after surgery.

Palatal fibroepithelial polyp and inflammatory papillary hyperplasia of the hard palate can be treated similarly using Laser HF using (Fibroma removal mode, 975nm, 5W, CW) in combination with loop of high frequency. LLLT application (Acupuncture mode, 660nm, 90mW, 90s interval) immediately after surgery (Figures 31-35).

Figure 31. a. Clinical appearance of the palatal fibroepithelial polyp and inflammatory papillary hyperplasia of the hard palate. b. Clinical appearance of the palatal fibroepithelial polyp and inflammatory papillary hyperplasia of the hard palate.

http://dx.doi.org/10.5772/52404

Figure 32. Immediate postsurgical view.

Figure 33. Follow up third day after surgery.

Figure 34. Follow up one week after surgery.

Figure 35. Follow up three weeks after surgery.

3.5. Exposure of impacted teeth

Exposure of an impacted tooth (soft tissue impaction) can be done using Laser HF, (Gingivectomy mode, 975nm, 3W, CW). After laser incision around the impacted crown, the mucosal tissue is removed with an elevator until the underlying crown is identified (Figures 36-39).

Figure 36. Clinical view before surgery.

Figure 37. Incision using diode laser.

Figure 38. Removal of the mucosal flap with an elevator.

http://dx.doi.org/10.5772/52404

Figure 39. Immediate application of the orthodontic element.

3.6. Crown lengthening

Crown lengthening is easily done using lasers. After raising the mucoperiosteal flap, selective osteotomy with the surgical bur is performed. Subsequent to the suturing and frenectomy, laser gingivectomy using LaserHF (Gingivectomy mode, 975nm, 3W, 10ms, 1:2) for the lengthening of clinical crowns is done and prepared for the immediate resin restoration, prior to final ceramic restoration (Figures 40-43).

Figure 40. a. Clinical appearance before surgery b. Clinical appearance before surgery.

Figure 41. a. Treatment planning before surgery. b. Radiograph before surgery.

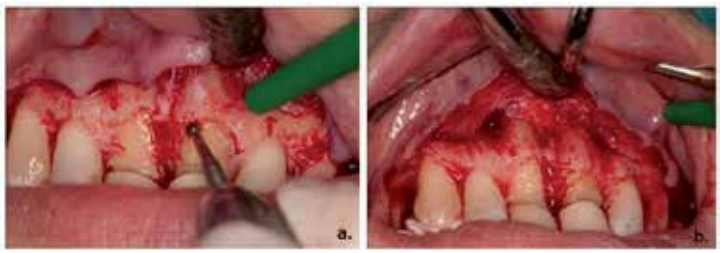

Figure 42. a. Selective osteotomy after raising the mucoperiosteal flap. b. Selective osteotomy completed.

Figure 43. a. Subsequent to the suturing and frenectomy, gingivectomy using diode laser was performed.b. Frenectomy, gingivectomy completed.

3.7. Dental implantology

Modification of the surgical laser technique can make it useful in dental implantology. The incisional mode of the diode laser can be used safely to uncover implants as long as care is taken to prevent heat conduction from surrounding tissues does not conduct back into the implant; this is done simply by limiting prolonged exposure. When using the proper wavelength, titanium does not absorb, but rather reflects the laser energy. Hydroxyapatite-coated implants might absorb this wavelength and are at risk. Another excellent use of the laser is for removal of any hyperplastic peri-implant tissue. This removal is accomplished easily by maintaining the tip of the laser parallel to the long axis of the implant, and running the laser arround the implant body. Using standard laser parameters, the tissue can be lowered uniformly to a level that allows good hygiene of the implant along with a bloodless working field [7, 15, 16, 24, 31]. The most important indication of laser treatment in implantology is application in the peri-implant soft tissues, as well as decontamination of the implant surfaces in order to treat peri-implant bony defects (open and close technique) and rehabilitate failing implants [7, 24-29]. This effect is significantly greater in combination with antimicrobial photodynamic therapy. For implant exposure in 2-stage implants, exposure of the osseointegrated dental implant in the second surgical phase can be done using Laser HF (Implant exposure mode, 975nm, 4W, CW) and healing abutment may be placed (Figures 44 a,b).

http://dx.doi.org/10.5772/52404

Figure 44. a. Dental implant exposure using diode laser. b. Healing abutment in place.

Re-exposure of osseointegrated dental implants may be performed using Laser HF (Implant exposure mode, 975nm, 4W, CW) following peri-implant mucositis and a healing abutment can be placed again; aPDT using Laser HF (PDT mode, 660nm, 50mW, 30s interval), in combination with antibiotic therapy for 5 postoperative days can be prescribed (Figures 45,46).

Figure 45. a. Peri implant mucositis. b. Reexposure of the dental implant using diode laser. c. Reexposure of the dental implant using diode laser.

Figure 46. aPDT and healing abutment placement.

Peri-implantitis treatment may also be done via a closed technique when identified radiographically just before second surgical phase of exposure. The aPDT using Helbo (Bredent, Senden, Germany, 2010) with 3DPerioprobe (650nm, 100mW, 60mW/cm^2), in combination with antibiotic therapy, during 10 days may be used (Figures 47-49).

Figure 47. a. Application of the photosensitizer (Helbo Endo Blue) through the periodontal area, without surgical opening. b. Application of the photosensitizer (Helbo Endo Blue) through the periodontal area, without surgical opening.

Figure 48. aPDT using diode laser with 3DPerioprobe.

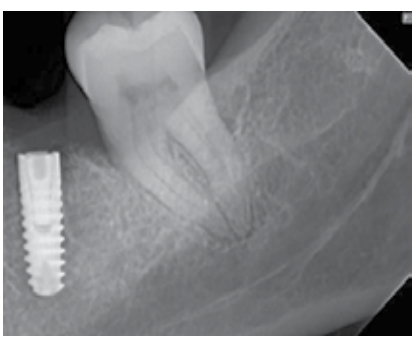

Figure 49. Control/follow-up RVG image 6 weeks after finishing the treatments and before implant exposure.

http://dx.doi.org/10.5772/52404

Advanced peri-implantitis identified on CBCT scan may also be treated. After raising the mucoperiosteal flap, periodontal treatment around implant using LaserHF (Perio-curretage mode, 975nm, 2W, 20ms, 1:4) can be used. The aPDT using the same device (PDT mode, 660nm, 50mW, 30s interval) was performed immediately before augmentation procedure and suturing (Figures 50-53).

Figure 50. a. Coronal CBCT scan. b. Axial CBCT scan.

Figure 51. After diode laser periodontal treatment, aPDT using the same device.

Figure 52. a. Augmentation using bone substitute material and collagen resorbable membrane. b. Augmentation completed.

Figure 53. Follow-up OPG 12 months after peri-implantitis treatment, without any clinical symptoms.

3.8. Therapeutic uses

Diode or therapeutic lasers, also called biostimulators have an anti-inflammatory activity, being highly efficient in the rapid healing of wounds as well as the reduction of acute and chronic pain based on the photobiostimulating activity. Anti-inflammatory laser activity is based on the reduction of prostaglandin concentration (PGE2), changing the direction of arachidonic acid. It has been proven that in acute inflammatory conditions laser lowers the activity of tumor necrosis factors (TNFs). The changes in activity of neurotransmitters especially serotonin, beta-endorphin and acetylcholinesterase result in its analgesic mechanism. Diode lasers cause the transient varices along the neuron, resulting in the disturbance of transmission signals as well as the inhibition of complex reaction creating the action potential [12-15, 37-39, 48-50].

LLLT (Low Level Laser Therapy) is the application of red and near infra-red light over injuries or lesions to improve wound and soft tissue healing, reduce inflammation and give relief for both acute and chronic pain. LLLT is used to increase the speed, quality and tensile strength of tissue repair to resolve inflammation and relieve pain. The effects of LLLT are photochemical (like photosynthesis in plants). When the correct intensity and treatment times are used, the red and near infrared light reduces oxidative stress and increases adenosine triphosphate (ATP). This improves cell metabolism and reduces inflammation. Low level laser therapy effects are biochemical and not thermal and cannot cause heating and therefore do not damage living tissue. Four distinct effects are known to occur when using low level laser therapy:

- growth factor response within cells and tissue as a result of increased ATP and protein synthesis; improved cell proliferation; change in cell membrane permeability to calcium up-take
- pain relief as a result of increased endorphin release; increased serotonin; suppression of nociceptor action
- strengthening the immune system response via increasing levels of lymphocyte activity and through a newly researched mechanism termed photomodulation of blood

- acupuncture point stimulation [13, 48-50].

Antimicrobial photodynamic therapy (aPDT) is a non-thermal light-induced inactivation of cells, microorganisms or molecules. "Antimicrobial" photodynamic therapy targets pathogenic microorganisms. Using a dye, the bacteria that cause infections are stained, sensitized and destroyed following exposure with light of a suitable wavelength and energy density. A ''photosensitizer", a coloring solution (Toluidine Blue, Methylene Blue etc.) is used. The oxygen atoms in the color molecules are activated by irradiation of appropriate light. They initiate singulet conditions, which have a toxic effect on the cells [7, 13, 51].

Third molar surgery. At the Department of Oral Surgery, School of Dental Medicine, University of Zagreb, a clinical study was performed. The aim of the study was to evaluate the impact of diode laser on the healing of wounds, pain symptoms and other postoperative symptoms which usually accompany the third molar surgery. The research included 150 participants, 61% of them were females and 39% of them were males. All the participants had absolute indication for the surgical removal of the lower third molar. The participants were randomly selected into three groups: the first group "P1" consisted of 50 patients that received the antimicrobial photodynamic therapy (aPDT); the second group "P2" consisted of 50 patients that received LLLT therapy (acupuncture mode). The remaining 50 patients were controls. In the photodynamic group ''P1" (n=50) just before the surgical suturing of the wound, a photosensitive substance (toluidine blue) was applied. After 60 seconds Paro-PDT solution was thoroughly washed with saline, and laser light was applied in two intervals (30 seconds each). The radiation power was 50 mW while the wavelength was 660 nm. Laser therapy in "acupunctured second group P2" was performed before surgical suturing of the wound without the application of Paro-PDT substance. After three intervals (90 seconds each), radiation power 90 mW, wavelength the same as in the first group 660 nm, all patients received identical postoperative instructions. Postoperative follow-ups were scheduled on third and seventh day after the laser therapy for patients in groups "P1" and "P2." On those days the treatment was repeated following the same protocol as on the day of surgery, and evaluation of the healing process and postoperative complications with two questionnaires, as wells as quality of life and patient's satisfaction (OHIP-CRO14) was performed. Fourteen days after surgery all patients were contacted by e-mail or telephone considering certain problems if problems occurred, and their satisfaction with the results of the surgery was noted. Average score of pain, swelling, halitosis, difficulties in feeding, sleeping and speech was exponentially lower within 14 days after postoperative monitoring in all 3 groups of patients (P1, P2 and K). The greatest drop of the average score, and the lowest intensity and number of postoperative problems was found in the group of patients treated with aPDT. This result can be explained with the positive influence of laser therapy, but also with the additional antimicrobial effect within hardly reachable places of toluidine chloride solution which was used in "P1" group of patients. Patients in laser acupuncture therapy group (LLLT) (P2), on the first and third postoperative day, did not show lower intensity of postoperative problems considering the control (K) group. On the seventh and fourteenth day, the intensity of problems was lower and equalized with the intensity of postoperative problems of the P1 group, which were better results considering the results of

the control group on the days mentioned. Results can be explained with the cumulative effect of laser therapy, while every new postoperative received dose of laser radiation stays and cumulates in the tissue. Every new dose of laser therapy had stronger effect on tissue that the one received before. The best indicators of positive effects with laser therapy on all of the postoperative problems can also be seen considering the difference with patient's work days lost between the groups. Results are shown on Figures 54-56, and Tables 1 and 2.

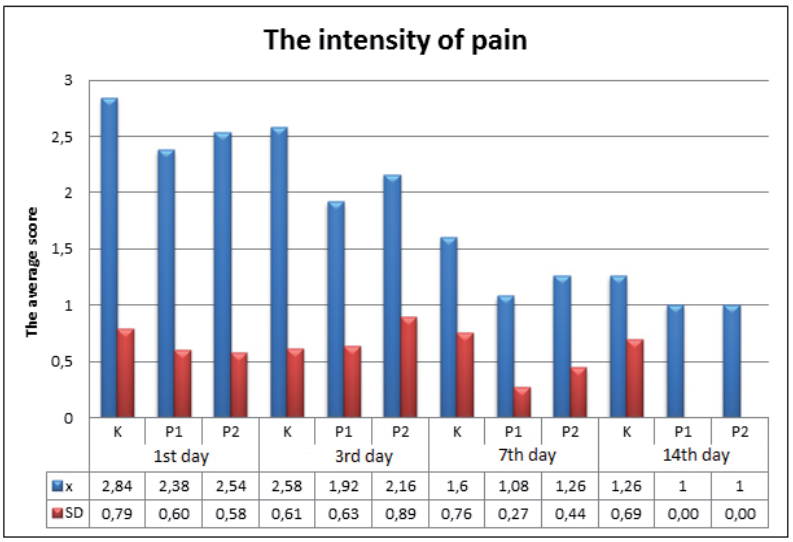

Figure 54. Distribution of pain intensity between groups.

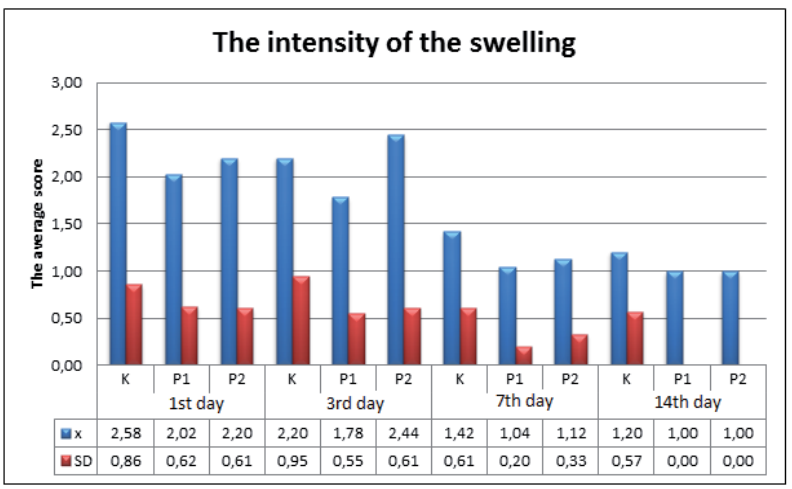

Figure 55. Distribution of swelling intensity between groups.

http://dx.doi.org/10.5772/52404

Variable	F	Df	P		Investigated groups of participants		
					P1	P2	K
Eating 1st postoperative day	3,46	149	0,034*	P1		NS	
				P2			
				K			
					P1	P2	K
Eating 3rd postoperative day	6,79	149	0,002**	P1		0,003**	0,022*
				P2		0,003**	NS
				K	0,022*	NS	
					P1	P2	K
Eating 7th postoperative day	17,90	149	<0,001**	P1		NS	<0,001**
				P2	NS		<0,001**
				K	<0,001**	<0,001**	
					P1	P2	K
Eating 14th postoperative day	5,16	149	0,007**	P1		NS	0,023*
				P2	NS		0,023*
				K	0,023*	0,023*	

Table 1. *=significant with 95% confidence; **= significant with 99% confidence; NS=non significantThe significance of differences in postoperative quality in eating.

Variable	F	Df	p		Investigated groups of participants		
					P1	P2	K
Halitosis 1st postoperative day	4,22	149	0,016*	P1		NS	0,02*
				P2	NS		NS
				K	0,02*	NS	
					P1	P2	K
Halitosis 3rd postoperative day	7,23	149	0,001**	P1		0,004**	0,008**
				P2	0,004**		NS
				K	0,008**	NS	
					P1	P2	K
Halitosis 7th postoperative day	17,37	149	<0,001**	P1		NS	<0,001**
				P2	NS		<0,001**
				K	<0,001**	<0,001**	
					P1	P2	K
Halitosis 14th postoperative day	8,02	149	<0,001**	P1		NS	0,002**
				P2	NS		0,005**
				K	0,002**	0,005**	

Table 2. *=significant with 95% confidence; **= significant with 99% confidence; NS=non significantThe significance of differences in the intensity of postoperative halitosis.

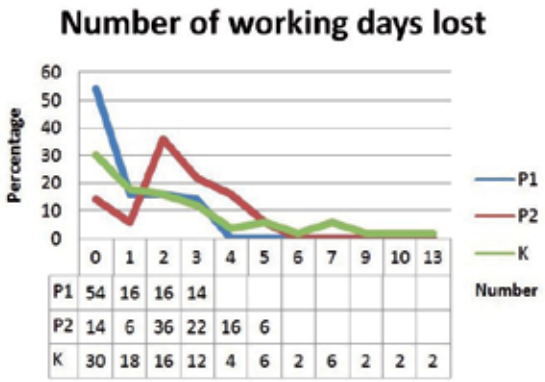

Figure 56. Distribution of the number of working days lost in groups.

Based on these results, it was concluded that:

- aPDT group (P1) had the lowest postoperative problems of all three groups.
- No complications in patients from groups P1 and P2 were found.
- Laser therapy significantly reduces postoperative problems after third molar surgery.
- Postoperative application of laser therapy reduces patient's use of analgesics.
- Laser therapy application prevents fever, and postoperative inflammation.
- Laser therapy improves patient's postoperative quality of life, reduces the number of lost working days.

3.9. Endodontic surgery

Among the various lasers appearing in the mid 1990s, diode lasers represent an attractive and valuable system due to many advantages including small size, possibility of various treatment applications, low power consumption and attractive price which makes them accessible to a wide range of dental professionals. Diode lasers have been used in soft tissue surgery, periodontal pocket therapy and peri-implantitis. Effective application is demonstrated also in endodontics, for root canal decontamination, and tooth whitening. The sterilization effect of the diode laser resembles that of Nd:YAG laser because their wavelengths are not absorbed by hard dental tissues so they do not have ablative effect on dentinal surface, and the risk of adverse effects is greatly diminished. In addition, this laser system has the bactericidal effect deep in the dentin. The 810 nm diode laser is able to penetrate the dentinal walls up to 750 μm. It has been demonstrated as being highly effective in decontamination of the root canals when used as a final disinfection protocol after chemomechanical preparation [52, 53]. De Souza et al [53] reported increased disinfection of the deep radicular dentin after irradiation with the 830 nm diode laser set at 3W for 5 s, repeated 4 times at intervals of 10 s. Gutknecht et al [54] have found 99.91% reduction in the bacteria number after irradiating teeth, which were previously incubated with *E. faecalis* suspension. Moritz

et al. [55] compared the antimicrobial efficacy of a diode laser (2W, 20ms pulse duration, 50 Hz) and conventional root canal disinfection methods in an *in vivo* study. He found higher reduction of streptococci and staphylococci in the laser group after each appointment during the endodontic therapy. Contrary results were reported in a clinical study of Gutknecht et al. [56], where no difference between the diode laser and 5% hypochlorite, when used for the root canal disinfection, was found. When using laser therapy, a major concern is the thermal effect of the laser energy on periodontal and alveolar bone tissues. The high energies that are delivered by medical lasers can lead to irreversible thermal damage to the surrounding structures. A study indicated that bone tissue was sensitive to heat at the level of 47°C, which represented an approximate 10°C increase in temperature for 1min [57]. Moritz et al [58] demonstrated that as long as correct parameters were used there was no need for concern. After measuring the canal depth, the optic fiber should be inserted in the root canal to 1 mm from the apex. As the fiber emits light from its distal end only, it should be withdrawn in slow spiral-forming movements from the apical to the coronal part in order to irradiate the dentinal walls completely, and to avoid excessive temperature rise on the tooth surface. It is very important to keep the fiber in constant motion during the root canal irradiation because if the fiber is kept stationary in the root canal, temperature rises.

Apart from decontamination efficacy, laser therapy has shown great promise in the removal of the smear layer and debris that remains on the root canal walls after mechanical instrumentation. Removal of the smear layer facilitates the antibacterial effect of intracanal irrigants and medicaments, and deeper penetration and adaptation of a filling material to the canal walls. Several studies have shown that the diode laser has similar effects on the dentinal walls like Nd:YAG laser, closing the opening of the tubules [58, 59].

Diode lasers energy has also been recommended to activate chemical irrigants such as 17% EDTA and sodium hypochlorite in LAI technique. Hmud et al. [60] used the 940 and 980 nm diode lasers with output power of 0.5-7W at 1-10Hz to activate water. They concluded that laser energy, delivered in the fluid, created cavitations, which could have potential to enhance the removal of debris and smear layer. Diode lasers with lower wavelengths and output powers of several milliwatts can be used to activate various photosensitizers, which in turns exert a lethal effect on bacteria [61]. There are several terms for this photochemical interaction: photo activated disinfection (PAD), photodynamic disinfection (PDD) or antimicrobial photodynamic therapy (aPDT).

Antimicrobial photodynamic therapy is based on the concept that a nontoxic photosensitizer, which bears a positive charge can directly target both gram-positive and gram-negative bacteria. After exposure to the light of an appropriate wavelength, the photosensitizer is activated, resulting in energy or electron transfer to available molecular oxygen with consequent formation of highly reactive oxygen such as singlet oxygen and free radicals. This process produces a cascade of oxidative events that cause damage to intracellular proteins, membrane lipids, and nucleic acids. In recent years, photodynamic therapy has been evaluated in root canals in many *in vitro* [62, 63] and *in vivo* studies [64, 65]. These studies suggested the potential of photodynamic therapy as an adjunct to conventional chemomechanical root canal preparation [66, 67]. Recent *in vivo* study of Silva et al [68] evaluated the

response of the apical and periapical tissues of dogs' teeth with apical periodontitis after one-session endodontic treatment with and without aPDT. They found moderate neoangiogenesis, fibrogenesis without signs of inflammation in the periapical region after aPDT, and concluded that aPDT could be a promising adjunct therapy to the one-session conventional chemomechanical root canal treatment. Garces et al. [65] conducted a randomized clinical study to find the benefits of aPDT used as an adjunct to conventional root canal treatment in patients with necrotic pulp harboring microflora resistant to previous antibiotic therapy. Their results showed that this combination of endodontic therapy and aPDT eradicated all 9 multi-drug resistant bacterial species in root canals.

Bago et al [69] compared in a recent *ex vivo* study performed at the Department of Endodontics and Restorative Dentistry and the Department of Oral Surgery, School of Dental Medicine, University of Zagreb, the antimicrobial action of a 975 nm diode laser (2W, t-on 5ms, t-off 25 ms, irradiation time: 20 s repeated for 3 times), aPDT, conventional and sonic activated irrigation, using EndoActivator system (Dentsply Maillefer) during root canal treatment against *E. faecalis* biofilm. The PDT was performed with 660 nm diode laser (Laser HF, Hager Werken, Duisburg, Germany), which uses toluidine blue, and with the Helbo laser (Grieskirchen, Austria), which uses phenothizine chloride. Power of both lasers was set at 100 mW and root canals were irradiated for 60 s. The results clearly showed the superiority of the PAD and the sonic activated irrigation, which achieved 99.99% reduction rate. Only these techniques succeeded in the eradication of *E. faecalis* from the root canals of 6 samples. Regarding the high-power diode laser, the results demonstrated greater difficulties in eliminating *E. faecalis*. Survival of *E.faecalis* and lower reduction rate can be attributed to the high resistance of *E. faecalis* to heat, due to its cell-wall structure [70].

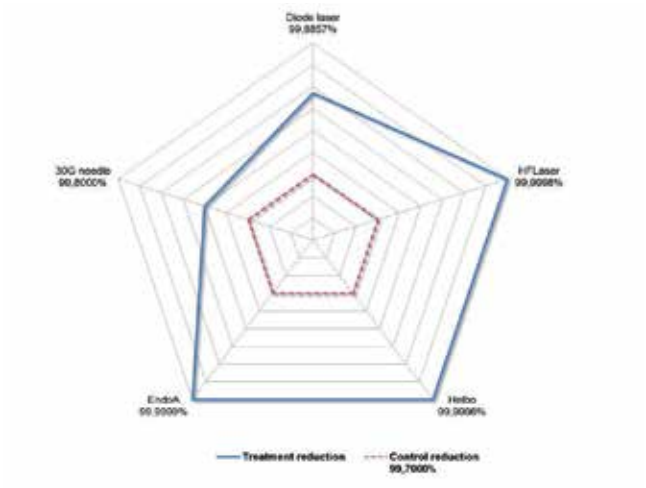

Figure 57. Antimicrobial efficacy of a high-power diode laser, photo activated disinfection, conventional and sonic activated irrigation.

The complexity of root canal system (inaccessible or unreachable areas such as isthmus, anastomoses, cul de sacs, fins), biofilm and therapy resistant micro-organisms on the root canal wall and in dentinal tubuli, make complete debridment and removal of bacteria almost impossible. The failure of the conservative endodontic therapy of teeth with periapical process, that do not heal, requires endodontic surgery protocols. Therefore, the application of laser in the root canals system has been recommended in many *in vivo* and *in vitro* studies due to its ability to disinfect root canals effectively. However, laser therapy cannot be used instead of the conventional instrumentation/irrigation protocol but as an adjunctive final disinfection protocol. Special attention has been given to the evaluation of the antimicrobial photodynamic therapy, which shows great promise in the field of endodontic disinfection, particularly because it does not affect ''friendly" bacterial flora, nor host cells.

3.10. Safety aspects

Lasers and intense pulsed light systems continue to advance rapidly in technology and applications. Serious consideration must be given to the correct selection, installation, training and use of the equipment. Many hazards exist with laser use, including electrical, mechanical, chemical, biological, optical and firehazards as well as concerns with regards to toxic effect of laser plume. Control measures should be implemented to minimize these hazards in accordance with legislation and common sense, and protective equipment that is available should be used and maintained appropriately [6]. It is recommended that a laser safety policy and procedure be written in each institution using lasers to treat patients. Laser safety warning signs should be placed on the door of any operating room using laser prior to usage. These signs should include the type and power of the laser being used [14].

The first aspect is the device safety. During the laser operation the actual power output must be supervised and if defective system causes a wrong dosage, an alarm must be activated. A safety switch off in the case of a component breakdown should be a standard feature of any medical laser system. Another aspect is the safety of staff and patients when laser procedures is undertaken. A prime consideration in laser safety is appropriate eyewear for both staff and patients. The patient must be protected against unintentional irradiation by safety covers and non-inflammable tubing, anaesthetics, and sterile sheets must be used. The issue of carrying off excessive heat and any pyrolysis products, which may be generated, must be reconsidered. It should be noted that dental mirrors absorb laser energy to various degrees and thus should never be deliberately lased. Likewise, surfaces which present reflection hazards should be identified and avoided. Generous use of wet gauze squares within the oral cavity provides an effective means for "trapping" scattered and reflected laser energy and for protecting soft tissues [1, 31]. Finally, it should be noted that lasers used during general anesthesia may pose a risk of ignition for flammable anesthetic gases [14, 15, 31].

4. Conclusion

Laser technology has made rapid progress over few past decades, and lasers have found a niche in many surgical specialities. Because of their many advantages, lasers have become indispensable in OMF surgery as an additional modality for soft tissue surgery. There are many uses for lasers in OMF surgery, and the advent of new wavelengths will undoubtedly lead to new procedures that can be performed with laser technology.

Practitioners should be satisfied that novel clinical approaches have a sound scientific basis, and are not adopted solely just on the basis of anecdotal reports or incomplete research. Despite the enthusiastic acceptance of this technology by professionals and the public, further research, including controlled clinical studies, to investigate the higher efficacy, as well as the other side effects of laser therapy, is still needed.

As Dr. Theodore Maiman, the inventor of the first laser stated: "The medical application of the laser is fascinating for two reasons. It is an optimistic mission on the one hand, while on the other it counteracts the original impression of the laser being a death ray."

Acknowledgements

The authors are grateful to Hager&Werken and Bredent for technical support. We would like to especially thank all employees of the Department of Oral Surgery and Department of Endodontics and Restorative Dentistry, School of Dental Medicine, University of Zagreb.

Author details

Dragana Gabrić Pandurić[1*], Ivona Bago[2], Irina Filipović Zore[1], Mato Sušić[1], Davor Katanec[1], Aleksandar Milenović[3] and Vanja Vučićević Boras[4]

*Address all correspondence to: dgabric@sfzg.hr

1 Department of Oral Surgery, School of Dental Medicine, University of Zagreb; University Dental Clinic, Clinical Hospital Center Zagreb, Croatia

2 Department of Endodontics and Restorative Dentistry, School of Dental Medicine, University of Zagreb; University Dental Clinic, Clinical Hospital Center Zagreb, Croatia

3 Department of Oral and Maxillofacial Surgery, School of Dental Medicine, University of Zagreb; Clinical Hospital Dubrava, Croatia

4 Department of Oral Medicine, School of Dental Medicine, University of Zagreb; University Dental Clinic, Clinical Hospital Center Zagreb, Croatia

References

[1] Müller, J. G., Berlien, P., & Scholz, C. (2006). The Medical Laser. *Medical Laser Application*, 21(2), 99-108.

[2] Einstein, A. (1917). Zür Quantentheorie der Stralung. *Physiol Z*, 18-121.

[3] Schawlow, A. L., & Townes, C. H. (1958). Infrared and Optical Masers. *Physical Review*, 1112-1940.

[4] Golnabi, H., & Mahdieh, M. H. (2006). Trend of Laser Research Developments in Global Level. *Optics & Laser Technology*, 38(2), 122-131.

[5] Maiman, T. H. (1960). Stimulated Optical Radiation in Ruby. *Nature*, 187-493.

[6] Shokrollahi, K., Raymond, E., & Murison, MS. (2004). Lasers: Principles and Surgical Applications. *Journal of Surgery*, 2(1), 28-34.

[7] Deppe, H., & Horch, H. H. (2007). Laser Applications in Oral Surgery and Implant Dentistry. *Lasers in Medical Science*, 22(4), 217-221.

[8] Driggers, R. G. (2003). Encyclopedia of Optical Engineering. *New York: Taylor&Francis*.

[9] Niemz, M. H. (2007). Laser-Tissue Interactions: Fundamentals and Applications (Biological and Medical Physics, Biomedical Engineering). *Springer-Verlag: Berlin*.

[10] Dederich, D. N. (1991). Laser/Tissue Interaction. *Alpha Omegan*, 84(4), 33-36.

[11] Dederich, D. N. (1993). Laser/Tissue Interaction: What Happens to Laser Light When it Strikes Tissue? *Journal of American Dental Association*, 124(2), 57-61.

[12] Parker, S. (2007). Verifiable CPD Paper: Laser-Tissue Interaction. *British Dental Journal*, 202(2), 73-81.

[13] Clayman, L., & Kuo, P. (1997). Lasers in Maxillofacial Surgery and Dentistry. *Thieme: New York*.

[14] Convissar, R. A. (2010). Principles and Practise of Laser Dentistry. *Mosby Elsevier: St Louis*.

[15] Strauss, R. A. (2000). Lasers in Oral and Maxillofacial Surgery. *Dental Clinics of North America*, 44(4), 851-873.

[16] Stabholz, A., Zeltser, R., Sela, M., Peretz, B., Moshonov, J., Ziskind, D., & Stabholz, A. (2003). The Use of Lasers in Dentistry: Principles of Operation and Clinical Applications. *Compendium of Continuing Education in Dentistry*, 24(12), 935-948.

[17] Gabrić, Pandurić. D. (2010). Physical and Ultrastructural Bone Effect Comparison Between Laser and Surgical Drill. PhD thesis. *University of Zagreb*.

[18] Eyrich, G. K. (2005). Laser-Osteotomy Induced Changes in Bone. *Medical Laser Application*, 20(1), 25-36.

[19] De Mello, E. D., Pagnoncelli, R. M., Munin, E., Filho, M. S., de Mello, G. P., Arisawa, E. A., & de Oliveira, M. G. (2008). Comparative Histological Analysis of Bone Healing of Standardized Bone Defects Performed With the Er:YAG Laser and Steel Burs. *Lasers in Medical Science*, 23(3), 253-260.

[20] Li, Z. Z., Reinisch, L., & Van de Merwe, W. P. (1992). Bone Ablation With Er:YAG and CO_2 Laser: Study of Thermal and Acoustic Effects. *Lasers in Surgery and Medicine*, 12(1), 79-85.

[21] Walsh, J. T. Jr, Flotte, T. J., & Deutsch, T. F. (1989). Er:YAG Laser Ablation Tissue: Effect of Pulse Duration and Tissue Type on Thermal Damage. *Lasers in Surgery in Medicine*, 9(4), 314-326.

[22] Frentzen, M., Götz, W., Ivanenko, M., Afilal, S., Werner, M., & Hering, P. (2003). Histological Results After Osteotomy With 80-μs CO_2 Laser Pulses and Air-Water Spray. *International Congress Series*, 1248, 383-384.

[23] Gontijo, I., Navarro, R. S., Haypek, P., Ciamponi, A. L., & Haddad, A. E. (2005). The Applications of Diode and Er:YAG Lasers in Labial Frenectomy in Infant Patients. *Journal of Dentistry for Children (Chic)*, 72(1), 10-15.

[24] Deppe, H., & Horch, H. H. (2007). Current Status of Laser Application in Oral and Cranio-Maxillofacial Surgery. *Medical Laser Application*, 22(1), 39-42.

[25] Romanos, G. E. (2003). Laser Surgical Tools in Implant Dentistry for the Long-Term Prognosis of Oral Implants. *International Congress Series*, 1248-109.

[26] Deppe, H., Horch, H. H., Greim, H., Brill, T., Wagenpfeil, S., & Donath, K. (2005). Peri-Implant Care With the CO_2 Laser: In Vitro and In Vivo Results. *Medical Laser Application*, 20(1), 61-70.

[27] Kreisler, M., Götz, H., & Duschner, H. (2002). Effect of Nd:YAG, Er:YAG, CO2, and GaAIAs Laser Irradiation on Surface Properties of Endosseous Dental Implants. *International Journal of and Oral Maxillofacial Implants*, 17(2), 202-211.

[28] Matsuyama, T., Aoki, A., Oda, S., Yoneyama, T., & Ishikawa, I. (2003). Effects of the Er:YAG Laser Irradiation on Titanium Implant Materials and Contaminated Implant Abutment Surfaces. *Journal of Clinical Laser Medicine and Surgery*, 21(1), 7-17.

[29] Park, C. Y., Kim, S. G., Kim, M. D., Eom, T. G., Yoon, J. H., & Ahn, S. G. (2005). Surface Properties of Endosseous Dental Implants After Nd:YAG and CO2 Laser Treatment at Various Energies. *Journal of Oral and Maxillofacial Surgery*, 63(10), 1522-1527.

[30] Giannini, R., Vassalli, M., Chellini, F., Polidori, L., Dei, R., & Giannelli, M. (2006). Neodymium:yttrium Aluminium Garnet Laser Irradiation With Low Pulse Energy: a Potentional Tool for the Treatment of Periimplant Disease. *Clinical Oral Implants Research*, 17(6), 638-643.

[31] Walsh, L. J. (1992). The Use of Lasers in Implantology: an Overview. *Journal of Oral Implantology*, 18(4), 335-340.

[32] Schwarz, F., Olivier, W., Herten, M., Sager, M., Chaker, A., & Becker, J. (2007). Influence of Implant Bed Preparation Using an Er:YAG Laser on the Osseointegration of Titanium Implants: a Histomorphometrical Study in Dogs. *Journal of Oral Rehabilitation*, 34(4), 273-281.

[33] Kesler, G., Romanos, G., & Koren, R. (2006). Use of Er:YAG Laser to Improve Osseointegration of Titanium Alloy Implants- a Comparison of Bone Healing. *International Journal of Oral and Maxillofacial Implants*, 21(3), 375-379.

[34] Salina, S., Maiorana, C., Iezzi, G., Colombo, A., Fontana, F., & Piattelli, A. (2006). Histological Evaluation, in Rabbit Tibiae, of Osseointegration of Mini-Implants in Sites Prepared With Er:YAG Laser Versus Sites Prepared With Traditional Burs. *Journal of Long Term Effects of Medical Implants*, 16(2), 145-156.

[35] El -Montaser, M., Devlin, H., Dickinson, M. R., Sloan, P., & Lloyd, R. E. (1999). Osseointegration of Titanium Metal Implants in Erbium-YAG Laser-Prepared Bone. *Implant Dentistry*, 8(1), 79-85.

[36] Arnabat-Dominguez, J., Espana-Tost, A. J., Berini-Aytés, L., & Gay-Escoda, C. (2003). Erbium:YAG Laser Application in the Second Phase of Implant Surgery: a Pilot Study in 20 Patients. *International Journal of Oral and Maxillofacial Implants*, 18(1), 104-112.

[37] Dörtbudak, O., Haas, R., & Mallath-Pokorny, G. (2000). Biostimulation of Bone Marrow Cells With a Diode Soft Laser. *Clinical Oral Implants Research*, 11(6), 540-545.

[38] Pinheiro, A. L., Lopes, C. B., Sathaiah, S., & Duarte, J. (2003). Laser Biomodulation in Bone Implants: a Raman Spectral Study. *International Congress Series*, 1248-449.

[39] Pinheiro, A. L., Limeira Junior., F.de A., Gerbi, M. E., Ramalho, L. M., Marzola, C., & Ponzi, E. A. (2003). Effect of Low Level Laser Therapy on the Repair of Bone Defects Grafted With Inorganic Bovine Bone. *Brazilian Dental Journal*, 14(3), 177-181.

[40] Frame, J. W. (2003). Recent Progress With the CO2 Laser in Oral Surgery. *International Congress Series*, 1248-3.

[41] D'Arcangelo, C., Di Nardo Di, Maio. F., Prosperi, G. D., Conte, E., Baldi, M., & Caputi, S. (2007). A Preliminary Study of Healing of Diode Laser Versus Scalpel Incisions in Rat Oral Tissue: a Comparison of Clinical, Histological, and Immunohistochemical Results. *Oral Surgery Oral Medicine, Oral Pathology, Oral Radioliology, and Endodontics*, 103(6), 764-773.

[42] Bryant, G. L., Davidson, J. M., Ossoff, R. H., Garrett, C. G., & Reinisch, L. (1998). Histologic Study of Oral Mucosa Wound Healing: a Comparison of a 6.0 to 6.8-Micrometer Pulsed Laser and a Carbon Dioxide Laser. *Larygoscope*, 108(1 Pt 1), 13-17.

[43] Greene, C. H., Debias, D. A., Henderson, M. J., Fair-Covely, R., Dorf, B., Radin, A. L., & Young-Seidman, W. L. (1994). Healing of Incisions in the Tongue: a Comparison of

Results with Miliwatt Carbon Dioxide Laser Tissue Welding Versus Suture Repair. *Annals of Otology, Rhinology and Laryngology*, 103(12), 964-974.

[44] Liboon, J., Funkhouser, W., & Terris, D. J. (1997). A Comparison of Mucosal Incisions Made by Scalpel, CO2 Laser, Electrocautery and Constant-Voltage Electrocautery. *Otolaryngology- Head and Neck Surgery*, 116(3), 379-385.

[45] Jin, J. Y., Lee, S. H., & Yoon, H. J. (2010). A Comparative Study of Wound Healing Following Incision With a Scalpel, Diode Laser or Er, Cr: YSGG Laser in Guinea Pig Oral Mucosa: a Histological and Immunohistochemical Analysis. *Acta Odontologica Scandinavica*, 68(4), 232-238.

[46] Romanos, G., & Nentwig, G. H. (1999). Diode Laser (980 nm) in Oral and Maxillofacial Surgical Procedures: Clinical Observations Based on Clinical Applications. *Journal of Clinical Laser Medicine and Surgery*, 17(5), 193-197.

[47] Stübinger, S., Saldamli, B., Jürgens, P., Ghazal, G., & Zeilhofer, H. F. (2006). Soft Tissue Surgery With the Diode Laser-Theoretical and Clinical Aspects. *Schweizer Monatsschrift fur Zahnmedicine*, 116(8), 812-820.

[48] Blaya, D. S., Guimarães, M. B., Pozza, D. H., Weber, J. B., & de Oliveira, M. G. (2008). Histologic Study of the Effect of Laser Therapy on Bone Repair. *The Journal of Contemporary Dental Practice*, 9(6), 41-48.

[49] Pinheiro, A. L. (2003). Recent Studies on Bone Regeneration. *International Congress Series*, 1248-69.

[50] De Medeiros, V. P., Toma, L., Reginato, R. D., Katchburian, E., Nader, H. B., & Faloppa, F. (2012). The Low Level Laser Therapy Effect on the Remodeling of Bone Extracellular Matrix. Photochemistry and PhotobiologyEpub ahead of print]

[51] Houk, L. D., & Humphreys, T. (2007). Masers to Magic Bullets: an Updated History of Lasers in Dermatology. *Clinical Dermatology*, 25(5), 434-442.

[52] Gutknecht, N., van Gogswaardt, D., Conrads, G., Apel, C., Schubert, C., & Lampert, F. (2000). Diode Laser Radiation and its Bactericidal Effect in Root Canal Wall Dentin. *Journal of Clinical Laser Medicine and Surgery*, 18(2), 57-60.

[53] Souza, E. B., Cai, S., Simionato, M. R. L., & Lage-Marques, J. L. (2008). High-Power Diode Laser in the Disinfection in Depth of the Root Canal Dentin. *Oral Surgery Oral Medicine Oral Pathology Oral Radiology and Endodontics*, 106(1), 68-72.

[54] Gutknecht, N., Moritz, A., Conrads, C., & Lampert, F. (1997). Der Dioden Laser und seine Bakterizide Wirkung im Wuzelkanal: Eine in Vitro Studie. *Endodontie*, 3-217.

[55] Moritz, A., Gutknecht, N., Schoop, U., Goharkhy, K., Doertbudak, O., & Sperr, W. (1997). Irradiation of Infected Root Canals with a Diode Laser in vivo: Results of Microbiological Examinations. *Laser sin Sirgery and Medicine*, 21(3), 221-226.

[56] Gutknecht, N., Alt, T., Slaus, G., Bottenberg, P., Rosseel, P., Lauwers, S., & Lampert, F. (2002). A Clinical Comparison oft he Bactericidal Effect of the Diode Laser and 5%

Sodium Hypochlorite in Necrotic Root Canals. *Journal of Oral Laser Application*, 2(3), 151-157.

[57] Eriksson, A. R., & Albrektsson, T. (1983). Temperature Threshold Levels for Heat-Induced Bone Tissue Injury: A Vital Microscopic Study int he Rabbit. *Journal of Prosthetic Dentistry*, 50(1), 101-107.

[58] Moritz, A., Gutknecht, N., Goharkhy, K., Schoop, U., Wernisch, J., & Sperr, W. (1997). In Vitro Irradiation of Infected Root Canals with a Diode Laser: Results of Microbiologic, Infrared Spectrometric, and Stain Penetration Examinations. *Ouintessence International*, 28(3), 490-493.

[59] Wang, X., Sun, Y., Kimura, Y., Kinoshita, J. I., Ishizaki, N. T., & Matsumoto, K. (2005). Effects of diode Laser Irradiation on Smear Layer Removal from Root Canal Walls and Apical Leakage after Opturation. *Phtomedicine and Laser Surgery*, 23(5), 575-581.

[60] Hmud, R., Kahler, W. A., George, R., & Walsh, L. J. (2009). Cavitational Effects in Aqueous Endodontic Irrigants Generated by Near-Infrared Lasers. *Journal of Endodontics*, 36(2), 275-278.

[61] Dobson, J., & Wilson, M. (1992). Sensitization of Oral Bacteria in Biofilms to Killing by Light from a Low Power Laser. *Archives of Oral Biology*, 37(11), 883-7.

[62] Seal, G. J., Ng, Y. L., Spratt, D., Bhatti, M., & Gulabivala, K. (2002). An in vitro Comparison of the Bactericidal Efficacy of Lethal Photosensitization or Sodium Hyphochlorite Irrigation on Streptococcus intermedius Biofilms in Root Canals. *International Endodontic Journal*, 35(3), 268-274.

[63] Soukos, N. S., Chen, P. S., Morris, J. T., Ruggiero, K., Abernethy, A. D., Som, S., Foschi, F., Doucette, S., Bammann, L. L., Fontana, C. R., Doukas, A. G., & Stashenko, P. P. (2006). Photodynamic Therapy for Endodontic Disinfection. *Journal of Endodontics*, 31(10), 979-984.

[64] Meire, M. A., Coenye, T., Nelis, H. J., & De Moor, R. J. G. (2012). Evaluation of Nd:YAG and Er:YAG irradiation, antibacterial photodynamic therapy and sodium hypochlorite treatment on Enterococcus faecalis. *International Endodontic Journal*, 45(5), 482-492.

[65] Garces, A. S., Nunez, S. C., Hamblim, M. R., Suzuki, H., & Ribeiro, M. (2010). Photodynamic Therapy Associated with Conventional Endodontic Treatment in Patients with Antibiotic-Resistant Microflora: A Preliminary Report. *Journal of Endodontics*, 36(9), 1463-1466.

[66] Lee, M. T., Bird, P. S., & Walsh, L. J. (2004). Photo-Activated Disinfection of the Root Canal: A New Role for Lasers in Endodontics. *Australian Endodontic Journal*, 30(3), 93-8.

[67] Rios, A., He, J., Glickman, G. N., Spears, R., Schneiderman, E. D., & Honeyman, A. L. (2011). Evaluation of Photodynamic Therapy Using a Light-Emitting Diode Lamp

against Enterococcus faecalis in Extracted Human Teeth. *Journal of Endodontics*, 37(6), 856-9.

[68] Silva, L. A. B., Novaes, A. B., de Oliveira, R. R., Nelson-Filho, P., Santamaria, M., & Silba, R. A. B. (2012). Antimicrobial Photodynamic Therapy for the Treatment of Teeth with Apical Periodontitis: A Histopathological Evaluation. *Journal of Endodontics*, 38(3), 360-366.

[69] Bago, I., Plečko, V., Gabrić, Pandurić. D., Schauperl, Z., Baraba, A., & Anić, I. (2012). Antimicrobial efficacy of a high-power diode laser, photo activated disinfection, conventional and sonic activated irrigation during endodontic therapy. *International Endodontic Journal. In Press.*

[70] Schoop, U., Kluger, W., Moritz, A., Nedjelik, N., Georgopoulos, A., & Sperr, W. (2004). Bactericidal effect of different laser systems in the deep layers of dentin. *Lasers in Surgery and Medicine*, 35(2), 111-6.

Section 8

Maxillofacial Fractures: Diagnosis and Management

Chapter 14

Management of Mandibular Fractures

Amrish Bhagol, Virendra Singh and Ruchi Singhal

Additional information is available at the end of the chapter

http://dx.doi.org/10.5772/53854

1. Introduction

The treatment of mandibular fractures has been in a constant state of evolution over the past few decades. The most significant advancements related to the management of fractures of the mandible are based on specific technical refinements in the methods of internal fixation. Also there is improvement in the knowledge of anatomy, pathophysiology, pharmacology and biomaterial science which influence our current management of mandibular fractures. Recent mandibular fracture management techniques have allowed for decreased infection rates and biological stable fixation of bone segments. This philosophy produces bony union and restoration of preinjury occlusion and normally eliminates the need for wire maxillomandibular immobilization. All this adds up to a faster, safer, more comfortable return to function. In spite of the presence of these modern techniques, closed reduction has by no means fallen by the wayside and still remains a commonly used procedure.This chapter presents an overview of general treatment principles in the management of mandibular fractures and also discusses the treatment strategies in detail depending on the age and anatomical site involved (symphysis, angle, condyle etc). Mandibular fractures in children and adults need different treatment approaches. Similarly, fractures of different anatomical sites in the mandible need different treatment modalities; they differ in their biomechanics, treatment requirements and complications. So each fracture is discussed individually taking care of the different schools of thought and controversies regarding their management. Major advances in the treatment of mandibular fracture in terms of biomaterials and minimally invasive surgical techniques are also discussed.

2. Historical overview

Historical references to mandible fracture diagnosis and treatment date back to 1650 BC as evidenced by the Edwin Smith Surgical Papyrus.[1,2] The patient described subsequently

INTECH
open science | open minds

© 2013 Bhagol et al.; licensee InTech. This is a paper distributed under the terms of the Creative Commons Attribution License (http://creativecommons.org/licenses/by/3.0), which permits unrestricted use, distribution, and reproduction in any medium, provided the original work is properly cited.

died, likely from infection secondary to the mandibular fracture. Hippocrates, the "father of medicine," also described the treatment of mandible fractures with circumferential dental wiring in some of his initial writings.[3] However, it was Salicetti, in 1275, who first presented maxillomandibular fixation as a treatment for fractures of the mandibles,[4,5] ; the reader was advised to "tie the teeth of the uninjured jaw to the teeth of the injured jaw." Although a fundamental concept in contemporary facial fracture management, Salicetti's concept of MMF disappeared for centuries until Gilmer applied the technique clinically and described its utility in more detail in the United States in 1887.[6] Despite a few early attempts at rigid internal fixation, for most of the 20th century[7], the management of mandibular and maxillary fractures was limited to the application of bandages, maxillomandibular fixation or Gunning-type splints for the edentulous. Later external frames were used in combination with pin fixation. Fracture treatment by open approach and direct transosseous wiring was avoided in the preantibiotic era since it almost inevitably produced infection and osteomyelitis. It was reserved for use in select cases involving the posterior mandible (i.e. ramus/ angle) or in edentulous patients. The earliest reports of mandibular fractures treated with an open reduction were from Buck, using an iron loop, and Kinlock, using a silver wire. [8,9] Gilmer, in 1881, described the use of two heavy rods placed on either side of the fracture that were wired together.[10] Schede (circa 1888) is credited with the first use of a true bone plate made of steel and secured with four screws.[9] In the 1960s, Luhr developed the vitallium mandibular compression plate through his research on rigid fixation of the facial skeleton. Luhr and Spiessl reintroduced the idea of utilizing miniature bone plates in the repair of mandibular fractures in 1968 and 1972.[11] In 1976, Spiessl and others continued to advance techniques of open reduction and internal fixation (ORIF) and developed the principles now advocated by the Arbeitsgemeinschaft fur Osteosynthesefragen (Association for Osteosynthesis/Association for the Study of Internal Fixation (AO/ ASIF).[12] This concept was unfortunately based on trying to 'fit' orthopedic principles and, worse, orthopaedic materials to the complex structures of the facial skeleton. The belief was that callus formation represented a failure of the healing process, because of excessive and undesirable movements across the fracture. Thus more heavy and complex methods were devised to increase the stability across the fracture. These plates were bulky, difficult to use and always required large skin incisions. This philosophy failed to see that perfectly good reduction and healing could be achieved by very unstable fixation methods like wiring of the teeth together. Whilst mandibular maxillary wire fixation was potentially dangerous and unpleasant, it was very effective in healing bones. These crude, heavy plating systems did, however, demonstrate the benefits of avoiding wire maxillomandibular fixation, including comfort, return to normal mastication and normal oral function. In reality, these heavy compression plates had a high morbidity. The neck scars were undesirable, nerve damage to both the facial and inferior alveolar nerves was common and infection of the plates frequent; a second operation to remove the plates was always necessary. The principles of heavy compression plating could not be applied to the thin bones of the upper facial skeleton.

One useful technique to arise from this principle of applying orthopedic material to the facial skeleton was the use of lag screws, which is a simple technique of producing interfragmentary stability by compression. These have a large screw hole bored on the outer

fragment and allow the tightening of the screw to compress the fragments together. In a few sites in the mandible it can be a simple effective treatment via the intraoral approach but since the screw must cross the fracture at right angles it has limited use. In the 1970s another concept of internal fixation for the repair of mandibular fractures was introduced by Michelet and colleagues and refined by Champy and co-workers; they placed small, bendable, non-compression plates along the lines of ideal osteosynthesis.[13,14] Both of these techniques have proven to be effective and are routinely used in the contemporary management of mandibular fractures. The use of small miniplates was successfully integrated into the rest of the facial skeleton, being refined and miniaturized for the periorbital and cranial non-load bearing areas. Most recently, bone-plating systems made from resorbable polymer have been introduced. Although these materials show significant promise, they have been utilized most often in the non-load bearing cranial and orbital regions. The resorbable materials themselves and the techniques used in their application continue to be redefined at a rapid pace in this early phase of development.[15,16]

3. Diagnosis

The diagnosis of mandibular fractures must begin with a careful history and clinical examination. Immediate attention must always be given to problems associated with airway compromise and bleeding which may endanger the patient's life. Once the airway, breathing and circulation have been adequately assessed, a quick neurologic function evaluation should be performed. Standard trauma protocols such as those described in the Advanced Trauma Life Support guidelines from the American College of Surgeons should be utilized for a comprehensive evaluation. While taking history, information about the mode of injury will often suggest a specific fracture pattern and may provide the surgeon with valuable insight regarding the potential for concomitant injuries. Patients who sustain fractures involving the mandible will often report a paresthesia or change in their occlusion noted immediately after the traumatic event. The patient's past medical and surgical history, medication use and known drug allergies should also be reviewed. Temporomandibular joint dysfunction and any previous non-surgical or surgical treatment should be carefully documented. When a mandibular fracture is suspected, meticulous clinical examination of the maxillofacial region is critical and should be carried out prior to the ordering of radiographic imaging studies.

3.1. Clinical examination

Without question, a change in occlusion is the most common physical finding in patients with fractures of the mandible. When examining the occlusion, it is important to consider that the patient may have had an abnormal dental or skeletal occlusal relationship (Class II or Class III) prior to the injury. Changes in occlusion will likely accompany fractures of the mandible, but may also be present in soft tissue trauma of the TMJ, fractures of the alveolus, dental fractures or fractures of the maxilla. When the fracture traverses a region of the mandible that includes the inferior alveolar nerve, some level of neurosensory disturbance in-

volving this nerve will result. Abnormalities in the mandibular range of motion or deviation of the mandible are also indicative of fracture, as can be an inability to close completely. These restrictions may also be the result of internal TMJ injury or hematoma. Sublingual ecchymosis is highly suggestive of a fracture involving the mandibular arch. Another indication of fracture is a bony step which is most easily recognized by careful palpation along the inferior border of the mandible.

3.2. Radiographic examination

Proper treatment of fractures of the mandible is dependent on proper diagnosis of the injury. Paramount in diagnosis of the details of the fracture and therefore the treatment options is the radiographic evaluation. In principle, these should be at least two films taken at right angles to each other. The plain films used include oblique views, posteroanterior (PA) Towne's view, and possibly a lateral view. All institutions have these views available to them. Some continue to use these views for routine screening of mandibular trauma. The efficacy of these views remains controversial if other screening techniques are available. Because of the diagnostic efficacy of panoramic radiographs and CT, the surgeons at our institution seldom obtain plain views except for the Towne's view, which we have found to be very useful in assessing displacement of subcondylar fractures.

A diagnostic-quality panoramic radiograph is the most comprehensive view possible with a single film and allows satisfactory visualization of all regions of the mandible (condyle, ramus, body and symphysis).[17] It is also useful in examining the existing dentition, presence of impacted teeth with respect to the fracture, alveolar process and position of the mandibular canal. [Figure 1]

Figure 1. Panoramic tomogram showing parasymphysis and subcondylar fractures of mandible.

In situations where a panoramic view of the mandible is not available, a series of different views of the mandible is required to adequately view all the anatomic regions of interest. This is more labor intensive and costly and subjects the patient to a higher dose of radiation. Despite the good visualization of the dentoalveolar structures obtained by a panoramic radiograph, additional periapical or occlusal radiographs are often helpful in viewing specific

http://dx.doi.org/10.5772/53854

areas of concern with more detail, especially when tooth or alveolar fractures are suspected. Parasymphysis fractures often benefit from occlusal films to display any obliquity of the fracture, which will certainly change the fixation method.

3.3. Computed tomography examination

Computed tomography *(CT)* currently offers the most detailed and comprehensive view of the facial skeleton. Current protocols allow for axial, coronal and reconstructed three-dimensional images to be formulated [Figure 2].

Figure 2. Three dimensional reconstruction CT of a panfacial fracture.

Despite this superior three-dimensional visualization, the use of CT scans for the diagnosis of isolated mandibular fractures is uncommon and may be cost-prohibitive. In our experience, the use of CT scans is reserved for cases involving complex (comminuted, avulsive, etc.) mandibular injuries or concomitant midfacial or orbital injuries. In some cases where a condylar fracture is suspected, the CT will allow for detailed three-dimensional imaging. Another useful application of the CT scan is in clinical situations (cervical spine injury, head injury) where the patient is not able to submit to routine radiographic positioning and techniques. Very young patients with limited cooperation may also be candidates for CT scan evaluation, but will often require sedation during the procedure. Magnetic resonance imaging (MRI) is of very limited value in evaluating bony injuries. It may be helpful to delineate injuries to the intracapsular structures of the TMJ, associated soft tissues or in cases of condylar displacement into the middle cranial fossa. Ultrasound has occasionally been used to determine condylar position after fractures.

4. Closed versus open treatment of mandibular fractures

Mandibular fractures have been successfully treated by closed-reduction methods for hundreds of years. Maxillomandibular fixation (MMF) is used to immobilize the fractured segments and allow osseous healing. When considering between open versus closed reduction of mandibular fractures the advantages should be weighed against the disadvantages. Considerations include the site and characteristics of the fracture and the morbidities of the treatment. Unwanted results including bony ankylosis or decreased mouth opening can be prevented by early mobilization of the mandible. Early mobilization helps to prevent possible ankylosis especially in patients with intracapsular fractures of the condyle. It is preferred to avoid maxillomandibular fixation when fractures involve the temporomandibular joint (TMJ) because postoperative physiotherapy can be started much earlier.

Advantages of closed reduction include simplicity, decreased operative time, and avoidance of damage to adjacent structures. Disadvantages of maxillomandibular fixation include inability to directly visualize the reduced fracture, need to keep the patient on a liquid diet, and difficulties with speech and respiration. The traditional length of immobilization of fractures when treated by closed reduction has been 6 weeks. Juniper and Awty found that 80% of mandibular fractures treated with open or closed reduction and maxillomandibular fixation had clinical union in 4 weeks [18]. They were able to show a correlation between the age of the patient and the predictability of early fracture union. Armaratunga found that 75% of mandible fractures had achieved clinical union by 4 weeks. Fractures in children healed in 2 weeks whereas a significant number of fractures in older patients took 8 weeks to achieve clinical union [19]. Although maxillomandibular fixation has long been considered a benign procedure it can be associated with significant problems. An excellent review of the deleterious effects of mandibular immobilization on the masticatory system is provided by Ellis [20]. Closed reduction of mandibular fractures can adversely affect bone, muscles, synovial joints, and periarticular connective tissues. The effects of immobilization on bone have been recognized in the orthopedic literature for many years as ''disuse osteoporosis''. Cortical and trabecular thinning, vascular distention, and increased osteoclastic activity have been described following joint immobilization [21]. Changes involving the musculature include not only muscle atrophy but also changes in muscle length and function.

5. Rigid fixation

Rigid fixation in the mandible refers to a form of treatment that consists of applying fixation to adequately reduce the fracture and also permit active use of the mandible during the healing process. The four AO/ASIF principles are

1. anatomical reduction
2. functionally stable fixation
3. atraumatic surgical technique

4. immediate active function.

Although many osteosynthesis systems are currently available to treat mandibular fractures, the principles of plate application are similar. An overview of the various types follows.

5.1. Compression plates

Compression plates cause compression at the fracture site making primary bone healing more likely. These plates can be bent in only two dimensions because of their design and if they are not contoured properly they are unable to produce compression. It is important to avoid compressing oblique fractures. They also require bicortical screw engagement to produce even compression along the fracture line. This necessitates their placement at the inferior border to eliminate damage to the inferior alveolar neurovascular structures or the roots of the teeth. A higher incidence of complications has been noted in fractures treated with compression plates [22]. Because of the relatively small cross section of bone surface in some fractures, interfragmentary compression is often not possible. At our centre, surgeons prefer noncompression plates for treating mandibular fractures.

5.2. Reconstruction plates

Reconstruction plates are recommended for comminuted fractures and also for bridging continuity gaps. These plates are rigid and have corresponding screws with a diameter of 2.3–3.0 mm. Reconstruction plates can be adapted to the underlying bone and contoured in three dimensions. [Figure 3]

Figure 3. ORIF of a comminuted fracture using a Reconstruction Plate.

A problem that may be associated with conventional reconstruction plates is loosening of the screws during the healing process leading to instability of the fracture.

5.3. Locking reconstruction plates

In 1987 Raveh et al. introduced the titanium hollow-screw osteointegrated reconstruction plate (THORP) [23]. This system achieves stability between the screw and plate by insertion of an expansion screw into the head of the bone screw. This causes expansion of the screw flanges and locks them against the wall of the hole in the bone plate. Later Herford and Ellis described the use of locking reconstruction bone plate/screw system for mandibular surgery [24]. This system simplified the locking mechanism between the plate and the screw (Locking Reconstruction Plate, Synthes Maxillofacial, Paoli, PA) by engaging the threads of the head of the screw with the threads in the reconstruction plate, thus eliminating the need for expansion screws. Locking plate/screw systems offer advantages over conventional reconstruction plates. These plates function as internal fixators by achieving stability by locking the screw to the plate and allow greater stability as compared to conventional plates [25]. Fewer screws are required to maintain stability. The most significant advantage of this type of system is that it becomes unnecessary for the plate to intimately contact the underlying bone in all areas. As the screws are tightened they will not draw the plate and underlying bone toward each other.

5.4. Lag screw fixation

Lag screws can provide osteosynthesis of mandibular fractures [26,27]. They work well in oblique fractures and require a minimum of two screws. The lag screw engages the opposite cortex while fitting passively in the cortex of the outer bone segment. This can be accomplished by using a true lag screw or by overdrilling the proximal cortex. This causes compression of the osseous segments and provides the greatest rigidity of all fixation techniques. The proximal cortex should be countersunk to distribute the compressive forces over a broader area and avoid microfractures. The anatomy of the symphyseal region of the mandible lends itself to use of lag screws in a different technique. The lag screws can be placed through the opposing cortices between the mental foramen and inferior to the teeth. Fractures should not be oblique with this technique because it may cause the fractures to override each other.

5.5. Miniplates

Miniplates typically refer to small plates with a screw diameter of 2.0 mm. These plates have been shown to be effective in treating mandibular fractures. Typically a superior and inferior plate is required for adequate fixation. An exception to this is in the mandibular angle region where a superior border plate placed at the point of maximal tension is sufficient [Figure 4].

An advantage of these plates is that they are stable enough to obviate the need for maxillomandibular fixation and have a very low profile. They are less likely to be palpable, which reduces the need for subsequent plate removal. Typically screws are placed monocortically but may be placed bicortically when positioned along the inferior border of the mandible. A minimum of two screws should be placed in each osseous segment. Smaller incisions and

less soft-tissue reflections are required with these plates when compared to larger plates and they can be placed from an intraoral approach, thus eliminating an external scar. Because these plates are less rigid than reconstruction plates, their use in treating comminuted fractures should be avoided. [28] A study at our centre evaluated the efficacy of 2.0-mm locking miniplate system versus 2.0-mm nonlocking miniplate system for mandibular fracture and concluded that both miniplate system present similar short-term complication rates. [29]

Figure 4. ORIF of an angle fracture using a single miniplate at the superior border.

5.6. Microminiplates

Microminiplates usually refer to small malleable plates with a screw diameter of 1.0–1.5 mm. Their use for mandibular surgery is limited because of their inability to provide rigid fixation and because they have a tendency for plate fracture during the healing process [30]. These plates can work well in the midface where the muscular forces are much less than those acting on the mandible. A recent study found a 30.4% complication rate when 1.3-mm microminiplates were used to provide osteosynthesis for mandibular fractures [31].

5.7. Bioresorbable plates

Bioresorbable plates are manufactured from varying amounts of materials including polydioxanone (PDS), polyglycolic acid, and polylactic acid. It has been shown that the breakage of a poly-L-lactic acid (PLLA) plate occurred at 50% of the yield strength required to break a miniplate [32]. Complications associated with these plates include inflammation and foreign-body-type reactions. Laughlin et al. showed in their study that resorbable plates are equal to the performance of titanium 2-mm plates, regarding healing of the fracture with

bone union and restoration of function. [33] We are also using resorbable plates for routine treatment of mandibular fractures. [Figure 5]

Figure 5. ORIF using a resorbable plate at the angle region.

The common complication which we encountered during their use was screw head fracture during tightening. Consideration may be given for use in pediatric patients with the understanding of the possible complications.

5.8. Three-dimensional miniplates

These miniplates are based on the principle that when a geometrically closed quadrangular plate is secured with bone screws, it creates stability in three dimensions. The smallest structural component of a 3-D-plate is an open cube or a square stone. [Figure 6]

Clinical results and biomechanical investigations in a study have shown a good stability of the 3-D-plates in the osteosynthesis of mandibular fractures without major complications. The thin 1.0 mm connecting arms of the plate allow easy adaptation to the bone without distortion. The free areas between the arms permit good blood supply to the bone. [34]. A study conducted at our center showed that there is no major difference in terms of treatment outcome between conventional and 3-Dimensional Miniplates, and both are equally effective in managing mandibular fracture. [35] We believe 3- D miniplates provide good stability and operative time is less because of simultaneous stabilization at both superior and inferior borders.

http://dx.doi.org/10.5772/53854

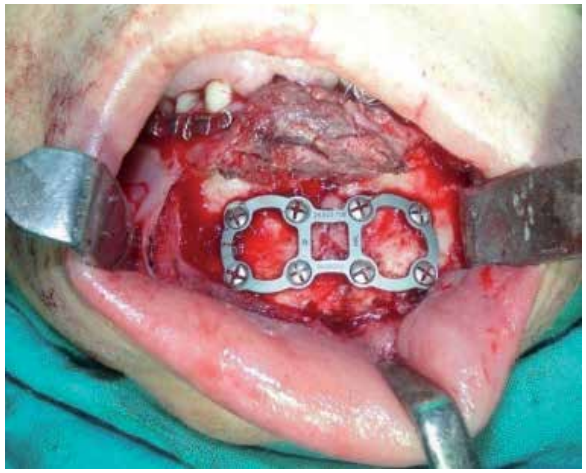

Figure 6. ORIF using a 3-Dimensional plate at symphysis fracture site.

6. General principles

6.1. Surgical technique

Intermaxillary fixation is placed prior to reducing a fracture. This allows for use of the occlusion to aid in anatomical reduction of the fracture. Use of full-arch bars combined with maxillomandibular fixation is the preferred method. The arch bars provide a way to maintain the occlusion postoperatively with elastic bands as needed during physiotherapy. The arch bars are usually removed after 4 weeks postoperatively.

The surgical approach depends on the site of the fracture. Either a transoral, vestibular, or transfacial approach may be performed. A facial approach provides excellent access but also produces a facial scar and adds the risk of damage to the facial nerve. Most fractures, excluding those of the condyle, can easily be approached through a transoral incision. A subperiosteal dissection with a periosteal elevator provides adequate access for reduction of the fracture and placement of fixation. Attention should be given to avoiding damage to the mental nerve, which exists the mental foramen near the apices of the premolar teeth. If additional exposure is needed, the nerve can be released by gently scoring the periosteum surrounding the nerve. Bone-reducing forceps are often helpful in reducing the fracture while adapting the bone plate. This also provides interfragmentary compression, making primary bone healing more likely. The smallest bone plate that will provide adequate stability under functional loads during the healing period is chosen. A minimum of two screws on either side of the fracture is required. Larger, more rigid plates are required to treat comminuted fractures or continuity defects [24]. The intermaxillary fixation that aided reduction of the fractures during plating is removed after the fixation is applied. A soft diet is recommended

for at least 3 weeks after miniplate fixation. It is important during the postoperative period to regain preinjury function, including maximal mouth opening, with active physiotherapy.

6.1.1. Teeth in the line of fracture

Most teeth in the line of fracture can be saved if appropriate antibiotic therapy and fixation techniques are used. Indications for removal of teeth in the line of fracture include grossly mobile teeth, partly erupted third molars with pericoronitis, teeth that prevent reduction of the fractures, fractured tooth roots, entire exposed root surfaces, or an excessive delay from the time of fracture to treatment. [36,37]

6.1.2. Antibiotics and mandible fractures

Zallen and Curry showed that mandibular fractures were associated with a 50% infection rate when patients did not receive antibiotic therapy. The infection rate was reduced to 6% for those patients who received antibiotics [38].

7. Treatment of specific fractures

7.1. Symphysis fractures

The optimal management of symphyseal and parasymphyseal fractures continue to evolve. Fractures in this area of the mandible predispose the patients to malocclusion and widening of the face if not properly treated. Arch bars and MMF are necessary to establish the premorbid relationship of the mandibular and maxillary teeth. However, care must be taken to avoid overtightening the MMF, which can cause flaring of the mandibular angles. The most common approach to the symphysis and parasymphysis is the transoral gingivolabial and gingivobuccal incision. With larger, comminuted fractures, an external approach may be necessary to accurately and rigidly fixate the mandible. Simple symphysis fractures can be treated with two miniplates. Because of the torsional forces generated during function, a single miniplate is insufficient to predictably maintain rigid fixation during healing [39]. One miniplate is placed at the inferior border and a second plate is placed superiorly. The superior plate is secured with a minimum of two monocortical screws in each segment whereas bicortical screws can be used on the inferior plate. Care should be taken to avoid damage to tooth roots while fixing the superior plate. These plates were placed in accordance to Champy's line of osteosynthesis. [Figure 7]

Several authors have shown that miniplate fixation along these lines is a very effective way to fixate these fractures. [40]

More rigid fixation should be considered for comminuted fractures. It is important to avoid ''flaring'' of the ramus in patients with a symphysis fracture and especially when combined with condyle fractures. This will be seen clinically as a dental crossbite of the posterior occlusion and also fullness of the mandibular angle region. This can be avoided by applying

pressure at the angle region during fixation, overbending the plate(s), and directly visualizing the lingual aspect of the reduced fracture.

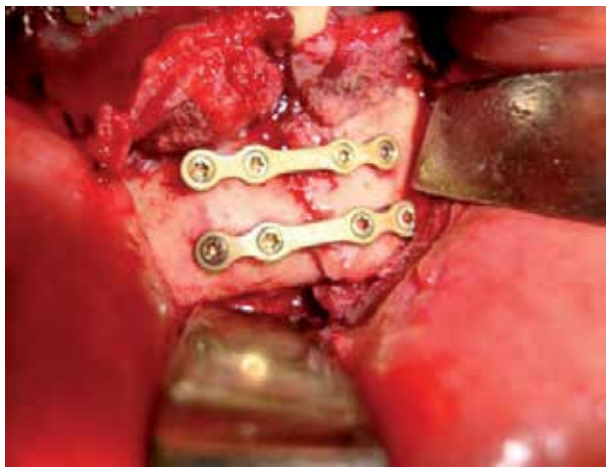

Figure 7. ORIF of symphysis fracture using two miniplates; one at the superior border and other at the inferior border along Champy's line of osteosynthesis.

Lag screw fixation is other useful technique in the symphysis and parasymphysis region [41]. When the lag screws are applied, it is imperative to reduce the lingual border of the fracture and re-establish the appropriate intergonial distance by squeezing the mandibular angles together. While holding the reduction, the lag screws may be applied. For optimal strength, two lag screws are placed. Several authors have suggested that a single strong plate with an arch bar is adequate in managing symphyseal fractures. We are also using single strong plates at inferior border along with arch bar as a tension band in our cases. No major complications have been noted in any of our patients.

7.1.1. Mandibular body fractures

Simple fractures involving the body of the mandible can be effectively treated with one miniplate along the Champy line of osteosynthesis. [Figure 8]

Care should be taken during the dissection to avoid damaging the mental nerve, which supplies sensation to the lower lip. If further reflection is necessary, the periosteum can be scored to release the nerve and allow improved visualization. Often a bone-reducing clamp can be applied prior to plate placement to aid in reduction of the fracture.

7.1.2. Angle fractures

The angle region of the mandible is one of the most common sites of fracture. Often trauma to the lateral mandible will cause a fracture at the angle and also involve the contralateral mandible. Many reasons for the greater proportion of fractures to this site have been cited. These include the presence of impacted third molars, a thinner cross-sectional area in this

region, and also the biomechanical lever arm in this area. A recent study looked at the incidence of fractures when teeth were involved. They found a significantly increased incidence of fractures involving the mandibular angle when there was an associated impacted third molar [42]. The angle region is a weak point, because the bone anterior and posterior (body and ramus, respectively) are thicker than the bone in the angle region [43]. These fractures are associated with the highest rate of complications [18]. The angle fracture can be further complicated by distraction and rotation by opposing forces of the elevator muscles (masseter, medial and lateral pterygoid, temporalis) and the depressor muscles (geniohyoid, genioglossus, mylohyoid, digastrics).

Figure 8. ORIF of a mandibular body fracture with a single miniplate between root apices and inferior alveolar canal along Champy's line of osteosynthesis.

Many techniques for treating mandibular angle fractures have been described. Because no teeth are present in the posterior (proximal) segment, arch bars cannot be used to stabilize the segments and there is no control over the proximal segment. Closed-reduction techniques are often associated with rotation of the ramus. With the introduction of plate-and-screw osteosynthesis many surgical methods have been described. Those who advocate large bone plates are attempting to eliminate interfragment mobility and thus allow for primary bone union [23,44]. Others have questioned the need for absolute rigidity for treatment of angle fractures In 1973, Michelet et al, described the use of small, malleable bone plates for treatment of angle fractures [13]. This led to a change from the previous belief that rigid fixation was necessary for bone healing. Later, Champy et al. validated the technique by performing several clinical investigations [14]. They determined the most stable location where bone plates should be placed based on the ''ideal lines of osteosynthesis''. The ''Champy technique'' involves placing a small bone plate along the superior border and using monocortical screws to secure the plate and avoid damage to the adjacent teeth or inferior alveolar neurovasular bundle. Absolute immobilization is not provided with this form of treatment (semirigid fixation). Clinical studies have shown that the amount of stability of the fractures is significant enough to eliminate the need for maxillomandibular fixation [45].

http://dx.doi.org/10.5772/53854

The superior border plate neutralizes distraction forces (tension) on the mandible while preserving the self-compressive forces that occur during function.

A prospective study looked at eight methods for treating mandibular angle fractures [45]:

1. closed reduction;
2. extraoral ORIF with a large reconstruction plate;
3. intraoral ORIF using a single lag screw;
4. intraoral ORIF using two 2.0-mm minidynamic compression plates;
5. intraoral ORIF using two 2.4-mm mandibular compression plate;
6. intraoral ORIF using two noncompression miniplates;
7. intraoral ORIF using a single noncompression miniplate; and
8. intraoral ORIF using a single malleable noncompression miniplate.

The results revealed that extraoral ORIF with a reconstruction plate and intraoral ORIF using a single miniplate are associated with the fewest complications (7.5% and 2.5%, respectively). This finding is interesting because the single miniplate is less rigid than the other forms of fixation, yet it is associated with the fewest complications. A possible explanation is that less extensive dissection is required and more of the blood supply is maintained.

We are also using intraoral ORIF using a single miniplate along the Champy's ideal line of osteosynthesis for angle fractures. [Figure 9]

Figure 9. Intraoral ORIF using a single miniplate along the Champy's ideal line of osteosynthesis for angle fractures.

The main problem we encountered is the inability to achieve anatomic reduction in cases of severely displaced angle fractures through intraoral approach. A study conducted at our centre evaluated the efficacy of using a single miniplate at the inferior border in the management of a displaced angle fracture through extraoral approach. [Figure 10-12]

Figure 10. Intraoperative view showing displaced angle fracture exposed through extraoral approach.

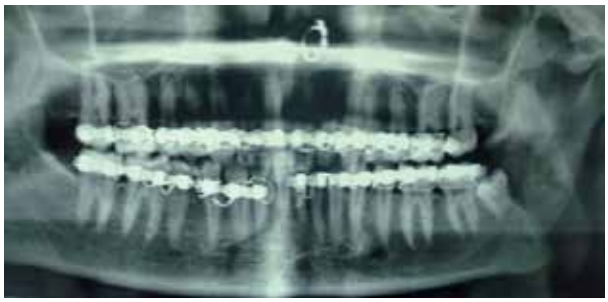

Figure 11. Panoramic Tomogram showing displaced left angle fracture.

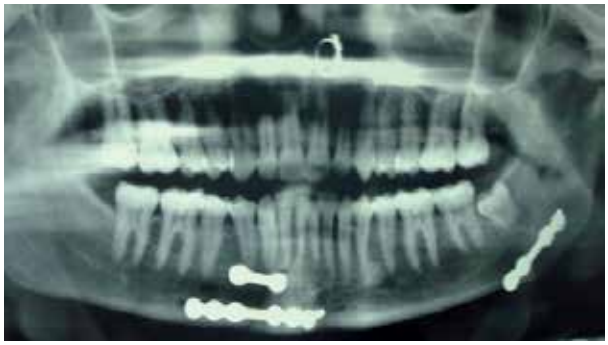

Figure 12. Panoramic Tomogram showing anatomically reduced angle fracture and fixation with a single miniplate at inferior border.

The study concluded that outcomes are acceptable in patients but a multicenter study with an appropriate comparison group is required to substantiate a more generalizable conclusion of efficacy of this single miniplate at inferior border. [46]

7.1.3. Condyle fractures

Fractures of the condyle can involve the head (intracapsular), neck, or subcondylar region. The head of the condyle may be dislocated outside of the fossa. The most common direction of displacement is in an anteromedial direction because of the pull from the lateral pterygoid muscle, which inserts on the anterior portion of the head of the condyle. No other type of mandibular fracture is associated with as much controversy regarding treatment as those involving the condyle. Factors considered in deciding whether to treat a condyle fracture open or closed include the fracture level, amount of displacement, adequacy of the occlusion, and whether the patient can tolerate maxillomandibular fixation. Those who advocate open treatment cite advantages including early mobilization of the mandible, better occlusal results, better function, maintenance of posterior ramal height, and avoidance of facial asymmetries [47]. The ramal height shortening can be assessed on panoramic radiograph [Figure 13] and can be restored by open treatment of condylar fractures. [Figure 14]

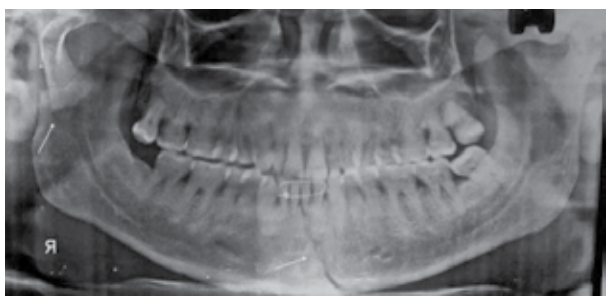

Figure 13. Panoramic Tomogram showing displaced right subcondylar fracture and left parasymphysis fracture. Note that there is loss of ramal height on the right side.

Figure 14. Panoramic Tomogram of fixation of subcondylar fracture using two miniplates; the vertical ramal height is restored by ORIF of subcondylar fracture.

Others prefer closed reduction mainly because of the possible complications associated with open reduction including damage to branches of the facial nerve and a cutaneous scar. Recently endoscopic subcondylar fracture repair has been described with encouraging results [48]. Nonsurgical management (closed reduction) includes MMF with elastics for a variable period followed by guiding elastics so as to maintain the occlusion while allowing jaw physiotherapy during healing. Measurable criteria should be assessed whether treating by closed or open methods. These should include pain-free movement, mouth-opening, jaw movement in all excursions, preinjury occlusion, radiographic assessment of deviation of the fractured fragment and shortening of the ascending ramus [49]. Zide and Kent described the absolute and relative indications for open reduction of condyle fractures [50]. Absolute indications include

1. displacement of the condylar head into the middle cranial fossa;
2. impossibility of obtaining adequate occlusion by closed reduction;
3. lateral extracapsular displacement of the condyle; and
4. invasion by a foreign body (e.g.gunshot wound)

Relative indications include

1. bilateral condyle fractures in an edentulous patient;
2. unilateral or bilateral condyle fractures when splinting is not recommended for medical reasons;
3. bilateral condyle fractures associated with comminuted midface fractures; and
4. bilateral condyle fractures and associated gnathological problems (e.g. lack of posterior occlusal support).

The degree of displacement of the condylar fracture has been used in deciding between open or closed treatment. Mikkonen et al. and Klotch and Lundy recommended open reduction if the condylar displacement was greater than 45 degrees in a sagittal or coronal plane and Widmark et al. recommended opening such fractures if the displacement was greater than 30 degrees [51-53]. The author proposed a new classification of subcondylar fractures of the mandible based on ramal height shortening and degree of fracture angulation. [54] The classification is as follows:

8. Fracture classification

On the basis of Towne's and panoramic radiograph, the fractures are categorized into 3 classes:

1. 1Class 1 (minimally displaced)—fracture with ramal height shortening; < 2 mm and/or degree of fracture displacement; <10°.

2. Class 2 (moderately displaced)—fracture with ramal height shortening; 2 to 15 mm and/or degree of fracture displacement; 10 to 35°

3. Class 3 (severely displaced)—fracture with ramal height shortening; >15 mm and/or degree of fracture displacement; >35°.

This new classification based on ramal height shortening and degree of fracture displacement can better guide clinical treatment. Class 1 fractures should be treated by closed method, while open reduction is recommended in Class 2 and Class 3 cases.

Intracapsular fractures involving the condylar head are difficult to treat and most recommend close treatment of these fractures to avoid damage to adjacent structures. Fractures involving the condylar neck and subcondylar region can be approached with less morbidity. Many surgical approaches have been described with the most common being the retromandibular, submandibular, and preauricular approaches [55]. A nerve stimulator can be helpful in identifying branches of the facial nerve during the dissection. A prospective study compared the effect on facial symmetry after either closed or open treatment of mandibular condylar process fractures [56]. It was found that treatment by closed methods led to asymmetries characterized by shortening of the face on the side of the injury. The loss of posterior height on the side of fracture is an adaptation that helps re-establish a new temporomandibular articulation. Loss of facial height on the affected side can lead to compensatory canting of the occlusal plane. Treatment of condylar process fractures should be individualized. Many factors, including the patient's own preference, should be considered. Whether surgical or nonsurgical treatment is chosen, we recommend early mobilization during the healing process.

8.1. Pediatric fractures

The management of pediatric fractures is complicated by the presence of deciduous teeth and the growing mandible. Children tend to be less tolerant of MMF. An acrylic splint can be helpful in managing mandibular fractures in children. [Figure 15]

Figure 15. Intraoperative view of use of acrylic splint in managing mandibular fractures in children.

This can be used without MMF to allow early postoperative physiotherapy to avoid ankylosis and/or growth disturbances, which are more common in pediatric patients [57].

Condylar process fractures in children younger than age 12 should be treated by closed methods in most instances. Damage to the condylar growth center can result in delayed growth and in facial asymmetry. Dalhlstrom et al. showed good restitution of the TMJ and no growth disturbances in 14 children, 5 years after nonsurgical treatment of their fractures [58].

Early animal studies showed that there was little sacrifice of mandibular growth and symmetry with induced condyle fractures when treated with closed reduction. Boyne compared three methods of fracture treatment in Rhesus monkeys and found no difference between those treated with internal fixation (wire), MMF, or no treatment [59].

8.2. Edentulous fractures

Fractures of the edentulous mandible most commonly involve the body region. Changes that occur with age include decreased osteogenesis, mandibular atrophy, and reduced blood supply. With age the inferior alveolar artery contributes less and less to perfusion of the mandible [60]. The lack of teeth makes it difficult to adequately reduce the fracture because MMF cannot be used to help reduce the bony fragments. It is important to define more carefully 'edentulous' mandibles, since the literature shows that only those severely atrophic mandibles with a bone height less than 10 mm stand out as a 'difficult' or special problem. Above these heights, normal miniplate fixation may be effective.

These fractures can be treated by either open or closed reduction methods. Closed techniques often involve wiring a mandibular prosthesis in place with circumandibular wires to stabilize the fracture. The second Chalmers J. Lyons Academy Study of fractures of the edentulous mandible reviewed 167 fractures in 104 edentulous mandibles. Fifteen percent of the patients developed a delayed fibrous union and 26% treated by closed reduction techniques had problems with union. The fewest complications occurred with the patients who received transfacial open reduction and internal fixation [61].

In addition to adequate reduction and stabilization of the fractured segments, the successful management of fractures involving the edentulous mandible requires that consideration be given to the amount of bone present. When the mandible is severely atrophic, it is possible that healing will not occur even if open reduction and internal fixation principles are properly applied. In some circumstances, treatment consists of simultaneous bone graft reconstruction at the time of fracture repair. This is also appropriate treatment for patients presenting with non-union of an edentulous fracture. In most cases plans for definitive prosthetic reconstruction are delayed until full healing of the bony site has occurred. Some authors, however, do advocate early reconstruction with bone grafting and osseo-integrated implants. [62]

Treatment methods for edentulous mandible fractures

- Closed reduction with the use of prosthetics (existing dentures or Gunning splints)

- External fixation
- Wire fixation
- Open reduction with internal fixation:

1. reconstruction plates (2.3-2.7 mm diameter screws)
2. mandible fixation plates (2.0-2.4 mm diameter screws):
    - dynamic compression plates
    - plates at both inferior and superior borders of the fracture
3. bone grafting and miniplate fixation

8.3. Infected fractures

Infected mandibular fractures resulting from a delay in treatment can present certain challenges. Treatment by MMF, external fixation, and rigid internal fixation has been recommended. The goals of treating mandibular fractures that are complicated by an infection include resolution of the infection and achievement of bony union. Rigid internal fixation can predictably be used for treatment of infected mandibular fractures [63]. Fracture union and resolution can be attained with fixation. Even if the infection is prolonged, the fracture can heal as long as rigidity of the fracture is maintained. The plate can be removed after the bony union is achieved. Alternatively, if it is noted that plate or screw loosening has occurred and rigidity between the osseous segments is lacking, a nonunion is likely. The patient should be treated to regain rigidity and eliminate any loose hardware.

9. Complications

Complications following mandible fracture repair may be the result of the severity of the original injury, the surgical treatment or patient non-compliance with the postoperative regimen. Problems related to mandibular fractures present unique challenges to even the most experienced surgeon. The consequences of complications may include problems in anatomic form (cosmetic deformity) or residual functional disturbances. Complication rates have improved since the early days of wire fixation, but even the most sound fixation techniques can yield undesirable results. Probably no other specific area of oral and maxillofacial surgery has been studied in more detail than the mandible fracture. Despite this fact, little prospective evidence is available regarding the outcomes of the various treatment modalities. Retrospective studies offer some evidence that certain techniques have independently done better than others, but better prospective studies are needed to further evaluate and compare these techniques.

9.1. Malocclusion and malunion

Improper alignment of the fracture fragments results in facial asymmetry and malocclusion. Malunions occur in 0–4.2% of fractures. Malunions result from improper reduction, insufficient immobilization, poor patient compliance, and the improper use of rigid internal fixation [64]. Residual arch form deformity following the surgical repair of a mandibular fracture is often the result of inadequate reduction. Failure to re-establish the anatomic configuration of the arch form result in occlusal prematurities and misalignment which will compromise masticatory function. Clinicians treating mandibular fractures need to be familiar with dental anatomy and occlusion in order to balance the functional forces appropriately. Preoperative study models (with or without model surgery) and splint fabrication may aid in fracture reduction in some cases. Poor apposition of fracture segments may results from a delay in or an absence of treatment, inadequate treatment, inability to align segments secondary to the presence of a foreign body or loss of bony landmarks. Malaligned fracture segments noted early in the postoperative course may be corrected by returning to the operating room for removal of the hardware and repeat reduction with internal fixation. When the discrepancies are not caught early, the fracture segments will go on to heal in the improper anatomic position (malunion). Significant malunions of the mandible will produce asymmetry and/or functional disturbances and can only be resolved through carefully planned osteotomies for reconstruction of the mandibular arch form. The most common cause of failure of fracture healing (non-union) is residual mobility across the fracture site. Movement of the bone ends will disrupt the fibrovascular structures, decrease the recruitment of osteoprogenitor cells and allow for fibrous tissue ingrowth instead of bony healing. Other contributors to fracture non-union include impaired healing capacity secondary to illness, tobacco use and infection. Non-union of mandibular fractures requires reoperation to excise any fibrous tissue within the fracture gap in combination with application of bone fixation. In some instances, there may be loss of bone, producing a continuity defect which will require bone graft reconstruction. Treatment strategies vary from patient to patient and with each surgeon's experience in using different techniques.

Comprehensive management of malocclusion and malunion requires a full orthognathic workup. Standard osteotomies are performed at a different site from the malunion for restoration of preinjury occlusion. In general, treatment involves osteotomies at the healed fracture sites if they are within the dental arch, whereas fractures proximal to the dental arch are treated with ramus procedures.

9.2. Infection

Infection, the most common complication of mandibular fractures, is reported in 0.4–32% of all cases [64]. The potential for infection is always a consideration when treating fractures of the mandible, especially when there is communication with the oral cavity (e.g. compound fracture). Other risk indicators for increased chance of infection include active substance abuse and non-compliance with postoperative regimens [65] A significant delay in treatment has also been associated with an increase in infection rates. [66] Other factors include mobility of the segments across the fracture site or loosening of screws

securing the plate. Poor plate adaptation, inadequate cooling during drilling, or placing the screw in the fracture line itself can lead to increased chance of infection developing. Leaving a tooth in the line of fracture can also lead to an increased incidence of complications. Of the facial bones, the mandible is the most frequently infected region following surgical intervention for traumatic injury. This is likely due to instability of the segments from muscular actions on the proximal and distal segments and the density of the bone. Manifestations of infection include cellulitis, abscess formation, fistula, osteomyelitis and rarely necrotizing fasciitis. [Figure 16]

Figure 16. Patient with non-union of body fracture of edentulous mandible; exposed necrotic bone with pus discharge can be noticed.

Management begins with clinical examination and plain radiographic studies to assess the status of the fractured segments and the hardware. The use of CT and MRI is appropriate when there is concern that the infection involves the surrounding soft tissues of the neck. Specimens for bacterial culture and sensitivity studies should be done as early as possible in the patient's clinical course.

Infections involving rigid fixation of mandibular fractures may not necessitate plate removal (minor) or may be major and require plate removal (loose hardware). Treatment of the infection requires antibiotics and determination of the stability of the fracture. The fracture site can heal and develop union in the face of infection as long as there is rigidity across the fracture site.

9.3. Delayed union and nonunion

Delayed union is failure of fracture union by 2 months. Infection, mobility, systemic disease, advanced age, and mandibular atrophy are contributing factors [64]. Delayed union by definition means that the fracture will eventually heal without further surgery. Rigid internal

fixation carries a lower incidence of delayed union compared to nonrigid fixation: 0–2.8% versus 1–4.4% [64].

Nonunion is the failure of a fracture to unite owing to arrested healing and requiring additional treatment to achieve fracture union. Mobility is the major cause of nonunion. More than 33% of nonunions involve infection [64]. Large bony gaps, traumatized devitalized tissue, older age, intervening soft tissue, and systemic disease all can contribute to nonunion. Mobility at the fracture site is manifested in nonunions. Debridement of the fracture fragments, bone grafting, usually from the iliac crest, and rigid fixation with internal or external fixation usually achieves fracture union. [Figure 17]

Figure 17. Placement of a Locking Reconstuction Plate for treatment of a mandibular non-union site.

9.4. Nerve injury

Sensory nerve injury, particularly of the inferior alveolar and mental nerves, commonly occurs with mandibular fractures [67]. In 11–59% of displaced mandibular fractures there is sensory nerve injury at diagnosis [68,69]. Most injuries are neuropraxias secondary to stretching or compression and resolve spontaneously. Causes of inferior alveolar or mental nerve injury are displaced fractures, delay in treatment, and improper use of drill or screws. Facial nerve dysfunction infrequently results from mandibular trauma. Damage to the facial nerve in temporal bone fractures can lead to paralysis. Retrograde edema distal to the geniculate ganglion can cause temporary facial nerve loss after condylar fractures. Condylar dislocations can cause facial nerve injury distal to the stylomastoid foramen. Injury to the facial nerve branches usually takes place iatrogenically during surgical treatment, though lateral displacement of the condyle can cause facial nerve injury [69]. The marginal mandibular branch is the one usually injured. The surgical anatomy of this branch has been well described by Dingman and Grabb [70], and meticulous dissection under the platysma in the region of the facial artery with identification of the branches of the marginal mandibular nerve can prevent injury to this nerve [71]. The design of the preauricular incision in the approach to the condyle can be accomplished by observing the landmark work of Al-Kayat and Bramley [72].

Patients with a paresthesia following a mandibular fracture should be observed during the postoperative period and the level of neurosensory return (subjective) is documented. In cases where patients report no improvement in their level of sensation after 6-8 weeks, the clinician may consider obtaining baseline nerve function data using objective testing. Objective neurosensory testing before 6 weeks may be of limited value because it is difficult to discern a Sunderland Class I injury (excellent prognosis without surgery) from a Sunderland Class V injury (poor prognosis without surgery) that early in the postoperative course. In the case of Sunderland Class IV and V injuries (equivalent to axonotmesis and neurotmesis) surgical repair is considered between 3 and 6 months [73]. Immediate management of inferior alveolar nerve injury at the time of mandibular fracture repair has been advocated in situations where there is displacement at the fracture site and anesthesia [74]. Although a more aggressive approach may have merit, it would be limited to situations where there is an observed transection of the nerve. Immediate decompression and exploration are not necessary in less severe nerve injuries (Sunderland Class I, II, III) and surgical maneuvers used to expose the nerve trunk (decortication) may compromise subsequent fracture healing

Author details

Amrish Bhagol[1*], Virendra Singh[1] and Ruchi Singhal[2]

*Address all correspondence to: bhagol.amrish@gmail.com

1 Department of Oral and Maxillofacial Surgery, Post Graduate Institute of Dental Sciences, Pt. B.D. Sharma University of Health Sciences, Rohtak, Haryana, India

2 Department of Pedodontic and Preventive Dentistry, Post Graduate Institute of Dental Sciences, Pt. B.D. Sharma University of Health Sciences, Rohtak, HaryanaIndia,

References

[1] The Edwin Smith Surgical Papyrus (trans. Breasted JH) University of Chicago Press, Chicago 1930

[2] Lipton JS. Oral surgery in ancient Egypt as reflected in the Edwin Smith Papyrus. Bulletin of the History of Dentistry 1982; 30: 108

[3] Hippocrates. Oeuvres completes (English trans. Withington ET) Cambridge, MA 1928

[4] Salicetti G. Cyrurgia 1275

[5] Prevost N. Translation of Salicetti's Cyrurgia. Lyons, France 1492

[6] Gilmer TL. A case of fracture of the lower jaw with remarks on the treatment. Archives of Dentistry 1887; 4: 388

[7] Ivy RH. Fracture of condyloid process of the mandible. Annals of Surgery 1915; 61: 502

[8] Buck G. Fracture of the lower jaw with replacement and interlocking of the fragments. Annalist NY 1846; 1:245.

[9] Dorrance GM, Bransfield JW. The History of Treatment of Fractured Jaws, vols 1 and 2. Washington, DC, 1941.

[10] Gilmer TL. Fractures of the inferior maxilla. Ohio State J Dent Sci 1881-1882;1: 309;2:14,57, 112.

[11] Luhr HG: Zur Stabilen osteosynthese bei Unterkeiferfrakturen. Dtsch Zahnarztl Z 1968;23: 754.

[12] Spiessl B. New concepts in maxillofacial bone surgery. Springer-Verlag, Berlin 1976

[13] Michelet FX, Deymes J. Dessus B. Osteosynthesis with miniaturized screwed plates in maxillofacial surgery. J Maxillofac Surg 1973; 1: 79.

[14] Champy M, Lodde JP, Schmitt R, et al. Mandibular osteosynthesis by miniature screwed plates via a buccal approach. J Maxillofac Surg 1978;6: 14.

[15] Suuronen R. Biodegradable fracture fixation devices in maxillofacial surgery. International Journal of Oral and Maxillofacial Surgery 1993;22: 50

[16] Eppley BL, Prevel CD, Sarver D. Resorbable bone fixation: its potential role in craniomaxillofacial trauma. Journal of Craniomaxillofacial Trauma 1996;2: 56

[17] Chayra GA, Meador LR, Laskin OM. Comparison of panoramic and standard radiographs for the diagnosis of mandibular fractures. Journal of Oral and Maxillofacial Surgery 1985;44; 677

[18] Juniper RP, Awty MD. The immobilization period for fractures of the mandibular body. J Oral Surg 1973; 36:157.

[19] Armaratunga NA de S. The relation of age to the immobilization period required for healing of mandibular fractures. J Oral Maxillofac Surg 1987; 45:111.

[20] Ellis E. The effects of mandibular immobilization on the masticatory system: a review. Clin Plast Surg 1989; 16:133–146.

[21] Geiser M, Trueta J. Muscle action, bone rarefaction and bone formation: an experimental study. J Bone Joint Surg 1958; 40B:282–311.

[22] Iizuka T, Lindqvist C. Rigid internal fixation of fractures in the angular region of the mandible: an analysis of factors contributing to different complications. Plast Reconstr Surg 1993; 91:265–271.

[23] Raveh J, Vuillemin T, Ladrach K, et al. Plate osteosynthesis of 367 mandibular fractures. J Craniomaxillofac Surg 1987; 15:244–253.

[24] Herford AS, Ellis E. Use of a locking reconstruction plate=screw system for mandibular surgery. J Oral Maxillofac Surg 1998; 56(11):1261–1265.

[25] Soderholm A-L, Lindqvist C, Skutnabb K, et al. Bridging of mandibular defects with two different reconstruction systems: an experimental study. J Oral Maxillofac Surg 1991; 49:1098.

[26] Niederdellman H, Shetty V. Solitary lag screw osteosynthesis in the treatment of fractures of the angle of the mandible: a retrospective study. Plast Reconstr Surg 1987; 80(1):68–74.

[27] Forrest CR. Application of minimal-access techniques in lag screw fixation of fractures of the anterior mandible. Plast Reconstr Surg 1999; 104:2127–2134.

[28] Edwards TJ, David DJ. A comparative study of miniplates used in the treatment of mandibullar fractures. Plast Reconstr Surg 1996; 97(6):1150–1157.

[29] Singh V, Kumar I, Bhagol A. Comparative evaluation of 2.0-mm locking plate system vs 2.0-mm nonlocking plate system for mandibular fracture: a prospective randomized study. Int J Oral Maxillofac Surg. 2011; 40(4):372-7.

[30] Potter J, Ellis E. Treatment of mandibular angle fractures with a malleable noncompression miniplate. J Oral Maxillofac Surg 1999; 57:288–292.

[31] Kim YK, Nam KW. Treatment of mandible fractures using low-profile titanium miniplates: preliminary study. Plast Reconstr Surg 2001; 108:38–43.

[32] Bos RRM, Boering G, Rozema FR, et al. Resorbable poly (L-lactide) plates and screws for the fixation of zygomatic fractures. J Oral Maxillofac Surg 1987; 45:751.

[33] Laughlin RM, Block MS, Wilk R, Malloy RB, Kent JN. Resorbable plates for the fixation of mandibular fractures: a prospective study. J Oral Maxillofac Surg. 2007 ;65(1): 89-96

[34] Farmand M. Experiences with the 3-D miniplate osteosynthesis in mandibular fractures. Fortschr Kiefer Gesichtschir. 1996; 41:85-7.

[35] Singh V, Puri P, Arya S, Malik S, Bhagol A. Conventional versus 3-Dimensional Miniplate in Management of Mandibular Fracture -A Prospective Randomized Study. Otolaryngol Head Neck Surg. May 2012 (Online Published)

[36] Neal DC, Wagner W, Alpert B. Morbidity associated with teeth in the line of mandibular fractures. J Oral Surg 1978; 36:859.

[37] Shetty V, Freymiller E. Teeth in the line of fracture: a review. J Oral Maxillofac Surg 1989; 47:1303.

[38] Zallen RD, Curry JT. A study of antibiotic usage in compound mandibular fractures. J Oral Surg 1975; 33:431.

[39] Champy M, Lodde JP, Schmitt R, et al.Mandibular osteosynthesis by miniature screwed bone plates via a buccal approach. J Oral Maxillofac Surg 1978; 6:14.

[40] Chritah A, Lazow SK, Berger J. Transoral 2.0-mm miniplate fixation of mandibular fractures plus 2 weeks maxillomandibular fixation: A prospective study. J Oral Maxillofac Surg 2002; 60:167-170.

[41] Ellis E 3rd. Lag screw fixation of mandibular fractures. J Craniomaxillofac Trauma 1997; 3: 16-26

[42] Fuselier JC, Ellis E, Dodson TB. Do mandibular third molars alter the risk of angle fractures? J Oral Maxillofac Surg 2002; 60(5):514–518.

[43] Shubert W, Kobienia BJ, Pollock RA. Cross-sectional area of the mandible. J Oral Maxillofac Surg 1997; 55:689–692.

[44] Becker R. Stable compression plate fixation of mandibular fractures. Br J Oral Surg 1974; 12:13–23.

[45] Ellis E III. Treatment methods for fractures of the mandibular angle. Int J Oral Maxillofac Surg 1999; 28(4):243–252.

[46] Singh V, Gupta M, Bhagol A. Is a Single Miniplate at the Inferior Border Adequate in the Management of an Angle Fracture of the Mandible? Otolaryngol Head Neck Surg. 2011;145(2):213-6.

[47] Ellis E, Throckmorton G. Facial symmetry after closed and open treatment of fractures of the mandibular condylar process. J Oral Maxillofac Surg 2000; 58(7):719–728.

[48] Martin M, Lee C. Endoscopic mandibular condyle fracture repair. Atlas Oral Maxillofac Surg Clin North Am. 2003;11(2):169-78.

[49] Singh V, Bhagol A, Goel M, Kumar I, Verma A. Outcomes of Open Versus Closed Treatment of Mandibular Subcondylar Fractures: A Prospective Randomized Study. J Oral Maxillofac Surg. 2010;68(6):1304-9

[50] Zide MF, Kent JN. Indications for open reduction of mandibular condyle fractures. J Oral Maxillofac Surg 1983; 41:89.

[51] Mikkonen P, Lindqvist C, Pihakari A, et al: Osteotomy–osteosynthesis in displaced condylar fractures. Int J Oral Maxillofac Surg 1989; 18:267.

[52] Klotch DW, Lundy LB. Condylar neck fractures of the mandible. Otolaryngol Clin North Am 1991; 24:181.

[53] Widmark G, Bagenholm T, Kahnberg KE, et al: Open reduction of subcondylar fractures. Int J Oral Maxillofac Surg 1996; 25:107.

[54] Bhagol A, Singh V, Kumar I, Verma A. Prospective Evaluation of a New Classification System for the Management of Mandibular Subcondylar Fractures.. J Oral Maxillofac Surg. 2010;68(6):1304-9

[55] Ellis E, Dean J. Rigid Fixation of mandibular condyle fractures. Oral Surg Oral Pathol 1993; 76:6.

[56] Ellis E, Throckmorton G, Palmieri C. Open treatment of condylar process fractures: assessment of adequacy of repositioning and maintenance of stability. J Oral Maxillofac Surg 2000; 58:27–34.

[57] Kaban LB, Mulliken MD, Murray JE. Facial fractures in children: an analysis of 122 fractures in 109 patients. Plast Reconstr Surg 1977; 59:15.

[58] Dahlstrom L, Kahnberg KE, Lindahl. 15 years follow-up on condylar fractures. Int J Oral Maxillofac Surg 1989; 18(1):18–23.

[59] Boyne PJ. Osseous repair and mandibular growth after subcondylar fractures. J Oral Surg 1967; 25(4):300–309.

[60] Bradley JC. Age changes in the vascular supply of the mandible. Br Dent J 1972; 132(4):142–144.

[61] Bruce RA, Ellis E III. The second Chalmers J Lyons Academy study of fractures of the edentulous mandible. J Oral Maxillofac Surg 1993; 51(8):904–911.

[62] Eyrich GK, Gratz Kw, Sailer HF. Surgical treatment ofthe edentulous mandible. Journal of Oral and Maxillofacial Surgery 1997;55: 1081-1087

[63] Koury M, Ellis E. Rigid internal fixation for treatment of infected mandibular fractures. J Oral Maxillofac Surg 1992; 50:434–443.

[64] Koury M. Complications of mandibular fractures. In: Kaban LB, Pogrell AH, Perrot D, eds. Complications in Oral and Maxillofacial Surgery. Philadelphia: WB. Saunders, 1997:121–146.

[65] Passeri LA, Ellis E, Sinn DP. Relationship of substance abuse to complications with mandibular fractures. Journal of Oral and Maxillofacial Surgery 1993;51: 22-25

[66] Moulton-Barrett R, Rubinstein AJ, Salzhauer MA et al. Complications of mandibular fractures. Annals of Plastic Surgery 1998;41 :258-263

[67] Thaller SR. Management of mandibular fractures. Arch Otolaryngol Head Neck Surg 1994; 120:44.

[68] Izuka T, Lindquist C. Sensory disturbances associated with rigid internal fixation of mandibular fractures. J Oral Maxillofac Surg 1991; 49:1264.

[69] Marchena JM, Padwa BL, Kaban LB. Sensory abnormalities associated with mandibular fractures: incidence and natural history. J Oral Maxillofac Surg 1998; 56:822–825.

[70] Dingman RO, Grabb WC. Surgical anatomy of the mandibular ramus of the facial nerve based on the dissection of 100 facial halves. Plast Reconstr Surg 1962; 29:266.

[71] Brusati R, Paini P. Facial nerve injury secondary to lateral displacement of the mandibular ramus. Plast Reconstr Surg 1978; 62(5):728–733.

[72] Al-Kayat A, Bramley PA. A modified pre-auricular approach to the temporomandibular joint and malar arch. Br J Oral Maxillofac Surg 1979.

[73] Zuniga JR. Advances in microsurgical nerve repair. Journal of Oral and Maxillofacial Surgery 1993; 51 (suppl I): 62-68

[74] Thurmuller P, Dodson TB, Kaban LB. Nerve injuries associated with facial trauma: natural history, management, and outcomes of repair. Oral and Maxillofacial Surgery Clinics of North America 2001; 13(2): 283-293

Chapter 15

Management of Midfacial Fractures

Sertac Aktop, Onur Gonul, Tulin Satilmis,
Hasan Garip and Kamil Goker

Additional information is available at the end of the chapter

http://dx.doi.org/10.5772/54644

1. Introduction

The management of midfacial fractures includes the treatment of facial fractures, dentoalveolar trauma, and soft-tissue injuries, as well as associated injuries, mainly of the head and neck [1]. The management of fractures of the maxillofacial complex remains a challenge for the oral maxillofacial surgeon, demanding both skill and expertise [2]. The success of treatment and implementation of preventive measures are more specifically dependent on epidemiologic assessments [3].Midfacial fractures can occur in isolation or in combination with other serious injuries, including mandibular, ophthalmologic, cranial, spinal, thoracic, and abdominal trauma, as well as upper and lower orthopedic injuries [4].The epidemiology of facial fractures varies in type, severity, and cause depending on the population studied. Differences among populations in the causes of maxillofacial fractures may be the result of differences in risk and cultural factors among countries, but are more likely to be influenced by the severity of injury [1,5]. The causes of maxillofacial fractures have changed over the past three decades, and they continue to do so. The main causes worldwide are traffic accidents, assaults, falls, sport-related injuries, and warfare [6-8]. Many articles pertaining to the incidence and causes of maxillofacial injuries have been published [1,4,7-10]. In 2003, Motamedi [7] reported the distribution of facial fractures as 72.9% mandibular, 13.9% maxillary, 13.5% zygomatic, 24.0% zygomatico-orbital, 2.1% cranial, 2.1% nasal, and 1.6% frontal injuries [Figure 1].

Causes of these maxillofacial injuries were automobile (30.8%) and motorcycle (23.2%) accidents, altercations (9.7%), sport (6.3%), and warfare (9.7%) [Figure 2].

The distribution of maxillary fractures was 54.6% Le Fort II, 24.2% Le Fort I, 12.1% Le Fort III, and 9.1% alveolar [7] [Figure 3].

According to Cook and Rowe [4], midfacial injuries occur most frequently in individuals aged 21–30 years (43%). The 11–20-year and 31–40-year age groups each account for 20% of these

INTECH
open science | open minds

© 2013 Aktop et al.; licensee InTech. This is a paper distributed under the terms of the Creative Commons Attribution License (http://creativecommons.org/licenses/by/3.0), which permits unrestricted use, distribution, and reproduction in any medium, provided the original work is properly cited.

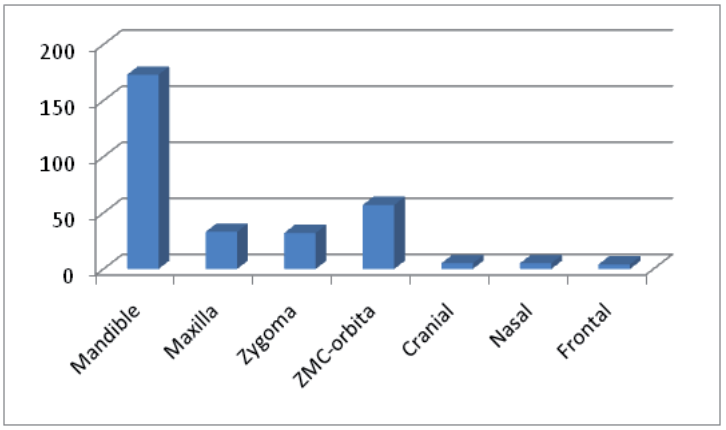

Figure 1. Fracture sites are shown for 237 maxillofacial trauma patients according to Motamedi

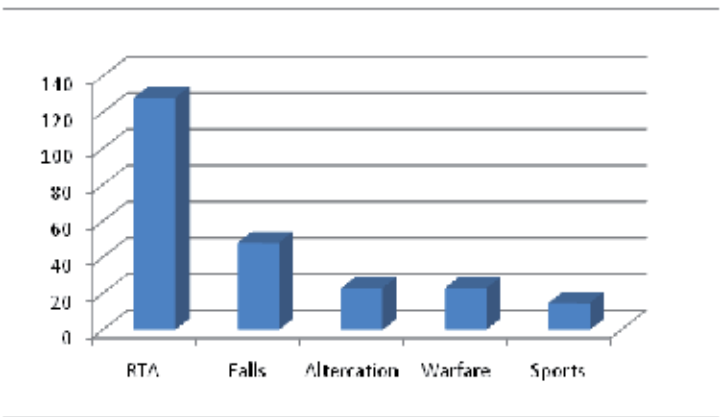

Figure 2. The causes of fracture for Motamedi's assessment of maxillofacial trauma patients

fractures. Most (83.1%) midfacial fractures occur in males, with the remainder (16.9%) occurring in females [4] [Figure 4].

Thoren [9] noted that injuries are associated with 25.2% of midfacial fractures. These injuries most commonly affect a limb (13.5%), followed by the brain (11.0%), chest (5.5%), spine (2.7%), and abdomen (0.8%) [9].

2. Surgical anatomy

The anatomy of the head is complex; the physical properties of the skin, bone, and brain differ markedly and the facial skeletal components articulate and interdigitate in a complex fashion, with the consequence that a given facial bone is rarely fractured without disrupting its

http://dx.doi.org/10.5772/54644

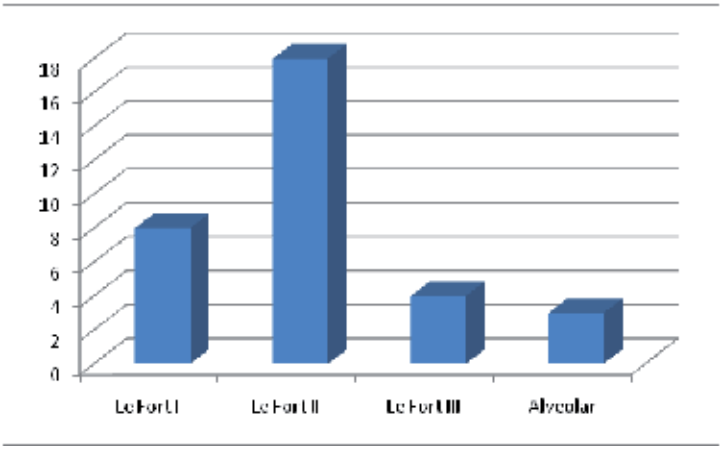

Figure 3. Distribution of maxillary fractures in Motamedi's assessment of maxillofacial trauma patients

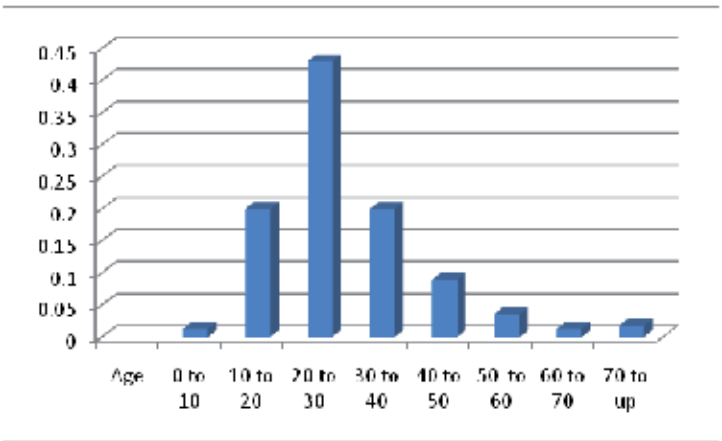

Figure 4. Age distribution of midfacial fracture patients according to Cook and Rowe.

neighbor [10]. The severity and pattern of a fracture depend on the magnitude of the causative force, impact duration, the acceleration imparted by impact to the affected part of the body, and the rate of acceleration change. The surface area of the impact site is also relevant [11,12]. The middle third of the facial skeleton is defined as an area bounded superiorly by a line drawn across the skull from the zygomaticofrontal suture, across the frontonasal and frontomaxillary sutures, to the zygomaticofrontal suture on the opposite side; and inferiorly by the occlusal plane of the maxillary teeth, or, in an edentulous patient, by the maxillary alveolar ridge. It extends posteriorly to the frontal bone in the superior region and the body of the sphenoid in the inferior region, and the pterygoid plates of the sphenoid are usually involved in any severe fracture [13].

The middle third of the facial skeleton comprises the following bones [14] [Figure 5]:

- Two maxillae
- Two zygomatic bones
- Two zygomatic processes of the temporal bones
- Two palatine bones
- Two nasal bones
- Two lacrimal bones
- The vomer
- The ethmoid and attached conchae
- Two inferior conchae
- The pterygoid plates of the sphenoid

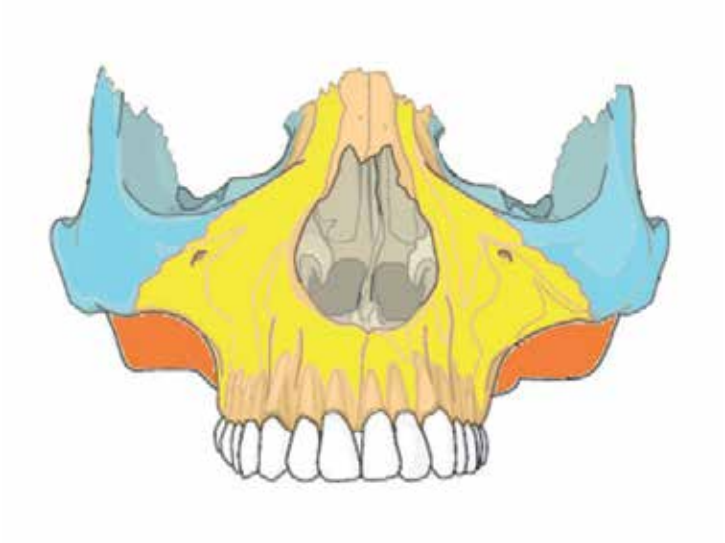

Figure 5. Bones of the middle third of the facial skeleton

The frontal bone and the sphenoid body and greater and lesser wings are not usually fractured. In fact, they are protected to a considerable extent by the cushioning effect achieved as the fracturing force crushes the comparatively weak bones comprising the middle third of the facial skeleton [13].

3. Initial management of the midfacial trauma patient

The initial assessment and management of a patient's injuries must be completed in an accurate and systematic manner to quickly establish the extent of any damage to vital life-support

systems. Patients are assessed and treatment priorities are established based on patients' injuries and the stability of their vital signs. Injuries can be divided into three general categories: severe, urgent, and non-urgent. Severe injuries are immediately life threatening and interfere with vital physiologic functions; examples are compromised airway, inadequate breathing, hemorrhage, and circulatory system damage or shock. These injuries constitute approximately 5% of patient injuries but represent more than 50% of injuries associated with all trauma deaths. Urgent injuries make up approximately 10–15% of all injuries and present no immediate threat to life. Patients with this type of injury may present with damage to the abdomen, orofacial structures, chest, or extremities that requires surgical intervention or repair, but their vital signs are stable. Non-urgent injuries account for approximately 80% of all injuries and are not immediately life threatening. Patients with this type of trauma eventually require surgical or medical management, although the exact nature of the injury may not become apparent until significant evaluation and observation are performed. The goal of initial emergency care is to provide life-saving and support measures until definitive care can be initiated. Any trauma victim with altered consciousness must be considered to have a brain injury. The level of consciousness is assessed by serial Glasgow Coma Scale evaluations [15] [Table 1].

Action	Score
Eye Opening	4
Spontaneous	3
To speech	2
To pain	1
None	6
Motor Response	5
Obeys	4
Localises pain	3
Withdraws from pain	2
Flexion to pain	1
Extension to pain	5
None	4
Verbal Response	3
Oriented	2
Confused	1
Inappropriate	
Incomprehensible	
None	

Adapted from Teasdale and Jennett [15]. A patient's score determines the category of neurologic impairment: 15 = normal, 13 or 14 = mild injury, 9–12 = moderate injury, and 3–8 = severe injury.

Table 1. Glasgow Coma Scale.

Other signs of brain damage include restlessness, convulsions, and cranial nerve dysfunction (*e.g*. a nonreactive pupil). The classic Cushing triad (hypertension, bradycardia, and respiratory disturbances) is a late and unreliable sign that usually closely precedes brain herniation. Hypotension is rarely due to head injury alone. Patients suspected of sustaining head trauma should not receive any premedication that will alter their mental status (*e.g*. sedatives or analgesics) or neurologic examination (*e.g*. anticholinergic-induced pupillary dilation).

3.1. Primary Survey: ABCs

During the primary survey, life-threatening conditions are identified and reversed quickly. This period calls for quick and efficient evaluation of the patient's injuries and almost simultaneous life-saving intervention. The primary survey progresses in a logical manner based on the ABC pneumonic: airway maintenance with cervical spine control, breathing and adequate ventilation, and circulation with control of hemorrhage. The letters D and E have also been added: a brief neurologic examination to establish the degree of consciousness, and exposure of the patient *via* complete undressing to avoid overlooking injuries camouflaged by clothing. Maxillofacial injuries may result in airway compromise caused by any of several factors: blood and secretions, a mandibular fracture that allows the tongue to fall against the posterior wall of the pharynx, a midfacial injury that causes the maxilla to fall posteroinferiorly into the nasopharynx, and foreign debris such as avulsed teeth or dentures. A large tonsillar suction tip should be used to clear the oral cavity and pharynx. The establishment of an oral airway assists with tongue position; however, care must always be taken to avoid manipulation of the neck and to provide access to the oral cavity and dentition for the reduction and fixation of any fractures requiring a period of intermaxillary fixation. Neither midfacial fractures nor cerebrospinal rhinorrhea are contraindications to nasal intubation. Care should be taken to pass the tube along the nasal floor into the pharynx, and the tube should be visualised before tracheal intubation. Hypertension or tachycardia during intubation can be attenuated with the intravenous administration of lidocaine or fentanyl. Intubation while the patient is awake causes a precipitous rise in intracranial pressure. Nasal passage of an endotracheal or nasogastric tube in a patient with a basal skull fracture risks cribriform plate perforation and cerebrospinal fluid infection. Slight elevation of the head will improve venous drainage and decrease intracranial pressure.

3.2. Physical examination

The physical examination should begin with an evaluation of soft-tissue injuries. Lacerations should be debrided and examined for disruption of vital structures, such as the facial nerve or parotid duct. The eyelids should be elevated to allow evaluation of the eyes for neurologic and ocular damage. The face should be symmetric, without discolouration or swelling suggestive of bony or soft-tissue injury. The bony landmarks should be palpated, beginning with the supraorbital and lateral orbital rims and followed by the infraorbital rims, malar eminences, zygomatic arches, and nasal bones. Any steps or irregularities along the bony margin are suggestive of a fracture. Numbness over the area of distribution of the trigeminal nerve is usually noted with fractures of the facial skeleton. The oral cavity should be inspected and

evaluated for lost teeth, lacerations, and occlusal alterations. Any tooth lost at the time of injury must be accounted for because it may have been aspirated or swallowed. The neck should also be examined for injury. Subcutaneous air may be visualised if massive injury is present; if subtle, it may be detected only by palpation. The presence of air in the soft tissue may be the result of tracheal damage. Any externally expanding edema or hematoma of the neck must be observed closely for continued expansion and airway compromise. Carotid pulses should be assessed. Palpation should be performed to detect abnormalities in the contour of the thyroid cartilage and to confirm the midline position of the trachea in the suprasternal notch.

3.3. Preoperative considerations

Patients with midfacial trauma often pose the greatest airway challenges to the anaesthesiologist. Preoperative airway evaluation must be detailed and thorough. Particular attention should be focused on jaw opening, mask fit, neck mobility, maxillary protrusion, macroglossia, dental pathology, nasal patency, and the existence of any intraoral lesion or debris. If any forewarning sign of problems with mask ventilation or endotracheal intubation is observed, the airway should be secured prior to anaesthesia induction. This process may involve fibreoptic nasal or oral intubation or tracheostomy. Nasal intubation with a preformed or straight tube with a flexible angle connector is usually preferred in dental or oral surgery. The endotracheal tube can then be directed cephalically and connected to breathing tubes passing over the patient's head.

3.4. Intraoperative management

Reconstructive surgery can be associated with substantial blood loss. Strategies to minimise bleeding include a slight head-up position, controlled hypotension, and local infiltration with epinephrine solutions. Because the patient's arms are typically tucked along the sides of the body, at least two intravenous lines should be established prior to surgery. This step is especially important if one line is used for the delivery of an anaesthetic or hypotensive agent. An arterial line can be helpful in cases of marked blood loss, as a surgeon leaning against the patient's arm may interfere with non-invasive blood pressure cuff readings. An oropharyngeal pack is often placed to minimize the amount of blood and other debris reaching the larynx and trachea. Due to the proximity of the airway to the surgical field, the anaesthesiologist's location is more remote than usual. This situation increases the likelihood of serious intraoperative airway problems, such as endotracheal tube kinking, disconnection, or perforation by a surgical instrument. Airway monitoring of end-tidal CO_2, peak inspiratory pressures, and esophageal stethoscope breath sounds assumes increased importance in such cases. At the end of the surgery, the oropharyngeal pack must be removed and the pharynx suctioned. Although the presence of some bloody debris during initial suctioning is not unusual, repeated efforts should be less productive. If there is a chance of postoperative edema involving structures that could potentially obstruct the airway (e.g. the tongue), the patient should be left intubated. Otherwise, extubation can be attempted once the patient is fully awake and shows no sign of continued bleeding. Appropriate cutting tools should be placed at the bedside of a patient with

intermaxillary fixation (*e.g.* maxillomandibular wiring), in case of vomiting or other airway emergency.

4. Dentoalveolar fractures

Fracture of the alveolar process is a common injury, comprising 2–8% of all craniofacial injuries. Nearby soft tissues and teeth are often damaged, increasing the severity of the situation [16]. The most common causes of such fractures are falls, motor vehicle accidents, sporting injuries, altercations, child abuse, and playground accidents. Direct or indirect force on a tooth, the latter transmitted most commonly through overlying soft tissues, may cause dentoalveolar injury [17].

4.1. Clinical examination

The practitioner should first ask when, where, and how the injury occurred and whether any treatment has been provided since that time. Answers to these simple questions could provide important clues. The patient's general health status should be known and his or her current situation examined when any nausea, vomiting, unconsciousness, amnesia, headache, or visual disturbance has occurred after injury. The examination of a patient's dentoalveolar injuries should assess the condition of the extraoral and intraoral soft tissues, jaws, and alveolar bone; establish the presence of any tooth displacement or mobility; and include tooth percussion and pulp testing [18]. Lacerations, abrasions, and contusions are very common in dentoalveolar injuries. Any vital structure crossing the line of laceration should be noted. The removal of blood clots, saline irrigation, and cleaning of the oral cavity facilitate inspection. Any foreign body within surrounding tissues should be examined carefully because bone or tooth fragments might have penetrated these areas, depending on the mechanism of injury. All fractured or missing teeth and restorations should be assumed to have been swallowed, aspirated, or lodged in adjacent structures. Alveolar segment fractures can be detected readily by visual examination and palpation. However, examination may be difficult because of post-injury pain. Sublingual ecchymosis on the mouth floor is pathognomonic for an underlying mandibular fracture. Step defects, crepitation, malocclusion, and gingival lacerations should raise the suspicion of possible underlying bony defects. The presence of fractured teeth should be noted. The depth of the fracture is very important. Complete mobility of the crown may indicate crown–root fracture. Post-injury occlusion should be checked and any displacement, intrusion, or luxation should be examined carefully. Percussion tests to determine sensitivity and pulp vitality should be performed to rule out periodontal ligament injury and many types of tooth fracture.

4.2. Imaging

Radiographic studies should be performed before intraoral manipulation. Radiography should determine the presence of root or jaw fracture, degree of extrusion or intrusion and its relationship to possible existing tooth germs, extent of root development, and presence of tooth

http://dx.doi.org/10.5772/54644

fragments and foreign bodies lodged in soft tissues. The combination of periapical, occlusal, and panoramic radiographs is used most frequently for the detection of damage to underlying tissues. Periapical radiographs provide the most detailed information about root fractures and tooth dislocation. Occlusal radiographs, however, provide larger fields of view and nearly the same level of detail as periapical radiographs; they are also very useful for the detection of foreign bodies. Panoramic radiographs provide useful screening views and visualize fractures of the mandible, maxilla, alveolar ridges, and teeth. Computed tomography (CT) offers insufficient resolution for the diagnosis of dental trauma, but cone-beam CT technology provides sufficient resolution to serve as a valuable tool in the diagnosis of various dental injuries [17,19,20].

4.3. Classification

The most commonly used simple and comprehensive classification of dentoalveolar injuries was developed by Andreasen [21] [Figure 6].

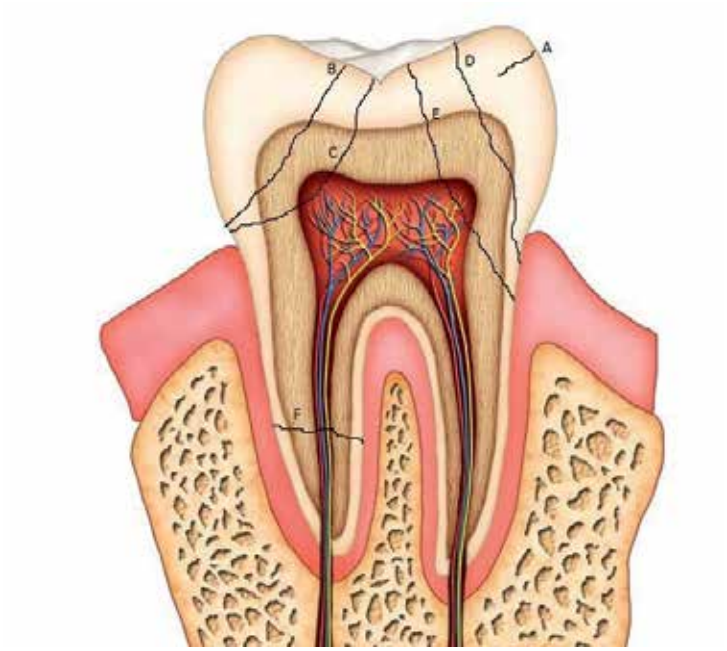

Figure 6. Diagram of Andreasen's classification

Dental tissues and pulp

- Simple crown infraction (crack in the tooth without loss of tooth substance)
- Uncomplicated crown fracture (confined to enamel, or enamel and dentine, with no root exposure)
- Complicated crown fracture (pulp exposure)

- Uncomplicated crown–root fracture (involving the enamel, dentine, and cementum without pulp exposure)
- Complicated crown–root fracture (involving the enamel, dentine, and cementum with pulp exposure)
- Root fracture (involving the dentine and cementum with pulp exposure)

Injuries to periodontal tissues

- Concussion: injury to the periodontium producing sensitivity to percussion without tooth loosening or displacement
- Subluxation: the tooth is loosened but not displaced
- Extrusive luxation, lateral luxation, intrusive luxation
- Avulsion: tooth displacement without accompanying comminution or fracture of the alveolar socket

Injuries to the supporting bone

- Comminution of the alveolar housing, often with intrusive or lateral luxation
- Fracture of a single wall of an alveolus
- Fracture of the alveolar process *en bloc* in a dentate patient; the fracture line does not necessarily extend through a tooth socket
- Fracture involving the main body of the mandible or maxilla

4.4. Treatment

The aim of dentoalveolar fracture treatment is to re-establish the normal form and function of the masticatory system. The involvement of pulp tissue makes a great difference in the treatment protocol.

4.4.1. Dental tissues and pulp

Simple crown infractions do not require treatment. Multiple cracks can be sealed with restorative materials to prevent staining. For uncomplicated crown fractures affecting only the enamel, grinding of the sharp edges is one possible solution. In cases of extensive enamel loss, a composite restoration may be used for recontouring. If a considerable amount of dentine is exposed, it should be covered with glass ionomer as an emergency treatment, and permanent composite restoration with bonding agents can be performed immediately or at a later stage. If the missing fragment is found, bonding to the tooth can be attempted with dentine bonding agents. Periodic follow-up visits should be scheduled to monitor pulp vitality. The management of complicated crown fractures is more challenging. If the exposed pulp tissue is vital, pulp capping or pulpotomy should be performed in cases without extensive crown loss. In cases of severe loss of crown substance or a lengthy interval between injury and treatment, pulp extirpation should be performed *via* $Ca(OH)_2$ application in the root canal. Permanent

root canal filling is carried out later in such cases. If the exposed pulp tissue is already necrotic, $Ca(OH)_2$ should be applied immediately after canal debridement. The course of treatment for uncomplicated crown–root fractures depends on the fracture location. An intact coronal fragment must be removed and inspected carefully to determine whether restoration of the remaining fragment is possible. If the fracture does not extend too far apically, the remaining fragment is suitable for restoration, and the pulp has not been exposed, the treatment protocol is the same as described above for crown fractures. Gingivectomy, ostectomy, or orthodontic extrusion might be required later for tooth restoration. In complicated crown–root fractures, pulp extirpation and $Ca(OH)_2$ application are recommended during the emergency stage, followed by the permanent restoration of the remaining tooth fragment after root canal filling. Surgical extrusion is an option for such fractures because the pulp tissue cannot be devitalised as in uncomplicated crown–root fractures. When no combination of procedures successfully renders the remaining fragment restorable, extraction of the tooth is necessary. When root fractures are located above or close to the gingival crevice, the whole tooth should be extracted; when the remaining tissue allows tooth restoration, only the coronal fragment should be removed for root canal therapy and post and core restoration. Fractures between the middle and apical thirds of the tooth have a good prognosis for pulp survival and the joining of root fragments to one another during healing. A displaced or mobile fragment should be repositioned correctly and the tooth should be splinted for 2–3 months. During this time, the fragments usually calcify. The tooth should be inspected for signs of pulp necrosis during follow-up visits and root canal therapy should be performed if necessary.

4.4.2. Injuries to periodontal tissues

Concussed teeth present only tenderness to percussion in the horizontal and vertical directions. Removing the tooth from occlusion is the only accepted treatment option in such cases. Subluxated teeth show no clinical or radiographic displacement, but damage to the periodontal ligament tissue is present. Periodontal tissue rupture can cause bleeding from the gingival margin crevice. Treatment in these cases is the same as described for concussion, and follow-up monitoring of pulp vitality is necessary. Extrusive luxation is characterized by neurovascular and periodontal ligament rupture with mobility and bleeding from the gingival margin. Pulp necrosis and external root resorption may be seen in later stages. The tooth should be positioned properly and splinted to uninjured adjacent teeth with an acid-etch/resin splint for 3 weeks. Other methods of splinting used routinely in oral and maxillofacial surgery are not recommended. If pulp necrosis occurs, endodontic therapy should be performed. Lateral extrusions often involve the alveolar bone, and may be characterized by complex gingival lacerations and step deformities. The goal of treatment is to properly reposition the alveolar bone and tooth, which can be accomplished with the application of an acid-etch/resin splint for 4–8 weeks. Intrusive luxation is characterized by obvious tooth displacement and comminution and fracture of the alveolus. The risks of pulpal necrosis and inflammatory root resorption are higher in such cases than in other dentoalveolar injuries. Affected teeth with complete root development and closed apices should be repositioned and stabilized with a non-rigid splint. Endodontic therapy within 10–14 days after injury, including canal filling with $Ca(OH)_2$, is recommended to retard or inhibit the inflammatory or replacement resorption

process. Intrusion of an incompletely developed tooth is discussed in the 'Midfacial Fractures in Children' section below. The fate of an avulsed tooth depends on the cellular viability of the periodontal fibres that remain attached to the root surface prior to reimplantation. Important factors determining the success of treatment measures are the length of time that the tooth has been out of the socket, the state of the tooth and periodontal tissues, and the manner in which the tooth has been preserved before replantation. Avulsed teeth should be stored temporarily in milk, saliva, saline, or Hank's solution. More than 15 min of extraoral exposure of a periodontal ligament will deplete most cell metabolites in the dental tissue. Teeth in poor hygienic condition and those with moderate to severe periodontal disease, gross caries involving the pulp, apical abscess, infection at the replanting site, and bony defects and/or alveolar injuries involving the loss of supporting bone are generally not replanted. For individuals with avulsed teeth with mature or closed apices who present within 2 h after injury, the tooth is placed in Hank's solution for about 30 min, then in doxycycline (1 mg/20 mL saline) to inhibit bacterial growth and aid pulpal revascularization; replantation and splinting with an acid-etch/resin splint for 7–10 days are then performed. Endodontic cleansing and shaping of the canal should be performed, and $Ca(OH)_2$ filling should be applied immediately prior to splint removal. The use of final gutta-percha obturation 6–12 months later is contingent on the resolution of canal and/or root pathology. To optimise the success of treatment, avulsed teeth should be replanted and stabilized within 2 h, before periodontal ligament cells become irreversibly necrotic. Teeth with apical openings >1 mm in diameter have a much better prognosis than do those with more mature or closed apices; however, when the extraoral period exceeds 2 h, apical root morphology has little effect on the treatment success rate.

4.4.3. Injuries to the supporting bone

Most alveolar fractures occur in the premolar and incisor regions. The treatment of these fractures involves proper reduction and rapid stabilization. Manipulation by pressure and rigid stabilization of the fragments are accepted closed-reduction techniques. Major displacement or difficulty with closed reduction may necessitate open reduction. Alignment of the involved teeth, edema of the segments, restoration of proper occlusion, and edema of the teeth in the fractured segment are important. The removal of teeth with no bony support may be considered, but should not be performed before the fractured bony segments have healed, even if the teeth are considered to be unsalvageable. Segment edema can be performed with acrylic or metal cap splints, orthodontic bands, fibreglass splints, transosseous wires, small or mini cortical plates, or transgingival lag screws; these materials should be applied for at least 4 weeks.

4.4.4. Complications

Pulp canal obliteration is characterized by the deposition of hard tissue within the root canal space and dark-yellow discolouration of the clinical crown. This complication is seen most frequently after tooth luxation or horizontal root fracture. A tooth with pulpal canal obliteration does not require treatment unless the pulp tissue becomes necrotic and develops periradicular radiolucency. Pulp necrosis is the most likely complication of dentoalveolar injury. Its

incidence depends on the type and severity of injury and the extent of root development; teeth with fully formed roots are affected more often. If pulp necrosis is detected, root canal therapy should be initiated immediately to prevent inflammatory root resorption. Internal root resorption can be an issue after most dentoalveolar injuries. This process is usually detected radiographically; if it is identified at an early stage, root canal therapy has an excellent prognosis. The risk of tooth fracture after endodontic therapy is increased in cases of large defects. Follow-up radiography is useful for the detection of internal root resorption. If necrotic pulp is not removed, inflammation of the root surface may occur and the tooth root will be resorbed. Inflammatory root resorption can be detected radiographically and treated by $Ca(OH)_2$ dressing after canal debridement. Ankylosis can occur following damage to large areas of the periodontal membrane, as a primary result of trauma, or as a result of inflammatory root resorption. Osseous replacement proceeds slowly in adults; the tooth may serve for several years, but will loosen eventually.

5. Le Fort fractures

Rene Le Fort famously characterized the types of midfacial fracture caused by anteriorly directed forces [22-24] [Figure7-9]. Most Le Fort fractures are caused by motor vehicle accidents, and this type of trauma is often associated with other facial fractures and orthopaedic and neurologic injuries.

5.1. Clinical Examination

5.1.1. Le Fort I fractures (Guerin fracture)

In Le Fort I fractures, a horizontal fracture line separates the inferior portion of the maxilla, the horizontal plates of the palatal bones, and the inferior one-third of the sphenoid pterygoid processes from the superior two-thirds of the face, which remain associated with the skull. The entire maxillary dental arch may be mobile or wedged in a pathologic position. The patient may have an anterior open bite. Step deformities can be palpated intraorally if edema allows. Hematomas in the upper vestibule (Guerin's sign) and epistaxis may occur. Le Fort I fractures can be detected readily by orthopantomography, and CT provides a superior level of detail. [Figure 7].

5.1.2. Le Fort II fractures

In Le Fort II fractures, the pyramidal mid-face is separated from the rest of the facial skeleton and skull base. The fracture begins inferior to the nasofrontal suture and extends across the nasal bones and along the maxilla to the zygomaticomaxillary suture, including the inferomedial third of the orbit. The fracture then continues along the zygomaticomaxillary suture to and through the pterygoid plates. [Figure 8].

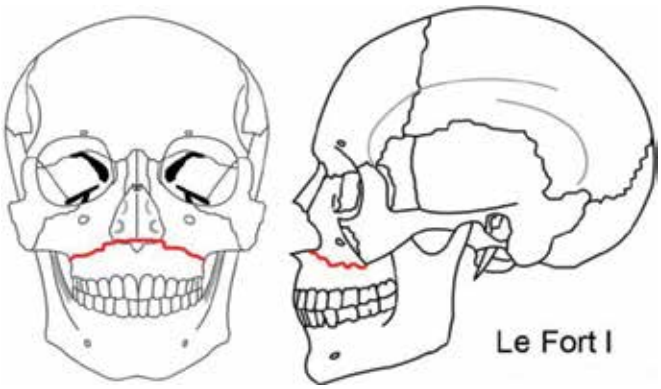

Figure 7. Le Fort I Fracture (Figure adapted from www.radiologytutorials.com)

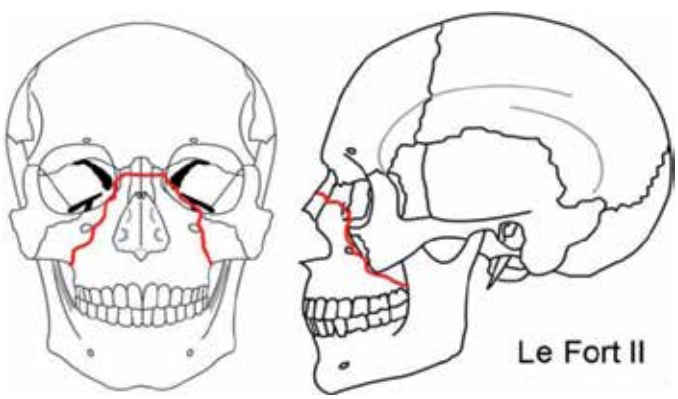

Figure 8. Le Fort II Fracture (Figure adapted from www.radiologytutorials.com)

5.1.3. Le Fort III fractures

In Le Fort III fractures, the face is essentially separated along the base of the skull due to force directed at the level of the orbit. The fracture line runs from the nasofrontal region along the medial orbit, through the superior and inferior orbital fissures, and then along the lateral orbital wall through the frontozygomatic suture. It then extends through the zygomaticotemporal suture and inferiorly through the sphenoid and the pterygomaxillary suture. In the past, Water's and lateral views were used to identify Le Fort fractures. CT and three-dimensional CT are now used most frequently, and axial and coronal scans are most useful for identifying midfacial fractures. Pterygoid plate fractures are found in all types of Le Fort fracture. Le Fort I fractures can be seen through the lateral aspect of the piriform aperture. Fractures of the infraorbital rim and zygomaticomaxillary buttress are unique to Le Fort II fractures. Only Le Fort III fractures involve the lateral orbital wall and zygomatic arch, and cerebrospinal fluid leakage can be a matter of concern. [Figure 9].

http://dx.doi.org/10.5772/54644

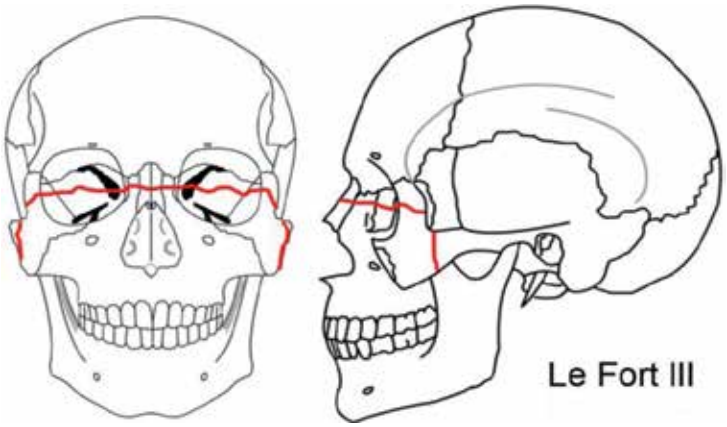

Figure 9. Le Fort III Fracture (Figure adapted from www.radiologytutorials.com)

5.1.4. Treatment

The basic principle employed in the treatment of Le Fort fractures is fixation of the maxilla to the next highest stable structure, which differs with Le Fort fracture level. At the Le Fort I level, fixation is performed along the vertical buttresses of the maxilla at the piriform and zygomatic buttress. At higher Le Fort levels, fixation to the nasal bones, orbital rims, or zygomaticofrontal sutures may be necessary. The restoration of proper occlusion is a main goal of treatment. Reconstruction and fixation of the paranasal and zygomaticoalveolar buttresses are often sufficient to re-establish the proper position of the maxilla in Le Fort I fractures. Fractures with minimal or no displacement can heal spontaneously. Bleeding from the nasal wall or septal cracks is common and can be managed by various types of nasal packing. Tamponades can be used at other bleeding sites, such as those with lacerations or abrasions. Intermaxillary fixation with arch bars should be performed after reduction of the maxilla, followed by internal fixation of the maxillary vertical buttresses with plates and screws. Le Fort I fractures can generally be approached *via* maxillary vestibular incisions. Reduction of the maxilla can be challenging because of impaction, telescoping, or a significant interval of time between injury and treatment. If resistance is encountered during mobilisation of the maxilla, Rowe or Hayton–Williams disimpaction forceps may be used to help reduce the fracture [Figure 10,11].

Incomplete fractures may make maxillary mobilisation difficult; in such cases, completion of the fracture with osteotomies can facilitate reduction. In cases of severe comminution, inadequate dentition, periodontal disease, or edentulous arches (Gunning splints), fabricated occlusal or palatal splints can be applied to establish intermaxillary fixation.

Le Fort II fractures can be reduced with Rowe impaction forceps and intermaxillary fixation. A maxillary buccal vestibule incision and any of various approaches to the orbital rim can be used if open reduction is necessary. Bilateral Lynch incisions are to expose the nasofrontal suture [Figure 12].

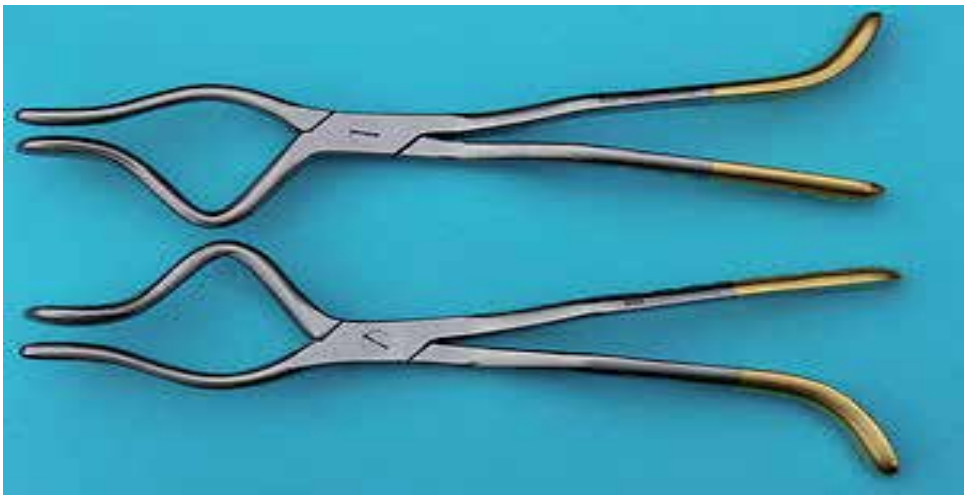

Figure 10. Rowe disimpaction forceps

Figure 11. Hayton Williams forceps

Le Fort III fractures rarely occur in isolation and are usually components of panfacial fractures. Bicoronal incisions can be used to expose the naso-orbito-ethmoidal region, frontozygomatic sutures, and lateral orbital rims. Pre-auricular, lower lid, and maxillary vestibular incisions can be performed when necessary.

5.1.5. Complications

Patients who have undergone intermaxillary fixation may experience breathing problems, which can be resolved by opening the nasopharyngeal airways. Hemorrhage of the posterior superior alveolar artery should be suspected when perfuse bleeding occurs following any fracture of the posterior alveolar wall. Rapid decreases in blood pressure, hemoglobin, and hematocrit are other signs of fatal hemorrhage. If the artery cannot be ligated, embolization is indicated after the identification of the bleeding source *via* angiography. Some forms of trauma cause paranasal sinus fractures. Sinus complications, such as chronic sinusitis, polyps,

http://dx.doi.org/10.5772/54644

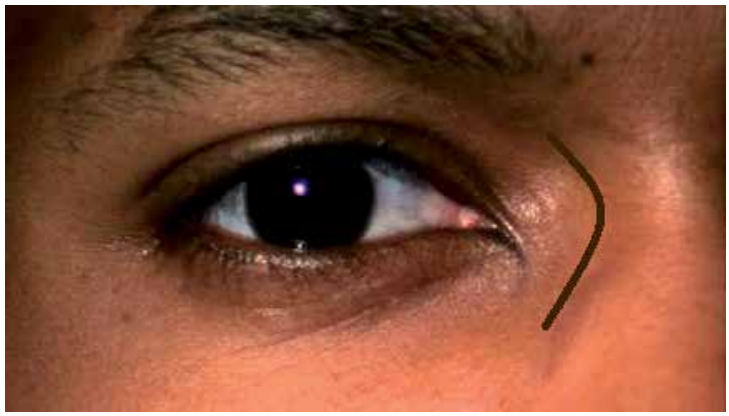

Figure 12. Lynch incision line

mucocele formation, and acute sinus infection may occur in such cases. Proper anatomic reduction of the sinuses can restore normal sinus function. Vision-related complications can be an issue before or after the reduction of a fracture, especially a high Le Fort fracture. Blindness, enophthalmos, and diplopia can occur due to intraorbital or retrobulbar hemorrhage or damage to the optic nerve caused by bone fragments. Improper rigid fixation of fracture segments will result in malocclusion; this complication usually occurs in patients with anterior open bites and/or class III fracture patterns. Improper rigid fixation may also cause numbness of the area innervated by the infraorbital nerve due to impingement of this nerve. A second surgical procedure is required to correct such complications. Malunion of maxillary fractures can obstruct the nasolacrimal ducts. Non-union of the segments may result in an inadequate blood supply, malpositioning, or infection. Foreign bodies, fractured teeth, and hematomas may cause infection.

6. Fractures of the zygomatic bone

Zygomatic bone fracture is the second most common midfacial injury, following nasal fracture. A zygomatic complex fracture is characterized by separation of the zygoma from its four articulations (frontal, sphenoidal, temporal, and maxillary). An independent fracture of the zygomatic arch is termed an isolated zygomatic arch fracture [Figure 13,14].

6.1. Clinical examination

The face is inspected and palpated to identify asymmetry caused by displaced fragments of the facial skeleton. Pain, ecchymosis, and periorbital edema with subconjunctival hemorrhage are the earliest clinical signs of a non-displaced zygomatic bone injury. Displaced fractures generally cause depression of the malar eminence and infraorbital rim. Damage to the zygomaticotemporal and infraorbital nerves may cause paraesthesia or anaesthesia in the cheek, lateral nose, upper lip, and maxillary anterior teeth. Epistaxis and diplopia are common

Figure 13. Zygomatic complex fracture

Figure 14. Isolated Zygomatic Arch fracture

in zygomatic bone fractures. Limitation of motion in the extraocular muscles and enophthalmos or exophthalmos should be noted, as they can be signs of fracture of the orbital floor or medial or lateral orbital walls. In such cases, ophthalmologic consultation should be consid-

ered before surgical intervention. An isolated zygomatic arch fracture typically has an M-shaped pattern, with two fragments collapsed medially and often impinging on the masseter muscle or even the muscular process of the mandible. Medial displacement of the zygomatic arch may cause mandibular trismus as a result of masseter muscle spasm or mechanical impingement of the coronoid process against the displaced segments. Direct lateral force causes an isolated zygomatic arch fracture or an inferomedially displaced zygomatic complex fracture; frontal force usually produces an inferoposteriorly displaced fragment. Extraoral step deformities of the zygomatic arch and inferior and superolateral orbital margins, as well as intraoral step deformities of the zygomaticomaxillary buttress, may be palpable if the region is free of edema. Axial and coronal CT images inhibit visualisation of the buttress of the midfacial skeleton. Three-dimensional images may be used to obtain additional information about the relationships of displaced and rotated fractured segments to surrounding bony structures. Plain radiography employing Waters' and Caldwell's views can also be used to detect zygomatic complex fractures. The submentovertex view is very helpful for the evaluation of the zygomatic arch and malar projection.

6.2. Treatment

The management of zygomatic bone fractures depends on the degree of displacement and the resultant aesthetic and functional deficits. Surgery can be delayed until the majority of facial edema is gone. Isolated zygomatic arch and zygomatic complex fractures with minimal or no displacement are not managed surgically. A soft diet restriction can help to avoid secondary fracture displacement. When displacement and minimal comminution are present, the Gillies technique is the standard reduction treatment for isolated zygomatic arch fractures [Figure 15]. In the Gillies approach, a 2-cm-long temporal incision is made behind the hairline, and the subcutaneous and superficial temporal fascia are dissected to the level of the temporalis muscle to reach the underlying temporal surface of the zygomatic bone; a zygomatic elevator is then used to reduce the arch fracture [25]. The use of a J-shaped hook elevator through a periauricular incision made anterior to the articular eminence and inferior to the zygomatic arch is an alternative approach for reducing zygomatic arch fractures. This approach is faster than the Gillies approach, but it can easily cause damage to the frontal branches of the facial nerve. Fixation of zygomatic arch fractures can be performed by packing the temporal fossa or using transcutaneous circumzygomatic arch wires while providing support with metal or aluminium finger splints. Open reduction is rarely performed in highly comminuted zygomatic arch fractures because it requires a time-consuming coronal incision.

Displaced zygomatic complex fractures require open reduction and internal fixation. Miniplates and microplates provide the best results with minimal complications. A useful option for displaced zygomatic fractures is the application of a transcutaneous Carroll–Girard screw in the malar region [Figure 16].

This technique enables excellent manipulation of the fractured segment for reduction. Reduction of the frontozygomatic suture, zygomaticomaxillary buttress, and inferior orbital rim should be the main goal of the treatment protocol. The perfect reduction of these three points of reference allows proper positioning of the fractured segment. The location and

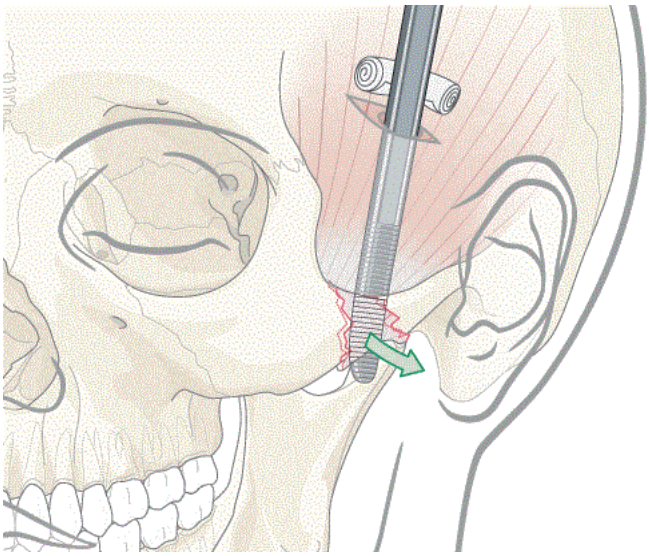

Figure 15. Gillies approach to zygomatic arch (Figure adapted from www.aofoundation.org)

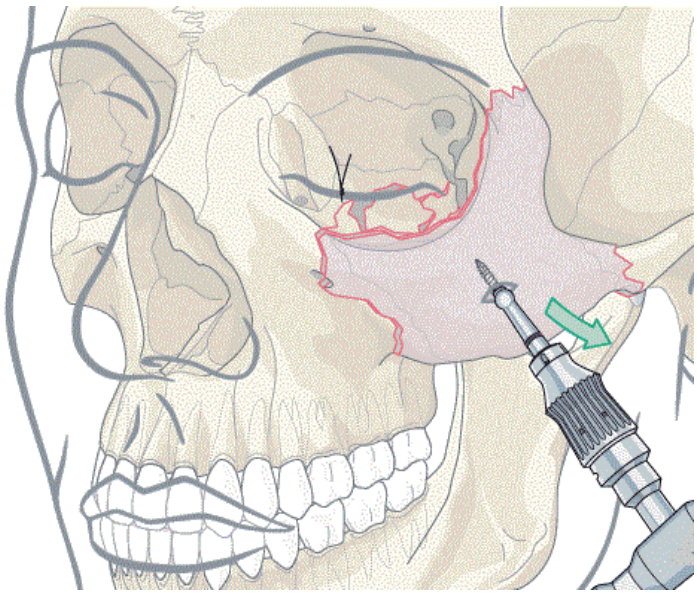

Figure 16. Useof Carroll-Girard screw (Figure adapted from www.aofoundation.org)

number of fixation sites depend on the fracture pattern, location, direction of displacement, and degree of instability. In more severe fractures, perfect reduction can be achieved with the use of the zygomatic arch as a fourth reference point. The zygomaticomaxillary buttress should be reduced first *via* an intraoral approach, while this structure is easy to reach; this technique

http://dx.doi.org/10.5772/54644

leaves no scar and may achieve reduction of the entire fractured segment. The zygomaticomaxillary buttress is approached surgically through a 3–5-mm-long incision in the maxillary vestibule above the mucogingival junction, extending from the canine region to first molar region. The protocol for minimally comminuted and displaced fractures should be temporary edema of the zygomaticofrontal suture with wires, reduction of the zygomaticomaxillary buttress and inferior orbital rim, and then replacement of the temporary zygomaticofrontal edema with a plate. The zygomaticofrontal suture is approached surgically through a lateral eyebrow incision, and the inferior orbital rim is approached *via* subciliary and transconjunctival incisions [Figure 17-19].

Figure 17. Lateral eyebrow incision line

Figure 18. Transconjuctival incision line

Figure 19. Subciliary incision line

In complex and highly comminuted fractures, the zygomatic arch should be reconstructed first; a coronal flap is usually used to gain access to this structure.

6.3. Complications

Restoration of the natural contour of the zygoma is the key to restoring facial projection in patients with displaced and comminuted fractures. Inadequate flattening the zygomatic arch and failure to achieve optimal rotation of the zygomaticomaxillary complex result in malar eminence flattening, asymmetry, and widening of the face. Inadequate reduction or edema of segments may cause malunion.

Poor or excessive reconstruction of the orbital rim should be avoided because an increase in orbital volume can cause enophthalmos and a decrease can cause exophthalmos. Diplopia can be caused by edema, hematoma, injury to cranial nerves 3, 4, or 6, and damage to extraocular muscles, and may heal spontaneously except in the latter case.

Although damage to the zygomaticomaxillary and zygomaticofacial nerves is less common, zygomaticomaxillary complex fractures often cause damage to the infraorbital foramen. Anaesthesia of the lower eyelid and malar and upper lip areas is common in infraorbital nerve injuries. Proper reduction of the fractured segments usually minimizes the risk of permanent symptoms. Blindness immediately after surgery may indicate impingement of the orbital apex contents by a bony fragment. Retrobulbar hematomas rarely develop, but compression of the central retinal artery causing disruption of the retinal circulation may lead to irreversible ischaemia of the optic nerve and permanent blindness.

Patients with zygomatic fractures may suffer from trismus, which may be caused by impingement of the zygomatic bone on the coronoid process of the mandible or ankylosis of the

coronoid process to the zygomatic arch. If a previous zygomatic bone or arch fracture has been reduced improperly, the zygomatic bone should be repositioned *via* osteotomy; otherwise, coronoidectomy is the most common solution.

7. Orbital fractures

Isolated orbital fracture is not a common type of midfacial fracture, but the incidence of midfacial fractures involving the orbit is high because all Le Fort II and III fractures and those of the naso-orbito-ethmoidal and zygomaticomaxillary complexes involve orbital injury. Orbital fractures may affect the internal and/or external orbital frame. Thus, fractures of the orbital region can be discussed in the context of zygomaticomaxillary complex, naso-orbito-ethmoidal complex, and isolated orbital fractures.

7.1. Clinical examination

As discussed above, zygomaticomaxillary complex fracture is the most common fracture type with orbital involvement. Like naso-orbito-ethmoidal fractures (discussed below), zygomaticomaxillary complex fractures are caused by blunt force applied directly to the bone. Isolated fractures of the orbit often occur as a result of direct force to the globe of the eye. A sudden increase in intraorbital pressure creates an outward force that causes fracture of the weakest bony structures in internal orbital walls. Isolated orbital fractures can be classified as 'blow-out' or 'blow-in'. Most blow-out fractures affect the anteroinferomedial aspect of the orbital cavity and displace the orbital globe posteromedially and inferiorly. A significant increase in the volume of the orbital cavity results in enophthalmos of the globe. Herniation of the orbital roof and globe to the maxillary sinus occurs in such fractures. When an isolated fracture is caused by low-energy force, linear fracture of the orbit may be detected. Linear fractures retain periosteal attachments and do not cause orbital globe herniation to the maxillary sinus or complete perforation of the maxillary sinus roof. More severe trauma causes a complex fracture involving two or more orbital walls. In complex internal orbital fractures, the globe is often displaced posteriorly and the optic canal may be involved. Blow-in fractures affect the orbital roof and may be diagnosed after severe injury of the anterior skull base. Rupture of the orbital roof reduces the orbital volume and often causes anteroinferior globe displacement.

The affected region should be inspected carefully to identify the presence of edema, chemosis, ecchymosis, lacerations, ptosis, asymmetric lid drape, canalicular injury, and/or canthal tendon disruption. Any step deformity or mobility around the orbital rim should be palpated before edema develops in surrounding tissues. Neurosensation of the infraorbital and supraorbital nerves should be tested. Ophthalmologic consultation is very important and necessary. Limitation of ocular movements can be caused by mechanical entrapment or neurologic injury. Three-dimensional CT and magnetic resonance imaging are preferred for the evaluation of orbital fractures. Waters' projection is the most useful plain radiographic modality because it enables visualisation of the orbital floor and roof. Ophthalmic ultrasonography and color Doppler imaging can provide additional information.

7.2. Treatment

Subciliary and transconjunctival incisions are the most aesthetically acceptable approaches to the orbital floor. Linear injuries of the orbital floor require no intervention unless they show signs of soft-tissue entrapment in fractured but self-reduced sites. In patients with blow-out or blow-in fractures, soft- and hard-tissue reduction and reconstruction are necessary. Grafting of the injured site with autografts, allografts, or alloplastic materials may be necessary to achieve proper anatomic reduction and stability and to prevent soft-tissue contraction. The iliac crest and nasal septal cartilage are the best donor sites for autografts, and the use of alloplastic titanium mesh can be successful in cases requiring extra support.

7.3. Complications

Most internal orbital fractures cause volumetric contraction or expansion of the orbital cavity, which may lead to diplopia, enophthalmos, exophthalmos, proptosis, and/or extraocular muscle imbalance. Extraocular muscle imbalance and diplopia can be the result of extraocular muscle entrapment or neuropathy of the 3rd to 5th cranial nerves. An increase in orbital volume causes enophthalmos, which may occur weeks or months after injury.

For some challenging fractures of the orbital floor, the transconjunctival approach may be safer than other methods. The placement of a transconjunctival incision at the conjunctival fornix appears to minimize the risk of eyelid malposition. A transantral endoscopic approach is an alternative method that avoids potential damage caused by lower-lid incisions.

8. Naso-orbito-ethmoidal fractures

Naso-orbito-ethmoidal facture can occur either in isolation or in association with other midfacial fractures. Most associated injuries affect the cervical spine and ocular and intracranial regions. This fracture type is caused by focused high-energy transfer to the intercanthal area. Because the naso-orbito-ethmoidal area contains several types of tissue (bone, cartilage, tendons, ocular tissue) restoration is challenging.

8.1. Clinical examination

Naso-orbito-ethmoidal fractures are characterized by three major post-injury symptoms: increased intercanthal distance, diminished nasal projection, and impaired nasofrontal and lacrimal drainage.

Markowitz *et al*. [26] developed the most widely used classification system for naso-orbito-ethmoidal fractures, which distinguishes three fracture types [Figure 20]:

- Type I: the medial canthal tendon is attached to a single, large central fragment
- Type II: the medial canthal tendon is attached to a comminuted but manageable central fragment; the canthal tendon remains attached to a fragment that is sufficiently large to allow osteosynthesis

http://dx.doi.org/10.5772/54644

- Type III: the medial canthal tendon is attached to a comminuted and unmanageable central fragment; the fragments are either too small to allow osteosynthesis or completely detached.

Figure 20. Classification of Nasoorbitoethmoidal fractures

Periorbital ecchymosis, subconjunctival hemorrhage, and pain are the most common signs and symptoms of naso-orbito-ethmoidal fractures. Other signs and symptoms include skin and mucosal lacerations, epistaxis, nasal obstruction, edema, telecanthus, and increased canthal angles. Depression of the bony segment causes internal and external nasal cosmetic deformities. Edema may obscure such depression for up to 5 days, and most surgeons recommend the postponement of surgery until the edema has resolved. The impaction of bony segments to the orbit may cause exophthalmos, proptosis, or ptosis. Fractures of cribriform plate and posterior wall of the frontal sinus may cause cerebrospinal fluid leakage. Nasal bone mobility, traumatic telecanthus, crepitus, and depressibility of the area are the clinical digital-examination findings for naso-orbito-ethmoidal fractures.

Increased intercanthal distance, termed telecanthus, is a key deformity resulting from naso-orbito-ethmoidal injury. Normal intercanthal distances are 29–36 mm in males and 29–34 mm in females; a distance exceeding 40 mm is classified as telecanthus and may indicate that surgical treatment is required.The medial canthal tendon is a very important anatomic factor in naso-orbito-ethmoidal injuries resulting in telecanthus. The pretarsal portions of the orbicularis oculi muscle in the upper and lower lids unite at the canthus to form the medial canthal tendon. The superficial portion of this tendon provides support to the eyelids and maintains the integrity of the palpebral fissure. Restoration of this component after canthal detachment is critical for maintaining proper eyelid appearance. The deeper portion, also called Horner's muscle, attaches to the posterior lacrimal crest and assists in the movement of fluid through the lacrimal system. Disruption of the medial canthal tendon causes contraction of the orbicularis oculi muscle, increasing the intercanthal distance and laterally displacing the rounded contour of the medial palpebral fissure. The 'bowstring test' is a useful method of assessing the status of the medial canthal tendon's attachment to the bone. This test involves lateral pulling of the lid while palpating the tendon area to detect movement of fracture segments [27] [Figure 21].

Figure 21. Bowstring test

Two- and three-dimensional CT using axial and coronal views are the most valuable imaging methods for the diagnosis of naso-orbito-ethmoidal fractures. The use of conventional imaging techniques is not recommended because these modalities do not provide adequate information.

8.2. Treatment

The goals of naso-orbito-ethmoidal fracture treatment are the resolution of the three major issues described above: Establishment of proper nasal projection, narrowing of the intercanthal distance, and establishment of the nasofrontal and lacrimal fluid route. The surgeon should seek to achieve satisfactory results in a single surgery because corrective secondary surgery may cause scarring and fibrosis. For this reason, most authors have advocated the postponement of surgery for 3–7 days to allow for the recession of edema. For naso-orbito-ethmoidal fractures involving a single fragment (type I), treatment can be attempted with closed reduction and the provision of intranasal packing support. If the fragment cannot be reduced satisfactorily by closed reduction, the operation should be converted immediately to an open reduction to avoid the need for secondary surgery. In most cases, a transoral approach is sufficient to reach the injured area without an additional incision.

Proper restoration of types II and III naso-orbito-ethmoidal fractures usually require wide access, which can be provided only by a coronal flap. Wide exposure of the nasal bones and medial orbital walls can be achieved readily. When necessary, a transoral approach can be used to access the paranasal areas and a transconjunctival approach can be used to expose the inferior orbital rim or inferomedial wall. Existing lacerations can also be used to access the injured area. Transcutaneous approaches are not considered to be acceptable because they cause facial scarring.

In severe naso-orbito-ethmoidal injuries, nasal dorsal strut grafting is often required to re-establish support for the entire nose. This graft is cantilevered from the stable frontal bone and placed in the subcutaneous plane, extending inferiorly to the nasal tip.

When the medial canthal tendon is detached completely or attached to an unusable bone fragment, its proper position must be secured immediately using medial canthopexy. The

medial canthal tendon should be reduced into a position slightly posterosuperior to the posterior lacrimal crest. The tendon is then sutured with a wire passing transnasally to a cantilevered miniplate on the opposing (undamaged) side. The canthopexy should be positioned sufficiently deep in the orbit to achieve the proper shape of the palpebral fissure and lower lid, as the superficial portion of the medial canthal tendon secures the position of the lower lid and contour of the palpebral fissure. Proper positioning of the medial canthal tendon will achieve correct lacrimal fluid drainage, which is aided by the deep portion of the tendon. When nasofrontal obstruction is a concern, endoscopic frontal sinus surgery can be indicated to re-establish nasofrontal drainage. The medial canthal tendon should be slightly over-reduced in canthopexy procedures to compensate for remodelling of related tissues.

8.3. Complications

Cosmetic deformities are foreseeable after nasal and naso-orbito-ethmoidal injuries. Postoperative septal hematoma, septal abscess, and/or destructive fracture of the septal cartilage/bone are the postoperative causes of nasal deformity. Massive comminution of the naso-orbito-ethmoidal complex is classically associated with saddle nose deformity. Bone grafting is required in most patients to establish proper nasal projection, symmetry, and contour. However, even bone grafts can be associated with potential resorption problems in the long term. Depending on the fracture level, cartilage or bone grafts and nasal implants can be used to improve the appearance of these deformities.

Septal deviation due to inadequate closed reduction often results in external nasal asymmetry. Direct septal visualisation *via* the open rhinoplasty approach is preferred for the correction of this defect.

After naso-orbito-ethmoidal injury, scar contracture results in cosmetic and functional deformities. Thus, secondary surgery should be avoided because it may result in scarring.

Open reduction and internal fixation procedures often damage the medial canthal tendon or nasolacrimal apparatus. As a result, epiphora related to nasolacrimal duct obstruction can be an issue. Intubation or stenting of the lacrimal duct may be necessary in such cases.

9. Midfacial fractures in children

Midfacial fractures are not common in children; they account for only 1–8% of pediatric fractures [28-31] and usually affect the mandible. This low incidence is related to the protection provided by the mandible and cranium, which absorb most of the traumatic impact, and to the elastic nature of midfacial bones and flexibility of osseous suture lines [32]. Children form a distinct patient group in maxillofacial surgery due to significant differences between the facial skeletons of children and adults. Depending on the patient's age, these differences include small bone size, small paranasal sinus volume, growth potential, the presence of tooth germs in alveoli during primary and mixed dentition stages, a more rapid healing process compared with adults, and difficulty with cooperation resulting in the need for general

anaesthesia in more cases than in adults [33]. The proportion of children in whom midfacial fractures are identified has increased over time, probably due to the increased use of adequate imaging modalities [34]. CT has largely supplanted standard radiography as the preferred imaging method for pediatric facial trauma.

The presence of tooth germs in alveoli potentially creates zones of weakness in the jaws and limits the placement of certain plate and screw types, given the need to avoid damage to the developing dentition. The treatment of pediatric patients with midfacial fractures using intermaxillary fixation is also quite difficult, and erupting or exfoliating teeth can be an issue. On the other hand, the on-going processes of tooth eruption and exfoliation may compensate for minor inaccuracies in reduction and fixation. Recognition of the differences between children and their adult counterparts is important in facial rehabilitation.

Several aspects of dentoalveolar trauma management in children differ from that in adults. Developing roots have open apices, and the preservation of pulp vitality is important. In complicated crown and crown–root fractures, pulpotomy can be performed 1–2 mm below the exposed pulp tissue and $Ca(OH)_2$ or mineral trioxide aggregate can be applied. The second step in such cases is composite restoration or bonding of the crown fragment to the tooth. If the pulp is necrotic, apexification with intracanal application of $Ca(OH)_2$ must be used instead of pulpotomy. In pediatric cases of intrusion, spontaneous re-eruption may occur. Orthodontic repositioning can be a second treatment plan unless movement is observed within about 3 weeks. In the pediatric dentition, osseous replacement in ankylosis occurs much faster than in adults; dentoalveolar ankylosis usually interferes with alveolar process growth, and the tooth might be malpositioned.

Fractures in the maxillary region tend to be less comminuted in children than in adults because children's paranasal sinuses are not fully developed. Open reduction and internal fixation are the preferred treatment methods, but intermaxillary fixation may be necessary in some cases. Avoiding damage to permanent tooth germs is a mandatory indication for closed reduction. Intermaxillary fixation with arch bars presents some difficulties in patients with mixed dentition, but the fixation period can be shorter than in adults. Teeth may be avulsed by the force of arch bars, and the fixation of arch bars to the teeth may not provide adequate retention because of weak and undeveloped roots. For this reason, the fabrication and use of Gunning splints to provide retention from the zygomatic arches, piriform apertures, and mandible *via* circumferential wires is recommended when intermaxillary fixation is necessary. As in adults, restoration of the normal anatomic position of the midfacial skeleton in children generally requires open reduction and stable fixation with miniplates and screws. In pediatric Le Fort II and III fractures, open reduction and internal fixation are necessary to re-establish proper anatomic and functional relationships. Pediatric fractures in the maxillary region are often of the greenstick type, which increases the complexity of fragment reduction. Because a greenstick fracture line limits fragment movement, proper reduction may require osteotomy.

Paediatric orbital fractures resulting in herniation and extraocular muscle entrapment require immediate intervention and even orbital exploration. Fractures of the orbital floor or wall in children heal rapidly, increasing the risks of scar cicatrisation and related ischemic necrosis of entrapped tissues.

Because the development of the nasal septum is a very important factor in facial growth, post-traumatic septal hematoma, which may cause septal necrosis and resorption, should not be ignored because it may result in saddle nose deformity.

Author details

Sertac Aktop*, Onur Gonul, Tulin Satilmis, Hasan Garip and Kamil Goker

Department of Oral and Maxillofacial Surgery, Marmara University, Istanbul, Turkey

References

[1] Gassner R, Tuli T, Hachl O, Rudisch A, Ulmer H. Cranio-Maxillofacial Trauma: A 10 Year Review Of 9543 Cases With 21 067 İnjuries. Journal Of Cranio-Maxillofacial Surgery. 2003;31:51–61

[2] Thomas DW, Hill CM: Etiology And Changing Patterns Of Maxillofacial Trauma. In: Booth PW, Schendel SA, Hausamen JE (Eds) Maxillofacial Surgery, Vol. Churchill Livingstone, 3, 2000

[3] Mouzakes J, Koltai PJ, Kuhar S, Bernstein DS, Wing P, Salsberg E:The İmpact Of Airbags And Seat Belts On The İncidence And Severity Of Maxillofacial İnjuries İn Automobile Accidents İn New York State. Arch Otolaryngol – Head Neck Surg. 2001;127:1189–1193

[4] Cook H E, Rowe M. A Retrospective Study Of 356 Midfacial Fractures Occurring İn 225 Patients. J Oral Maxillolac Surg. 1990;48:574 578

[5] Girotto JA, Mackenzie E, Fowler C, Redett R, Robertson B, Manson PN:Long-Term Physical İmpairment And Functional Outcomes After Complex Facial Fractures. Plast Reconstr Surg. 2001;108:312–327

[6] Afzelius LE, Rosen C: Facial Fractures: A Review Of 368 Cases. Int J Oral Surg. 1980;9:25

[7] Motamedi M H K. An Assessment Of Maxillofacial Fractures: A 5-Year Study Of 237 Patients. J Oral Maxillofac Surg. 2003;61:61-64

[8] Ansari M H. Maxillofacial Fractures İn Hamedan Province, Iran: A Retrospective Study (1987–2001).Journal Of Cranio-Maxillofacial Surgery. 2004;32, 28–34

[9] Thorén H, Snäll J, Salo J, Taipale L S, Kormi E, Lindqvist C,Törnwall J. Occurrence And Types Of Associated Injuries İn Patients With Fractures Of The Facial Bones. J Oral Maxillofac Surg. 2010;68:805-810

[10] Banks P, Brown A: Etiology, Surgical Anatomy And Classification. In: Banks P, Brown A (Eds), Fractures Of The Facial Skeleton. Philadelphia, USA: Elsevier, 1e4, 2001

[11] Shankar A N Et Al.. The Pattern Of The Maxillofacial Fractures E A Multicentre Retrospective Study. Journal Of Cranio-Maxillo-Facial Surgery Xxx (2012) 1-5 Doi: 10.1016/J.Jcms.2011.11.004

[12] Simpson DA, Mclean AJ: Mechanisms Of İnjury. In: David DJ, Simpson DA (Eds) Craniomaxillofacial Trauma, Vol. 101. Churchill Livingstone, 1995

[13] Killey H C. Fractures Of The Middle Third Of The Facial Skeleton. Bristol: John Wright & Sons Limited, 1977

[14] Norton N S. Netter's Head And Neck Anatomy For Dentistry. Philadelphia: Saunders Elsevier, 2007

[15] Teasdale G, Jennett B. Assessment of coma and impaired consciousness: a practical scale. Lancet 1974;2:81–4.

[16] Z. Nya´ra´dy, E. Orsi, K. Nagy, L. Olasz, J. Nya´ra´dy: Transgingival lag-screw osteosynthesis of alveolar process fracture. Int. J. Oral Maxillofac. Surg. 2010; 39: 779–782.

[17] Ellis E III. Soft Tissue and Dentoalveolar Injuries. In: Hupp J R et al. (ed.). Contemporary Oral and Maxillofacial Surgery Fifth Edition. Missouri: Mosby Elsevier; 2008. p474-7

[18] Fonseca RJ, Marciani RD, Hendler BH. Oral and maxillofacial surgery, trauma. Vol 3. Diagnosis and management of dentoalveolar injuries. Philadelphia (PA):W.B. Saunders Co; 2000. p. 48–50.

[19] Snawder KD, Bastawni AE, O'Toole TJ. Tooth fragments lodged in unexpected areas. JAMA 1976;233:1378–9.

[20] Leather D L, Gowans R E. Management of Alveolar and Dental Fractures, In: Miloro M (ed.) Peterson's Principles of Oral and Maxillofacial Surgery Second Edition. London: BC Decker Inc; 2004; 383-400.

[21] Andreasen JO, editor. Traumatic injuries of the teeth. 1st ed. Philadelphia (PA): W.B. Saunders; 1972.

[22] Le Fort R. Etude experimentale sur les fractures de la machoire superiore. Rev Chir 1901; 23:208–27.

[23] Le Fort R. Etude experimentale sur les fractures de la machoire superiore. Rev Chir 1901;23:360–79.

[24] Le Fort R. Etude experimentale sur les fractures de la machoire superiore. Rev Chir 1901;23:479–507.

[25] Gillies HD, Kilner TP, Stone D. Fractures of the malarzygomatic compound, with a description of a new x-ray position. Br J Surg 1927;14:651.

[26] Markowitz BL, Manson PN, Sargent L, et al. Management of medial canthal tendon in nasoethmoid orbital fractures: the importance of the central fragment in classification and treatment, Plast Reconstr Surg. 1991;87:843-853

[27] Furnas DW, Bircoll MJ. Eyelash traction test to determine if the medial canthal ligament is detached. Plast Reconstr Surg 1973;52:315–7.

[28] Rowe NL. Fractures of the jaws of children. J Oral Surg. 1969;27:497-507

[29] Posnick JC, Wells M, Pron GE. Pediatric facial fractures: evolving paterns of treatment. J Oral Maxillofac Surg. 1993;51:836-844

[30] Gassner R, Tuli T, Höchl O, et al. Craniomaxillofacial trauma in children: a review of 3385 cases with 6060 injuries in 10 years. J Oral Maxillofac Surg. 2004;62:399-407

[31] Qaqish C, Caccamese Jr JF. Pediatric Mid-face Fractures. In: Bagheri SC, Bell RB, Khan HA (ed.). Current therapy in oral and maxillofacial surgery. Missouri: Saunders Elsevier; 2012.p851-8

[32] Ferreira P, Marques M, Pinho C, Rodrigues J, Reis J, Amarante J. Midfacial fractures in children and adolescents: a review of 492 cases. British Journal of Oral and Maxillofacial Surgery. 2004;42:501—505

[33] Iatrou I, Theologıe-Lygıdakıs N, Tzerbos F. Surgical Protocols And Outcome For The Treatment Of Maxillofacial Fractures İn Children: 9 Years' Experience. Journal Of Cranio-Maxillo-Facial Surgery. 2010;38:511-516

[34] Thorén H, Iso-Kungas P, Iizuka T, Lindqvist C, Törnwall J. Changing trends in causes and patterns of facial fractures in children Oral Surg Oral Med Oral Pathol Oral Radiol Endod. 2009;107:318-324.

Section 9

Advanced Maxillofacial Distraction Osteogenesis: State-of-the-Art

Chapter 16

Distraction Osteogenesis

Hossein Behnia, Azita Tehranchi and Golnaz Morad

Additional information is available at the end of the chapter

http://dx.doi.org/10.5772/54647

1. Introduction

Distraction osteogenesis (DO) is defined as the formation of new bone between the vascular surfaces of osteotomized bone segments, separated gradually by distraction forces. [1] The incipient concept of distraction osteogenesis, as first described for correction of limb length discrepancies by Codivilla [2] in 1905, represented an osteotomized femur subjected to repeated forces of traction and counter-traction. This technique achieved a length increase of 3 to 8 cm; an amount that surpassed that attainable by other methods common at that time. Codivilla asserted that confronting the resistance of the muscles surrounding a bone is inevitable if the discrepancies are to be corrected. Abbott and Saunders later used the technique for elongation of tibia. [3] Distraction osteogenesis proved advantageous over other conventional methods for management of bone defects, particularly bone grafting, in that it provided simultaneous expansion of the functional soft tissue matrix, referred to as *distraction histogenesis*. [1] The method however, remained undeveloped until it resurged in 1950s by Ilizarov, leading to several successful endeavors increasing the length of the extremities. In 1992, McCarthy [4] expanded the application of distraction osteogenesis to the craniofacial skeleton by attempting to ameliorate mandibular length deficiency in patients with hemifacial microsomia and Nager's syndrome. Accomplishing an average increase of 20 mm in the mandibular length in these preliminary cases, craniofacial DO rendered promising insights for treatment of craniofacial skeletal abnormalities. Hitherto, a plethora of treatment protocols and modalities have evolved in order to improve the outcomes of craniofacial DO.

2. The biology of distraction osteogenesis

Distraction osteogenesis initiates by surgically simulating bone fractures via osteotomy of the deficient bone. Normal fracture healing occurs through a cascade of molecular and cellular

INTECH
open science | open minds

© 2013 Behnia et al.; licensee InTech. This is a paper distributed under the terms of the Creative Commons Attribution License (http://creativecommons.org/licenses/by/3.0), which permits unrestricted use, distribution, and reproduction in any medium, provided the original work is properly cited.

events triggered in response to injury. Formation of hematoma followed by chondrogenesis and angiogenesis eventually leads to the formation of hard callus by means of intramembranous and endochondral ossification. The resultant woven bone subsequently remodels into a more mature lamellar bone to restore the strength and function of the organ. [5], [6] During distraction osteogenesis however, the application of mechanical forces to the bone segments alters the repair process of the osteotomized bone segments, characteristic of fracture healing, to a regenerative process. [5] Evaluation of mechanotransduction mechanisms has demonstrated that tensile forces increase the expression of bone morphogenic proteins by osteoblasts and stimulate intramembranous bone formation. [7] This regenerative effect of gradual traction on tissue growth was originally designated by Ilizarov as the Law of Tension-Stress. [8] The process of distraction osteogenesis incorporates 3 major phases. The *Latency* phase is the period Which starts immediately subsequent to the creation of osteotomy and lasts till the commencement of distraction. This delay allows for tissue organization and formation of callus which bridges the gap between the two osteotomized bone surfaces. [5], [9], [10] Aronson et al conducted an animal study to test the outcome of different latency durations on bone regenerations. [11] Contrasting to other concurrent studies, it was observed that bone formation was most reliable when no latency period was considered prior to distraction; hence the suggestion that latency phase may not be essential. A recent study appraising the benefits of the latency period on the outcomes of dentoalveolar DO proved that although a latency period did not enhance the amount and density of the newly formed bone, it slightly increased bone maturation. However, it was assumed that despite the minor effect of the latency period on the regenerated bone, this phase may be crucial for soft tissue regeneration. [12] Regardless of the existing controversy on the importance of the latency phase, a review on the corresponding literature demonstrated that a 5-7 day latency period is the most recommendable protocol for the various indications of craniofacial DO. [1]The second phase known as the *Distraction* period is characterized by the application of distraction forces. Histologically, this phase begins with configuration of a Fibrous Inter-Zone (FIZ) at which dense fibers of collagen demonstrate a longitudinal arrangement parallel to the direction of the distraction forces. In between the collagen bundles osteoblastic activity creates a zone of Micro-Column Formation (MCF). The two ends of the FIZ are characterized by areas of primary mineralization, thus dubbed as Primary Mineralization Front (PMF). [5], [10], [13] The distraction phase continues with active synthesis of fibrous tissue in central areas and active mineralization at the ends, till the acquired amount of elongation is gained. [14] As the major features of the distraction phase, Ilizarov underscored the significance of the rate and rhythm of distraction forces on the quality and quantity of the newly regenerated bone. The rate and the rhythm, respectively defined as the speed and the frequency of the applied distraction forces were assessed in an animal study. The results, reported in 1989, suggested distraction of 1 mm per day applied as 0.25 mm per 6 hours as the ideal distraction rate and rhythm for limb elongation. This was while slower distraction rates led to premature consolidation of the bone and faster distraction was accompanied by hindrance of osteogenesis. Moreover, he claimed that more satisfying results were obtained when distraction forces were applied with higher frequencies. [15] The current standard protocols of craniofacial DO seem to apply distraction forces at a rate of 1 mm per day 2-3 times. Nevertheless, these features may be altered in different patients. [1] Subsequent

http://dx.doi.org/10.5772/54647

to the cessation of distraction, the third phase, designated as the *Consolidation* phase begins. This stage of distraction osteogenesis is distinguished by the growth of mineralization in a centripetal pattern. Moreover, transverse bridging connects the micro-columns of bone in the IFZ, leaving a honeycomb appearance. By the end of this phase, bone is being remodeled into a more mature lamellar bone, strong enough to function. [10] The duration of this period can be determined based on the amount of distraction. One month consolidation has been suggested for each centimeter of distraction. [16]

3. Mandibular distraction osteogenesis

The primary attempts for mandibular distraction osteogenesis date back to the 1970s when animal studies were designed to restore surgically shortened canine mandibles via gradual distraction. [17], [18] McCarthy et al were the first to apply gradual distraction for lengthening the human mandible. [4] The preliminary report of their study presented four children who underwent unilateral and bilateral mandibular expansion for management of unilateral microsomia and Nager's syndrome, respectively; 18 to 24 mm of mandibular distraction was achieved. Common indications for mandibular distraction are summarized in Table 1.

Syndromic
Goldenhar Syndrome
Pierre Robin Sequence
Treacher Collins Syndrome
Nager's Syndrome
Non-Syndromic mandibular hypoplasia (Unilateral/ Bilateral)
Retrognathia
Narrow mandible
Hemifacial Microsomia
Obstructive Sleep Apnea
Temporomandibular joint
Lack of TMJ translation
TMJ Ankylosis
Segmental bone defects
Alveolar Deficiencies

Table 1. Common indications for mandibular distraction osteogenesis

3.1. Mandibular lengthening

Mandibular hypoplasia, a condition associated with length deficiency in the mandibular ramus or/ and body, is a manifestation of impairment of mandibular growth caused by syndromic or non-syndromic congenital conditions or as a result of trauma. Depending on the severity of the deficiency, mild to severe esthetic and functional problems arise which obligate

intervention. Mandibular hypoplasia has been traditionally managed by bone grafting, orthognathic surgery, and orthodontic therapy. These treatment approaches may contribute to considerable morbidity and unsatisfactory results in many situations, not to mention instances in which treatment appears unfeasible. The advent of craniofacial distraction osteogenesis has provided an alternative treatment modality to eliminate the shortcomings of conventional protocols for management of this craniofacial discrepancy. [4] In correction of mandibular hypoplasia in angle's class II patients where great amounts of advancement (> 10 mm) are required, DO has shown promising results with negligible relapse. This is probably due to the simultaneous expansion of the surrounding soft tissue. [19] In comparison, the bilateral sagittal split osteotomy, the most common treatment choice, not only provides less stable results with advancements larger than 6 mm, but is also likely to be accompanied by serious adverse events, namely neurosensory disturbance of inferior alveolar nerve and disorders of the temporomandibular joint. [20], [21] On the other hand, bone grafting is another common choice of treatment for severe hypoplastic mandibles. [22], [23] Yet, the procedure seems not to be very desirable, since it may be associated with donor site morbidity and resorption of the graft. Another important indication for mandibular distraction osteogenesis is a lack of condylar translation. In growing patients with mandibular hypoplasia in whom condylar translations occurs normally during mandibular movements, functional orthodontic treatment may be of greater merit for restoration of the deficiency. Nevertheless, DO is a technique-sensitive procedure and demands patient compliance. Therefore, until randomized controlled trials have proved it beneficial over other treatment options for mandibular hypoplasia, it remains an alternative rather than a replacement for the existing treatment modalities. [20], [21]A variety of distraction devices have been designed and introduced for clinical implications; each associated with pros and cons. Extraoral distractors which are fixed in place by transcutaneous pins, are generally easier to manipulate and allow for multidirectional distraction. However, the psychosocial problems consequent to the presence of the device as well as facial scarring led to the emergence of intraoral distractors. [24], [25] McCarthy introduced the first intraoral distraction device in 1995. [26] Intraoral distractors are of three types: tooth-borne, bone-borne and hybrid distractors. [25] Finite element analysis of intraoral distraction devices demonstrated the hybrid type to be the most stable under masticatory loads, while tooth-borne distractors were the most reliable in transferring the expansion to the bone. [27] The morbidity associated with bone-borne devices appear to be higher than tooth-borne distractors. [28] While tooth-borne devices seem beneficial as they facilitate subsequent tooth movement, concerns such as greater mandibular expansion at the alveolar section comparing to the basal bone may arise with this type of distractor. [25] Shetye et al demonstrated that application of intraoral distractors may be associated with higher incidence of minor adverse events, with no effect on treatment outcome. This is while the occurrence of major incidents is more likely when extraoral distraction devices are used. [29]Mandibular hypoplasia is generally divided into two groups of unilateral and bilateral hypoplasia. A meta-analysis of mandibular distraction osteogenesis demonstrated the most common indication for unilateral DO to be hemifacial/craniofacial microsomia. [30] Unilateral craniofacial microsomia is a genetic disorder that affects the derivatives of the first and the second brachial arch and is initially characterized by abnormal growth of the mandibular ramus. The asym-

metric growth of the mandible may gradually affect the growth of the surrounding structures, a fact that encourages surgeons to begin treating patients at early ages. The resultant facial asymmetry has been corrected via unilateral DO particularly in growing children. [31], [32] The authors analyzed the posteroanterior cephalometric changes subsequent to unilateral distraction osteogenesis in 10 patients. [33] Improvements in the piriform angle, intergonial angle, and the occlusal cant revealed the influence of the treatment on the maxillary and midfacial growth. It is highly suggested that the treatment be continued with functional orthodontic therapy in growing children. Functional appliances can act to obtain symmetry during growth. We have performed the combination of distraction osteogenesis and functional orthodontic therapy in a group of our patients. [34] It is advisable that the patient be followed until the end of growth and if necessary the functional orthodontic therapy be continued.

3.1.1. Lengthening for asymmetry

Case 1

An 8-year-old male patient with a history of right condylar trauma at birth presented with facial asymmetry, cant of the occlusal plane, deviation of the midline, and a deep-bite malocclusion (Figure 1-A, B, C). A horizontal osteotomy was made at the body of the right ramus below the mandibular foramen and a custom-made unidirectional extraoral distractor was fixed in place (Figure 1-D, E). Following a 7-day latency period, the distractor was activated at a rate of 1mm/ day. Distraction was stopped after the ramus was elongated by 22 mm (Figure 1-F). Subsequent to removal of the distractor a hybrid functional appliance was used to manage the posterior right open-bite created as a result of mandibular lengthening (Figure 1-G, H). Functional therapy continued for 3 years when fixed orthodontic therapy was initiated in order to restore the position of impacted left canine (Figure 1-I, J).

3.1.2. Unilateral mandibular hypoplasia

Case 2

A 6-year-old male patient with a history of trauma at age 2, presented with facial asymmetry and midline deviation due to unilateral mandibular hypoplasia (Figure 2-A, B). A horizontal osteotomy was done in the right ramus and a unidirectional intraoral distractor (KLS Martin, Tuttlingen, Germany) was fixed in place (Figure 2-C). Distraction was initiated with an oblique vector (Figure 2-D). Consequently, along with a posterior open bite, the teeth were deviated to the opposite side to a considerable extent (Figure 2-E). This was corrected via cross elastic traction (Figure 2-F). The patient was followed during growth and no deviation or facial asymmetry occurred; hence no need for further orthodontic treatment.

3.1.3. Hemifacial microsomia

Case 3

A 9-year-old male patient with hemifacial microsomia type 2 A was planned to receive distraction osteogenesis for treatment of facial asymmetry (Figure 3-A, B). Mandibular ramus

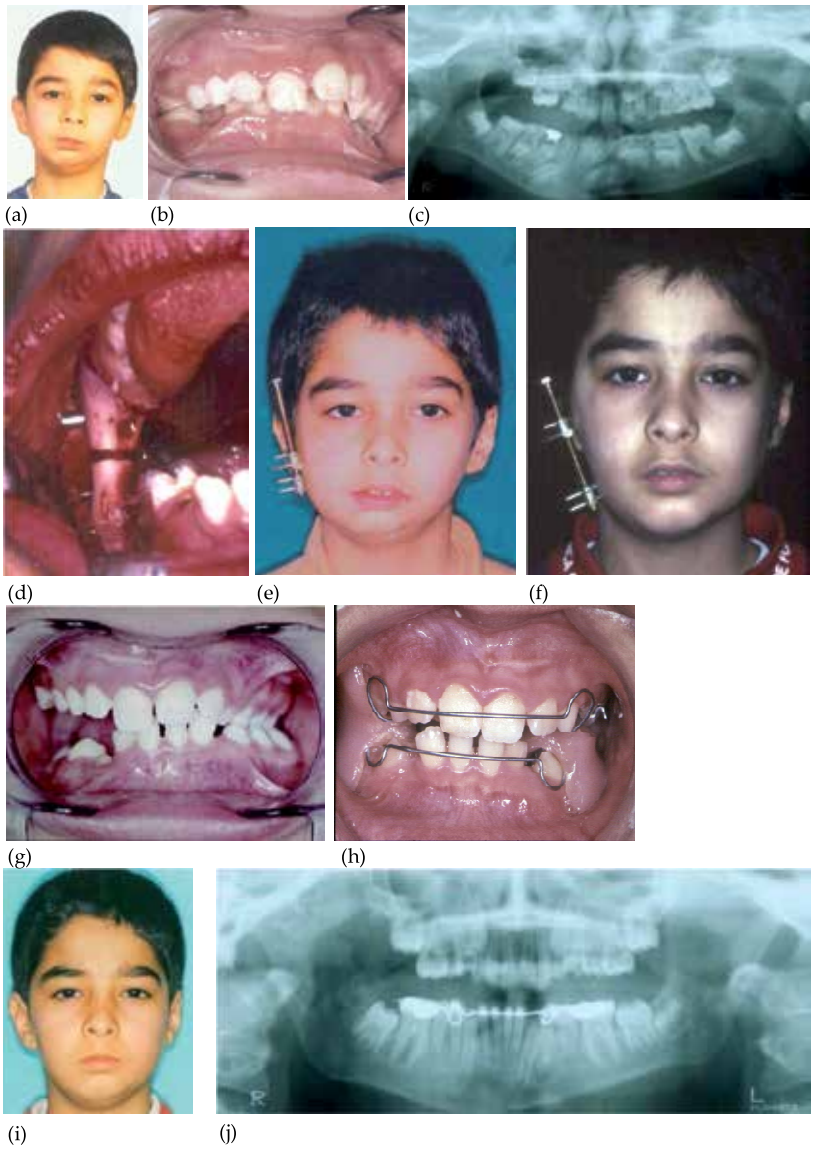

Figure 1. (a) Pre-distraction facial appearance. Facial asymmetry and cant of occlusal plane is apparent. (b) Pre-distraction intraoral view. (c) Panoramic view. (d) Horizontal osteotomy was made at the body of the right ramus below the mandibular foramen. (e) A custom-made unidirectional extraoral distractor was fixed in place. (f) Ramus was elongated by 22 mm. (g) The posterior open-bite was created at the right side as a result of mandibular lengthening. (h) A hybrid functional appliance was used to manage the posterior right open-bite. (i) Facial appearance 3 years post-distraction. (j) Panoramic view 3 years post-distraction.

was elongated using an extraoral distractor. Following a 2-month consolidation period, the distractor was removed. Orthodontic functional therapy was started to correct the posterior open bite (Figure 3-C, D). Orthodontic therapy was continued for 5 years (Figure 3-E, F).

http://dx.doi.org/10.5772/54647

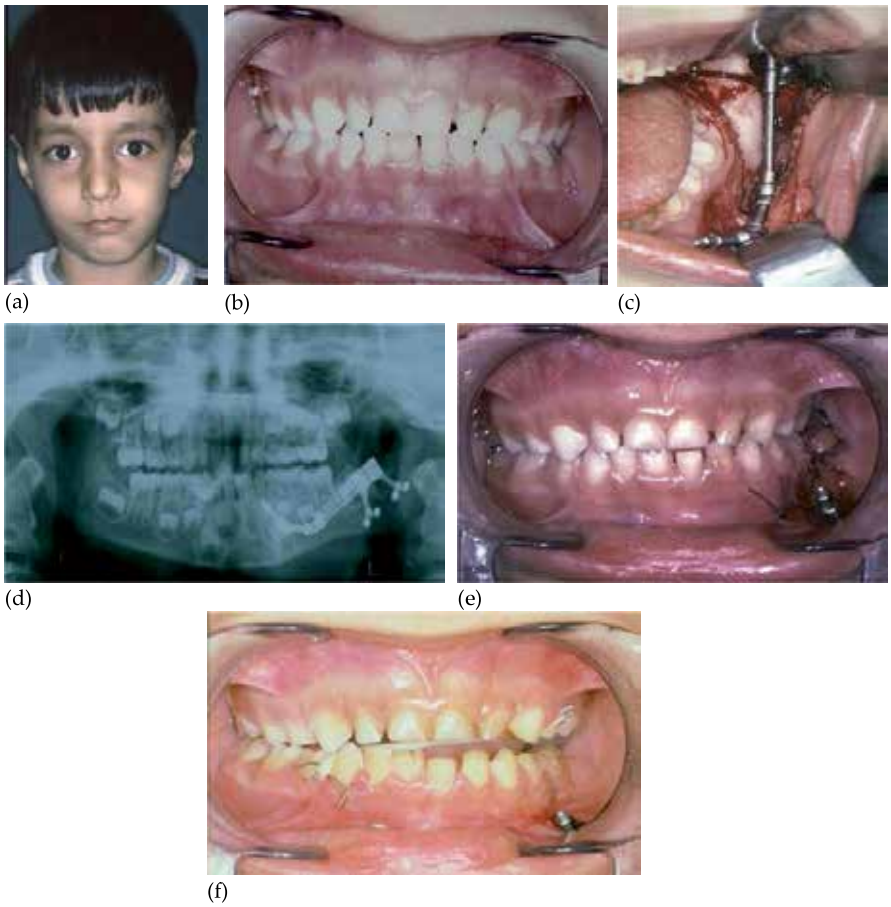

Figure 2. (a) Pre-distraction facial appearance demonstrates facial asymmetry due to childhood trauma. (b) Intraoral view shows midline deviation. (c) A horizontal osteotomy was made at the body of the right ramus and an intraoral distractor was fixed in place. (d) Distraction was initiated with an oblique vector. (e) Post-distraction intraoral view. Teeth were deviated to the opposite side. (f) Deviation was corrected via cross elastic traction.

3.1.4. Hemifacial microsomia

Case 4

A 17 year-old female patient with hemifacial microsomia presented with facial asymmetry and midline deviation to the right. The right maxillary canine was impacted (Figure 4-A-E). Pre-distraction orthodontic therapy included maxillary expansion and repositioning the impacted canine into the arch (Figure 4-F, G). Subsequently, unilateral osteotomy in the ramus was performed and an extraoral distraction device was fixed in place. With a rate of 1mm per day, distraction was continued until adequate elongation was obtained (Figure 4-H-K). Fixed orthodontic treatment was ongoing during the consolidation period (Figure 4-L). Final maxillary and mandibular arch coordination was achieved through bimaxillary orthognathic surgery (Figure 4-M-S).

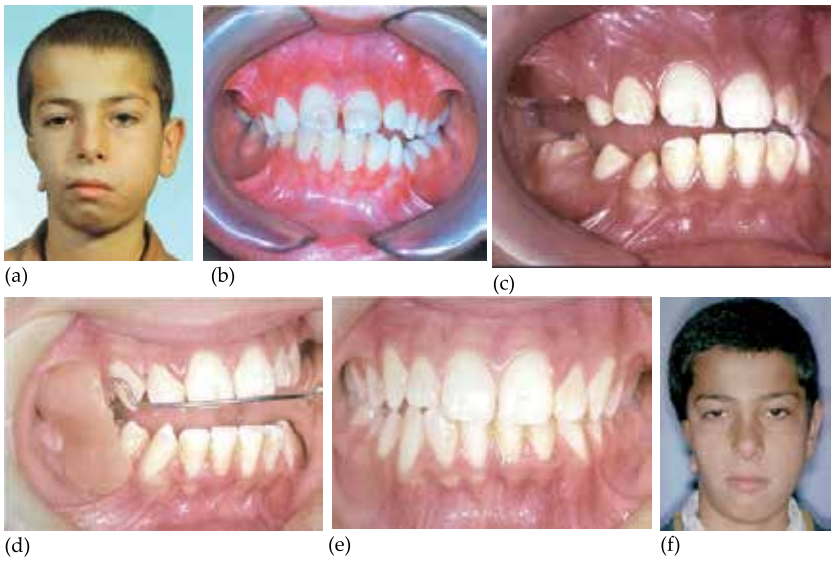

Figure 3. (a) Pre-distraction facial asymmetry due to hemifacial microsomia. (b) Pre-distraction intraoral view. (c) Post-distraction intraoral view. Unilateral posterior open was created. (d) Orthodontic functional therapy was started to correct the posterior open bite. (e) Five years post-distraction intraoral view. (f) Facial appearance 5 years post-distraction.

3.1.5. Facial asymmetry

Case 5

A 13-year-old female patient presented with mandibular deformity due to left condylar ankylosis (Figure 5-A). The patient had received a costochondral graft at age 6 and the function of the joint was restored (Figure 5-B). The remaining facial asymmetry was planned to be resolved via distraction osteogenesis. Using an extraoral custom-made distraction device, the left ramus was elongated by 18 mm (Figure 5-C). The resultant posterior open bite was corrected via 3 years of hybrid functional therapy followed by fixed orthodontic treatment (Figure 5-D, E, F).

3.1.6. Mandibular asymmetry due to condylar ankylosis

Case 6

A 16-year-old female patient presented with mandibular asymmetry due to left condylar ankylosis (Figure 6-A, B). At age 8, the patient had undergone a condylectomy procedure for treatment of the condylar ankylosis. She was then a candidate for distraction osteogenesis. Elongation of the left ramus (20 mm) was achieved by an extraoral distraction device (Leibinger Multiguide, Freiburg, Germany) (Figure 6-C, D). Eight months following removal of the distractor, the patient was orthodontically prepared for an orthognathic surgery. The surgery included Le Fort I and bilateral sagittal split osteotomies as well as genioplasty. A normal class I occlusion was obtained (Figure 6-E, F).

http://dx.doi.org/10.5772/54647

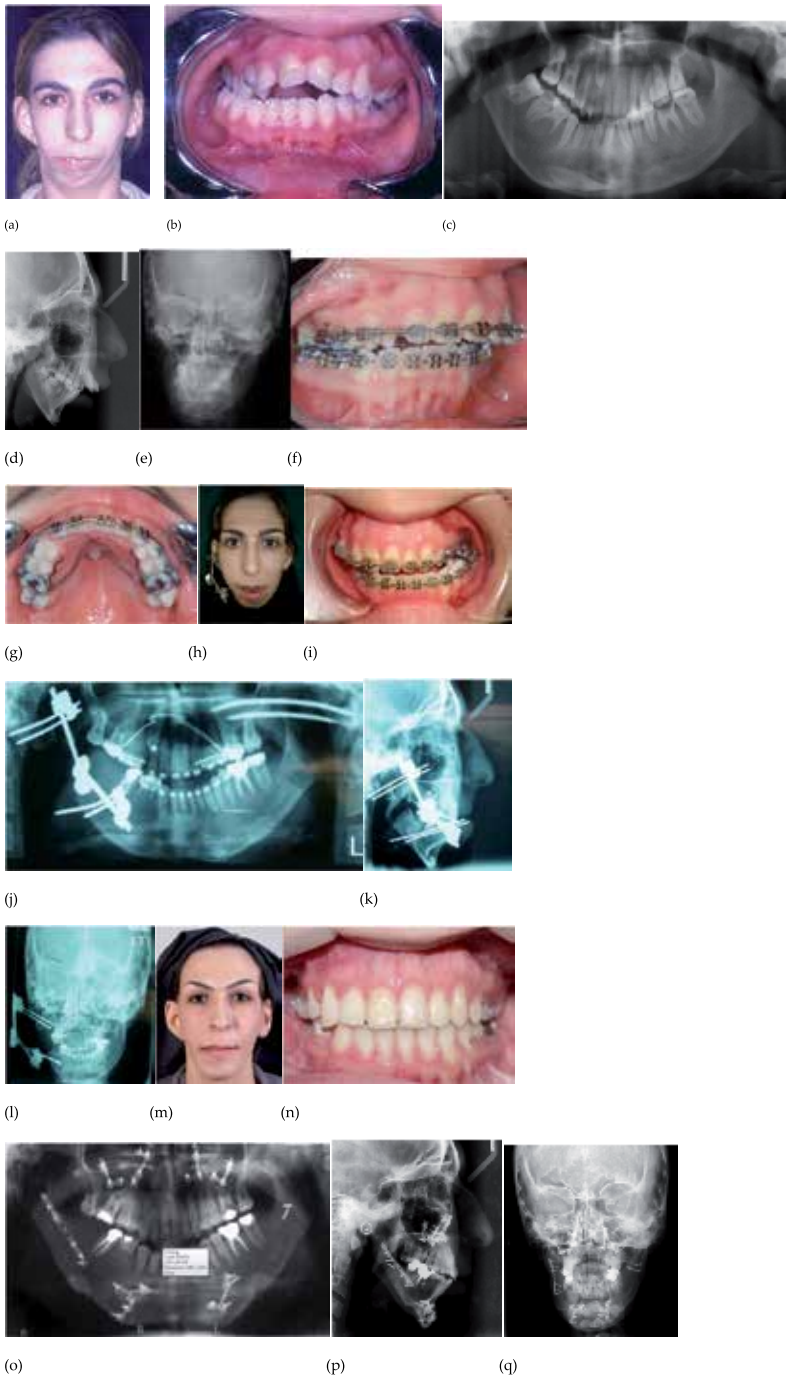

Figure 4. (a) Pre-distraction facial asymmetry. (b) Pre-distraction intraoral view. (c) Pre-distraction panoramic view. (d) Pre-distraction lateral cephalometric view. (e) Pre-distraction posteroanterior (PA) cephalometric view. (f) Orthodon-

tics included maxillary expansion. (g) The impacted canine was brought into the arch. (h) Post-distraction facial appearance. (i) Post-distraction intraoral view. (j) Post-distraction panoramic view. (k) Post-distraction lateral cephalometric view. (l) Post-distraction PA cephalometric view. (m) Post-orthognathic surgery facial appearance. (n) Post-orthognathic surgery intraoral view. (o) Post-orthognathic surgery panoramic radiograph. (p) Lateral cephalometric radiograph. (q) Post-orthognathic surgery PA cephalometric radiograph.

Figure 5. (a) Pre-distraction facial asymmetry. (b) Pre-distraction panoramic view. Bone screws remained from a previous costochondral bone graft can be observed. (c) Immediate post-distraction panoramic view. Mandibular ramus elongated by 18 mm. (d) Posterior open bite was corrected via functional therapy and fixed orthodontic therapy. (e) Six years post-distraction facial appearance. (f) Normal occlusion was obtained.

3.2. Bilateral hypoplasia

Similar to unilateral mandibular hypoplasia, several etiologies are documented for bilateral hypoplasia including syndromic conditions, condylar fracture due to trauma, and class II malocclusion. Along with undesirable facial appearance and disorders in the masticatory system, micrognathia which itself may be symmetric or asymmetric, can cause mild to lethal

http://dx.doi.org/10.5772/54647

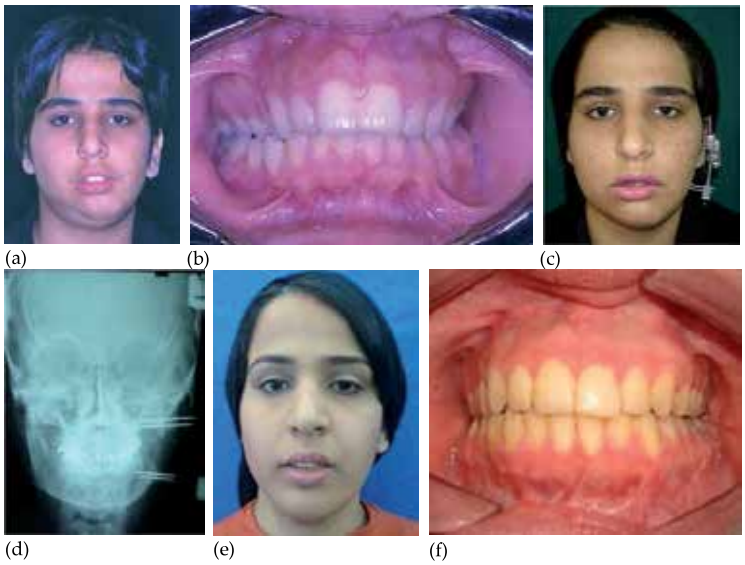

Figure 6. (a) Pre-distraction facial appearance. (b) Pre-distraction intraoral view. (c) Extraoral distractor was used for mandibular lengthening. (d) Left ramus was elongated by 20 mm. (e) Two years post-distraction facial appearance. Orthognathic surgery has been performed. (f) Normal occlusion has been obtained.

degrees of airway obstruction. [35] Havlik and Bartlett [36] as well as Moore and co-workers [37] were the first to apply distraction osteogenesis for management of micrognathia. A meta-analysis indicated Pierre Robin sequence as the most common condition treated with bilateral DO. [30] Pierre Robin syndrome is a congenital anomaly characterized as a triad of micrognathia, glossoptosis, and cleft palate. [38] Obstructive sleep apnea; recognized in severe degrees of the syndrome, implicates intervention at early ages. Severe airway obstruction which may also be a manifestation of temporomandibular joint ankylosis [39] is traditionally treated with tracheotomy. This invasive intervention although remains to be the gold standard, has been associated with considerable morbidity. [40] Mandibular DO allows for early treatment in neonates and infants. It is noteworthy that despite the promising results accomplished with DO at early ages [40]- [42], long-term follow-ups are required to evaluate the stability of the outcomes.

3.2.1. Severe mandibular deficiency

Case 7

A 6-year-old boy presented with severe mandibular deficiency. The patient suffered from obstructive sleep apnea (Figure 7-A-F). Prior to distraction osteogenesis, orthodontic treatment was done and included maxillary arch expansion with a quad-helix appliance followed by application of an anterior bite plate (Figure G). Subsequently, bilateral distraction osteogenesis was performed via extraoral multi-guide distraction devices (Leibinger, Freiburg, Germany). The amount of elongation obtained at the end of the distraction phase was about 32 mm;

though not equal on both sides (Figure H-J). Obstructive sleep apnea was completely resolved in this patient. Treatment was continued with functional orthodontic therapy; however, the patient was only followed for 2 years (Figure K-P).

3.2.2. Mandibular deficiency

Case 8

A 14-year-old patient presented with skeletal class II malocclusion and severe deep bite (Figure 8-A, B). The deficiency was planned to be corrected by distraction osteogenesis. Bilateral horizontal osteotomies were made in the body of the ramus. Unidirectional intraoral distractors (KLS Martin, Tuttlingen, Germany) were fixed in place (Figure 8-C). Following mandibular lengthening for 20 mm, an anterior open bite was created which could be attributable to improper distraction vector, a common adverse event with unidirectional distraction devices (Figure 8-D). This problem was solved by elastic traction (Figure 8-E) and normal occlusion was obtained. The patient has now been followed for 8 years (Figure 8-F, G).

3.3. Mandibular widening

Transverse mandibular deficiency is a common clinical problem, diagnosed by a narrow, V-shaped arch and anterior dental crowding. This problem may occur as an isolated condition, a component of certain syndromes [43], or a consequence of symphyseal fracture and tissue loss. [25], [44] Depending on the amount of the deficiency, various treatment protocols are available for mandibular arch expansion. The use of Arch wires, Schwarz plates, lingual arches and functional appliances has been hampered to some extent by the limited stability of the accomplished results. On the other hand, tooth extraction or interdental stripping, more commonly indicated for adult patients, may not provide adequate space in severe cases. [44], [45] Management of extreme transverse deficiencies was conventionally achieved via osteotomy and placement of bone grafts. Attempting to rectify the possible adverse events of bone grafting, Guerrero first used symphyseal distraction osteogenesis for mandibular widening and called it "rapid surgical mandibular expansion". [46] This technique holds promising potential for expansion of the mandibular basal bone. More predictable results can be obtained in a shorter treatment period. Yet, the probable relapse of the treatment gains is a major concern for surgeons. The possibility of teeth proclination, nonhomogeneous dental and skeletal expansion, as well as device-related difficulties should also be taken into consideration. [47] Based on the literature, symphyseal distraction osteogenesis has been suggested for patients above 12 years old. [1] Chung and Tae evaluated dental stability in an average 1.5 year follow-up duration subsequent to symphyseal distraction osteogenesis. By following the changes of 13 landmarks on study models, it was demonstrated that the total amount of surgical expansion did not decrease by relapse. [47] Both extraoral and intraoral distraction devices can be used for symphyseal distraction osteogenesis. Intraoral devices are more esthetically appealing. Though, as suggested by Kita et al, when extremely narrow mandibles are to be expanded, placement of intraoral devices may not be feasible due to inadequate space. Moreover, the design of intraoral distractors does not allow for large amounts of expansion. Kita et al used symphyseal distraction osteogenesis via extraoral devices to treat extreme transverse man-

http://dx.doi.org/10.5772/54647

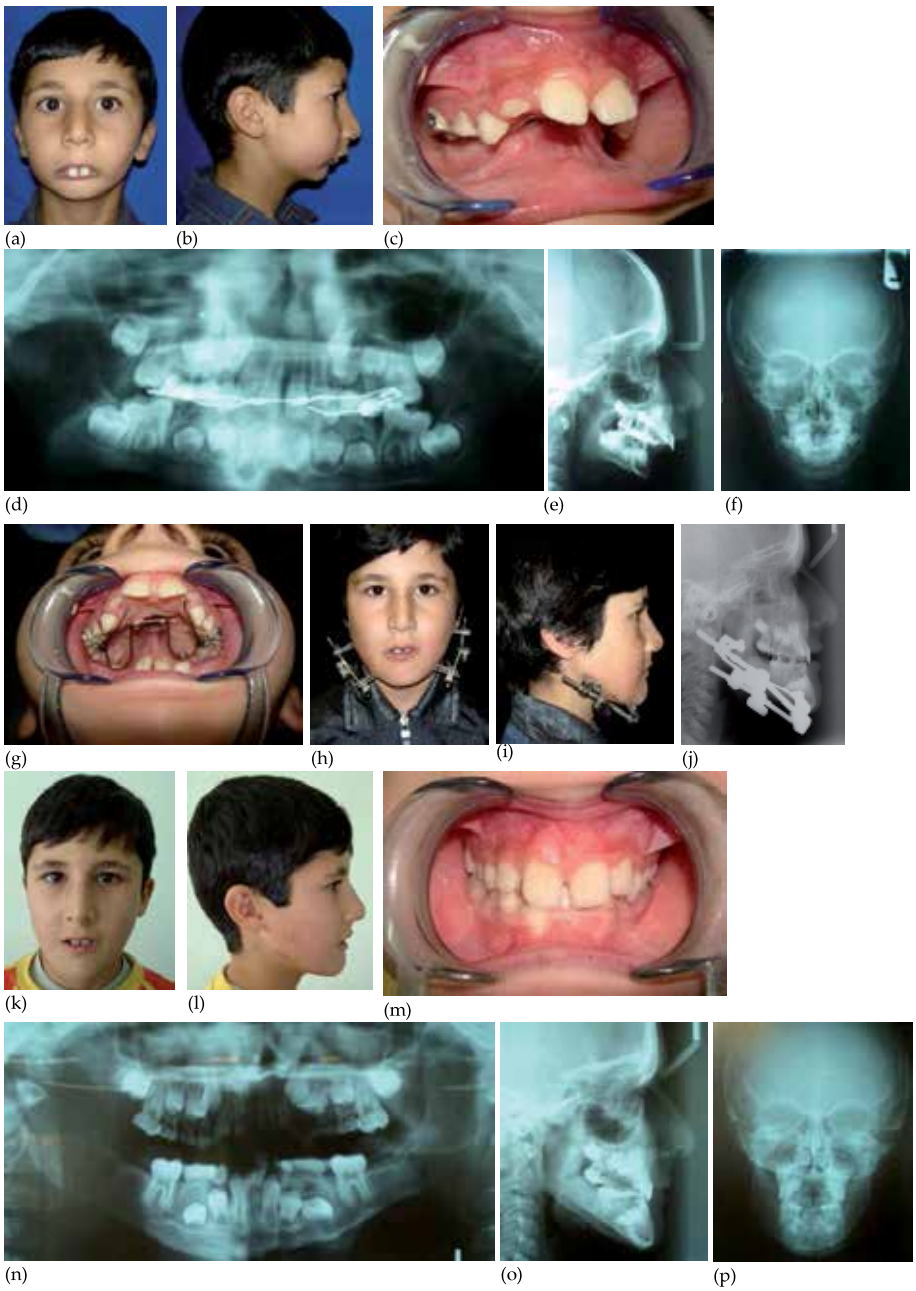

Figure 7. (a) Pre-distraction facial appearance. (b) Profile view. (c) Intraoral view. (d) Pre-distraction panoramic view. (e) Pre-distraction lateral cephalometric view. (f) Pre-distraction posteroanterior cephalometric view. (g) Pre-distraction orthodontic treatment included maxillary expansion via a quad-helix appliance. (h) Post-distraction facial appearance. (i) Profile view. (j) Lateral cephalometric view. (k) Two years post-distraction appearance. (l) Profile. (m) Intraoral view. (n) Two years post-distraction panoramic view. (o) Post-distraction lateral cephalogram. (p) Two years post-distraction PA cephalogram.

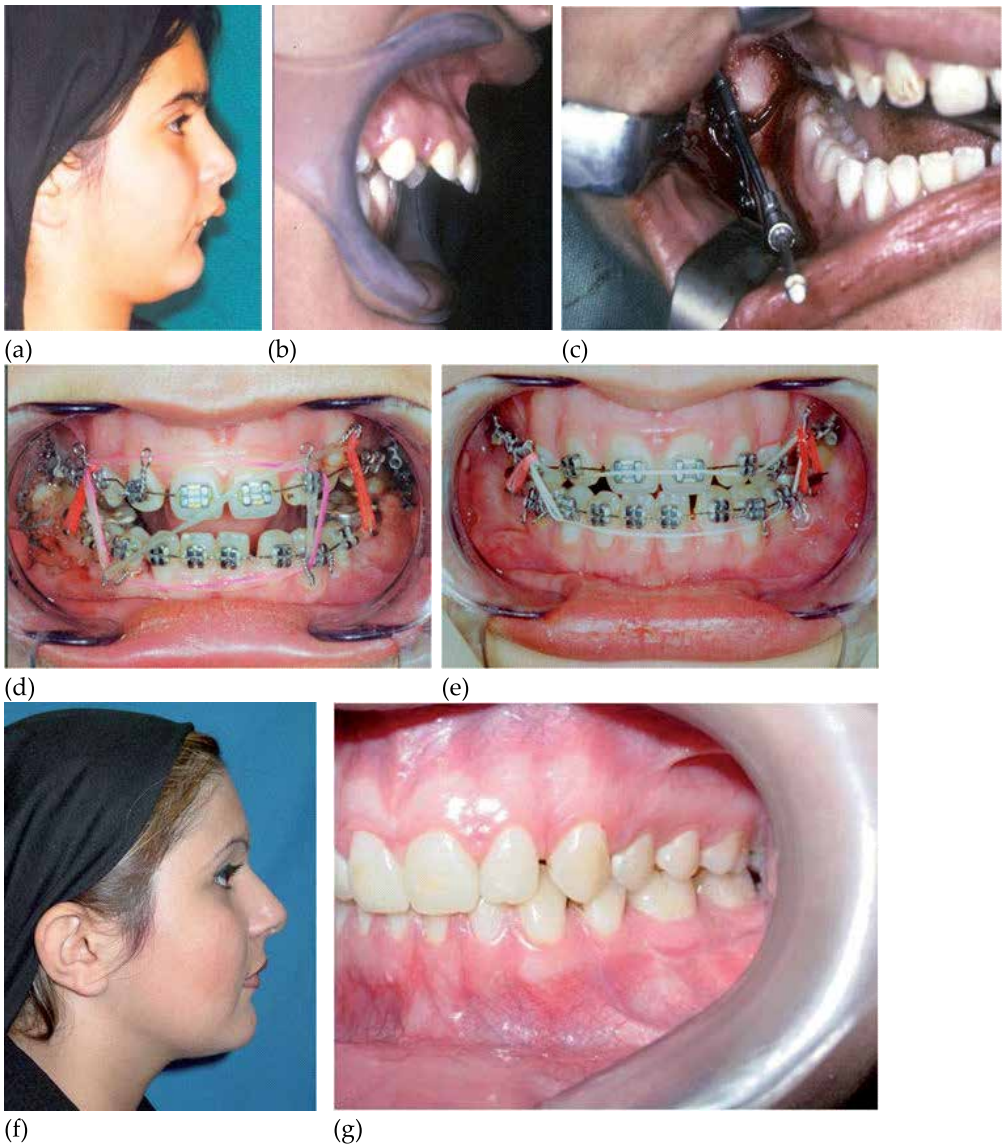

Figure 8. (a) Pre-distraction facial appearance. (b) Pre-distraction intraoral view. (c) Unidirectional intraoral distractors were fixed in place. (d) Following mandibular lengthening for 20 mm, an anterior open bite was created. (e) Anterior open bite was corrected by elastic traction. (f) Eight years post-distraction facial appearance. (g) Intraoral view.

dibular deficiencies in patients with hypoglossia-hypodactyly syndrome. [43]A plethora of investigations and modifications have attributed to enhanced efficiency of mandibular distraction osteogenesis. Yet, the technique is not exempt of adverse events. Diverse rates of incidence have been reported for different mandibular distraction osteogenesis procedures. Shetye et al [29] classified the potential adverse events associated with mandibular DO into three groups: minor incidents indicated those with no influence on the outcome. Moderate and

major incidents were both defined as events that result in undesirable outcome and can or cannot be resolved via invasive procedures, respectively. Their 16 year follow-up of 141 patients who underwent mandibular DO for unilateral or bilateral mandibular lengthening demonstrated that minor and moderate incidents were reported in 26.99% and 20.35%, respectively; while in only 5.31% of patients did major events occur. The majority of major incidents included TMJ ankylosis and derangements as well as fibrous union. Nevertheless, taken all the above-mentioned complications into considerations, investigators seem to be unanimous in the safety of distraction osteogenesis.

3.4. Maxillary distraction osteogenesis

The Principles of distraction osteogenesis have been applied for correction of transverse and sagittal discrepancies of the maxilla and the midface associated with orofacial clefts and several syndromes. Midfacial distraction osteogenesis was first evaluated in animal studies performed on sheep [48] and dogs [49]. A preliminary human report of maxillary and midfacial advancement through the application of a distraction device was published by Cohen et al in 1997. [50] Two children with cleft lip and palate, midfacial hypoplasia, and class III malocclusion underwent treatment with distraction osteogenesis. Up to 11 mm advancement of the midfacial complex was achieved in both patients. Two years later, Mommaerts introduced a technique for maxillary expansion using a transpalatal distractor. [51] In comparison to rapid palatal expansion, the treatment protocol most frequently used for maxillary expansion, palatal distraction osteogenesis was asserted to eliminate particular adverse events such as alveolar bending, tooth tipping, buccal cortex fenestration, and relapse. Common indications for maxillary and midface distraction osteogenesis are summarized in Table 2.

Orofacial Clefts
Craniosynostosis
Crouzon's Syndrome
Apert's Syndrome
Pfeiffer Syndrome
Midface deficiencies of other causes
Alveolar deficiencies

Table 2. Common indications for maxillary and midface distraction osteogenesis.

3.5. Maxillary and midfacial advancement

The majority of cleft lip and palate patients suffer from degrees of maxillary hypoplasia, either as a primary manifestation of the cleft or secondary to attempts for cleft repair. This often complex discrepancy is conventionally corrected through a series of surgeries including different osteotomies. The inception of distraction osteogenesis for advancement of maxillary-midface in cleft patients brought new insight into the treatment of these patients. A meta-analysis of conventional osteotomies and distraction osteogenesis, along with many similarities between the two techniques, suggested distraction osteogenesis to be advanta-

geous for it eliminates the need for bone grafts. [52] Moreover, it was demonstrated that most protocols postponed treatment with conventional osteotomies until growth was completed. In contrast, distraction osteogenesis was more frequently performed in growing patients; although, overcorrection was recommended to preclude relapse. Different types of extraoral and intraoral distractors have been established for maxillary distraction osteogenesis. Extraoral distractors have the capacity for multidirectional maxillary advancement and the vectors can be changed during the process. [53] Yet, many patients have difficulty accepting extraoral devices primarily due to the unappealing appearance and discomfort. [54] Moreover, the external position of these devices makes them prone to loosening and fracture following an accidental trauma. [53] Rigid external distraction (RED) device is fixed to the cranium. This allows for protection of maxillary teeth comparing to other types of extraoral devices which are anchored to the maxilla. [54] The stability of maxillary advancement with RED was evaluated in a 3-year prospective study. To avoid the possible interference of growth in the outcomes, the study was performed on adult patients. The relapse was reported to be 22% after 3 years. [55] Internal distractors cause less psychosocial problems for the patient and are less likely to be loosened or displaced during the distraction period or following traumatic forces. Moreover, being more easily tolerated by patients, an internal device can be maintained during the consolidation phase for as long as deemed necessary for prevention of relapse. [53], [54], [56] Nevertheless, installation of intraoral distractors may not be always feasible due to inadequate space. In addition, intraoral distractors provide unidirectional bone movement; hence demanding precise positioning. [53] Complications such as fracture and collapse of the cleft alveolar bone has been reported with intraoral devices used for Le Fort I distraction. [56] Picard et al described a rigid internal device (RID) with the ability to provide unrestricted lengthening for total or segmental advancement of the maxilla. In 19 syndromic, cleft, and traumatic patients treated with this distractor, an average advancement of 9.6 mm was achieved. [54] A retrospective study comparing extraoral and intraoral distractors for midface advancement in syndromic patients demonstrated no significant difference regarding the complication rate and amount of lengthening between the two types. Accordingly, both distractors were asserted to be safe and it was suggested that choosing a device be individualized based on each patients needs and toleration. [53]Mild to moderate cases of maxillary hypoplasia which were traditionally corrected via Le Fort I osteotomy, have been successfully treated with anterior maxillary distraction osteogenesis. [57] Le Fort I osteotomy shows a negative impact on velopharyngeal competence and speech while this problem is rarely seen with anterior maxillary distraction osteogenesis. [57] Nonetheless, more severe cases may necessitate Le Fort I distraction.

3.5.1. Cleft lip and palate and class III malocclusion

Case 9

A 17-year-old female patient with cleft lip and palate presented with a class III malocclusion and anterior and posterior cross bite (Figure 9 A-C). Following pre-distraction orthodontic treatment, maxillary advancement was performed through Le Fort I osteotomy and RED device (KLS Martin, Figure 9-D). Maxilla was advanced by 18 mm (Figure 9-E, F). Orthodontic

http://dx.doi.org/10.5772/54647

treatment continued for a year. Meanwhile, the patient received a removable partial prosthesis to replace the anterior missing teeth. Subsequently, the patient underwent rhinoplasty and primary lip repair (Figure 9-G-J). The procedures for lip repair are still ongoing.

Figure 9. (a) Pre-distraction appearance. (b) Profile view. (c) Lateral cephalometric view. (d) Maxillary distraction osteogenesis was performed using an RED device. (e) Post-distraction facial appearance. (f) Post-distraction lateral cephalometric view. (g) Two years post-distraction facial appearance. (h) Profile. (i) Intraoral view. (j) Lateral cephalometric view.

Distraction osteogenesis has also proved valuable for treatment of patients affected with craniosynostosis. This condition caused as a result of premature fusion of cranial sutures is a clinical feature of particular syndromes such as Crouzon, Apert, and Pfeiffer. In the severe expression of these syndromes, it may be crucial to initiate treatment as early as 1 year of age. [58] Le Fort III and monobloc osteotomies are frequently used for management of craniosynostosis. [59] During the recent years, distraction osteogenesis has become popular for correction of syndromic maxillary hypoplasia. The amount of advancement of midface that can be achieved by distraction osteogenesis is generally greater than the amount obtained by conventional osteotomies such as Le Fort III and monobloc osteotomy. [60] Long-term follow

ups of syndromic patients who underwent maxillary-midface advancement with distraction osteogenesis have proved the stability of the results. [59], [61], [62]

3.6. Maxillary expansion

Maxillary transverse deficiency is a condition associated with anterior and posterior dental crowding, unilateral or bilateral cross-bite, as well as TMJ and respiratory problems. Expansion of maxillary bone during growth is usually feasible through orthodontic treatments. However, with skeletal maturation, a combination of surgical and orthodontic techniques may be inevitable in order to accomplish adequate expansion. When the condition is accompanied with cleft lip and palate, it poses even greater challenges for treatment. Treatment of maxillary constriction can be performed by means of Le Fort I osteotomy and expansion. This protocol allows for multidirectional expansion of the maxillary complex; however, the resistance of the palatal fibromucosa diminishes the stability of the results. Another treatment option established for this deformity is surgically assisted rapid maxillary expansion (SARME). This technique eliminates soft tissue resistance via distraction histogenesis and can be based upon either tooth-borne or bone-borne devices. Tooth-borne distractors transfer forces to the teeth, leading to tooth-related adverse events such as root resorption, tooth tipping, and cortical fenestration. In contrast, bone-borne devices; first introduced by Mommaerts as a transpalatal distractor (TPD), are exempt of these undesirable effects for they directly apply forces to the bone. [63], [64] Application of bone-borne distractors becomes of paramount importance particularly when insufficient tooth support exists due to tooth missing and impaction. [65] Yet, they require a secondary surgery for removal. [63], [64] It is noteworthy that despite the disadvantages commonly considered for tooth-borne device, no considerable difference in dental tipping and stability has been found between tooth-borne and bone-borne maxillary distractors. [64], [66]

3.6.1. Skeletal class III malocclusion and narrow maxilla

Case 10

A 25-year-old female patient presented with dental and skeletal class III malocclusion and a narrow maxilla. Both maxillary and mandibular midlines had a shift to the right side. A 2-mm reverse over jet and anterior and posterior cross bites were present (Figure 10-A-D). Restriction in mandibular movement was found on examination. Treatment plan included SARPE via Smile distractor (Titamed). Transverse distraction was started at a rate of 1mm/ day and continued until 10 mm expansion was achieved (Figure 10-E, F). Post-distraction fixed orthodontic treatment closed the resultant gap between the two central incisors and repositioned the right lateral incisor into the dental arch (Figure 10-G-J).

3.6.2. Maxillary transverse deficiency

Case 11

A 20-year-old male patient presented with a class III malocclusion, maxillary transverse deficiency, severe anterior crowding, anterior open-bite, and bilateral cross-bite (Figure 11-A-

http://dx.doi.org/10.5772/54647

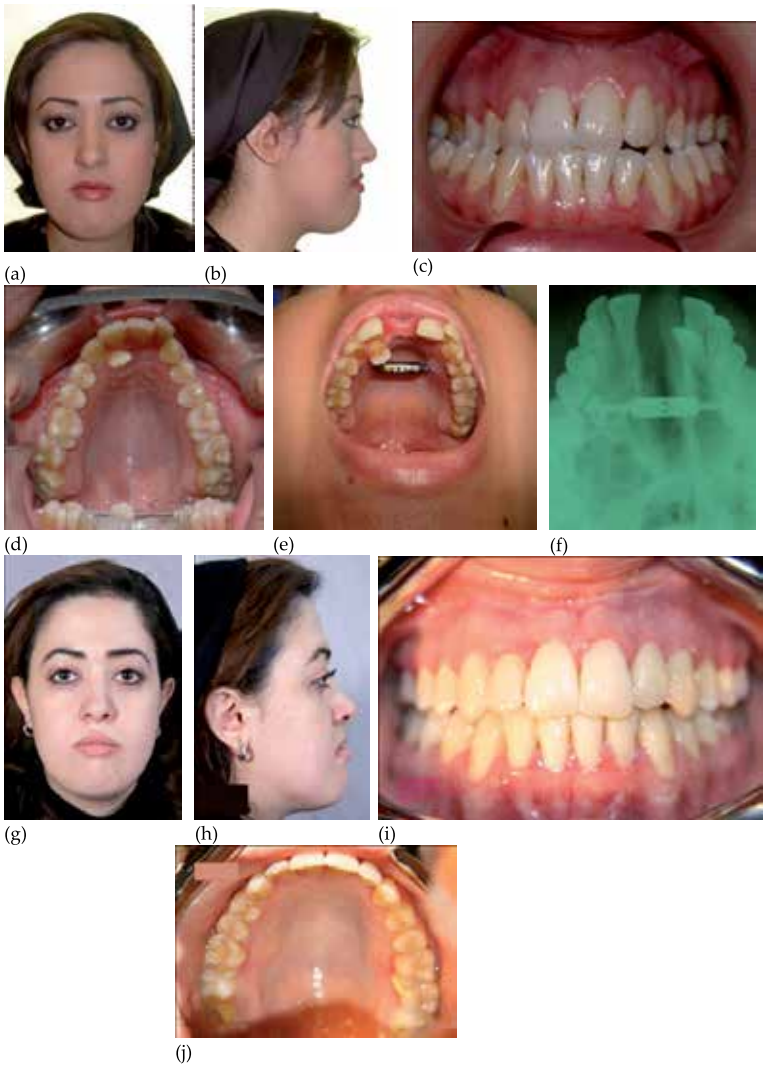

Figure 10. (a) Pre-distraction facial appearance. (b) Profile. (c) Intraoral view. (d) Pre-distraction intraoral view, the right lateral incisor is in a palatal position. (e) Post-distraction intraoral view. Maxilla expanded by 10mm. (f) Post-distraction radiograph. (g) Post-orthodontic treatment facial appearance. (h) Profile. (i) Intraoral view. (j) Post-orthodontic intraoral view. The right lateral incisor is repositioned into the arch.

E). The treatment plan included SARME with a bone-borne distractor followed by orthognathic surgery in order to respectively correct the transverse deficiency and the open bite. An osteotomy was made in the palatal midline, between the roots of the two central incisors and the distraction device (Smile distractor, Titamed) was placed (Figure 11-F-H). Following a 7-day latency period, the distractor was activated at a rate of 1mm/ day. When expansion of 10 mm was achieved, activation was stopped and the device was maintained for a 2-month consolidation period (Figure 11-I). The device was kept for another 4 months until the space

created between the central incisors was closed by orthodontic forces. Subsequently, the patient was orthodontically prepared for orthognathic surgery, Le Fort I osteotomy (Figure 11-K). Arch coordination was obtained. The patient is still under orthodontic treatment (Figure 11-L-P). It is worth mentioning that in this patient, alignment of maxillary teeth could have been achieved by extraction of premolars and fixed orthodontic therapy. However, this treatment protocol would impede maxillary and mandibular arch coordination. On the other hand, it is important that the amount of maxillary expansion is proportional to the mandibular arch.

3.7. Alveolar distraction osteogenesis

Alveolar distraction osteogenesis is pre-implant/ pre-prosthetic procedure which tends to restore the alveolar deficiencies and prepare the alveolar ridge for further rehabilitative treatments. Alveolar distraction osteogenesis was first evaluated in an animal model by Block et al. [67] Chin and Toth extended its application to human. [68] Alveolar ridge augmentation is frequently conducted via the use of different types of bone grafts. However, distraction osteogenesis not only decreases the complications and the duration of treatment, but also allows for reconstruction of large defects by simultaneously expanding the surrounding soft tissue. [69] Studies have suggested the amount of newly formed bone resorption prior to implant placement to be greater with onlay bone grafting in comparison to distraction osteogenesis. Peri-implant bone loss was comparable between the two techniques. [70], [71] On the other hand, the amount of augmentation gained with distraction osteogenesis was reported to be significantly greater than that obtained with inlay bone grafts. [72] Depending on the type and the extension of an alveolar defect, distraction osteogenesis may be considered either as an absolute treatment for reconstruction or as an adjunctive therapy along with other bone grafting procedures. Jensen and Block presented a classification of alveolar defects aiming to facilitated treatment planning with alveolar distraction osteogenesis. Accordingly, the more complex a defect, the greater the possibility of requiring bone grafts prior or subsequent to distraction osteogenesis. [73] This treatment modality can also be considered when previous attempts for bone grafting have failed. [74]

3.7.1. Vertical alveolar distraction osteogenesis

The technique of alveolar distraction osteogenesis have been successfully used for enhancing alveolar ridge height. [69], [74]- [81] The majority of studies evaluated the efficiency of distraction osteogenesis in the anterior parts of maxilla and mandible and the amount of obtained augmentation was reported between 5 to 15 mm. Benefits of this method for augmentation of severely atrophic ridges remains to be a matter of controversy. Basal bone fracture and neurosensory complications have been suggested as the two most common problems associated with vertical distraction of atrophic mandibular ridges. [82] Indication of vertical alveolar distraction osteogenesis is therefore limited to areas where 5-7 mm of alveolar bone exists. [83]

http://dx.doi.org/10.5772/54647

Figure 11. (a) Pre-distraction facial appearance. (b) Profile. (c) Intraoral view. (d) Pre-distraction panoramic view. (e) Pre-distraction lateral cephalometric view. (f) Osteotomy was made in the palatal midline. (g) Palatal distractor in place before activation. (h) Periapical radiography. (i) Two months post-distraction intraoral view. (j) Two months post-distraction occlusal radiograph. (k) Anterior open bite was planned to be corrected via orthognathic surgery. (l) Post-orthognathic surgery facial appearance. (m) Profile. (n) Intraoral view. (o) Post-orthognathic surgery panoramic view. (p) Post-orthognathic cephalometric view.

Distraction devices for alveolar distraction osteogenesis include both extraoral and intraoral devices as well as distraction implants. Extraoral distractors which are mainly positioned subperiosteally in the buccal vestibule, can only be used when a bone height of 6-7 mm is present. Comparing intraoral and extraoral distractors for alveolar distraction osteogenesis, Uckan et al demonstrated that the majority of complications associated with intraoral distractors were related to displacement and fracture of the transport segment. However, interference of the device with the opposing dental arch was considered the most frequent complication with extraoral distractors. [71] Distraction implants initially pose distraction forces to augment the alveolar ridge and are subsequently kept in place to act as a dental implant. These devices have the advantage of eliminating the need for a second surgery for distractor removal. Yet, it is highly likely that the ideal position of the distractor does not correspond to the desirable position of the implant. [81], [83]

3.7.2. Alveolar deficiency

Case 11

A 20 year-old female patient presented with a large bone defect in the anterior mandible due to resection of a central giant cell granuloma (Figure 12-A, B). The patient underwent alveolar distraction osteogenesis. Horizontal osteotomy was performed and an intraoral distractor (KLS Martin) was placed (Figure 12-C, D). Following a 7-day latency phase distraction was initiated at a rate of 1 mm per day. 18mm augmentation was achieved (Figure 12-E). After the consolidation period, the distractor was removed and dental implants were inserted into the regenerated bone. Due to insufficient ridge width, a guided bone regeneration procedure was done to induce bone regeneration over the exposed surfaces of the implants (Figure 12-F). 3 months later, at the second stage of implant surgery inadequate keratinized tissue was compensated by a connective tissue graft from the palate (Figure 12-G-I). Fixed implant-supported prosthesis restored the missing teeth (Figure 12-J).

3.8. Horizontal alveolar distraction osteogenesis

Horizontal alveolar ridge augmentation through distraction osteogenesis demands for extreme preciseness in technique and the design of distractors. The amount of alveolar ridge width increase reported with distraction osteogenesis is 2.5 mm to 7 mm. [84]- [89] Horizontal alveolar distraction can be conducted via simple bone screws to meticulously designed distractors. All devices have a distraction rod in common which is fixed in the cortical lingual/ palatal bone plate and allows for the buccal/ labial movement of the transfer segment. [84] Nevertheless, the intricacy of device positioning as well as the difficulty of performing an osteotomy in a narrow alveolar ridge have greatly restricted the indication of horizontal alveolar distraction osteogenesis. [85] Therefore, in many cases with horizontal alveolar deficiency, bone grafting techniques become advantageous over distraction osteogenesis.

http://dx.doi.org/10.5772/54647

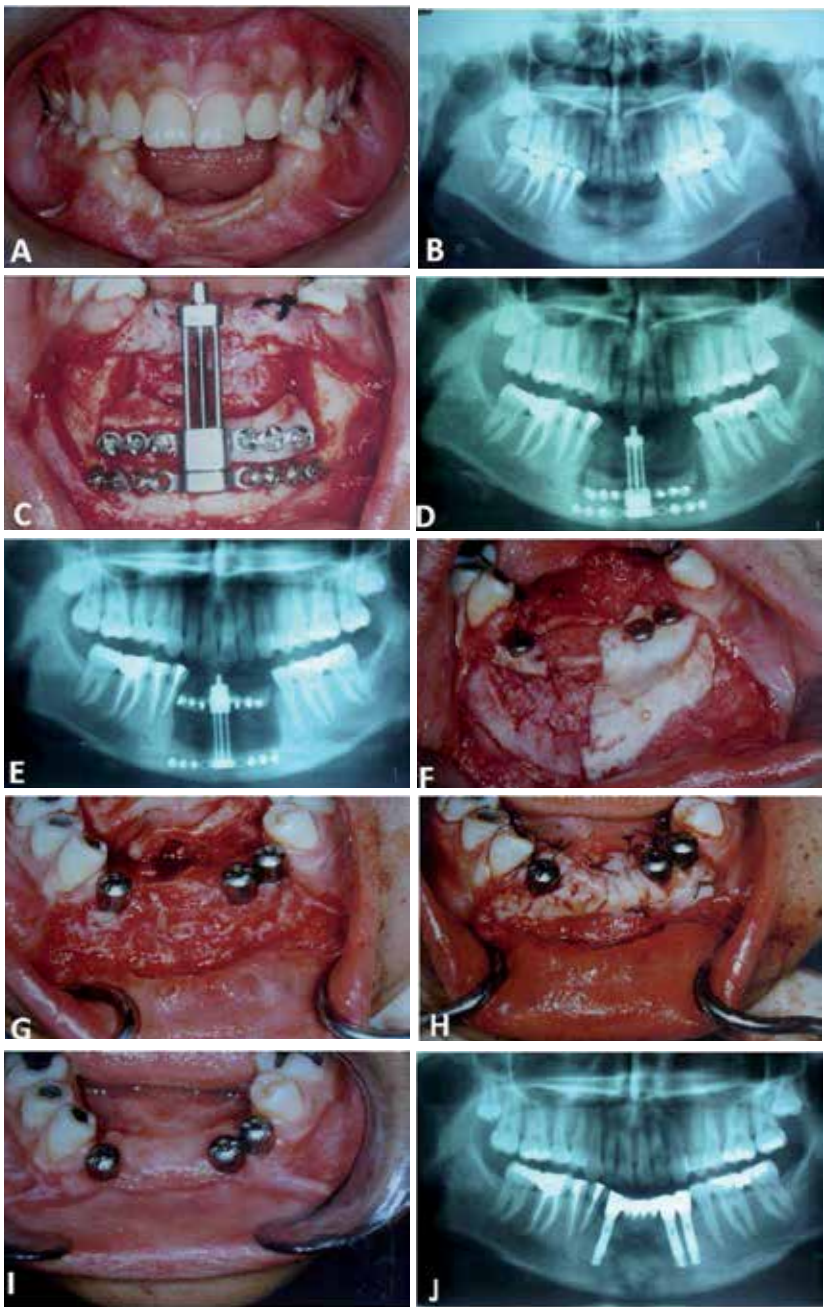

Figure 12. A. Large bone defect in the anterior mandible due to resection of a central giant cell granuloma. Intraoral view. B. Large anterior mandibular defect. Panoramic view. C. Intraoral distractor was placed. D. Panoramic view. E. Post-distraction panoramic view 18mm augmentation was achieved. F. As a result of insufficient ridge width, a guided bone regeneration was done with implant placement. G. Second stage implant surgery, 3 months later. H. Inadequate keratinized tissue was compensated by a connective tissue graft harvested from the palate. I. Two months following the second stage implant surgery. J. Fixed implant-supported prosthesis was placed. Panoramic view.

Acknowledgements

The authors wish to express their sincere gratitude to Dr. Ladan Eslamian; Professor of Department of Orthodontics, School of Dentistry, Shahid Beheshti university of Medical Sciences who took the responsiblity for orthodontic management of one of our patients, presented as case 9.

Author details

Hossein Behnia[1*], Azita Tehranchi[2] and Golnaz Morad[3]

1 Department of Oral and Maxillofacial Surgery, School of Dentistry, Shahid Beheshti University of Medical Sciences, Tehran, Iran

2 Department of Orthodontics, School of Dentistry, Shahid Beheshti University of Medical Sciences, Tehran, Iran

3 Dental Research Center, Shahid Beheshti University of Medical Sciences, Tehran, Iran

References

[1] Swennen G, Schliephake H, Dempf R, Schierle H, Malevez C. Craniofacial distraction osteogenesis: a review of the literature: Part 1: clinical studies. Int J Oral Maxillofac Surg 2001;30(2):89-103.

[2] Codivilla A. The classic: On the means of lengthening, in the lower limbs, the muscles and tissues which are shortened through deformity. 1905. Clin Orthop Relat Res 2008;466(12):2903-9.

[3] Abbott LC, Saunders JB. The Operative Lengthening of the Tibia and Fibula: a Preliminary Report on the Further Development of the Principles and Technic. Ann Surg 1939;110(6):961-91.

[4] McCarthy JG, Schreiber J, Karp N, Thorne CH, Grayson BH. Lengthening the human mandible by gradual distraction. Plast Reconstr Surg 1992;89(1):1-8; discussion 9-10.

[5] Ai-Aql ZS, Alagl AS, Graves DT, Gerstenfeld LC, Einhorn TA. Molecular mechanisms controlling bone formation during fracture healing and distraction osteogenesis. J Dent Res 2008;87(2):107-18.

[6] Marsh DR, Li G. The biology of fracture healing: optimising outcome. Br Med Bull 1999;55(4):856-69.

[7] Morgan EF, Gleason RE, Hayward LN, Leong PL, Palomares KT. Mechanotransduction and fracture repair. J Bone Joint Surg Am 2008;90 Suppl 1:25-30.

[8] Ilizarov GA. The tension-stress effect on the genesis and growth of tissues. Part I. The influence of stability of fixation and soft-tissue preservation. Clin Orthop Relat Res 1989(238):249-81.

[9] Fischgrund J, Paley D, Suter C. Variables affecting time to bone healing during limb lengthening. Clin Orthop Relat Res 1994(301):31-7.

[10] Aronson J. Experimental and clinical experience with distraction osteogenesis. Cleft Palate Craniofac J 1994;31(6):473-81; discussion 81-2.

[11] Aronson J, Shen X. Experimental healing of distraction osteogenesis comparing metaphyseal with diaphyseal sites. Clin Orthop Relat Res 1994(301):25-30.

[12] Moore C, Campbell PM, Dechow PC, Ellis ML, Buschang PH. Effects of latency on the quality and quantity of bone produced by dentoalveolar distraction osteogenesis. Am J Orthod Dentofacial Orthop;140(4):470-8.

[13] Aronson J, Good B, Stewart C, Harrison B, Harp J. Preliminary studies of mineralization during distraction osteogenesis. Clin Orthop Relat Res 1990(250):43-9.

[14] Vauhkonen M, Peltonen J, Karaharju E, Aalto K, Alitalo I. Collagen synthesis and mineralization in the early phase of distraction bone healing. Bone Miner 1990;10(3): 171-81.

[15] Ilizarov GA. The tension-stress effect on the genesis and growth of tissues: Part II. The influence of the rate and frequency of distraction. Clin Orthop Relat Res 1989(239):263-85.

[16] Merloz P. Bone regeneration and limb lengthening. Osteoporos Int;22(6):2033-6.

[17] Michieli S, Miotti B. Lengthening of mandibular body by gradual surgical-orthodontic distraction. J Oral Surg 1977;35(3):187-92.

[18] Snyder CC, Levine GA, Swanson HM, Browne EZ, Jr. Mandibular lengthening by gradual distraction. Preliminary report. Plast Reconstr Surg 1973;51(5):506-8.

[19] Altug-Atac AT, Grayson BH, McCarthy JG. Comparison of skeletal and soft-tissue changes following unilateral mandibular distraction osteogenesis. Plast Reconstr Surg 2008;121(5):1751-9.

[20] Ow A, Cheung LK. Skeletal stability and complications of bilateral sagittal split osteotomies and mandibular distraction osteogenesis: an evidence-based review. J Oral Maxillofac Surg 2009;67(11):2344-53.

[21] Schreuder WH, Jansma J, Bierman MW, Vissink A. Distraction osteogenesis versus bilateral sagittal split osteotomy for advancement of the retrognathic mandible: a review of the literature. Int J Oral Maxillofac Surg 2007;36(2):103-10.

[22] Kaban LB, Moses MH, Mulliken JB. Surgical correction of hemifacial microsomia in the growing child. Plast Reconstr Surg 1988;82(1):9-19.

[23] Padwa BL, Mulliken JB, Maghen A, Kaban LB. Midfacial growth after costochondral graft construction of the mandibular ramus in hemifacial microsomia. J Oral Maxillofac Surg 1998;56(2):122-7; discussion 27-8.

[24] Pereira MA, Luiz de Freitas PH, da Rosa TF, Xavier CB. Understanding distraction osteogenesis on the maxillofacial complex: a literature review. J Oral Maxillofac Surg 2007;65(12):2518-23.

[25] Tae KC, Kang KH, Kim SC. Unilateral mandibular widening with distraction osteogenesis. Angle Orthod 2005;75(6):1053-60.

[26] McCarthy JG, Staffenberg DA, Wood RJ, Cutting CB, Grayson BH, Thorne CH. Introduction of an intraoral bone-lengthening device. Plast Reconstr Surg 1995;96(4): 978-81.

[27] Boccaccio A, Cozzani M, Pappalettere C. Analysis of the performance of different orthodontic devices for mandibular symphyseal distraction osteogenesis. Eur J Orthod; 33(2):113-20.

[28] Raoul G, Wojcik T, Ferri J. Outcome of mandibular symphyseal distraction osteogenesis with bone-borne devices. J Craniofac Surg 2009;20(2):488-93.

[29] Shetye PR, Warren SM, Brown D, Garfinkle JS, Grayson BH, McCarthy JG. Documentation of the incidents associated with mandibular distraction: introduction of a new stratification system. Plast Reconstr Surg 2009;123(2):627-34.

[30] Ow AT, Cheung LK. Meta-analysis of mandibular distraction osteogenesis: clinical applications and functional outcomes. Plast Reconstr Surg 2008;121(3):54e-69e.

[31] Kofod T, Norholt SE, Pedersen TK, Jensen J. Unilateral mandibular ramus elongation by intraoral distraction osteogenesis. J Craniofac Surg 2005;16(2):247-54.

[32] Shetye PR, Grayson BH, Mackool RJ, McCarthy JG. Long-term stability and growth following unilateral mandibular distraction in growing children with craniofacial microsomia. Plast Reconstr Surg 2006;118(4):985-95.

[33] Tehranchi A, Behnia H. Facial symmetry after distraction osteogenesis and orthodontic therapy. Am J Orthod Dentofacial Orthop 2001;120(2):149-53.

[34] Tehranchi A, Behnia H. Treatment of mandibular asymmetry by distraction osteogenesis and orthodontics: a report of four cases. Angle Orthod 2000;70(2):165-74.

[35] Wang X, Wang XX, Liang C, Yi B, Lin Y, Li ZL. Distraction osteogenesis in correction of micrognathia accompanying obstructive sleep apnea syndrome. Plast Reconstr Surg 2003;112(6):1549-57; discussion 58-9.

[36] Havlik RJ, Bartlett SP. Mandibular distraction lengthening in the severely hypoplastic mandible: a problematic case with tongue aplasia. J Craniofac Surg 1994;5(5): 305-10; discussion 11-2.

[37] Moore MH, Guzman-Stein G, Proudman TW, Abbott AH, Netherway DJ, David DJ. Mandibular lengthening by distraction for airway obstruction in Treacher-Collins syndrome. J Craniofac Surg 1994;5(1):22-5.

[38] P R.

[39] Feiyun P, Wei L, Jun C, Xin X, Zhuojin S, Fengguo Y. Simultaneous correction of bilateral temporomandibular joint ankylosis with mandibular micrognathia using internal distraction osteogenesis and 3-dimensional craniomaxillofacial models. J Oral Maxillofac Surg;68(3):571-7.

[40] Senders CW, Kolstad CK, Tollefson TT, Sykes JM. Mandibular distraction osteogenesis used to treat upper airway obstruction. Arch Facial Plast Surg;12(1):11-5.

[41] Scott AR, Tibesar RJ, Lander TA, Sampson DE, Sidman JD. Mandibular distraction osteogenesis in infants younger than 3 months. Arch Facial Plast Surg;13(3):173-9.

[42] Shen W, Jie C, Chen J, Zou J, Ji Y. Mandibular distraction osteogenesis to relieve Pierre Robin severe airway obstruction in neonates: indication and operation. J Craniofac Surg 2009;20 Suppl 2:1812-6.

[43] Kita H, Kochi S, Yamada A, Imai Y, Konno N, Saitou C, et al. Mandibular widening by distraction osteogenesis in the treatment of a constricted mandible and telescopic bite. Cleft Palate Craniofac J 2004;41(6):664-73.

[44] Conley R, Legan H. Mandibular symphyseal distraction osteogenesis: diagnosis and treatment planning considerations. Angle Orthod 2003;73(1):3-11.

[45] Sukurica Y, Gurel HG, Mutlu N. Six year follow-up of a patient treated with mandibular symphyseal distraction osteogenesis. J Craniomaxillofac Surg;38(1):26-31.

[46] Gurrereo.

[47] Chung YW, Tae KC. Dental stability and radiographic healing patterns after mandibular symphysis widening with distraction osteogenesis. Eur J Orthod 2007;29(3): 256-62.

[48] Rachmiel A, Jackson IT, Potparic Z, Laufer D. Midface advancement in sheep by gradual distraction: a 1-year follow-up study. J Oral Maxillofac Surg 1995;53(5):525-9.

[49] Staffenberg DA, Wood RJ, McCarthy JG, Grayson BH, Glasberg SB. Midface distraction advancement in the canine without osteotomies. Ann Plast Surg 1995;34(5): 512-7.

[50] Cohen SR, Burstein FD, Stewart MB, Rathburn MA. Maxillary-midface distraction in children with cleft lip and palate: a preliminary report. Plast Reconstr Surg 1997;99(5):1421-8.

[51] Mommaerts MY. Transpalatal distraction as a method of maxillary expansion. Br J Oral Maxillofac Surg 1999;37(4):268-72.

[52] Cheung LK, Chua HD. A meta-analysis of cleft maxillary osteotomy and distraction osteogenesis. Int J Oral Maxillofac Surg 2006;35(1):14-24.

[53] Meling TR, Hogevold HE, Due-Tonnessen BJ, Skjelbred P. Midface distraction osteogenesis: internal vs. external devices. Int J Oral Maxillofac Surg;40(2):139-45.

[54] Picard A, Diner PA, Galliani E, Tomat C, Vazquez MP, Carls FP. Five years experience with a new intraoral maxillary distraction device (RID). Br J Oral Maxillofac Surg;49(7):546-51.

[55] Aksu M, Saglam-Aydinatay B, Akcan CA, El H, Taner T, Kocadereli I, et al. Skeletal and dental stability after maxillary distraction with a rigid external device in adult cleft lip and palate patients. J Oral Maxillofac Surg;68(2):254-9.

[56] Mitsukawa N, Satoh K, Morishita T. Le Fort I distraction using internal devices for maxillary hypoplasia in patients with cleft lip, palate, and alveolus: complications and their prevention and management. J Craniofac Surg;21(5):1428-30.

[57] Richardson S, Agni NA, Selvaraj D. Anterior maxillary distraction using a tooth-borne device for hypoplastic cleft maxillas-a pilot study. J Oral Maxillofac Surg; 69(12):e542-8.

[58] Marchac A, Arnaud E. Cranium and midface distraction osteogenesis: current practices, controversies, and future applications. J Craniofac Surg;23(1):235-8.

[59] Kuroda S, Watanabe K, Ishimoto K, Nakanishi H, Moriyama K, Tanaka E. Long-term stability of LeFort III distraction osteogenesis with a rigid external distraction device in a patient with Crouzon syndrome. Am J Orthod Dentofacial Orthop;140(4):550-61.

[60] Ko EW, Chen PK, Tai IC, Huang CS. Fronto-facial monobloc distraction in syndromic craniosynostosis. Three-dimensional evaluation of treatment outcome and facial growth. Int J Oral Maxillofac Surg;41(1):20-7.

[61] Fearon JA. Halo distraction of the Le Fort III in syndromic craniosynostosis: a long-term assessment. Plast Reconstr Surg 2005;115(6):1524-36.

[62] Meazzini MC, Allevia F, Mazzoleni F, Ferrari L, Pagnoni M, Iannetti G, et al. Long-term follow-up of syndromic craniosynostosis after Le Fort III halo distraction: a cephalometric and CT evaluation. J Plast Reconstr Aesthet Surg;65(4):464-72.

[63] Cortese A, Savastano M, Savastano G, Claudio PP. One-step transversal palatal distraction and maxillary repositioning: technical considerations, advantages, and long-term stability. J Craniofac Surg;22(5):1714-9.

[64] Seeberger R, Kater W, Schulte-Geers M, Davids R, Freier K, Thiele O. Changes after surgically-assisted maxillary expansion (SARME) to the dentoalveolar, palatal and nasal structures by using tooth-borne distraction devices. Br J Oral Maxillofac Surg; 49(5):381-5.

[65] Verlinden CR, Gooris PG, Becking AG. Complications in transpalatal distraction osteogenesis: a retrospective clinical study. J Oral Maxillofac Surg;69(3):899-905.

[66] Verstraaten J, Kuijpers-Jagtman AM, Mommaerts MY, Berge SJ, Nada RM, Schols JG. A systematic review of the effects of bone-borne surgical assisted rapid maxillary expansion. J Craniomaxillofac Surg;38(3):166-74.

[67] Block MS, Chang A, Crawford C. Mandibular alveolar ridge augmentation in the dog using distraction osteogenesis. J Oral Maxillofac Surg 1996;54(3):309-14.

[68] Chin M, Toth BA. Distraction osteogenesis in maxillofacial surgery using internal devices: review of five cases. J Oral Maxillofac Surg 1996;54(1):45-53; discussion 54.

[69] Turker N, Basa S, Vural G. Evaluation of osseous regeneration in alveolar distraction osteogenesis with histological and radiological aspects. J Oral Maxillofac Surg 2007;65(4):608-14.

[70] Perry M, Hodges N, Hallmon DW, Rees T, Opperman LA. Distraction osteogenesis versus autogenous onlay grafting. Part I: outcome of implant integration. Int J Oral Maxillofac Implants 2005;20(5):695-702.

[71] Uckan S, Oguz Y, Bayram B. Comparison of intraosseous and extraosseous alveolar distraction osteogenesis. J Oral Maxillofac Surg 2007;65(4):671-4.

[72] Bianchi A, Felice P, Lizio G, Marchetti C. Alveolar distraction osteogenesis versus inlay bone grafting in posterior mandibular atrophy: a prospective study. Oral Surg Oral Med Oral Pathol Oral Radiol Endod 2008;105(3):282-92.

[73] Jensen OT, Block M. Alveolar modification by distraction osteogenesis. Atlas Oral Maxillofac Surg Clin North Am 2008;16(2):185-214.

[74] Nocini PF, Albanese M, Buttura da Prato E, D'Agostino A. Vertical distraction osteogenesis of the mandible applied to an iliac crest graft: report of a case. Clin Oral Implants Res 2004;15(3):366-70.

[75] Dinse WE, Burnett RR. Anterior maxillary restoration using distraction osteogenesis and implants: a clinical report. J Prosthet Dent 2008;100(4):250-3.

[76] Gozneli R, Ozkan Y, Akalin ZF, Ozkan Y. Rehabilitation of maxillary anterior esthetics by alveolar distraction osteogenesis with immediate implant placement: a case report. Implant Dent;19(6):468-76.

[77] Lee HJ, Ahn MR, Sohn DS. Piezoelectric distraction osteogenesis in the atrophic maxillary anterior area: a case report. Implant Dent 2007;16(3):227-34.

[78] Penarrocha-Diago M, Gomez-Adrian MD, Garcia-Garcia A, Camacho-Alonso F, Rambla-Ferrer J. Vertical mandibular alveolar bone distraction and dental implant placement: a case report. J Oral Implantol 2006;32(3):137-41.

[79] Rachmiel A, Gutmacher Z, Blumenfeld I, Peled M, Laufer D. [Vertical alveolar ridge augmentation using distraction osteogenesis]. Refuat Hapeh Vehashinayim 2001;18(1):64-9, 78.

[80] Raghoebar GM, Liem RS, Vissink A. Vertical distraction of the severely resorbed edentulous mandible: a clinical, histological and electron microscopic study of 10 treated cases. Clin Oral Implants Res 2002;13(5):558-65.

[81] Yalcin S, Ordulu M, Emes Y, Gur H, Aktas I, Caniklioglu C. Alveolar distraction osteogenesis before placement of dental implants. Implant Dent 2006;15(1):48-52.

[82] Perdijk FB, Meijer GJ, Strijen PJ, Koole R. Complications in alveolar distraction osteogenesis of the atrophic mandible. Int J Oral Maxillofac Surg 2007;36(10):916-21.

[83] McAllister BS, Gaffaney TE. Distraction osteogenesis for vertical bone augmentation prior to oral implant reconstruction. Periodontol 2000 2003;33:54-66.

[84] Aikawa T, Iida S, Senoo H, Hori K, Namikawa M, Okura M, et al. Widening a narrow posterior mandibular alveolus following extirpation of a large cyst: a case treated with a titanium mesh-plate type distractor. Oral Surg Oral Med Oral Pathol Oral Radiol Endod 2008;106(5):e1-7.

[85] Bulut E, Muglali M, Celebi N, Bekcioglu B. Horizontal alveolar distraction of the mandibular canine regions for implant placement. J Craniofac Surg;21(3):830-2.

[86] Garcia-Garcia A, Somoza-Martin M, Gandara-Vila P, Saulacic N, Gandara-Rey JM. Horizontal alveolar distraction: a surgical technique with the transport segment pedicled to the mucoperiosteum. J Oral Maxillofac Surg 2004;62(11):1408-12.

[87] Laster Z, Rachmiel A, Jensen OT. Alveolar width distraction osteogenesis for early implant placement. J Oral Maxillofac Surg 2005;63(12):1724-30.

[88] Oda T, Suzuki H, Yokota M, Ueda M. Horizontal alveolar distraction of the narrow maxillary ridge for implant placement. J Oral Maxillofac Surg 2004;62(12):1530-4.

[89] Watzak G, Zechner W, Tepper G, Vasak C, Busenlechner D, Bernhart T. Clinical study of horizontal alveolar distraction with modified micro bone screws and subsequent implant placement. Clin Oral Implants Res 2006;17(6):723-9.

Section 10

Advanced Oral and Maxillofacial Reconstruction

Chapter 17

Reconstruction of Mandibular Defects

Maiolino Thomaz Fonseca Oliveira,
Flaviana Soares Rocha, Jonas Dantas Batista,
Sylvio Luiz Costa de Moraes and
Darceny Zanetta-Barbosa

Additional information is available at the end of the chapter

http://dx.doi.org/10.5772/52104

1. Introduction

Surgical reconstruction of mandibular bone defects is a routine procedure for rehabilitation of patients with deformities caused by trauma, infection or tumor resection. The mandible plays a major role in masticatory and phonetic functions, supporting the teeth and defining the contour of the lower third of the face. Therefore, mandibular discontinuity produces severe cosmetic and functional deformities, including loss of support for suprahyoid muscles and subsequent airway reduction. Reconstruction of these severe defects is mandatory for restoring the patient's quality of life. Surgical techniques have improved considerably in the last decade, but reconstruction of large bone defects of the mandible still pose a great challenge in maxillofacial rehabilitation. Several things can be done to optimize the surgery; the use of prototyping modeling for instance provides a better assessment of the bone defect and pre-contouring of the fixation plates, reducing operating time. The choice of the most suitable titanium plate system is critical to the success of the procedure. Mandibular defects with loss of continuity require more robust (load bearing) systems supporting mandibular function. Many studies consider the use of plates and screws temporary treatment due to the large number of complications such as fracture of plates and screws, plate exposure and infection. Thus, the use of grafts both in the first operation or in a two-stage procedure ensures a more predictable result.

Bone grafts are widely used in reconstructive surgery of the mandible. Incorporation of the bone graft restores continuity, shape, and strength of the jaw to near normal function. Installation of dental implants in the grafted areas is important to restore masticatory function and maintain bone graft volume. Autogenous bone is the best choice for major reconstructions due to lack of rejection, and the presence of viable osteogenic cells that increase bone

INTECH
open science | open minds

© 2013 Oliveira et al.; licensee InTech. This is a paper distributed under the terms of the Creative Commons Attribution License (http://creativecommons.org/licenses/by/3.0), which permits unrestricted use, distribution, and reproduction in any medium, provided the original work is properly cited.

formation and incorporation at the graft site. The use of a vascularized graft is a good choice because it increases the success of the treatment. However, this technique is not available in all medical centers. Autogenous free bone (non-vascularized) is still the most used graft, even in major reconstructions [1]. The high vascularity of the soft tissues in the oral cavity has allowed the use of free bone graft in the repair of oral cavity defects; but larger grafts increase the risk of bone resorption or failure of graft take. Hyperbaric oxygen therapy is currently being used to optimize bone healing. This procedure increases bone cellular activity and capillary ingrowth, inducing new bone formation and accelerating bone healing. The aim of this chapter is to present our experience with a series of patients with extensive mandibular defects where the use of autogenous free bone grafts along with hyperbaric oxygen therapy as an important adjuvant was beneficial to the outcome.This chapter also presents other alternatives for mandibular reconstruction.

2. Defect evaluation

In mandibular reconstruction, the restoration of bone continuity is not the only criteria for success. The ultimate goals constituting success is attaining near normal morphology and appropriate relation to the opposing jaw, adequate bone height and width, good facial contour and support for overlying soft tissue structures and restoration of jaw of function.

Bony reconstruction planning begins with evaluation of the patient's anatomy in order to define the full extent of the existing defect (both bone and soft tissues) and select the best reconstruction technique for each particular case. The size of the defect will define the magnitude of the reconstruction [2,3]. Some defects may not need to be restored to original size and shape. Loss of a significant portion of a mandibular ramus, for example, may be adequately managed by providing continuity from the condyle to the body of the mandible without restoring the coronoid process.

The quantity and quality of the soft tissues are both important when choosing the reconstructive method. The complete closure of the soft tissue without tension is essential for success. If the tissue is inadequate in quantity, the use of horizontal incisions in the periosteum must be used to guarantee tissue flexibility when needed. This ensures good (tension-free) repair, minimizes postoperative discomfort and reduces dehiscence (one of the most commonly observed complications after grafting in the oral cavity).

On the other hand, if the quantity of soft tissue is adequate but the quality is poor, the reconstruction will be compromised or limited. Tissue with extensive scarring provides a poor host bed for any grafting procedure. When considering the use of non-vascularized bone grafts, the ideal soft and hard tissue bed should have enough bulk, vascularity, and cellularity in order to permit bone graft incorporation. In several cases, tissue loss, scar contracture, and previous irradiation will hamper secondary reconstruction. In this setting, the use of hyperbaric oxygenation should always be considered, because it promotes vascularization and angiogenesis.

Preoperative radiographic evaluation of patients undergoing reconstructive bone surgery aims to evaluate the nature and extent of the lesion and provide the surgeon with anatomic mapping of important structures. Also, follow-up examinations to confirm healing and to

http://dx.doi.org/10.5772/52104

discover complications at an early stage are paramount. The selection of the most appropriate imaging method in each case must take into account the diagnostic capability and cost-effectiveness. Radiographic analysis, computed tomography with three-dimensional (3D) images and magnetic resonance can provide important information. With the development of rapid prototyping methods, such as stereolithography, fused deposition modeling and selective laser sintering, 3D reconstruction based on biomodels have become indispensible tools both for mandibular resection and bony reconstruction.

The use of 3D biomodels, may help delineate the osteotomy area, improving the accuracy of marginal resection. Pre-modeling of reconstruction plates according to the mandibular anatomy is also facilitated. At the time of the secondary reconstruction, the individual plate gives the surgeon a clear direction where the bone should be ideally placed. Another important possibility with these models is the reproduction of the anatomy of the resected area based on mirror imaging of the contralateral side of the mandible. This procedure guides the surgeon as to where to cut the bone graft in the donor area and enhance visualization of the points to be remodeled in the graft prior to fixation to reproduce the new mandible.

3. Reconstruction plates

Mandibular reconstruction plates and screws (2.4 System) are the most widely used devices for mandibular reconstruction; however 2.0 plates can be used in selected cases. With the conventional fixation technique, the tightening of the screws presses the plate against the bone (load sharing). This pressure generates friction, which may contribute to resorption of the grafted bone. However, with the locking systems (load bearing), additional threads within the screw head allows the plate to be anchored to the intraosseous screw instead of being compressed onto the bone. This reduces interference to the bone blood supply underlying the plate, prevents bone pressure necrosis and decreases the potential for plate failure at the screw-bone interface. These plates and screws provide an excellent rigid frame construction with high mechanical stability which is extremely useful in bone grafting (Figures 1-6).

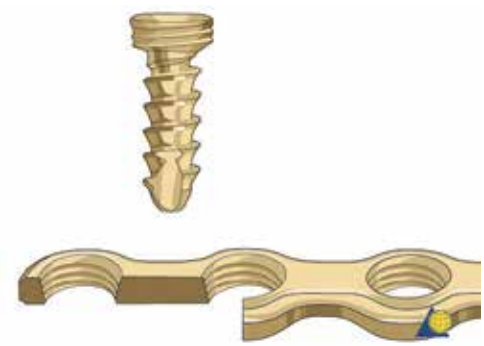

Figure 1. The locking plate has a corresponding threaded plate hole. Copyright by AO Foundation, Switzerland. Source: AO Surgery Reference, www.aosurgery.org.

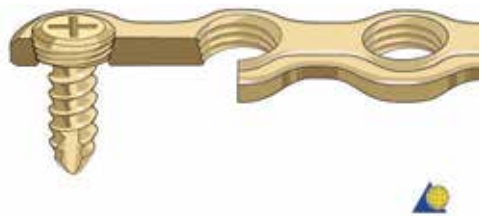

Figure 2. During insertion the locking head screw engages and locks into the threaded plate hole. Copyright by AO Foundation, Switzerland. Source: AO Surgery Reference, www.aosurgery.org.

Figure 3. If necessary the threaded plate hole also accepts nonlocking screws, which permit greater angulation. Copyright by AO Foundation, Switzerland. Source: AO Surgery Reference, www.aosurgery.org.

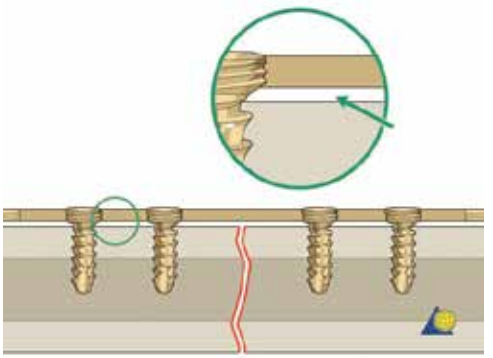

Figure 4. With the locking head screws engaged in the plate, the plate is not pressed onto the bone. This reduces interference to the blood supply to the bone underlying the plate. Copyright by AO Foundation, Switzerland. Source: AO Surgery Reference, www.aosurgery.org.

Reconstruction plates are usually shaped before the mandibular resection and applied afterwards. By bending these plates and placing drill holes in the proximal and distal mandible segments before complete mandibular resection, the surgeon can more confidently maintain the proper occlusion and relationships of the remaining mandibular segments after removal of the involved bone. Even in edentulous cases, this planning maintains a more natural con-

http://dx.doi.org/10.5772/52104

tour and good joint function. With the currently available low-profile locking reconstruction plates, the contoured plate can closely approximate the natural mandibular projection without sacrificing durability and strength, even when used in conjunction with bone grafts. If, however, there is involvement of the buccal cortex of the mandible, direct plate contouring to the bone is not always possible. In these cases, removal of the buccal part of the lesion to allow plate positioning before complete resection is a possible option with satisfactory results. Post-resection freehand plate contouring and fixation is another possibility, however it is difficult, presumes the need of inter-maxillary fixation (IMF) and often yields suboptimal symmetry.

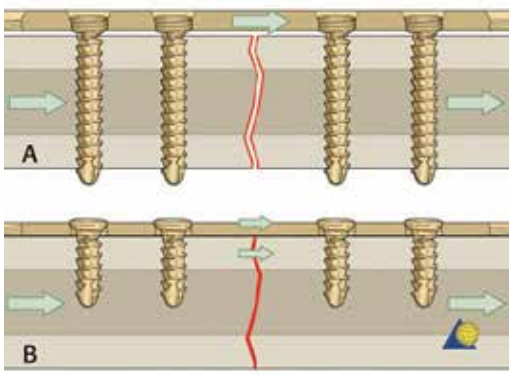

Figure 5. Loading forces are transmitted directly from the bone to the screws, then onto the plate, across the gap and again through the screws into the bone. Friction between plate and bone is not necessary for stability. The plate and screws provide adequate rigidity and do not depend on the underlying bone (load bearing osteosynthesis) when using a locking reconstruction plate 2.4. Copyright by AO Foundation, Switzerland. Source: AO Surgery Reference, www.aosurgery.org.

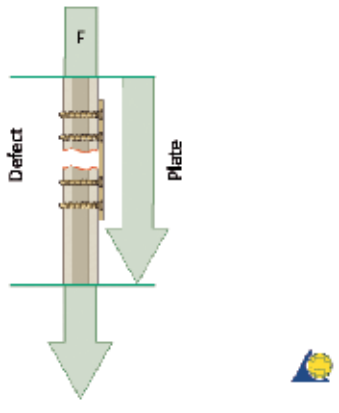

Figure 6. In load-bearing fixation the plate assumes 100% of the functional loads. Copyright by AO Foundation, Switzerland. Source: AO Surgery Reference, www.aosurgery.org.

It is important to understand the appropriate possibilities for bone graft fixation. In our experience, adequate internal fixation using reconstruction locking plates and, subsequently, free autogenous bone grafts seem to be most satisfactory.

4. Free bone grafting

During harvesting, tissue connections between the bone graft and surrounding tissues are transected. In the recipient site, the bone must be revitalized mainly via tissue ingrowth, although it is known that many cells within free bone grafts are able to survive after transplantation. The revitalization goes along with a process of initial remodeling and bone resorption, which is associated with bone volume loss. The amount of resorption depends on many factors, such as the quality of the bone (cortical, cancellous), bone graft fixation to surrounding bone, biomechanical properties (functional loading), the dimensions of the bone graft (it takes longer to revitalize large bone grafts, and therefore, usually they show greater percentage of bone loss) and tissue qualities at the recipient site (vascularization). The amount of bone formed is directly proportional to the number of viable osteogenic cells transferred. The next phase involves revascularization, remodeling, and reorganization of the previously formed bone by osteoblasts and osteoclasts.

Non-vascularized autogenous bone grafts can be harvested from the patient's calvarium, rib, ilium, tibia or fibula [4]. They can be successfully used for reconstruction of small to medium size mandibular defects with favorable prognosis. However, in large mandibular defects, bone reconstruction is still challenging.

Cancellous bone grafts, consisting of medullary bone and bone marrow, contain the highest percentage of viable cells. These grafts become rapidly vascularized due to their particulate structure and large surface area. In contrast, cortical grafts consisting of lamellar bone, provides more resistance to the graft. Cortico-cancellous bone grafts contain both cortical and underlying cancellous bone providing both viable cells and necessary strength for bridging discontinuous defects. The combination of particulate cortical bone and cancellous marrow provides the best potential for osteogenesis.

Bone harvesting should always be performed with sharp instruments under abundant irrigation, and the surgical time must be as short as possible to minimize tissue necrosis and preserve cell viability [5]. The same principles are required during the bone adaptation in the recipient site. The lack of adaptation of the bone block onto the recipient site and the presence of gaps can generate fibrous tissue interposition, which can be avoided with filling the gap with particulate autogenous bone, platelet rich plasma (PRP) or biomaterials.

The recipient site preparation should facilitate the subsequent adaptation of the graft and also expose the bone marrow, favoring revascularization, since the vessels from the periosteum were compromised when it was displaced. The cortical bone in the recipient site can be perforated or even removed with drills to enable contact of the marrow spaces of the graft [6].

http://dx.doi.org/10.5772/52104

Graft fixation is essential to allow its revascularization and incorporation. Movement of the bone block during the healing period results in fibrous tissue between the graft and the recipient site or graft resorption [5,6]. The fixation screws can be used in a passive or compressive manner, however, in the latter case, excessive compression must always be avoided. In cases of mandibular reconstruction decortication is extremely important before the placement of the grafts to support revascularization and facilitate the graft adaptation.

5. Hyperbaric oxygen therapy

The hyperbaric oxygen (HBO) is a therapeutic modality performed within devices called pressurized containers, in which the patient breathes pure oxygen at a high pressure. The HBO promotes an increase in the amount of dissolved oxygen in the blood due to increased pressure inside the chamber, aiding tissue oxygenation [7] (Figure 7).

Figure 7. Patient in an HBO chamber during a hyperbaric oxygen therapy session.

For years, conventional medicine thought of HBO only as a treatment for decompression sickness and air embolism. However, the use of HBO is becoming increasingly common in general practice. HBO has already been used in the treatment of carbon monoxide poisoning, cerebral arterial gas syndrome, decompression sickness, osteoradionecrosis and clostridial gas gangrene. It is also beneficial to improve the healing of a variety of compromised or hypoxic wounds including diabetic ulcers, radiation-induced tissue damage, gangrene, and necrotizing anaerobic bacterial infections [8].

Complications of HBO can be due to either O_2 toxicity or barotrauma. O_2 toxicity is due to formation of superoxide, OH- and H_2O_2. Signs and symptoms of O_2 toxicity mainly involve respiratory system and central nervous system with symptoms like anxiety, nausea, vomiting, seizures, vertigo and decreased level of consciousness. Patients also show respiratory discomfort ranging from dry cough and substernal pain to pulmonary edema and fibrosis [7].

HBO is contraindicated in a patient with pneumothorax due to increased risk of gas embolism. It is also contraindicated in epileptics, hyperthermia and acidosis due to increased risk of seizures. Chronic obstructive pulmonary disease, malignant tumors, pregnancy, claustrophobia, hereditary spherocytosis and optic neuritis are other relative contraindications for the use of HBO therapy [9].

Following maxillofacial trauma there is a vascular disruption which leads to the formation of a hypoxic zone. While hypoxia is necessary to stimulate angiogenesis and revascularization, extended hypoxia will blunt the healing process. HBO may be used to aid in the healing of these compromised wounds by increasing oxygen diffusion from the capillaries to tissues [10]. The available oxygen also has bacteriostatic and bactericidal activites, enhances the phagocytic capacity of white blood cells and promotes differentiation of fibroblasts by interfering with the synthesis of collagen. Important biological events such as angiogenesis and osteogenesis are also stimulated by HBO [11], improving tissue repair and increasing the overall success of reconstruction procedures.

The stimulation of osteogenesis by HBO has been reported in animal experiments and clinical cases. In 1996, Sawai et al. conducted a study to evaluate the effect of hyperbaric oxygen therapy on autogenous free bone grafts transplanted from iliac crest to the mandibles of rabbits and the results indicate that HBO accelerates the union of autogenous free bone grafts [12]. Other studies also demonstrated that HBO elevates alkaline phosphatase activity, a marker of bone formation, in rats following mandibular osteotomy [13], increased osteoblastic activity and angiogenesis in irradiated mandibles undergoing distraction [14] and increased vascular endothelial growth factor expression during bone healing [15].

5.1. A hyperbaric oxygen protocol in mandibular reconstructions

The following treatment steps are included in these sessions: 10 minutes of ventilation to fill the chamber with 100% oxygen, 10 to 15 minutes of diving (0.06 to 0.12 kgf/cm^2 in 1 minute), the patients are exposed to 2.4 ATA (Atmosphere Absolute) pressure for 90 minutes, 10 minutes of re-surfacing and 10 minutes of air ventilation. HBO is given every day and the treatment starts 10 days before bony reconstruction and continues for another 40 days after the surgical procedure.

6. Clinical cases

Figure 8. Patient with ossifying fibroma in the right side of the mandible. Extra and intra oral appearance.

Figure 9. Computed Tomography and panoramic images revealing the lesion area.

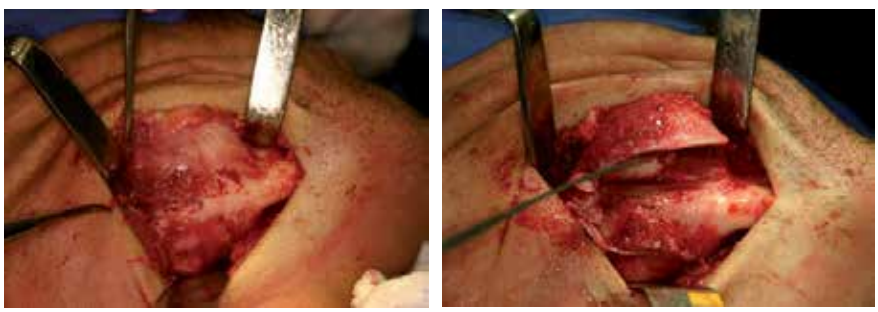

Figure 10. Part of the lesion was removed to permit reconstruction plate modeling maintaining mandibular contour.

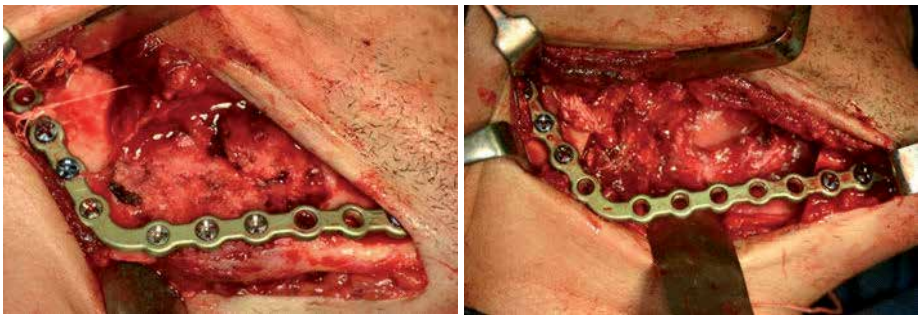

Figure 11. Reconstruction plate installation prior and after complete removal of the lesion. This preserves dental occlusion and condylar position.

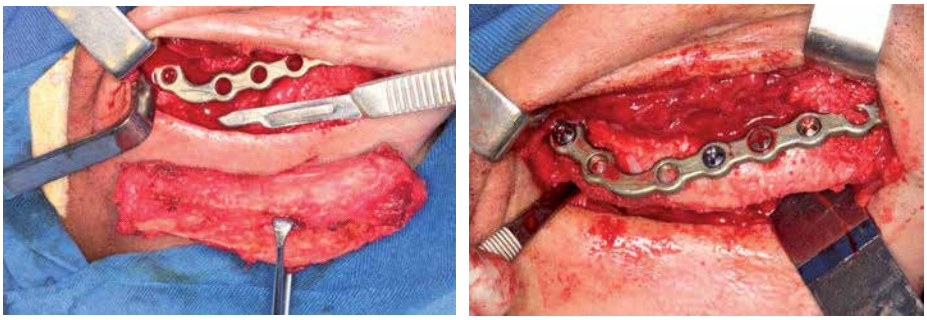

Figure 12. Mandibular reconstruction with free iliac bone 6 months after resection.

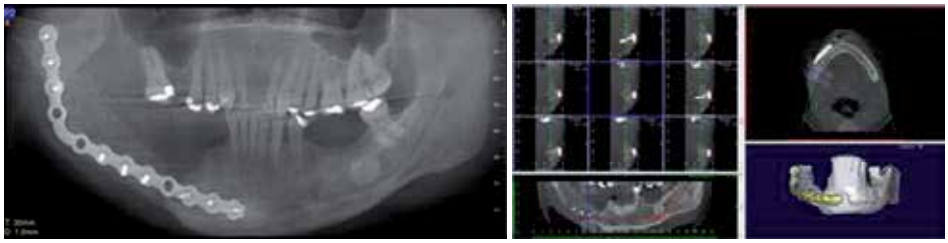

Figure 13. Computed Tomography images 8 months after bony reconstruction revealing the maintenance of bone graft volume. The next step is implant installation for final oral rehabilitation.

http://dx.doi.org/10.5772/52104

Figure 14. Extra-oral image 8 months after bony reconstruction showing preserved mandibular contour and facial symmetry.

6.1. Clinical case

Figure 15. Patient sought treatment for mandibular reconstruction 5 years after undergoing surgery for removal of an ossifying fibroma. There was a significant impairment of the symmetry of the face and backward positioning of the soft tissues of the lower face ("Andy Gump" deformity).

Figure 16. Intraoral image showing the soft tissue condition. There was difficulty in mouth opening.

Figure 17. Radiographic images revealing failure of the fixation system and major deficiency in lower face position.

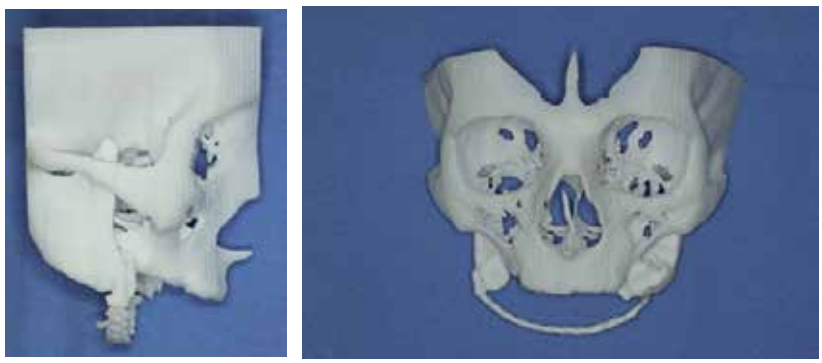

Figure 18. biomodels constructed to better understand the case and assist planning mandibular reconstruction.

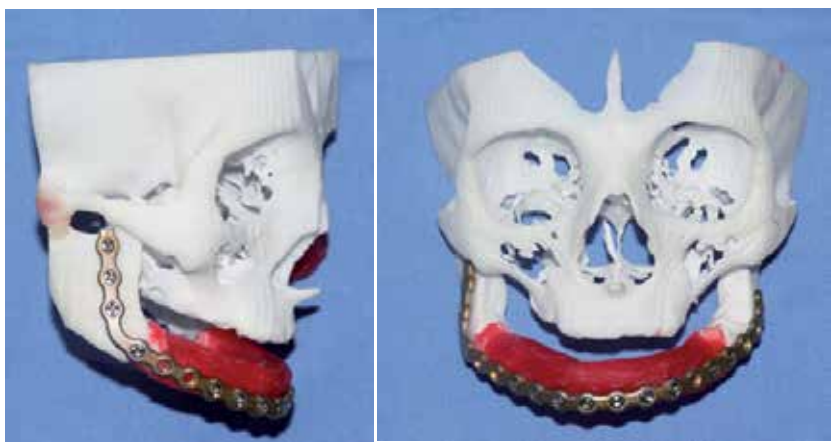

Figure 19. The 2.4 reconstruction plate was previously modeled to facilitate the surgery procedure and reduce operation time.

http://dx.doi.org/10.5772/52104

Figure 20. After the surgical approach, the 2.0 miniplate was removed and the bone segments located.

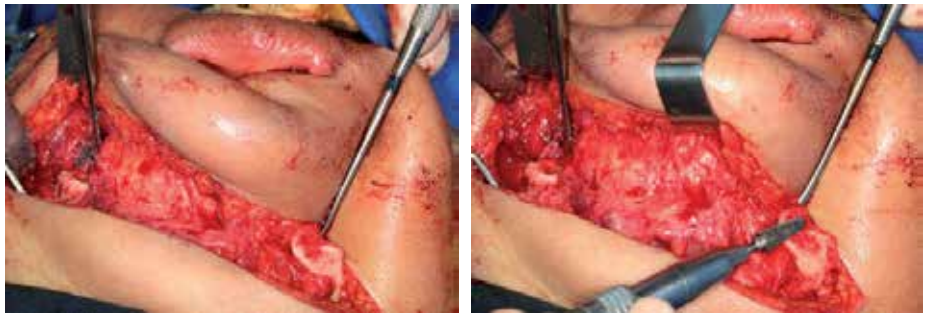

Figure 21. Refreshing the bone margins is important to enhance bone graft take.

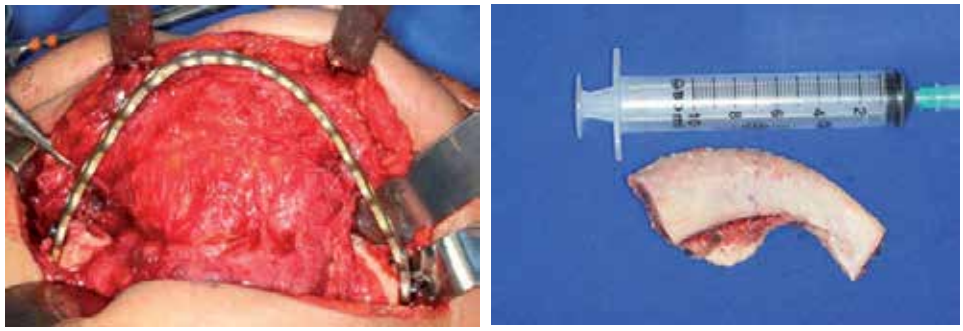

Figure 22. The locking plate was installed and the iliac crest bone was removed.

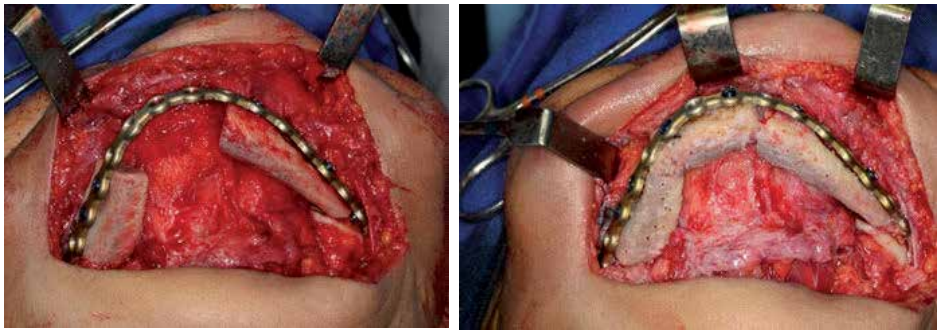

Figure 23. Positioned and fixed bone blocks. In this case the locking plate supports the full load.

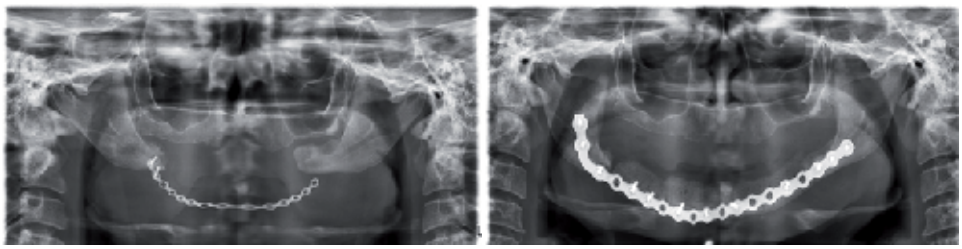

Figure 24. Pre and post-operative images of mandibular reconstruction.

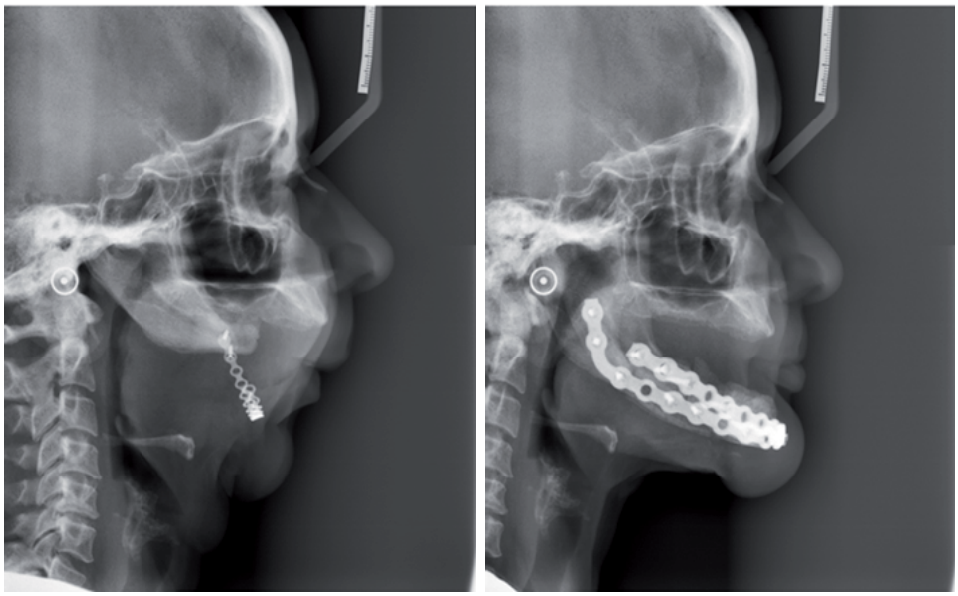

Figure 25. Pre and post-operative profile imagesof mandibular reconstruction.

http://dx.doi.org/10.5772/52104

Figure 26. Postoperative appearance after mandibular reconstruction with preserved contour of the mandible and face.

7. Clinical case

Figure 27. The patient was diagnosed with ameloblastoma in the left mandibular body. The panoramic radiograph shows an extensive multilocular lesion and resorption of tooth roots.

Figure 28. Computed Tomography images are important to define the extent of the affected area.

Figure 29. Installation of the 2.4 reconstruction plate before and after complete remove the lesion. These preserves dental occlusion and condylar position.

Figure 30. Mandibular reconstruction with iliac free bone 9 months after the resection.

Figure 31. Intraoral examination evidenced good quality of soft tissue.Orthodontic brackets are installed to prevent extrusion of the upper teeth.Panoramic image 6 months after mandibular bony reconstruction demonstrating bone volume maintenance.

http://dx.doi.org/10.5772/52104

Figure 32. Postoperative appearance after mandibular reconstruction with preserved contour of the mandible and face.

7.1. Clinical case

Figure 33. The patient was diagnosed with ameloblastoma in left mandibular body. The panoramic radiograph shows an extensive multilocular lesion and resorption of tooth roots.

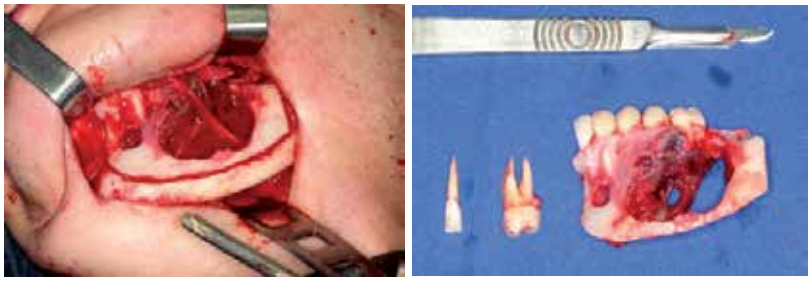

Figure 34. Marginal mandibular resection preserving the mandible basis.

Figure 35. Installation of the 2.4 locking reconstruction plate. The presence of plate protects the jaw of a possible fracture.

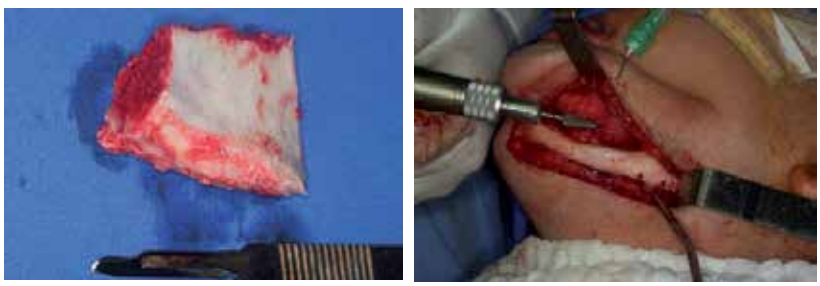

Figure 36. Mandibular bony reconstruction 8 months after resection. The receptor site of the graft should be prepared by removing part of the bone cortex. This favors the incorporation of the graft.

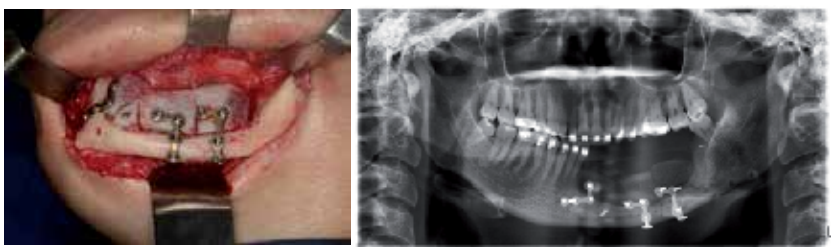

Figure 37. In this case, the reconstruction plate was removed and the bone blocks were fixed using 2.0 miniplates. The use of miniplates provided a better fit and positioning of the blocks.

Figure 38. Postoperative appearance after mandibular reconstruction with preserved contour of the mandible and face. Intraoral examination evidenced good quality of soft tissue. Orthodontic brackets are installed to prevent extrusion of the upper teeth.

Author details

Maiolino Thomaz Fonseca Oliveira[1], Flaviana Soares Rocha[1], Jonas Dantas Batista[1], Sylvio Luiz Costa de Moraes[2] and Darceny Zanetta-Barbosa[1]

1 Department of Oral and Maxillofacial Surgery and Implantology – School of Dentistry - Federal University of Uberlândia – UFU, Brazil

2 Head, Clinic for Cranio-Maxillofacial Surgery at Hospital São Francisco. Director of Facial Reconstruction Center – RECONFACE. Faculty AO-Foundation

References

[1] Pogrel MA, Podlesh S, Anthony JP, Alexander J. A comparison of vascularised and nonvascularized bone grafts for reconstruction of mandibular continuity defects. J Oral Maxillofac Surg. 1997 Nov;55(11):1200-6.

[2] Bernstein S, Cooke J, Fotek P, Wang HL. Vertical bone augmentation: where are we now? Implant Dent. 2006 Sep;15(3):219-28. Review.

[3] McAllister BS, Haghighat K. Bone augmentation techniques. J Periodontol. 2007 Mar; 78(3):377-96.

[4] Weibull L, Widmark G, Ivanoff CJ, Borg E, Rasmusson L. Morbidity after chin bone harvesting--a retrospective long-term follow-up study. Clin Implant Dent Relat Res. 2009 Jun;11(2):149-57. Epub 2008 Jul 24.

[5] Cypher TJ, Grossman JP. Biological principles of bone graft healing. J Foot Ankle Surg. 1996 Sep-Oct;35(5):413-7.

[6] Buser D, Dula K, Hirt HP, Schenk RK. Lateral ridge augmentation using autografts and barrier membranes: a clinical study with 40 partially edentulous patients. J Oral Maxillofac Surg. 1996 Apr;54(4):420-32; discussion 432-3.

[7] Brazilian Society of Hyperbaric Medicine (SBMH), 2010.

[8] DESOLA J, CRESPO A, GARCIA A et al: Indicaciones y Contraindicaciones de la Oxigenoterapia Hiperbarica. Nº 1260, 5- 11 de Junho de JANO/Medicina, 1998;LIV.

[9] Fernandes TD. [Hyperbaric medicine]. Acta Med Port. 2009 Jul-Aug;22(4):323-34. Epub 2009 Aug 10. Review. Portuguese.

[10] Feldmeier JJ. Hyperbaric oxygen for delayed radiation injuries. Undersea Hyperb Med. 2004 Spring; 31(1):133-45.

[11] Jacobson AS, Buchbinder D, Hu K, Urken ML. Paradigm shifts in the management of osteoradionecrosis of the mandible. Oral Oncol. 2010 Nov;46(11):795-801. Epub 2010 Sep 16. Review.

[12] Sawai T, Niimi A, Takahashi H, Ueda M. Histologic study of the effect of hyperbaric oxygen therapy on autogenous free bone grafts. J Oral Maxillofac Surg. 1996 Aug; 54(8):975-81.

[13] Nilsson LP. Effects of hyperbaric oxygen treatment on bone healing. An experimental study in the rat mandible and the rabbit tibia. Swed Dent J 1989;64(1):1-33.

[14] Muhonen A, Haaparanta M, Gronroos T, Bergman J, Knuuti J, Hinkka S, et al. Osteoblastic activity and neoangiogenesis in distracted bone of irradiated rabbit mandible with or without hyperbaric oxygen treatment. Int J Oral Maxillofacial Surg 2004;33(2):173-8.

[15] Fok TC, Jan A, Peel SA, Evans AW, Clokie CM, Sándor GK. Hyperbaric oxygen results in increased vascular endothelial growth factor (VEGF) protein expression in rabbit calvarial critical-sized defects. Oral Surg Oral Med Oral Pathol Oral Radiol Endod. 2008 Apr;105(4):417-22.

Chapter 18

Microsurgical Reconstruction of Maxillary Defects

Shahram Nazerani

Additional information is available at the end of the chapter

http://dx.doi.org/10.5772/52720

1. Introduction

The maxilla is the functional and esthetic keystone of the midface, forming part of each of the key midfacial elements; these are the orbits, the zygomatico-maxillary complex, the nasal unit, and the stomatognathic complex. Maxillary reconstruction is a challenging endeavor in functional and esthetic restoration. Given its central location in the midface and its contributions to the midface, maxillary defects are inherently complex because they generally involve more than one midfacial component. Maxillary defects are composite in nature, and they often require skin coverage, bony support, and mucosal lining for reconstruction. Reconstruction of maxillary defects secondary to warfare, trauma, ablative tumor surgery, or congenital deformities must meet the following goals namely: (1) obliteration of the defect; (2) restoration of essential functions such as mastication and speech, (3) provision for adequate structural support to each of the midfacial units and (4) esthetic restoration of facial features. This chapter will discuss the anatomic considerations, the historical approaches to maxillary reconstruction as well as state-of-the-art techniques in use today.

2. Anatomy

Understanding the complex three-dimensional anatomy of the maxilla and its relationship to contiguous structures is critical to approaching reconstruction of the midface. Conceptually, the maxilla can be described as a geometric structure with six walls (a hexahedron, Figure 1).

The roof of the box is the floor of the orbit; the floor forms the anterior hard palate and alveolar ridge; the lateral walls form the lateral walls of the maxillary sinuses and are a part of the lacrimal system. The maxillary sinus, the largest of the paranasal sinuses, is contained within the central portion of the maxilla. Anteriorly it comprises the midface supporting the nose and anterior teeth. Overlying the posterior pterygoid region of the maxilla is the cranial base.

INTECH
open science | open minds

© 2013 Nazerani; licensee InTech. This is a paper distributed under the terms of the Creative Commons Attribution License (http://creativecommons.org/licenses/by/3.0), which permits unrestricted use, distribution, and reproduction in any medium, provided the original work is properly cited.

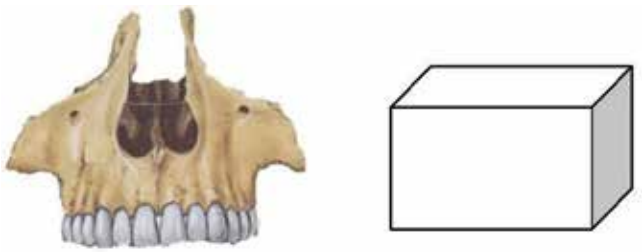

Figure 1. The maxilla and the schematic metaphor of a hexahedron.

Figure 2. The maxilla with its surrounding bony structures.

The maxilla provides structural support between the skull base and the occlusal plane, supports the globe, separates the oral and nasal cavities and resists the forces of mastication. [1]

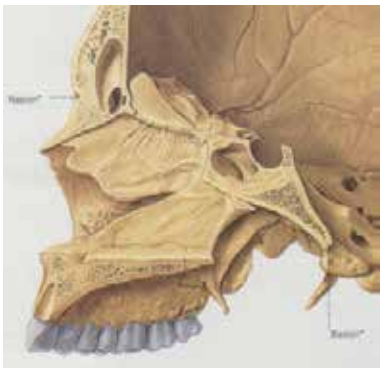

Figure 3. The maxilla with its projections create the bony foundation of the midface.

Finally, the overlying soft tissues, including the mimetic musculature of the midface, are supported by the maxilla and influence to a large extent one's unique facial appearance.

http://dx.doi.org/10.5772/52720

3. Historical procedures for maxillary reconstruction

Traditionally, reconstruction of large maxillary defects was accomplished by obturation of the defect with a prosthetic appliance. [2,3] Before the development of more sophisticated reconstructive techniques, prosthetic appliances were the only modality available to address the functional and esthetic requirements of such a complex defect. Both functional and esthetic results were far from optimal (Figure 4).

Figure 4. A hemi-maxillary obturator prosthesis.

Edgerton and Zovickian [4] reviewed early attempts at autogenous reconstruction of the maxilla and reported a palatal reconstruction technique using cervical flaps. These early reconstructive endeavors progressed from local flaps, such as forehead, upper lip, cheek, pharyngeal, turbinate, and tongue flaps, to tube flaps from the upper extremity, thorax, and abdomen. [5,6] Numerous other local flaps have been described for maxillary and palatal reconstruction. Generally, these have been useful for small defects or to augment other tissue-transfer techniques used to reconstruct larger defects. [7-17]

One of the earliest descriptions of a staged maxillary reconstruction with both soft tissue and bone was by Campbell in 1948. [18] He combined a temporalis muscle flap with a rotational palatal mucosal flap for soft-tissue reconstruction. An iliac bone graft was then placed in a second procedure; this was followed by the placement of a vestibular skin graft. The resulting reconstructed maxilla was capable of supporting a conventional maxillary denture.During the 1960s and 1970s, pedicled myocutaneous flaps were developed and replaced the more cumbersome tube flaps previously used in reconstructive surgery. However, these flaps tended to be quite bulky and were limited in their capacity to replicate the complexities of the resected maxillary structures. During the 1980s, a revolution in reconstructive surgery was brought about by the introduction of free tissue transfer techniques. These techniques have been widely applied in maxillary reconstruction, [18-25] and they have made possible the use of less bulky fascial or fasciocutaneous and osseous flaps. [26-36] Alongside the development of these tissue transfer techniques was the development of osseointegration pioneered by Branemark. [37-39] This technology, in combination with free tissue transfer, has made autogenous reconstruction of the maxilla and dentofacial rehabilitation possible. [40-45]

4. Classifying midfacial defects

Because of the disparate shapes and sizes of defects affecting the maxilla, the complex three-dimensional anatomy and the contiguous relationship of the maxilla to the surrounding structures, the broad category of maxillectomy constitute a wide spectrum of diverse defects. [46] Thus, a classification system to group this wide array of possible composite tissue defects was needed to facilitate clinical decision-making by outlining preferred reconstructive options and their common functional and esthetic sequelae. Attesting to both the variety and complexity of midfacial defects, numerous different classification schemes have been proposed. Based on a combined experience with 45 maxillectomies, Brown *et al*. developed a classification scheme allowing a very detailed description of 10 possible defects involving the palate; defects of the midface not involving the palate were excluded from the classification. [47] Unfortunately, the status of the orbital floor and zygoma, which play an important role in both the function and cosmesis of the midface, were not specifically addressed and specific recommendations for the reconstruction of each type was not given.

Wells and Luce proposed a classification system based on the extent of maxillary resections. [48] The schema allows the distinct classification of defects; however, proposed treatment focuses on the use of prosthetic obturators and/or the use of regional flaps rather than the specific use of microsurgical tissue transfer. In contrast, Yamamoto advocated the use of complex microsurgical procedures, specifically, the combined latissimus dorsi myocutaneous free flap with scapular bone based on the angular branch of the thoracodorsal artery and the rectus abdominis myocutaneous flap combined with costal cartilage based on the vascular connection between the eighth intercostal and deep epigastric vascular system. [49-50] Based on their 10-year experience with 38 maxillary reconstructions, they designed a complex reconstructive algorithm that ultimately culminates in nine different clinical scenarios based predominantly on the aforementioned vascularized, composite-tissue flaps. Futran and

http://dx.doi.org/10.5772/52720

Mendez presented an algorithm designed to depict options for midface reconstruction. Based on a thorough review of the literature, they classified defects as those involving the palate, the inferior maxilla, or the total maxilla with or without orbital exenteration. [46] Their algorithm was designed to delineate types of tissue required to reconstruct a particular defect, such as soft-tissue flaps or vascularized bone flaps rather than specific flap options. Spiro *et al*. proposed a relatively straightforward classification system that divides defects into three subtypes but does not specifically address the involvement of adjacent structures such as the orbit and zygoma. [51] based on a review of 108 patients, Davison *et al*. similarly divided patients into the two broad categories of "compete" or "partial" maxillectomy defects. [52] Although their group proposed a wide range of reconstructive techniques, the lack of a specific defect-oriented classification system outlining the remaining portion of the hard palate, dentition, orbit, and zygoma makes such an algorithm difficult to apply as a reconstructive guide. [53]

Figure 5. Maxillary atrophy after midface radiation for a small maxillary tumor 10 years back.

The same could be said for the classification proposed by Foster *et al*. [54] based on a single-surgeon series of 26 midfacial reconstructions; they classified defects into those involving soft-tissues and those involving bone. Bony midfacial defects were then subclassified into those involving more or less than half the palate. Triana *et al*. assessed 51 midfacial defects that had been treated with microvascular free-tissue transfer procedures. [55] The defects were classified as those seen after inferior partial maxillectomy, subtyped into the extent of palate lost and subdivided depending on the amount of malar bone and zygomatic arch lost. Okay *et al*. performed a retrospective review of 27 consecutive palatomaxillary reconstructions and designed a defect-oriented classification system designed to delineate the indica-

tion for prosthetic reconstruction, soft-tissue reconstruction, or vascularized bone-containing free flaps. [53] The authors concluded that the classification system does not address all factors required for decision-making. Although most of these classification systems allow for accurate descriptions of anatomical defects, many do not provide a clear algorithm for flap selection based on defect category. Others do not provide a comprehensive system for classifying defects of the midface that includes important structures such as the orbit or zygoma. One of the newer classifications has been proposed by McCarthy *et al*.56 They classify the maxillary defect of oncologic surgery origin into five distinct types; it is a rather straightforward classification but there are some deficiencies in this classification i.e. maxillary atrophy after radiation therapy (Figure 5,6).

Figure 6. Lateral skull x-ray showing the extent of atrophy of the mandible and maxilla.

An all inclusive classification is yet to be found; but as a rule of thumb maxillary reconstruction can be divided into three groups :

a. *Upper maxilla* which needs space filling or bulky flaps

b. *Lowermaxillaoralveolarridge* for which the prefabricated bone flaps are the best solution C: C*ombined or total maxillary defects* in this group a single flap addressing both the problems is yet to be found.

The McCarthy classification is as follows:

http://dx.doi.org/10.5772/52720

4.1. Type l: Limited maxillectomy

Type l defects include resection of one or two walls of the maxilla, excluding the palate. In most cases, the anterior wall is partially removed with either the medial wall and/or, occasionally, the orbital rim. In addition, these resections commonly involve the overlying cheek and can extend onto the lips, nose, or eyelids. Thus, type l or limited maxillectomy defects usually require a significant amount of skin for resurfacing with minimal associated bone volume (Figure 7).

Figure 7. Type l defect of the right hemi-maxilla with the alveolar ridge intact.

4.1.1. Treatment

The radial forearm fasciocutaneous flap provides good external skin coverage and minimal bulk in this setting. Multiple skin islands can be designed and de-epithelialized when needed to wrap around bone grafts or supply nasal lining. If critical segments of bone are missing, such as the orbital rim or the anterior floor of the orbit, nonvascularized bone grafts can provide the needed support. Other flap options, depending on the amount of soft-tissue bulk required, include the lateral arm flap, anterolateral thigh flap, [57] and scapula flap. [58]

4.2. Type ll: Subtotal maxillectomy

Type ll defects include resection of the maxillary arch, hard palate, and anterior and lateral walls (five walls) with preservation of the orbital floor (Figure 8).

Figure 8. Type ll defect, the alveolar ridge is removed but the floor of orbit is intact.

All type ll defects involving more than 50 percent of the transverse palate require flaps that provide a substantial surface area with which to reline the nasal floor and palatal roof, and bone for structural support. [59-61] Similarly, in patients who do not have sufficient retentive surfaces and/or teeth to support a conventional prosthesis, vascularized bone-containing free flap reconstruction is indicated.

4.2.1. Treatment

The associated bulk provided by the skin and soft tissues is a significant disadvantage to using the fibula osteocutaneous flap, therefore we recommend the use of the prelaminated fibula free flap for the reconstruction of these defects (Figures 9-15).62

Figure 9. A defect created after a maxillary tumor with alveolar ridge loss (two years after surgery).

Figure 10. The prelaminated fibula created and matured on the leg.

http://dx.doi.org/10.5772/52720

Figure 11. The flap has been transferred and the defect reconstructed.

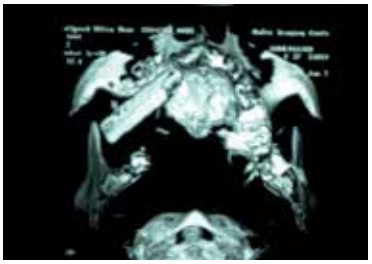

Figure 12. Axial CT scan showing the fibula in place.

Figure 13. The x-ray after implant fixture insertion.

Figure 14. The fixed prosthesis in place.

Figure 15. The panoramic view of the implant and the prelaminated fibula in place two years after surgery.

Various other donor sites have also been used to reconstruct these defects. Schliephake used a fasciocutaneous forearm flap followed by secondary bone grafting in two patients and reported that secondary nonvascularized bone grafting increases the risk of infection and is therefore not recommended. [63]

Use of the iliac crest free flap harvested with the internal oblique muscle has been reported by others. Iliac bone is plentiful and can provide a suitable bed for osseointegrated implants; however, its disadvantages include its short vascular pedicle and the potential for significant donor-site morbidity following its harvest. [58]

4.3. Type lll: Total maxillectomy

Type lll defects include resection of all six walls of the maxilla. These total maxillectomy defects are further subdivided into type lll a defects, where the orbital contents are preserved; and type lll b defects, where the orbital contents are exenterated.

4.3.1. Type llla

Reconstruction after total maxillectomy with preservation of the orbital contents is technically more challenging than maxillectomy with orbital exenteration. In this setting, reconstruction must: (1) provide support to the orbital contents, (2) obliterate any communication between the orbit and nasopharynx, and (3) reconstruct the palatal surface. When the orbital floor has been resected, support needs to be restored to the orbital contents; otherwise, the globe will prolapse downward, causing severe vertical dystopia with significant diplopia (Figure 16).

A variety of methods have been advocated to provide orbital support, including nonvascularized and vascularized bone grafts, alloplastic substitutes, and soft-tissue "slings." [64-65] we strongly advocate the use of **nonvascularized bone grafts** to support the orbital contents. By contrast, the use of alloplastic substitutes in defects that potentially expose it to the oronasal cavity increase the opportunity for periprosthetic infection. The volume of a soft-tissue flap may change over time [66] secondary to muscle atrophy, scar contracture, or changes in nutritional status. In this setting, even minor changes in volume can translate into significant changes in the vertical position of the soft-tissue sling and consequently the volume of the orbital cavity.

http://dx.doi.org/10.5772/52720

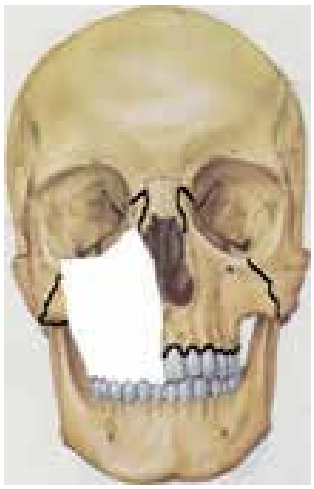

Figure 16. The defect created schematically shown; the floor of the orbit is intact.

By using the **rectus abdominis free flap** in combination with nonvascularized bone grafts, reconstruction of a three-dimensional defect is facilitated because the bone, skin, and soft-tissue components may be inset into their desired positions without compromising the microvascular aspect of the reconstruction. In addition, the rectus abdominis can be harvested easily during the resection and the pedicle can be extended up to 19 cm to reach the neck vessels.

Alternatively, the **temporalis flap** can be used to cover bone. Using this approach, however, requires the subsequent use of a palatal obturator; thus, the temporalis muscle flap is indicated primarily in older patients who are not candidates for free-tissue transfer. It is also useful for the patient who has an intact palate and preserved orbital contents (usually ethmoidal tumor resections), where access for free flap vessels is exceedingly difficult and muscle coverage is still needed to cover orbital bone grafts. [67] We however, support the use of vascularized bone flaps in this setting. The osteocutaneous free flap most frequently described for reconstruction of the maxillary region are the scapula, fibula, and radius. Each donor site has its own advantages and disadvantages.

The **osteocutaneous radial forearm flap** has been used for simultaneous reconstruction of the infraorbital margin and external skin in the midface. [68] Unfortunately, the volume of tissue transferred is rarely enough to obliterate the maxillary cavity completely, and palatal defects must be obturated with a prosthesis. [69]

Others have advocated the use of the **subscapular flap** to reconstruct defects caused by total maxillectomy with orbital preservation. Replacement of the alveolar arch inferiorly with the lateral scapular bone and the orbital floor and rim with the scapular tip has been described. [70] Schliephake reported difficulty however, in tailoring the scapular bone over the malar prominence, infraorbital rim, and maxillary wall at the same time that the lateral border of the scapula was to be positioned for placement of implants at the alveolar crest. [63] Yamamoto

et al. have similarly reported using the scapular bone in conjunction with costal cartilage for reconstruction of all the maxillary buttresses in extended midfacial defects. [49]

Several authors have described the use of **free fibula osteocutaneous flaps** to reconstruct combined maxillary and mandible defects. [71] we think that the prefabricated fibula can address the alveolar ridge and the palate but cannot reconstruct both the mandible and maxilla in one setting and also the prefabricated fibula cannot act as a space filling flap for upper maxillary defects (Figure 17,18).

Figure 17. The matured fibula ready for transfer.

Figure 18. The "on table" preparation of the fibula has been done, the complete maxillary arch is created, the amount of soft tissue can only cover the palatal defect

However, Futran *et al*. found that as the need for reconstruction of the zygomatic complex, infraorbital rim, and the floor increased, the fibula flap was limited in its ability to restore the entire maxillary form. [67] In addition, it was difficult to osteotomize and orient the bone to restore both the palate and the infraorbital area. Even with the harvest of additional soleus muscle bulk, it was difficult to rotate the skin paddle to resurface the palate and provide zygomatic and infraorbital contour. Based on this experience, their group concluded that when orbitozygomatic support is the primary objective, use of the fibular free flap is not advocated.

Brown presented three cases of reconstruction with the **iliac crest myo-osseous flap** with favorable functional results. [47] A "block" of iliac bone was used to restore alveolus, zygomatic prominence, and orbital rim with success. Genden *et al*. Described use of the iliac crest–

internal oblique osteomusculocutaneous free flap in six patients, four of whom had type llla defects. [72] The iliac crest was fashioned to recreate the inferior orbital rim; the internal oblique muscle was used to reline the palate and resurface the ipsilateral lateral nasal wall. Based on their report, all four patients achieved facial symmetry and underwent placement of osseointegrated implants. Others have discouraged the use of this flap however, because of its potentially excessive bulk, limited soft-tissue mobility in relationship to the bone and short pedicle length. [70-73]

4.3.2. Type lllb

Patients with type lllb defects undergo resection of the entire maxilla in addition to exenteration of the orbit (also known as the extended maxillectomy). These defects are extensive and have both large-volume and large–surface area requirements. The palate needs to be closed; the medial wall of the maxilla often needs to be restored to maintain an adequate airway; and the often extensive external defect, which can involve the eyelids, cheek, and occasionally the lip, need to be reconstructed. In addition, the anterior cranial base in the area of the sphenoid is often exposed and coverage of the brain becomes essential (Figure 19).

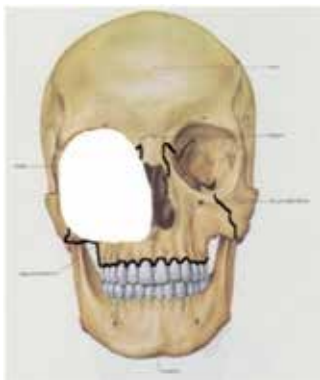

Figure 19. Type lllb defect; the lower portion of maxilla is intact.

If the external skin of the cheek is intact, a rectus abdominis free flap with a skin island used to close the palate is a simple, straightforward solution. If the flap is not too bulky, a second skin island to restore the lateral nasal wall can be used. A third skin island can be used to provide closure of the external skin deficit if necessary.4 [73-75]

Shestak *et al*. successfully used the **latissimus dorsi flap** in three patients with type lllb defects to fill the orbital cavity, seal the palate, and recontour the soft tissue of the face and cheek. [75] The latissimus dorsi was used because of its bulk, reliable anatomy, and ample pedicle length.

Palatal closure has its advantages and disadvantages in these reconstructions. If the palate is not closed (and muscle alone is used to cover the brain), the resultant massive intraoral defect requires a very large obturator, which can be difficult to support if there are no teeth left in the remaining maxilla. Palatal closure, although not ideal, makes sense because these patients can

usually speak well and eat soft solids without dentures. Denture fitting can be difficult if the skin bulges downward and there are no teeth to fit the prosthesis. However, because these patients would have similar difficulties with an open palate and function well even without a denture when closed, we feel that the palatal closure is generally advisable.

We do not attempt to reconstruct bony deficits in these patients because of the extensive nature of the defects. Bone-containing free flaps do not have the same versatility with regard to providing intraoral and extraoral lining and soft-tissue bulk and are therefore not generally indicated for the massive type lllb resections.

4.4. Type lV: Orbitomaxillectomy

Type lV or orbitomaxillectomy defects include five walls of the maxilla and the orbital contents, leaving the dura and brain exposed. The palate is usually left intact with these resections. Reconstructive objectives include the provision of adequate soft tissue and the resurfacing of external skin defects where necessary. Thus, a flap that provides a medium volume of soft tissue and has the potential to cover a medium/large surface area with one or more skin islands is required (Figure 20).

Figure 20. The complete defect with orbit involved.

The rectus abdominis flap can meet these requirements. These are conceptually simple reconstructive procedures, but the principal challenge is technical; one needs to anastomose the flap to a donor vessel in the neck, as temporal and facial vessels are usually resected or are unreliable. Dissection of the rectus pedicle extends the length up to 20 cm. A superficial tunnel in the face-lift plane allows transfer of the vessels; or, if the maxillary tubercle is resected, access can be gained by a parapharyngeal approach medial to the mandible. Maintaining the nasal

airway is often the most difficult problem in these patients; thus, a second skin island to address lateral nasal wall reconstruction is helpful. [76]

4.5. Reconstruction with vascularized autogenous tissue

Advances in tissue transfer techniques have made sophisticated reconstruction with autogenous tissues possible. In the past, it was thought that autogenous reconstruction after tumor surgery would interfere with examination for residual or recurrent disease. Advances in diagnostic techniques such as computerized tomography, magnetic resonance imaging, and endoscopy now enable the surgeon to evaluate the resection bed without direct inspection. [77-80] With the numerous free and pedicled flaps and the adjunctive modalities, such as enteral feeding tubes, tracheostomy, and osseointegrated dental prostheses now available to the reconstructive surgeon, many of the technical difficulties related to autogenous reconstruction can be circumvented, both in the perioperative period and over the long term.

The idea of "one wound one scar" has drastically altered our reconstructive approaches. Local flaps in extensive defects only make a defect a "larger" defect and a "larger scar" ensues and in extensive maxillary defects "new" tissue must be brought into the wound and enlarging the scar by local or adjacent flaps is not advisable. The free or prefabricated flaps are not the "last ditch measures" and they must be considered as the first line of treatment in these complex midfacial defects (Figure 21,22).

Figure 21. Frontal view, note the amount of forehead and upper lip scar.

Figures 21 shows a war-wounded veteran after 25 operations by world famous surgeons; the midface defect has been treated by local flaps, the maxillary defect remains and maxillary nonvascularized bone grafts, have all resorbed, the face and forehead are scarred.

Figure 22. The maxillary defect from below.

5. State of the art procedures: Flap prefabrication and prelamination

Flap prefabrication is a term that was first introduced and later clinically applied by Shen in the early 1980s.81-82 Flap prefabrication and prelamination are two closely related concepts. Clinical applications of flap prefabrication and prelamination are relatively new to the field of reconstructive plastic surgery. Although the two terms are often used interchangeably in the literature, they are two distinctly different techniques. Understanding their differences is helpful in planning the reconstructive strategy. They are primarily used in reconstructing complex defects where conventional techniques are not indicated.

5.1. Flap prefabrication

Flap prefabrication starts with introduction of a vascular pedicle to a desired donor tissue that on its own does not possess an axial blood supply. After a period of neovascularization of at least 8 weeks, this donor tissue can then be transferred to the recipient defect based on the newly acquired axial vasculature (Figure 23).

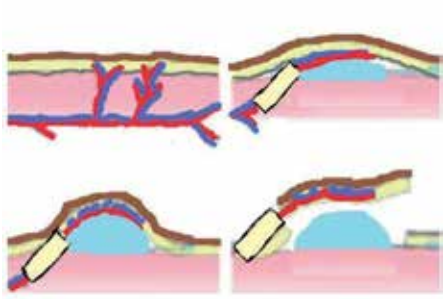

Figure 23. Flap prefabrication stages; vascular pedicle transferred under the skin paddle and the pedicle wrapped by either PTFE or silicone 62 and sometimes a tissue expander is inserted for expansion; the flap after proper expansion is transferred as a free or island flap.

http://dx.doi.org/10.5772/52720

Cartilage and bone can be incorporated into these flaps but they are mostly suitable for ear and nose reconstruction and for maxillary or mandibular reconstructions the prelamination method is the better choice. Flap prelamination, begins with building a three-dimensional structure on a reliable vascular bed. This composite structure, once matured in approximately 6-8 weeks can then be transferred to the recipient defect.

5.2. Flap prelamination

Flap prelamination is a term first coined by Pribaz and Fine in 1994. [83] The definition of "lamination" means bonding of thin sheets together to give a multilayered construction. In reconstructive surgery, the term "flap prelamination" has been used to describe a process of two or more stages for constructing a complex three-dimensional structure. The first stage involves adding different layers to an existing axial vascular territory as composite grafts, allowing time for the tissues to mature before being transferred (Figure 24-26).

Figure 24. The fibula with the muscle cuff has been dissected and is attached to the leg via its vascular pedicle.

Figure 25. The pedicle has been prepared up to the trifurcation of the artery.

Figure 26. The pedicle is wrapped in silicone sheet and the bone flap is fixed to the leg surface and covered by a split-thickness skin graft, (postoperative day 10).

An intermediate stage may be needed to further modify the flap, such as thinning, delaying, or adding additional tissue. [84] At the next stage, when the remote composite flap is completed, it is transferred to the defect based on the original axial blood supply. As with any composite graft, these added layers have to be sufficiently thin or small for them to take. The rationale for prelaminating those layers at a different site before transfer results from the belief that this offers the best chance for the prelaminating layers to heal, stabilize, and assume their expected structures and positions if the construction is performed in a reliable vascular bed at a less conspicuous site instead of in situ, where local complicating factors can be numerous. This is particularly important for reconstruction of functional units that need to be transferred to complex local environments, where structural leaks may cause grave complications (e.g., neourethra in the perineum and neoesophagus in the mediastinum).

5.3. Flap maturation

Because the blood supply is not manipulated, the time for a prelaminated flap to mature is shorter than for a prefabricated flap, [85] usually between 4 and 6 weeks. Intuitively, this makes sense because it represents a similar amount of time for any composite graft to fully take, whereas in a prefabricated flap, neovascularization needs to take place over a much larger and sometimes thicker dimension of tissue. Intermediate manipulation may be required to obtain a thinner flap or to delay an extended portion of a flap or to add additional graft material (Figure 27).

5.4. Flap transfer

Because the layering of structures takes place in an established vascular territory, venous congestion is usually not a problem in a prelaminated flap as it is often in a prefabricated flap. However, all flaps, including prelaminated flaps, become edematous after transfer, and there is increased scarring at each tissue healing interface. In attempting to reconstruct complex

http://dx.doi.org/10.5772/52720

Figure 27. Postoperative week 8,the flap is completely matured and ready for transfer

three-dimensional structures, the multiple layers with scarring and contractile forces at each interface can result in distortion and loss of contour of the flap. Because of this, the initial result is often suboptimal, and generally several revisions are necessary. This occurs especially in the face, where prelamination is used for reconstruction of central facial features, such as the nose and surrounding tissues. Once the prelaminated flap is healed in place and a stable foundation has been obtained, the external part can be de-epithelialized and covered with local advancement flaps or, in the case of nostril reconstruction, with a forehead flap for final esthetic reconstruction (Figure 28,29).

Figure 28. The flap has been dissected free from the leg and hangs on the pedicle which is wrapped in silicone, the dissection of the pedicle is fascilitated by the silicone sheet

6. Osseointegration techniques

The development of osseointegrated implants has revolutionized the approach to the dental rehabilitation of patients requiring maxillary reconstruction. The work of Branemark [86] and others has resulted in the development of the materials and techniques necessary to provide predictable and reliable implants that can be completely incorporated into grafted bone and

Figure 29. The silicone sheet is removed and the flap is ready for transfer.

support a fixed and stable dental prosthesis. [87-94] The use of osseointegrated implants in conjunction with free tissue transfer represents state-of-the-art reconstruction of large maxillary defects. The use of osseointegrated implants for dental rehabilitation has previously been much more extensively discussed in the context of mandibular reconstruction than that of maxillary reconstruction. [95] Some fundamental concepts of functional dental restoration with prosthetics should be understood. The reconstruction should provide for retention, support, and stabilization of the denture. Retention involves preventing the displacement of the prosthesis from the denture-bearing surface. Support implies that masticatory forces should not cause the prosthesis to impact vertically against the soft tissue of the load-bearing surface. Stabilization refers to the prevention of excessive lateral movement of the prosthesis. Dentures may be implant-borne, in which case the osseointegrated implants completely retain, support, and stabilize the prosthesis, or implant-retained, in which case the support and stabilization functions are shared by the denture-bearing surface and the retention of the prosthesis is completely dependent on the osseointegrated implants. Dentures that do not require osseointegrated implants are tissue-borne and tooth-supported, relying on the native tissues for retention and stabilization. [96]

Tissue-borne prostheses generally cannot be used in extensive maxillary defects because of insufficient residual palatal and alveolar tissues to provide support and retention. Funk *et al*. [96] defined such defects as those involving more than two-thirds of the maxillary arch. These defects typically require surgical reconstruction of the maxillary arch to provide neoalveolar bone of adequate thickness (approximately 10 mm) to accommodate osseointegrated implants, support a denture, and prevent its movement during mastication (Figure 30-34).

Bony reconstruction of the maxillary arch allows placement of the osseointegrated implants axial to the occlusal forces, a key factor for successful implant function. [96] Osseointegrated implants may be placed at the time of the reconstruction or secondarily, 6 to 8 weeks later. [96] Three to 8 months after placement, the osseointegrated implants are uncovered and prepared for final prosthetic reconstruction by a prosthodontist. [95]

http://dx.doi.org/10.5772/52720

Figure 30. The maxillary defect after shrapnel injury.

Figure 31. The matured fibula ready for transfer.

Figure 32. The fibula in place six months after surgery, please note the dark color of the grafted skin

Figure 33. The patient ten years after surgery with implant in place, the skin graft has completely transformed into mucosa and is glistening and has the color of mucosa.

Figure 34. The dentures in place, ten year postoperatively.

The use of free tissue transfer techniques in combination with osseointegrated implants for maxillary reconstruction has been reported by various authors. [97] Holle *et al*. [98] described a two-stage procedure for the reconstruction of maxillectomy defects. Initially, an osseous flap was created from the lateral border of the scapula; it incorporated osseointegrated implants, was covered with skin grafts, and was protected with a PTFE membrane. Three months later, the flap was harvested and transferred to the face using a microsurgical technique. This procedure successfully restored facial contour and allowed full dental rehabilitation. Funk *et al*. [59] used free scapular osseocutaneous flaps with primary or secondary osseointegrated implants for large palatomaxillary defects in three patients. These patients all underwent successful dental rehabilitation, with 94 percent stability of the implants at an average of 18 months after the completion of rehabilitation. Nakayama *et al*. [99] reconstructed a bilateral maxillectomy defect with a free fibula osseocutaneous flap combined with osseointegrated implants. Igawa *et al*. [100] recently reported the use of a prefabricated iliac crest free flap, which was secondarily vascularized by a rectus abdominis muscle flap and covered by split-

thickness skin graft, with the secondary placement of osseointegrated implants for functional alveolar ridge reconstruction after hemimaxillectomy.

7. Summary

Maxillary defects are one of the most challenging problems facing the reconstructive surgeon. Microsurgical tissue transfers evolved from the groin flap transfer to the complicated flap prefabrication and prelamination approaches to difficult reconstructive needs. These sophisticated techniques are distinctively different and yet can be perfectly complementary. Prelamination can add virtually anything to where there is a good axial blood supply, and prefabrication can bring an axial blood supply to almost anywhere in the body. The two techniques can even be combined when certain complex reconstructive needs are present. Prefabrication and prelamination can also serve as a conduit through which products of tissue engineering and embryonic stem cell technologies can be applied to the reconstruction of head and neck defects. Tissues synthesized in vitro with better structural, color, texture, and functional match can be prelaminated to a site that has already been prefabricated. Prefabrication of a bioabsorbable matrix system can create a well perfused scaffold to which more and larger subunits can be prelaminated.

As our understanding of the techniques evolves, the breadth of their usage will also expand. These techniques will continue to be useful to help solve many difficult problems that baffle even the very best reconstructive surgeons, and the potential for these techniques may be used to bring tissue engineering from the laboratory to clinical reality. Lastly, as progress is made in transplant pharmacology, the immunologic barrier to feasible composite tissue allograft transplantation may be overcome. This represents the beginning of a new era in reconstructive surgery.

Author details

Shahram Nazerani[1,2]

1 Associate Professor of Surgery, Firouzgar Hospital, Teheran, Iran

2 Tehran University of Medical Sciences, Tehran, Iran

References

[1] Schendel, S. A., and Delaire, J. Facial Muscles: Form, Function, and Reconstruction in Dentofacial Deformities. In W. H. Bell (Ed.), *Surgical Correction of Dentofacial Deformities*, Vol. 3. Philadelphia: Saunders, 1985.

[2] Hammond, J. Dental care of edentulous patients after resection of maxilla. *Br. Dent. J.* 120: 591, 1966.

[3] Curtis, T. A., and Beumer, J. Restoration of Acquired Hard Palate Defects: Etiology, Disability, and Rehabilitation. In J. Beumer, T. A. Curtis, and M. T. Marunick (Eds.), *Maxillofacial Rehabilitation: Prosthodontic and Surgical Considerations.* St. Louis: Ishiyaku EuroAmerica, 1996.

[4] Edgerton, M. T., Jr., and Zovickian, A. Reconstruction of major defects of the palate. *Plast. Reconstr. Surg.* 17: 105, 1956.

[5] Converse, J. M. Early and late treatment of gunshot wounds of the jaw in French battle casualties in North Africa and Italy. *J. Oral Surg.* 3: 112, 1945.

[6] Miller, T. A. The Tagliacozzi flap as a method of nasal and palatal reconstruction. *Plast. Reconstr. Surg.* 76: 870, 1985.

[7] Miller, T. A. The Tagliacozzi flap as a method of nasal and palatal reconstruction. *Plast. Reconstr. Surg.* 76: 870, 1985.

[8] Elliott, R. A., Jr. Use of nasolabial skin flap to cover intraoral defects. *Plast. Reconstr. Surg.* 58: 201, 1976.

[9] Chambers, R. G., Jaques, D. A., and Mahoney, W. D. Tongue flaps for intraoral reconstruction. *Am. J. Surg.* 118: 783, 1969.

[10] Jackson, I. T. *Local Flaps in Head and Neck Reconstruction.* St. Louis: Mosby, 1985.

[11] Niederdellmann, H., Munker, G., and Lange, G. Reconstruction of a defect of the orbital floor with a rotated flap from the nasal wall: A case report. *J. Maxillofac. Surg.* 2: 153, 1974.

[12] Crow, M. L., and Crow, F. J. Resurfacing large cheek defects with rotation flaps from the neck. *Plast. Reconstr. Surg.* 58: 196, 1976.

[13] Edgerton, M. T., and DeVito, R. V. Closure of palatal defects by means of a hinged nasal septum flap. *Plast. Reconstr. Surg.* 31: 537, 1963.

[14] Becker, D. W., Jr. A cervicopectoral rotation flap for cheek coverage. *Plast. Reconstr. Surg.* 61: 868, 1978.

[15] Guerrerosantos, J., and Altamirano, J. T. The use of lingual flaps in repair of fistulas of the hard palate. *Plast. Reconstr. Surg.* 38: 123, 1966.

[16] Wallace, A. F. Esser's skin flap for closing large palatal fistulae. *Br. J. Plast. Surg.* 19: 322, 1966.

[17] Komisar, A., and Lawson, W. A compendium of intraoral flaps. *Head Neck Surg.* 8: 91, 1985.

[18] Campbell, H. H. Reconstruction of the left maxilla. *Plast. Reconstr. Surg.* 3: 66, 1948.

[19] Baker, S. R. Closure of large orbito-maxillary defects with free latissimus dorsi myocutaneous flaps. *Head Neck Surg.* 6: 828, 1984.

[20] Matloub, H. S., Larson, D. L., Kuhn, J. C., *et al*. Lateral arm free flap in oral cavity reconstruction: A functional evaluation. *Head Neck Surg.* 11: 205, 1989.

[21] Matloub, H. S., Sanger, J. R., and Godina, M. Lateral Arm Neurosensory Flap. In H. B. Williams (Ed.), *Transactions of the 8th International Congress on Plastic and Reconstructive Surgery.* Montreal: International Plastic and Reconstructive Surgery, 1983. P. 125.

[22] Jones, N. F., Hardesty, R. A., Swartz, W. M., *et al*. Extensive and complex defects of the scalp, middle third of the face, and palate: The role of microsurgical reconstruction. *Plast. Reconstr. Surg.* 82: 937, 1988.

[23] Inoue, T., Harashina, T., Asanami, S., and Fujino, T. Reconstruction of the hard palate using free iliac bone covered with jejunal flap. *Br. J. Plast. Surg.* 41: 143, 1988.

[24] Panje, W. R., Krause, C. J., Bardach, J., and Baker, S. R. Reconstruction of intraoral defects with the free groin flap. *Arch. Otolaryngol.* 103: 78, 1977.

[25] Vaughan, E. D. The radial forearm free flap in orofacial reconstruction: Personal experience in 120 consecutive cases. *J. Craniomaxillofac. Surg.* 18: 2, 1990.

[26] Vuillemin, T., Raveh, J., and Ramon, Y. Reconstruction of the maxilla with bone grafts supported by the buccal fat pad. *J. Oral Maxillofac. Surg.* 46: 100, 1988.

[27] Kruger, E. Reconstruction of bone and soft tissue in extensive facial defects. *J. Oral Maxillofac. Surg.* 40: 714, 1982.

[28] McCarthy, J. G., and Zide, B. M. The spectrum of calvarial bone grafting: Introduction of the vascularized calvarial bone flap. *Plast. Reconstr. Surg.* 74: 10, 1984.

[29] Cutting, C. B., McCarthy, J. G., and Berenstein, A. Blood supply of the upper craniofacial skeleton: The search for composite calvarial bone flaps. *Plast. Reconstr. Surg.* 74: 603, 1984.

[30] Yaremchuk, M. J. Vascularized bone grafts for maxillofacial reconstruction. *Clin. Plast. Surg.* 16: 29, 1989.

[31] Antonyshyn, O., Gruss, J. S., and Birt, B. D. Versatility of temporal muscle and fascial flaps. *Br. J. Plast. Surg.* 41: 118, 1988.

[32] Serafin, D., Riefkohl, R., Thomas, I., and Georgiade, N. G. Vascularized rib periosteal and osteocutaneous reconstruction of the maxilla and mandible: An assessment. *Plast. Reconstr. Surg.* 66: 718, 1980.

[33] Lind, M. G., Arnander, C., Gylbert, L., *et al*. Reconstruction in the head and neck regions with free radial forearm flaps and split-rib bone grafts. *Am. J. Surg.* 154: 459, 1987.

[34] MacLeod, A. M., Morrison, W. A., McCann, J. J., *et al*. The free radial forearm flap with and without bone for closure of large palatal fistulae. *Br. J. Plast. Surg.* 40: 391, 1987.

[35] Conley, J., and Patow, C. Cranio Osseo-Myofascial Flaps. In J. J. Conley (Ed.), *Flaps in Head and Neck Surgery.* New York: Thieme Medical Publishing, 1989.

[36] Casanova, R., Cavalcante, D., Grotting, J. C., Vasconez, L. O., and Psillakis, J. M. Anatomic basis for vascularized outer table calvarial bone flaps. *Plast. Reconstr. Surg.* 78: 300, 1986.

[37] Branemark, P. I. Osseointegration and its experimental background. *J. Prosthet. Dent.* 50: 399, 1983.

[38] Jackson, I. T., Tolman, D. E., Desjardins, R. P., and Branemark, P. I. A new method for fixation of external prostheses. *Plast. Reconstr. Surg.* 77: 668, 1986.

[39] Tjellstrom, A., and Jacobsson, M. The Bone Anchored Maxillofacial Prosthesis. In T. Albrektson and G. Zarb (Eds.), *The Branemark Osseointegrated Implant.* Chicago: Quintessence Publishing, 1989.

[40] Holle, J., Vinzenz, K., Wuringer, E., *et al*. The prefabricated combined scapula flap for bony and soft-tissue reconstruction in maxillofacial defects: A new method. *Plast. Reconstr. Surg.* 98: 542, 1996.

[41] Li, K. K., Stephens, W. L., and Gliklich, R. Reconstruction of the severely atrophic edentulous maxilla using Le Fort I osteotomy with simultaneous bone graft and implant placement. *J. Oral Maxillofac. Surg.* 54: 542, 1996.

[42] Schmelzeisen, R., Neukam, F. W., Shirota, T., *et al*. Postoperative function after implant insertion in vascularized bone grafts in maxilla and mandible. *Plast. Reconstr. Surg.* 97: 719, 1996.

[43] Nakayama, B., Matsuura, H., Ishihara, O., *et al*. Functional reconstruction of a bilateral maxillectomy defect using a fibula osteocutaneous flap with osseointegrated implants. *Plast. Reconstr. Surg.* 96: 1201, 1995.

[44] Arcuri, M. R. Titanium implants in maxillofacial reconstruction. *Otolaryngol. Clin. North Am.* 28: 351, 1995.

[45] Donovan, M. G., Dickerson, N. C., Hanson, L. J., and Gustafson, R. B. Maxillary and mandibular reconstruction using calvarial bone grafts and Branemark implants: A preliminary report. *J. Oral Maxillofac. Surg.* 52: 588, 1994.

[46] Futran ND, Mendez E. Developments in reconstruction of midface and maxilla. *Lancet Oncol*. 2006;7:249–258.

[47] Brown JS, Rogers SN, McNally DN, Boyle M. A modified classification for the maxillectomy defect. *Head Neck* 2000;22:17–26.

[48] Wells MD, Luce EA. Reconstruction of midfacial defects after surgical resection of malignancies. *Clin Plast Surg*. 1995;22:79–89.

[49] Yamamoto Y, Kawashima K, Sugihara T, Nohira K, Furuta Y, Fukuda S. Surgical management of maxillectomy defects based on the concept of buttress reconstruction. *Head Neck* 2004;26:247–256.

[50] Yamamoto Y. Mid-facial reconstruction after maxillectomy. *Int J Clin Oncol*. 2005;10:218–222.

[51] Spiro RH, Strong EW, Shah JP. Maxillectomy and its classification. *Head Neck* 1997;19:309–314.

[52] Davison SP, Sherris DA, Meland NB. An algorithm for maxillectomy defect reconstruction. *Laryngoscope* 1998;108:215–219.

[53] Okay DJ, Genden E, Buchbinder D, Urken M. Prosthodontic guidelines for surgical reconstruction of the maxilla: A classification system of defects. *J Prosthet Dent*. 2001;86:352–363.

[54] Foster RD, Anthony JP, Singer MI, Kaplan MJ, Pogrel MA, Mathes SJ. Microsurgical reconstruction of the midface. *Arch Surg*. 1996;131:960–965; discussion 965–966.

[55] Triana RJ Jr, Uglesic V, Virag M, *et al*. Microvascular free flap reconstructive options in patients with partial and total maxillectomy defects. *Arch Facial Plast Surg*. 2000;2:91–101.

[56] McCarthy, Colleen M. M.D., M.S.; Cordeiro, Peter G. M.D. Microvascular Reconstruction of Oncologic Defects of the Midface, *Plastic & Reconstructive Surgery.* 2010 ;126 :6 ; 1947-1959

[57] Amin A, Rifaat M, Civantos F, Weed D, Abu-Sedira M, Bassiouny M. Free anterolateral thigh flap for reconstruction of major craniofacial defects. *J Reconstr Microsurg*. 2006;22:97–104.

[58] Archibald S, Jackson S, Thoma A. Paranasal sinus and midfacial reconstruction. *Clin Plast Surg.* 2005;32:309–325.

[59] Funk GF, Arcuri MR, Frodel JL Jr. Functional dental rehabilitation of massive palatomaxillary defects: Cases requiring free tissue transfer and osseointegrated implants. *Head Neck* 1998;20:38–51.

[60] Genden EM, Wallace DI, Okay D, Urken ML. Reconstruction of the hard palate using the radial forearm free flap: Indications and outcomes. *Head Neck* 2004;26:808–814.

[61] Cordeiro PG, Bacilious N, Schantz S, Spiro R. The radial forearm osteocutaneous "sandwich" free flap for reconstruction of the bilateral subtotal maxillectomy defect. *Ann Plast Surg*. 1998;40:397–402.

[62] Nazerani S, Behnia H, Motamedi MH . Experience with the prefabricated free fibula flap for reconstruction of maxillary and mandibular defects. J Oral Maxillofac Surg. 2008 Feb;66(2):260-4.

[63] .Schliephake H. Revascularized tissue transfer for the repair of complex midfacial defects in oncologic patients. *J Oral Maxillofac Surg*. 2000;58:1212–1218.

[64] Cinar C, Arslan H, Ogur S, Kilic A, Bingol UA, Yucel A. Free rectus abdominis myocutaneous flap with anterior rectus sheath to provide the orbital support in globe-sparing total maxillectomy. *J Craniofac Surg*. 2006;17:986–991.

[65] .Askar I, Oktay MF, Kilinc N. Use of radial forearm free flap with palmaris longus tendon in reconstruction of total maxillectomy with sparing of orbital contents. *J Craniofac Surg*. 2003;14:220–227.

[66] Sarukawa S, Okazaki M, Asato H, Koshima I. Volumetric changes in the transferred flap after anterior craniofacial reconstruction. *J Reconstr Microsurg*. 2006;22:499–505; discussion 506–507.

[67] Futran ND, Haller JR. Considerations for free-flap reconstruction of the hard palate. *Arch Otolaryngol Head Neck Surg*. 1999;125:665–669.

[68] McLoughlin PM, Gilhooly M, Phillips JG. Reconstruction of the infraorbital margin with a composite microvascular free flap. *Br J Oral Maxillofac Surg*. 1993;31:227–229.

[69] Chepeha DB, Moyer JS, Bradford CR, Prince ME, Marentette L, Teknos TN. Osseocutaneous radial forearm free tissue transfer for repair of complex midfacial defects. *Arch Otolaryngol Head Neck Surg*. 2005;131:513–517.

[70] Coleman JJ III. Osseous reconstruction of the midface and orbits. *Clin Plast Surg*. 1994;21:113–124.

[71] Taylan G, Yildirim S, Akoz T. Reconstruction of large orbital exenteration defects after resection of periorbital tumors of advanced stage. *J Reconstr Microsurg*. 2006;22:583–589.

[72] Genden EM, Wallace D, Buchbinder D, Okay D, Urken ML. Iliac crest internal oblique osteomusculocutaneous free flap reconstruction of the postablative palatomaxillary defect. *Arch Otolaryngol Head Neck Surg*. 2001;127:854–861.

[73] Cordeiro PG, Disa JJ. Challenges in midface reconstruction. *Semin Surg Oncol*. 2000;19:218–225.

[74] Taylan G, Yildirim S, Akoz T. Reconstruction of large orbital exenteration defects after resection of periorbital tumors of advanced stage. *J Reconstr Microsurg*. 2006;22:583–589.

[75] Shestak KC, Schusterman MA, Jones NF, Johnson JT. Immediate microvascular reconstruction of combined palatal and midfacial defects using soft tissue only. *Microsurgery* 1988;9:128–131.

[76] Cordeiro PG, Santamaria E. A classification system and algorithm for reconstruction of maxillectomy and midfacial defects. *Plast Reconstr Surg.* 2000;105:2331–2346; discussion

[77] Boyne, P. J., Christiansen, E. L., and Thompson, J. R. Advanced imaging of osseous maxillary clefts. *Radiol. Clin. North Am.* 31: 195, 1993.

[78] Metes, A., Hoffstein, V., Direnfeld, V., *et al*. Three-dimensional CT reconstruction and volume measurements of the pharyngeal airway before and after maxillofacial surgery in obstructive sleep apnea. *J. Otolaryngol.* 22: 261, 1993.

[79] Remonda, L., Schroth, G., Ozdoba, C., *et al*. Facial intraosseous arteriovenous malformations: CT and MR features. *J. Comput. Assist. Tomogr.* 19: 277, 1995.

[80] Bradrick, J. P., Smith, A. S., Ohman, J. C., and Indresano, A. T. Estimation of maxillary alveolar cleft volume by three-dimensional CT. *J. Comput. Assist. Tomogr.* 14: 994, 1990.

[81] Shen ZY. Vascular implantation into skin flap: Experimental study and clinical application. A preliminary report. *Plast Reconstr Surg.* 1981;68:404–410.

[82] Shen ZY. Microvascular transplantation of prefabricated free thigh flap (letter). *Plast Reconstr Surg.* 1982;69:568.

[83] Pribaz JJ, Fine NA. Prelamination: Defining the prefabricated flap. A case report and review. *Microsurgery* 1994;15:618–623.

[84] Walton RL, Burget GC, Beahm EK. Microsurgical reconstruction of the nasal lining. *Plast Reconstr Surg.* 2005;115:1813–1829.

[85] Pribaz JJ, Fine NA. Prefabricated and prelaminated flaps for head and neck reconstruction. *Clin Plast Surg.* 2001;28:261–272.

[86] Branemark, P. I. Osseointegration and its experimental background. *J. Prosthet. Dent.* 50: 399, 1983.

[87] Jackson, I. T., Tolman, D. E., Desjardins, R. P., and Branemark, P. I. A new method for fixation of external prostheses. *Plast. Reconstr. Surg.* 77: 668, 1986.

[88] Tjellstrom, A., and Jacobsson, M. The Bone Anchored Maxillofacial Prosthesis. In T. Albrektson and G. Zarb (Eds.), *The Branemark Osseointegrated Implant.* Chicago: Quintessence Publishing, 1989.

[89] Holle, J., Vinzenz, K., Wuringer, E., *et al*. The prefabricated combined scapula flap for bony and soft-tissue reconstruction in maxillofacial defects: A new method. *Plast. Reconstr. Surg.* 98: 542, 1996.

[90] Li, K. K., Stephens, W. L., and Gliklich, R. Reconstruction of the severely atrophic edentulous maxilla using Le Fort I osteotomy with simultaneous bone graft and implant placement. *J. Oral Maxillofac. Surg.* 54: 542, 1996.

[91] Schmelzeisen, R., Neukam, F. W., Shirota, T., *et al*. Postoperative function after implant insertion in vascularized bone grafts in maxilla and mandible. *Plast. Reconstr. Surg.* 97: 719, 1996.

[92] Nakayama, B., Matsuura, H., Ishihara, O., *et al*. Functional reconstruction of a bilateral maxillectomy defect using a fibula osteocutaneous flap with osseointegrated implants. *Plast. Reconstr. Surg.* 96: 1201, 1995.

[93] Arcuri, M. R. Titanium implants in maxillofacial reconstruction. *Otolaryngol. Clin. North Am.* 28: 351, 1995.

[94] Donovan, M. G., Dickerson, N. C., Hanson, L. J., and Gustafson, R. B. Maxillary and mandibular reconstruction using calvarial bone grafts and Branemark implants: A preliminary report. *J. Oral Maxillofac. Surg.* 52: 588, 1994.

[95] Urken, M. L., Buchbinder, D., Weinberg, H., *et al*. Primary placement of osseointegrated implants in microvascular mandibular reconstruction. *Otolaryngol. Head Neck Surg.* 101: 56, 1989.

[96] Funk, G. F., Arcuri, M. R., and Frodel, J. L., Jr. Functional dental rehabilitation of massive palatomaxillary defects: Cases requiring free tissue transfer and osseointegrated implants. *Head Neck* 20: 38, 1998.

[97] Schmelzeisen, R., Neukam, F. W., Shirota, T., *et al*. Postoperative function after implant insertion in vascularized bone grafts in maxilla and mandible. *Plast. Reconstr. Surg.* 97: 719, 1996.

[98] Holle, J., Vinzenz, K., Wuringer, E., *et al*. The prefabricated combined scapula flap for bony and soft-tissue reconstruction in maxillofacial defects: A new method. *Plast. Reconstr. Surg.* 98: 542, 1996.

[99] Nakayama, B., Matsuura, H., Ishihara, O., *et al*. Functional reconstruction of a bilateral maxillectomy defect using a fibula osteocutaneous flap with osseointegrated implants. *Plast. Reconstr. Surg.* 96: 1201, 1995.

[100] Igawa, H. H., Minakawa, H., and Sugihara, T. Functional alveolar ridge reconstruction with prefabricated iliac crest free flap and osseointegrated implants after hemimaxillectomy. *Plast. Reconstr. Surg.* 102: 2420, 1998.

Chapter 19

Maxillofacial Reconstruction of Ballistic Injuries

Mohammad Hosein Kalantar Motamedi,
Seyed Hossein Mortazavi, Hossein Behnia,
Masoud Yaghmaei, Abbas Khodayari,
Fahimeh Akhlaghi, Mohammad Ghasem Shams and
Rashid Zargar Marandi

Additional information is available at the end of the chapter

http://dx.doi.org/10.5772/53119

1. Introduction

This chapter presents our experience with treatment of facial fractures and defects subsequent to various ballistic injuries based on experience gained from management of numerous warfare injuries during the Iraq-Iran war and thereafter (1986-2013).

2. Presentation

The clinical presentation and devastation of penetrating injuries of the face resulting from ballistic weaponry varies according to the caliber of the weapon used, the distance from which the victim is shot and velocity of the projectile. Projectiles from ballistic weaponry may be either high-velocity or low- velocity.

2.1. High-velocity projectiles

High-velocity projectiles to the face have devastating functional and esthetic consequences because they shatter and scatter the bones and teeth. The entry wound is usually small while the exit wound is large and management is difficult.

INTECH
open science | open minds

© 2013 Motamedi et al.; licensee InTech. This is a paper distributed under the terms of the Creative Commons Attribution License (http://creativecommons.org/licenses/by/3.0), which permits unrestricted use, distribution, and reproduction in any medium, provided the original work is properly cited.

2.2. Low-velocity projectiles

Low-velocity projectiles are usually less devastating with regard to fracture pattern and tissue damage ; therefore management of these injuries is usually less complicated.

3. Management

Generally, treatment of ballistic injuries mandate prompt assessment and early comprehensive management in the first operation [1-3]. However, some [4,5] feel that delayed reconstruction of ballistic injuries, avoidance of mini-plates, use of small incisions, minimal exposure of bony fragments, external pin fixations, and avoidance of intraosseous wiring is safer (fearing necrosis, infection and other complications).

3.1. Controversies in comprehensive management: Early vs. delayed intervention

3.1.1. Proponents of delayed intervention

Ballistic wounds are considered contaminated and this is why some are against early intervention and comprehensive management at the first operation. Advocates of delayed intervention state that delayed repair ensures a clean, segregated wound bed [5].

3.1.2. Proponents of early intervention

Those in favor of early intervention and comprehensive management at the first operation state that delay causes problems such as contracture scars, deformity, displacement of bone segments (due to muscle pull), difficulty in fracture reduction, patient anxiety, longer hospital stay and an additional operation to reopen the same wound (closed hastily at the field hospital, nearest emergency post or local hospital before transfer) in order to graft the hard or soft tissues [6,7].

In the maxillofacial region many ballistic injuries may be treated early; and several authors have opposed the strategy of universally delaying all surgical interventions of facial ballistic injuries suggesting a more comprehensive surgical operation can be done primarily in many [2,6-8]. Good results following acute treatment of projectile facial wounds during a 4-year period in the Afghan war has been reported more recently. Definitive and comprehensive treatment of ballistic facial injuries in the first stage with minimal debridement has been shown to result in better restoration of the facial deformity, lower morbidity, faster return of function, shorter hospital stay, and one less operation for the patient (when bone continuity was obtained)[2,7,9,10]. Additional advantages of early single-stage repair include a fresh wound, ability to expose and locate displaced fracture segments upon debridement, easier anatomic reduction of facial fractures (no fibrosis), facilitated arch bar placement, facilitated fracture manipulation reduction and osteosynthesis (no contractures) and definitive soft-tissue management. Moreover, it also allows for restoration of

occlusion, salvaging loose teeth, a more expedient return of function and closer restoration of pre-injury appearance postoperatively [9,10].

3.2. Injury assessment

Ballistic injuries to the face must be assessed and addressed with regard to the wounds sustained, the injury profile and general status of the patient to decide when and how to treat. The criteria which dictate when to operate are discussed in this chapter as are the results, outcomes, and benefits of treating both hard and soft tissues in the first operation (early comprehensive management).

4. Early comprehensive management of ballistic injuries to the face

From 1991 to 2012 we treated 51 patients aged 8 – 50 years (mean 24.4±7.8 yrs.) for ballistic injuries of the face; 30 were rendered early comprehensive management based on indication.

4.1. Indications for early intervention to treat both hard and soft tissue ballistic injuries at the first operation

Early intervention and comprehensive management was done when there was:

- No gross infection
- No bone comminution to preclude osteosynthesis
- No extensive soft tissue loss to preclude bone coverage
- No general health problems such as medical instability or moribund patient
- No need for major grafting
- No concomitant more serious or life-threatening injuries requiring urgent attention

In these cases, acute management aimed to treat both hard and soft tissue injuries definitively at the first operation to restore arch continuity; because occlusion, form, function and esthetics can be restored later provided that continuity has been restored.

4.2. Contraindications for early intervention to treat both hard and soft tissue ballistic injuries in the first operation

Early intervention and comprehensive management was not done when there was:

- Gross infection
- Concomitant more serious injury or multiple injuries of higher priority
- Poor general health
- Pulverized bone precluding fixation

- Extensive loss of soft-tissue (requiring distant flaps)
- Requirment for large bone grafts

4.3. Treatment procedure (inside-out and bottom-up)

Thirty patients with maxillofacial ballistic injuries underwent early intervention to treat both hard and soft tissues at the first operation; basic treatment included:

a. General anesthesia, nasoendotracheal intubation and throat pack placement

b. Extensive oral and extraoral irrigation (dilute hydrogen peroxide + povidone iodide followed by normal saline), brushing the teeth and debridement of facial wounds.

c. Arch bar placement (in dentate patients), establishing occlusion and temporary maxillo-mandibular fixation (MMF)

d. Removal of floating fragments (teeth particles, debris, and shell fragments) while salvaging bone; tooth roots within the alveolus were not extracted at this stage nor were mobile teeth.

e. Locating the scattered bone segments within the wound and using them to restore bone continuity especially in the mandible.

f. Removal of temporary MMF and removal of throat pack.

g. Placement of MMF.

h. Wound closure in layers following irrigation (from the inside-out) using 3-0 polygalactin, 4-0 polygalactin and 5-0 nylon sutures respectively.

Note: In addition to arch bars, titanium miniplates or wires were used as necessary following fracture reduction.

- In all dentate cases, arch bars were first placed and intermaxillary fixation (temporary MMF) was done prior to bone reduction to re-establish the occlusion. Then, the fractured and scattered bone segments were realigned and fixated using miniplates, lag screws, reconstruction plates, or titanium trays (Figure 1 A-D). Final MMF was placed after removal of the throat pack.
- Arch bar placement with MMF but without osteosynthesis was possible when the reduced bone segments contained teeth.
- High velocity ballistic wounds cause fracture and dispersion of teeth, bone, foreign bodies and debris into the lips, tongue, cheeks, and elsewhere; these sites were visualized, palpated and searched prior to wound closure.
- Projectiles beyond the depth of the wound and not within reach were not sought.
- After management of the hard tissues, soft tissue injuries were treated by debridement and primary wound closure performed loosely in layers from the inside out, using common local flap techniques to compensate for the tissue loss.

http://dx.doi.org/10.5772/53119

- In cases with bone comminution the soft tissues were closed and bone graft was done 3 – 4 weeks later when wounds had healed.

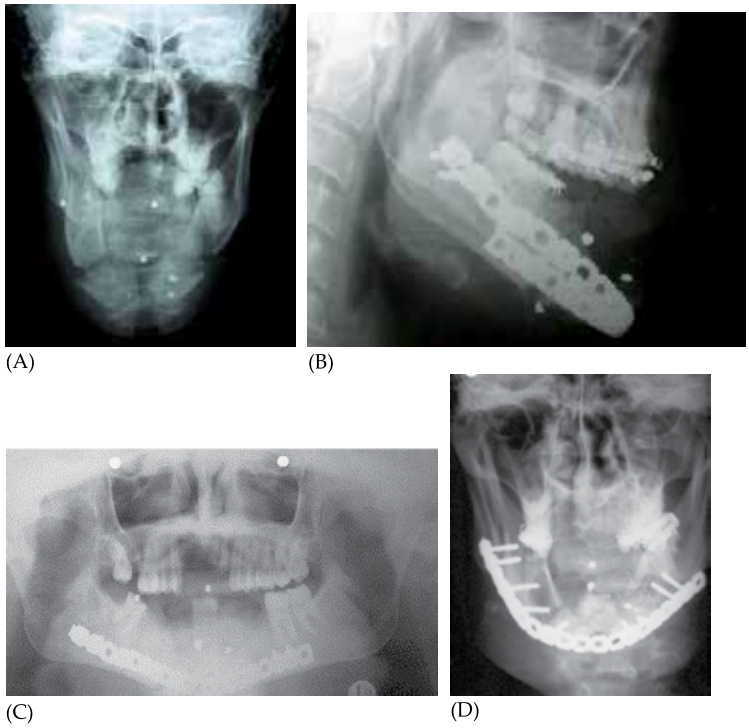

Figure 1. (A) Posterior–anterior skull radiograph of a typical patient shot in the face revealing multiple fragments of the mandible displaced inferiorly into the neck due to suprahyoid muscle pull. First arch bars and MMF and then a reconstruction plate were placed. (B) Lateral view after location, reduction of segments, and screw fixation of bone fragments ; large bone segments were secured to the reconstruction plate restoring continuity and chin projection. Smaller segments were wedged in place. (C) Panoramic view 6 months later showing bone consolidation and restoration of bone continuity. Had this not been done another operation to bone graft the mandible would have been necessary again with MMF. (D). PA view postoperatively. Note bone segments, reduced and fixed by 2.7mm screws in order to obtain mandibular continuity.

5. Clinical course

Thirty of 51 patients were treated for both hard and soft tissues injuries at the first operation (comprehensive intervention). Patient ages ranged from 8 to 50 years (mean 24.4±7.8 years). All patients were male. The mandible was injured in 96% and the maxilla in 54%; 22% required tracheotomy; 91% had isolated facial injuries with no other body area injured; 64% were managed in a single definitive early operation and 36% required two major operations. In the acute group, 6/30 patients had minor complications such as scarring and wound discharge. Transient postoperative discharge from the flap suture site was noted in these patients; this

resolved within several weeks following daily irrigation and cleansing of the wound site. The procedures in these patients are shown in Table 1.

Early comprehensive intervention for firearm injuries to the face was effective in all 30 selected cases. This resulted in restoration of occlusion and continuity of the jaw, fixation of luxated or extruded teeth, early return of function, prevention of segment displacement due to tissue contracture, less scarring, and no need for major bone graft reconstruction later on [Table 2]. Flap healing was favorable in all patients. None of the patients had major complications (i.e., necrosis or osteomyelitis).

Procedure and type of fracture fixation	Percentage
Primary debridement + open fracture reduction (without wire, plate, or screw osteosynthesis) + wound closure	62.5 %
Primary debridement + open reduction (with wire, plate, or screw osteosynthesis) + wound closure	37.5 %

Table 1. Type of fracture fixation used in 30 patients treated via early comprehensive intervention in the first operation.

Those not treated primarily were only debrided and had arch bars placed. Definitive treatment of hard and soft tissue management was rendered in another subsequent operation after soft tissues and defects had healed. At that time, bone reduction was difficult because of scarring, and displacement of remaining segments (due to muscle pull especially in the chin, mandibular angle and ramus where medial displacement was common). Reduction of extruded and displaced teeth was also difficult and often not feasible. Wound edges were inverted and required undermining. No significant differences however, were noted in terms of infection or other major complications following early or delayed intervention [Table 2].

Treatment	Displaced / extruded or intruded teeth	Healing	Fracture reduction and fixation	Wound Bed	Contracture	Hospital stay	Arch bar placement and occlusion	Anxiety	Ability to expose / locate
Early	Can be placed back into the socket and into occlusion	Primary	Easy	Fresh	Not seen	Shorter	Easier	Less	Easier
Delayed	Often cannot be placed in the socket or into occlusion	Secondary	Difficult	Often granulated requiring refreshing of tissue borders	Seen often	Longer	More difficult	Greater	More difficult

Table 2. Comparison of benefits of early comprehensive intervention versus delayed intervention in management of maxillofacial ballistic injuries.

In some injuries primary treatment may not be indicated nor possible (ie.brain edema) see Figure 2.

http://dx.doi.org/10.5772/53119

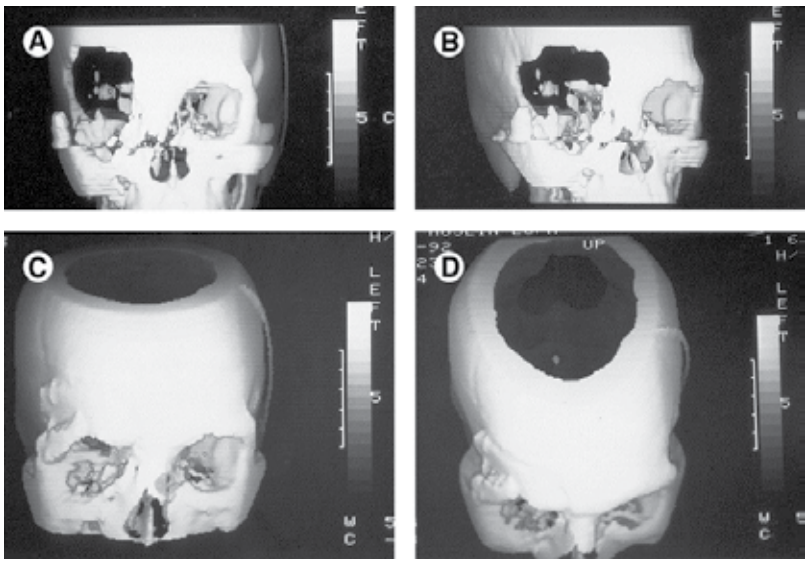

Figure 2. (A) Three-dimensional computed tomography scan of an extensive high-velocity bullet wound exiting the right orbit and anterior skull. (B) Note the amount of damage that may be inflicted by high-velocity projectiles. (C and D) After neurosurgery, reconstruction of the hard tissues was done via iliac bone grafts.

6. Discussion

There is no consensus on the timing of treatment for bone and soft tissue injuries resulting from firearms. The conventional method is primary closure, serial debridements and definitive reconstruction at a later stage. An alternative to this approach is immediate definitive surgical intervention and reconstruction at the first operation [11-17]. The presence of concomitant injuries of the body, fear of postoperative infection, unavailability of surgical hardware and lack of surgical experience in the treatment of penetrating ballistic injuries are among the factors that had created supporters for delayed treatment [2]. The use of external fixators have been recommended by some [4]; but in our unit we find them to be bulky and uncomfortable. They also add additional scars to the already damaged face. Our study shows that ballistic jaw fractures can often be reduced, immobilized, and fixed in occlusion at the time of the first operation along with primary closure and internal fixation with less trauma (provided that soft tissue coverage is feasible and MMF is used). If reconstruction plates are used MMF may be omitted [16,18].

6.1. Rationale for primary comprehensive management of hard and soft tissues at the time of the first operation

In our unit, we aim to restore bone continuity primarily (especially in the mandible). Because, if integrity of the jaw is restored, subsequent operations are facilitated for both the patient and

surgeon and because MMF will not be needed again in subsequent operations. Additionally, when intervention is delayed, a myriad of problems set in:

- Fibrosis occurs around bone segments and makes locating and mobilizing them difficult or predisposes them to necrosis.
- Bone edges round-off (we cannot fix the puzzle) and will require refreshening upon reconstruction (for bone graft take).
- Restoration of pre-injury form and function in jaws without continuity is more difficult in delayed patients as the remaining segments often become displaced due to muscle pull (i.e., medial and superior rotational displacement of the mandibular ramus and posterior-inferior displacement of the chin). This makes reduction extremely difficult due to fibrosis and contracture.
- Release of this fibrotic tissue is necessary to reduce fracture segments; this requires stripping the tissues off the bone segments thus devitalizing them.

Often in high velocity facial injuries, the hard tissues are found to be scattered and displaced rather than avulsed. Locating and securing them in place is better than aggressive debridement to remove them in fear of sequestration and infection. Because, doing so, devitalizes and strips the fragments from their vital attachments. Often tracking the path of the projectile to the fracture facilitates finding segments of fractured bone. The bone segments can then be manipulated and wedged into their proper place after locating them at the very time of wound debridement. The bone although fragmented is fresh at that time and more likely to take. Upon primary intervention, projectiles not within reach via the wound bed are disregarded as exploration for these foreign bodies is often unnecessary and may be detrimental for the patient [2,16]. Arch bars, titanium miniplates or wire osteosynthesis were applied when necessary following open reduction along with MMF [Table 1]. All fractures do not require internal fixation however. Arch bar placement and restoration of occlusion following open reduction followed by MMF is sometimes adequate [2]. This is often possible when fractured bone segments contain teeth. Sali Bukhari recently reported on facial gunshot wounds. He found facial gunshot wounds to frequently involve the mandible and reiterated that early management of gunshot wounds not only results in better esthetics, reduced hospital stay and early return to function, but also to a better psychosocial profile preventing depression; when the patient has to tolerate the mutilated face and defective jaw for several days or longer until definitive treatment is rendered he no doubt suffers. The latter is an important issue of concern often overlooked and not addressed in most studies [18].

6.2. Overview of consequences inherent to delayed management

Inherent consequences of delayed management inlude:

- Loss of loose or extruded teeth (which cannot be placed back into the alveolus after delay of several days or more and may not take).
- Problems in restoring occlusion

http://dx.doi.org/10.5772/53119

- Difficulty in fracture reduction due to callus formation
- Displacement of bone segments due to contracture and muscle pull
- Excessive granulation tissue formation and fibrosis of wounds
- Problems in eating due to untreated wound
- Anxiety due to deformity, anticipation of treatment and uncertainty
- Scarring and less esthetic outcome
- Increased cost and length of hospital stay
- An additional major operation

6.3. Hard tissue management

Vayvada *et al*. treated 15 patients with high-energy bullet wounds. The conventional approach with delayed reconstruction was done for 10 patients and immediate definitive surgical reconstruction for 5 patients. They stated that immediate reconstruction eliminated the disadvantages of the conventional method such as high infection rate, high scarring rate and deformities resulting from contraction of tissues (similar to our findings)[13]. In our series, 22% of our patients required tracheotomies. This compared well with that found by Hollier *et al*., where 21% of all facial fractures required a tracheostomy [9]. In all cases, in our series arch bars were placed with MMF prior to bone reduction to ensure proper occlusion. MMF postoperatively prevents chronic osteomyelitis or nonunion *via* preventing movement of segments. The application of arch bars for gunshot injuries of the jaws is the mainstay of treatment to re-establish arch form, occlusion and dentoalveolar stability.

6.4. Soft tissue management

Local undermining and the use of regional soft-tissue advancement rotation flaps for primary closure of maxillofacial soft tissue defects during the first operation has proved beneficial from both an esthetic and functional point of view [2,11,13,19]. Leaving defects open results in extensive scarring of the facial tissues and complicates subsequent surgical procedures, and should be avoided even in contaminated penetrating wounds [2,11,13,16,19]. In such situations, debridement and loose closure of the tissues transferred locally followed by administration of antibiotics may be a better alternative [2,11,13,14].

6.5. Antibiotics

Antibiotic therapy plays a major role in the prevention of infection of both hard and soft-tissues; early and appropriate surgical debridement, copious irrigation, fixation and immobilization of injured tissues, detailed wound closure, drainage, maintenance of clean dressings, nutrition, tetanus prophylaxis, and restoration of circulating fluid volume are equally important in ballistic injuries [2,11,13,16,19]. Soft tissue healing is usually favorable in patients with penetrating facial injuries; however, postoperative discharge from the suture sites may be seen.

This usually resolves within several weeks after daily irrigation with dilute povidone iodine or hydrogen peroxide solutions. Form and function of the soft tissue reconstructed regions recover usually within a year postoperatively. The esthetic results that can be obtained are generally acceptable to patients [2,11,13,14].

6.6. General health

The general health status of the wounded patient is important. The hemodynamic of the patient must be addressed early on as the oxygen carrying capacity is influential in both wound healing and prevention of infection in injured victims who have suffered extensive blood loss. This issue may warrant delayed intervention especially in the light of more serious concomitant injuries [2,7,11,14].

6.7. Mental health

The emotional conditions of patients with facial ballistic injuries have been evaluated and major depression signs have been reported. Functional evaluation has shown a significant correlation between facial appearance after reconstruction and social activity level [16-18]. Thus, the sooner the surgical treatment is rendered the sooner the psychological recovery.

6.8. Revisions

Revisions and secondary operations are often necessary and were performed in 36% of our patients following the first operation. Revisions are usually needed to remove scars, etc. near the eyes, the alar base of the nose, oral commissures and the vermilion border of the lips. Many of these and other operations including masticatory rehabilitation and restoration of occlusion with osseointegrated implants can be done later under local anesthesia and sedation on an outpatient basis [14,16,20].

7. Summary

The resultant injury from ballistic wounds are diverse because of the variability of the projectile, its motion, velocity, and the characteristics of the tissues involved. When a high-velocity projectile strikes the jaw, often the wound will consist of a severely comminuted mandible surrounded by damaged soft tissues and implanted multiple foreign bodies. This presents a challenge for the treating surgeon. The anatomy and function of the jaw is such that the care of the gunshot wound requires a combination of trauma surgery and reconstructive surgeries. There are varying techniques advocated for the management of ballistic wounds to the face. However, for the comminuted fracture sustained from a ballistic wound, an approach involving intermaxillary fixation, wound debridement and immediate management using a comprehensive approach that can restore function and esthetics. This approach to the comminuted jaw has led to the effective management provided communition is not extensive. The complication rate is comparable with the current

http://dx.doi.org/10.5772/53119

literature and provides many advantages mainly a 1-stage major operation to restore appropriate function and cosmesis to the patient. [12,14,16].

7.1. Surgical Intervention in ballistic injuries

Ballistic wounds are associated with a high incidence of maxillofacial injuries requiring surgical intervention. Many may be treated acutely and definitively with procedures designed to repair both the hard and soft tissue injuries simultaneously to restore bony continuity (especially in the mandible), restoration of esthetics and function using the tissues within or adjacent to the wound. This is advocated because if continuity of the mandible can be obtained subsequent operations will not need maxillomandibular fixation again. Additionally, the course of healing is not disrupted with another subsequent operation (in the same wound) and because it may decrease hospital stay without increasing patient morbidity in patients selected for this intervention. Moreover, residual defects can be treated later as out-patient procedures.

7.1.1. Soft-tissue reconstruction

Soft-tissue reconstruction of facial defects and deformities following ballistic injury is not always an easy or straightforward procedure. The limited availability of adjacent skin, the complex function, contours, texture and intricate innervation of the face, especially in the area of the eyes and the lips, along with the many facial esthetic subunits make the goals of restoring function and esthetics challenging and often difficult to achieve [21]. Local flaps utilize tissue that abuts the defect requiring coverage. These flaps are used to cover skin defects in areas without enough tissue laxity to afford primary closure. The donor site for a local flap ideally should have enough laxity to allow primary repair in addition to providing tissue to the recipient site for coverage of the defect.

In victims of ballistic injuries, the difficulty in application of standard soft-tissue transfer techniques to treat facial defects, is compounded by devastation resulting from high-velocity projectiles in a patient with often multiple, concomitant injuries. Thus, reconstruction is more problematic because of extensive tissue mutilation, edema, compromised blood supply and the involvement of the underlying hard-tissues compounded by the contaminated nature of ballistic wounds [19,22]. Despite these facts, attempting simple closure may often prove adequate to treat the resultant defect or deformity (Figure 3).

However, in complicated cases with extensive tissue loss we face more dilemmas [2,19]. Appreciation of basic flap techniques, as well as applicable modifications and combinations of different flaps can prove invaluable to the maxillofacial surgeon confronted by ballistic injuries, allowing for a more acceptable cosmetic and functional result. In this section we present the application of several useful local flap combinations used to reconstruct various-sized, full-thickness facial defects and deformities in patients with ballistic injuries and discuss applications of local flaps in several facial subunits.

Figure 3. (A) View of the patient on admission, depicting extensive hard and soft tissue destruction by the exiting projectile (B) Immediate postoperative photograph. (C) Twelve months after bone grafting the mandible with iliac bone chips in titanium mesh and ridge augmentation. (D)Facial form and function has been restored.

7.1.2. Soft-tissue procedures

The soft-tissue procedures used were basically local-advancement or rotation-advancement flaps, used in conjunction with pedicled fat or subcutaneous supporting flaps, nasolabial, cheek, cervical, Dieffenbach and Abbe-type flaps. Scar revision, tissue repositioning, and lengthening procedures, such as W, V-Y, Z, or multiple Z-plasty techniques were used both primarily and secondarily depending on the individual case.

Thirty-three patients suffering ballistic injuries were treated at our department from 1986 to 2012. There were 32 males and 1 female patient, aged between 8 and 53 years, with an average age of 24.18 years. Bullets were the most common cause(70%), followed by shrapnel (21%), land mines (6%), and one breech block injury (3%). All patients included in this study had full thickness soft-tissue defects and were seen l-3 days after the initial injury. The soft-tissue

http://dx.doi.org/10.5772/53119

injuries involved the anatomical facial subunits (orbital, infraorbital, buccal,zygomatic, labial, mental and parotidomasseteric). At the operation, after hard tissues were addressed the soft-tissue injuries were treated by debridement and primary closure by combining, modifying, and tailoring standard local flap techniques to fit the location of the injury and compensate for the tissue loss.

The operations were classified regionally: the perioral region was involved in 15 cases (45%), the midface and cheeks were involved in 13 cases (39%), and the periorbital area was involved in 5 cases (15%). Local advancement flaps were applied initially for the majority of the patients (48%) followed by Z-plasty (39%) listed in Table 3.

Soft Tissue Procedure	Number
Cutaneous local advancement flaps	18
Cervicofacial advancement flaps	4
Zygomaticofacial advancement flaps	2
Preauricular advancement flap	1
Columellar reconstruction	1
Tissue rearrangement	8
Mucosal finger flaps	2
Double Abbe flap	1
Commissuroplasty	5
Pedicled fat flap	1
Supporting flaps	5
Dieffenbach flap	1
Nasolabial flaps	4
Perialar flap	1
Skin graft	1
Abbe flap	1
Z-plasty	13
V-Y-plasty	3
W-plasty	1
Palatal flap	1
Direct lip repair	1
Strip graft	1

Table 3. List of basic soft-tissue procedures used to treat maxillofacial ballistic soft-tissue injuries. Cutaneous local advancement flaps followed by Z-plasty procedures were most commonly used.

7.1.2.1. Perioral reconstruction

Three basic factors were considered prior to perioral reconstruction: (1) utilization of the remaining portions of the injured lips if possible; (2) using the opposite lip as the next resort when there was inadequate tissue for repair; and (3) use of local flaps from the sides of the defect.

- When as much as one-quarter of the lip was missing, direct linear closure, Z-plasty, or double Z-plasty (to prevent notching of the vermilion) was done. Larger defects of the lips and perioral regions were treated using flaps.
- When reconstruction with flaps was contemplated, several options were considered depending on the lip involved and amount of tissue loss:

Lateral defects of the lips

For lateral defects of up to one-third of the upper or lower lip, treatment usually utilized nasolabial flaps, a lateral flap combined with vermilion advancement (Figure 4), or the Abbe Estlander flap.

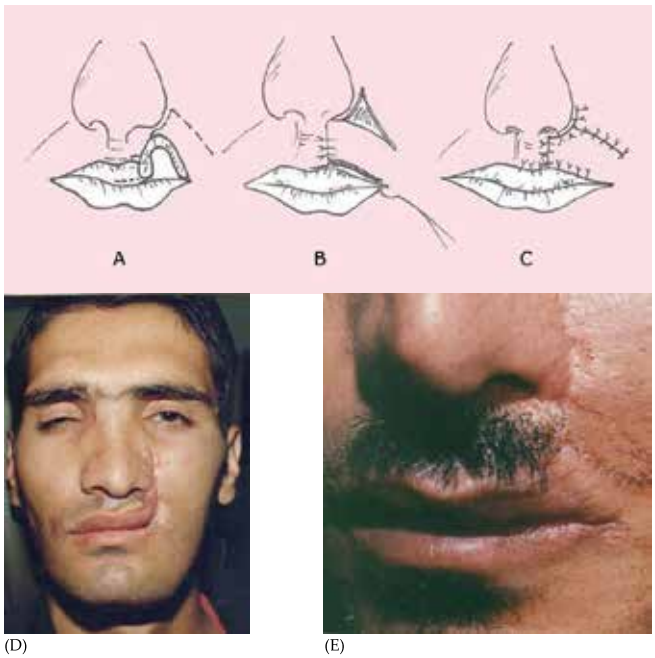

Figure 4. (A) Lateral defect of the upper lip with a nasolabial flap outlined for repair, (B) The nasolabial flap is transposed and the vermilion border of the upper lip is advanced laterally to the corner of the mouth. (C) Closure leaving inconspicuous scars in the philtrum, nasolabial, and alar fold. (D) A patient with a lateral upper lip defect resulting from a bullet. (E) View after treatment with a modified nasolabial flap and commisuroplasty. The maxillomandibular fractures were treated earlier.

We used a modified Abbe technique whenever possible, to preclude the need for a subsequent commisuroplasty (Figure 5).

Midline defects of the lips

For midline defects of the upper lip, treatment by direct advancement of the remaining portions of the lip with perialar excisions or an Abbe flap, taken from the midline of the lower lip and rotated 180 °, was used.

http://dx.doi.org/10.5772/53119

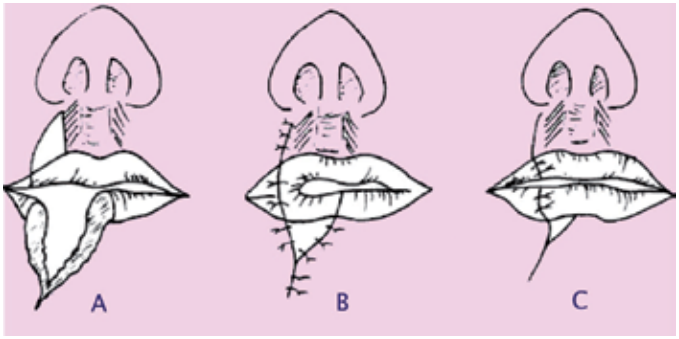

Figure 5. (A) Outline of the modified Abbe flap to repair a moderate-sized defect of the lower lip. (B) A triangular section of the upper lip is rotated to repair the lower lip defect. (C) The pedicle is sectioned two weeks later (note the commissures are spared).

Lower lip defects

Small-to-moderate sized defects of the lower lip were treated similarly. Lateral rotation or Abbe flaps, Z or V-Y plasties, were used (Figure 6).

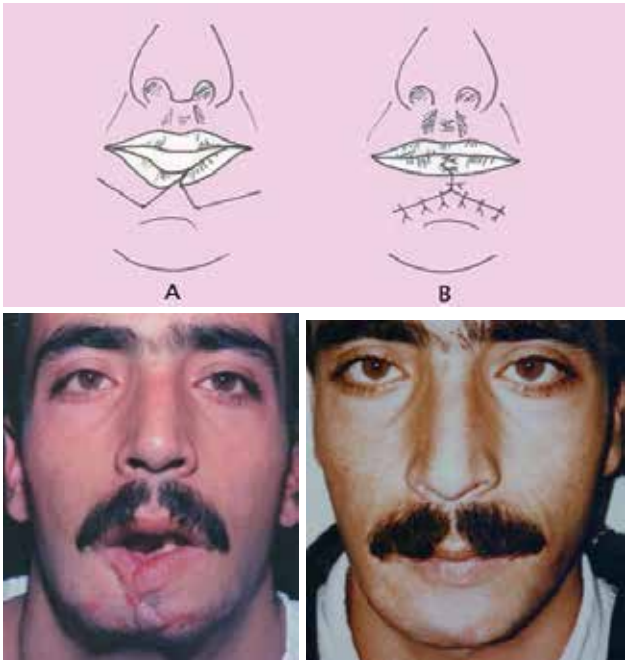

Figure 6. (A) Medial defect of the lower lip causing unsightly retraction. (B) Correction by lateral advancement flaps and V-Y plasty. (C) A patient with a gunshot wound defect of the chin, lower lip, and labiomental fold. (D) View of the patient after treatment of maxillomandibular fractures, iliac bone grafting, advancement flaps, V-Y, and Z-plasties.

In cases of complete loss of the lower lip and labiomental soft tissues, we combined bilateral Dieffenbach flaps with double Abbe flaps of the upper lip, and a cervical advancement flap, which proved relatively functional and effective in restoring lip competence and lip seal (Figure 7).

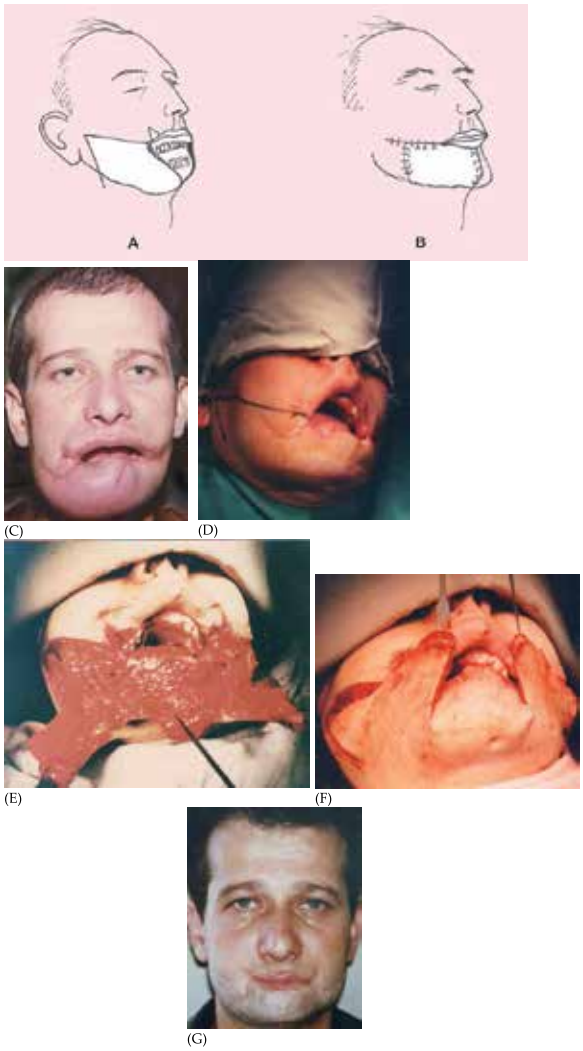

Figure 7. (A) Total defect of the lower lip and mentolabial tissues. (B) Treatment by Dieffenbach flaps, advancement of the full-thickness bilateral cheek flaps, and double Abbe flaps. (C) A similar defect in a gunshot patient with previously reconstructed hard tissues and soft tissue closure. The total loss of the lower lip and mentolabial tissues caused constant, intolerable, salivary drooling. The mandible was reconstructed primarily by fixing the fragmented bone segments to a reconstruction plate in the first operation,(same patient whose radiographs are shown in Figure 1). (D) Outline of the Dieffenbach flap used to reconstruct the lower lip. (E) Flap mobilization with double Abbe flaps outlined. (F) Flaps made passive for advancement. (G) 6-month postoperative photograph of the patient, showing restoration of lip competence.

http://dx.doi.org/10.5772/53119

Superficial deformities of the lips

Superficial deformities or residual defects which often occur with contraction of linear scars can distort the contour of the lip vermilion or cause notching. These were effectively treated by scar excision, re-creation of the defect, tissue rearrangement combined with supporting flaps, and Z- or V-Y plasty procedures, which proved useful when tissue lengthening was required (Figure 8).

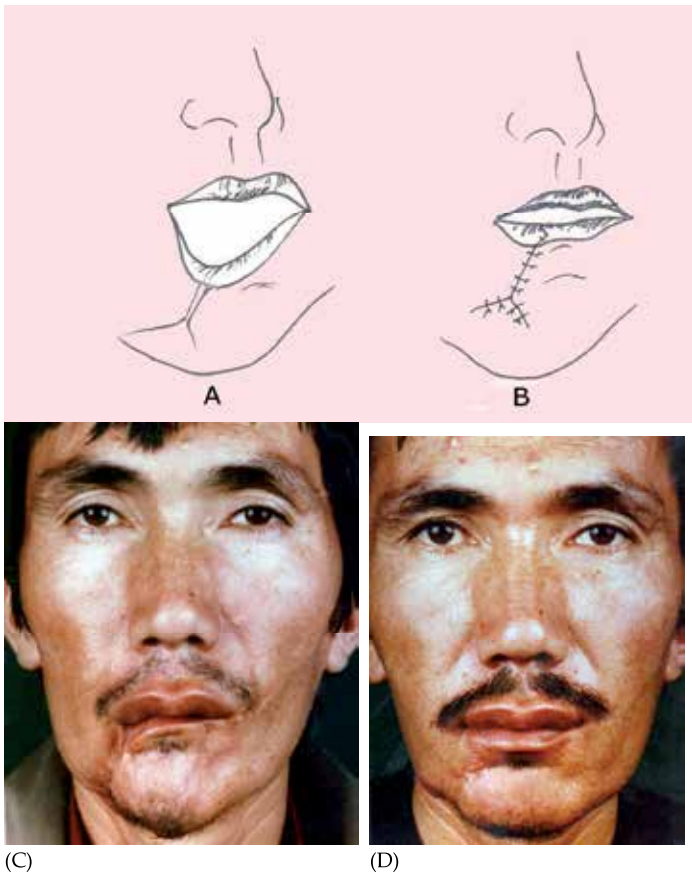

Figure 8. (A) Scarring and distortion of a lower lip defect. (B) Correction by scar excision, recreation of the defect, full-thickness lateral flap advancement, and V-Y and Z-plasty. (C) Gunshot patient with a similar contracture deformity. (D) After treatment. The right hemimandible was reconstructed using iliac bone marrow graft in a titanium mesh tray prior to this procedure.

7.1.2.2. Midface and cheek reconstruction

For reconstruction in cases with defects of the cheeks, zygomatic, and midfacial areas, the lateral cheek advancement or rotation flap was used. Transfer of tissue was based on the laxity found in the preauricular tissues, the lower face, and the neck. The larger the defect, the more

extensive the flap preparation. The deep surface of the flap was anchored to the soft tissue, and sometimes included the periosteum over the malar area, to help prevent traction on the eyelid (Figure 9).

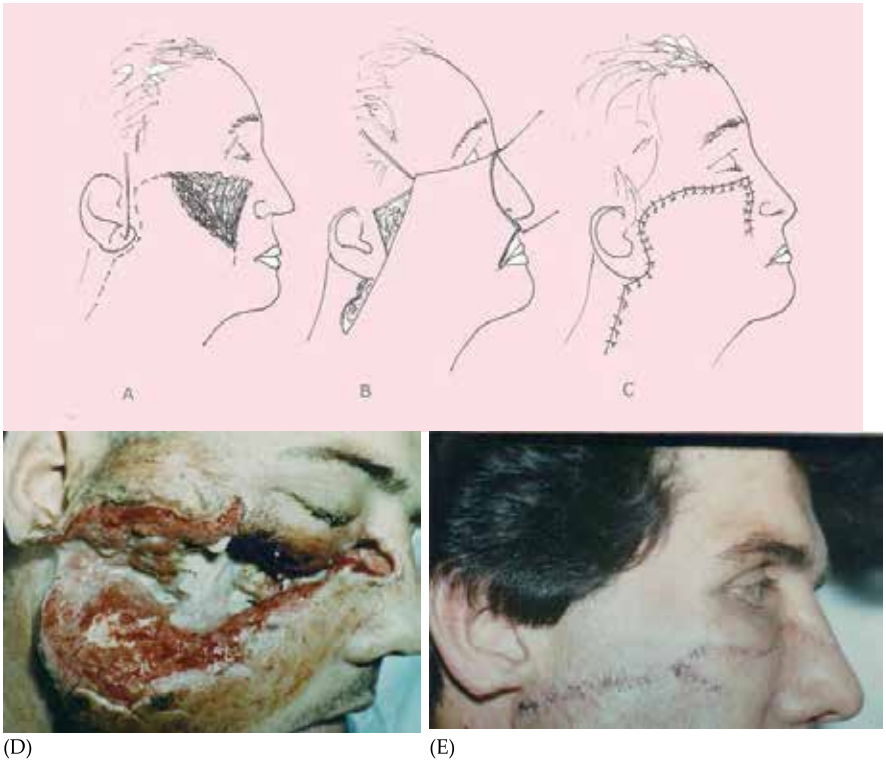

Figure 9. (A) Outline of a cervicofacial cheek flap for an avulsion defect. (B) Flap mobilization. (C) Reconstruction. (D) A patient with an extensive, deep avulsion defect of the right cheek and zygomatic area due to a high-velocity shrapnel. (E) View of the patient l week after the second surgical stage, note the previous scars of the cervicofacial-zygomatico-facial cheek advancement flap and primary closure in the preauricular area are still slightly visible.

This procedure was sometimes combined with a superiorly based nasolabial flap when ectropion was eminent. Smaller defects of the cheeks were treated with local undermining combined with Z-plasties and pedicled fat or subcutaneous supporting flaps to fill the defects and restore the natural prominence of the cheek.

7.1.2.3. Periorbital reconstruction

Reconstruction of defects of the lower eyelid or upper cheek basically employed the versatile nasolabial flap. For defects of this area, the pedicle of this flap was based superiorly, on the angular artery and rotated 90 ° to close the defect. The tip of the flap was anchored at the corner under the eyelid giving added support to the lower eyelid. This flap was also used to treat lower lid ectropion (Figure 10).

http://dx.doi.org/10.5772/53119

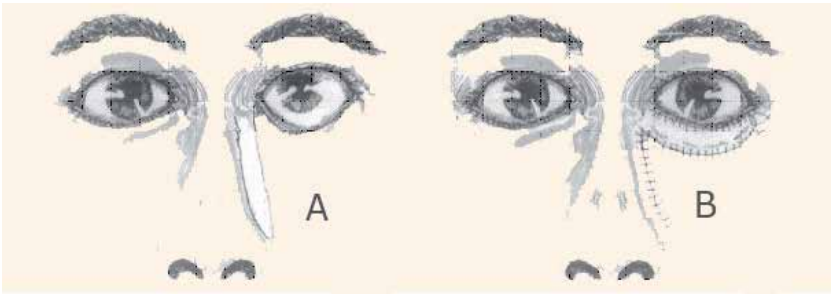

Figure 10. (A) Outline of a nasolabial flap for treatment of lower lid sagging and ectropion. (B) Reconstruction.

7.1.3. Hard-tissue injuries

Hard tissues were usually treated primarily along with closure of the soft-tissue injuries (76%). These procedures varied from debridement only (16%),primary debridement, closed reduction, and fixation (45%), primary debridement, open reduction and wire osteosynthesis (12%), or via primary debridement, open reduction and plate osteosynthesis (3%). When soft-tissue loss precluded primary treatment of hard tissues, or when grafts were needed, these were done secondarily (24%). Secondary graft procedures involved: block grafts (12%), block grafts secured to a reconstruction plate (3%), and cortiocancellous iliac bone placed into titanium mesh trays (9%). All grafts were harvested from the anterior iliac crest and placed transcutaneously.There were no bone graft failures.

7.1.4. Clinical course

Initial healing of the flaps was uncomplicated in 76% of the patients. However, postoperative discharge from the suture sites was seen in 24% of the patients. This usually resolved within several weeks using daily irrigation and cleansing of the discharge site. None of the soft-tissue flaps sloughed or developed necrosis. Form and function of the regions reconstructed with soft-tissue usually recovered within one year postoperatively. The esthetic results obtained were acceptable in our cases. None required facial nerve grafting, as only the terminal nerve endings were injured in our cases and functional recovery was good.

8. Discussion

8.1. Timing treatment

Ballistic injuries to the face can have minor or often, devastating consequences. The timing, sequence, and appropriate application of surgical procedures and techniques used for reconstruction and rehabilitation of these injuries, have proved to be influential to the final outcome and esthetic result [19]. The staged sequence of treatment dictating the timing of both hard and soft-tissue treatment are dependent to a large extent on surgical judgment and the

general condition of the patient. The selection of the appropriate surgical technique as well as the timing of surgery is important to prevent infection, wound dehiscence, graft rejection, facial deformity and subsequent revisional operations. Complications prolong hospital stay, postoperative morbidity and increase treatment costs.

8.2. Basic surgical stages

Surgical management of maxillofacial ballistic wounds has generally been divided into three stages [19,23,24]:

1. Debridement, fracture stabilization, and primary closure
2. Reconstruction of hard-tissues, provided that the soft-tissue coverage is adequate (Figure 11).
3. Rehabilitation of the oral vestibule, alveolar ridge, and secondary correction of residual deformities.

(A) (B)

Figure 11. (A) Patient suffering a bullet wound to the face. Note small entry wound below the chin and large exit wound through the face. The patients wounds had been closed and a tracheostomy had been performed prior to transfer. The mandible, maxilla, zygoma and nasal bone were fractured. The wound was re-opened, debrided, arch bars were placed and open reduction was done; then the wound was closed. (B) Patient 6 months postoperatively. No other subsequent surgical treatment was necessary.

Often, stages one and two can be done in the first operation [2,7,19]. Early definitive and comprehensive treatment of the facial injury is the mainstay of treatment when indicated. This results in lower morbidity and better results [2,7,19,23-29]. Local undermining and use of regional soft-tissue advancement rotation flaps for primary closure of maxillofacial soft-tissue defects from projectile injuries have proved beneficial from an esthetic and functional point of view [19]. Leaving defects open results in extensive scarring of the facial tissues complicating subsequent surgical procedures and should be avoided [23,24]. Debridement, cleansing and loose closure of locally transferred tissue is a better alternative. Surprisingly, despite the

contaminated nature of ballistic injuries of the face, entry and exit wounds of the soft-tissues can be closed primarily following careful debridement and extensive irrigation [19,23,24]. Owing to the excellent facial blood supply, primary closure of facial ballistic wounds is the treatment of choice when indications are met [19,23-25]. Underlying compound facial fractures(without extensive comminution) can be reduced, immobilized and fixed in occlusion at the time of primary closure provided that soft tissue coverage is adequate and soft tissue attachments to the bone are preserved [16,19]. In selected patients without severe comminution or infection, osteosynthesis of all free and attached bone fragments using plates in accordance with AO-ASIF can be performed concomitantly with debridement and primary closure. In such cases it is wise to preserve periosteal blood supply and muscle attachments to the attached bony fragments during reduction and fixation. Antibiotic therapy also plays a major role in the prevention of infection of both hard and soft-tissues after primary closure; early and appropriate surgical debridement, copious irrigation, fixation and immobilization of injured hard tissues, detailed wound closure, drainage, and maintenance of clean dressings, nutrition, and circulating fluid volume are equally important [16,19,23]. The hemodynamics of the patient require correction to optimize oxygen carrying capacity influential in wound healing and prevention of infection in victims who have suffered extensive blood loss [14,16,19,23,24].

8.3. Revisions

In the next stage when facial soft-tissue injuries are treated electively, previous scars should be excised. In order to treat residual defects, the basic surgical strategy should be to try and rearrange the scars to lie in the natural skin folds (Figure 12).

Such revisions and secondary operations are often necessary and were undertaken in 48% of our patients. This involves operations directed towards rehabilitation and re-establishment of a more normal facial appearance and function which include minor cosmetic procedures and scar revisions. Those most commonly indicated are periorbital, around the alar base, the oral commissures and the vermilion border of the lips. Symmetry in these areas is essential. Many of these operations may be performed under local anesthesia and sedation on outpatients. Masticatory rehabilitation and restoration of occlusion is facilitated with osseointegrated implants. The main problem encountered by the surgeon treating facial soft-tissue injuries in victims remains the lack of adequate suitable tissue to close or reconstruct the defects. In the face, muscle function of the reconstructed facial soft tissues, especially in the lips and perioral regions require composite skin-muscle-mucosal flaps, which become reinnervated and show a high degree of functional recovery yielding acceptable results [15-17,21,26].

8.4. Basic flap principles

8.4.1. Patterns

Most local flaps are random pattern flaps with no specific named vascular supply. Examples include rhomboid flaps, V-Y flaps, bilobed flaps and Z-plasty.The length to width ratio of a local flap is very important, and should be approximately 1:1 in most cases to ensure adequate vascular supply to the flap. This ratio is somewhat variable depending on the underlying

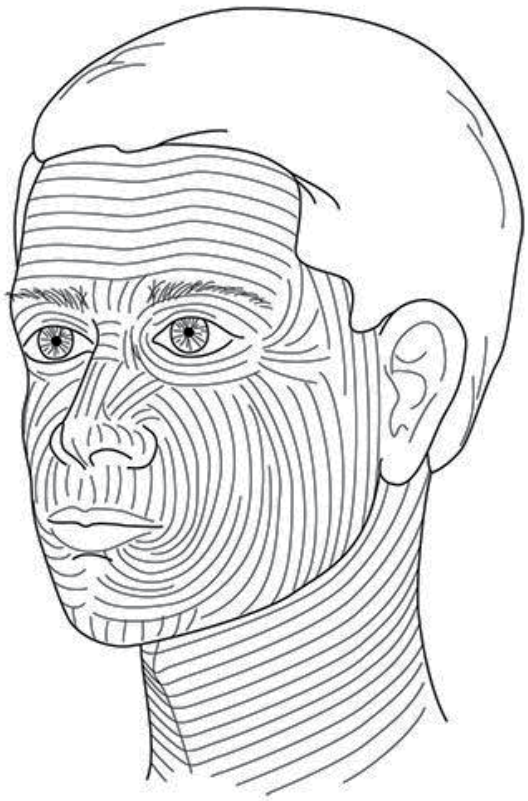

Figure 12. Langer's lines of the face.

vascularity. For example, flaps in highly vascular areas such as the face can be longer with a narrower base, while a poorly vascularized area such as the lower extremity requires that flap length be equal to flap width. Closure of the donor site for a local flap is usually done in two layers: a layer of absorbable deep dermal fine sutures followed by skin closure with intradermal absorbable or transcutaneous monofilament suture. If the sutures are tied too tightly or left in too long, suture marks will be visible, decreasing the esthetic result. When utilized on the face, sutures should be removed in three to seven days. Local flaps remain erythematous and edematous for many weeks, not taking their final form for three to six months or more, thus any revisional operations should wait [27,28].

8.4.2. Defect size assessment

Assessment of defect size is important in planning reconstruction especially in the area of the lips. However, in many cases, assessment of the exact size of the defect can only be done after debridement, approximation of the wound edges and muscles, and when the remaining tissues have been brought into proper position. In patients with scarring, such scar tissue must first

http://dx.doi.org/10.5772/53119

be released. When Abbe flaps are contemplated, it should be noted that the flap pedicle should lie directly opposite the defect. The pedicle is based on the labial artery, located 0.5 cm beneath the mucosal lining of the inner aspect of the lip and must be preserved. In designing this flap; the horizontal dimension of the base of the flap along the vermilion, should be one half of the horizontal defect in the upper lip. In all cases, the vertical dimension of the flap and the defect in the upper lip should be equal. It is advocated that the flap should not exceed 2 cm in width so that the lower (donor) lip does not become too constricted [21,26-28]. Division of the pedicle is usually performed after 2-3 weeks.

A common error when using flaps, is the tendency to inadequately mobilize or extend the flaps. All flaps should be of adequate size to remain in place without tension, otherwise dehiscence, scarring, ectropion or increased scleral show may result. On the whole, we feel that, local flaps in the form of lateral flaps, cheek flaps, nasolabial flaps, rotation advancement flaps alone or in combination with Abbe flaps, tissue rearrangement procedures, supporting flaps, or lengthening procedures such as V-Y or Z plasties, are easier to undertake and have less morbidity for the injured patient when compared with distant flaps.

8.4.3. Benefits of the rhomboid flap

The rhomboid flap is versatile and can be used to cover the bullet entry wound (Figure 13).

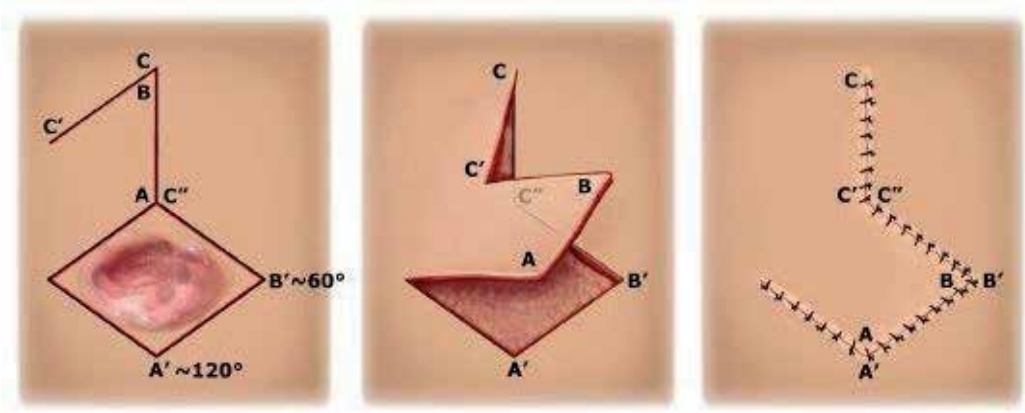

Figure 13. The rhomboid flap can be used to cover the bullet entry wound.

8.4.4. Benefits of Z-plasty

The primary reasons to perform a Z-plasty are to improve contour, release scar contracture, relieve skin tension, and mobilize tissue for reconstructive surgery.

Z-plasty has several main tissue effects:

- Redirection of scar - The new scar reorients from the axis of the central limb to a line connecting the tips of the lateral limbs. Z-plasty is used to redirect the scar into "relaxed skin

tension lines" (ie, Langer's lines Figure 12), natural skin folds, or along the border of an esthetic unit (ie, nasolabial fold) to improve cosmetic or functional outcome.

- Lengthening of the scar - Z-plasty lengthens the initial wound or scar. It is used to release contractures and redirect scars (Figure 14).

(A) (B)

Figure 14. (A) Patient suffering a bullet wound to the left zygoma, maxilla and palate. Treated via dermal flaps and Z-plasty. (B)Patient months postoperatively. The Caldwell procedure plus antrostomy was done simultaneously with the soft tissue repair.

The amount of lengthening is related to the angle between the central and lateral limbs. Larger angles produce the most lengthening, but can be difficult to close because of skin tension. Narrow angles (<45°) are easier to close, but produce minimal lengthening and have a higher risk of flap necrosis due to their precarious blood supply.

Central/lateral limb angle	30º	45º	60º	75º	90º
Theoretical gain in length	25%	50%	75%	100%	120%

The 60 degree Z-plasty (ie, classic Z-plasty) is most commonly used because it provides the optimal balance between lengthening and ease of closure.

- Tissue mobilization - Z-plasty mobilizes adjacent tissue to close skin defects that might otherwise have required a skin graft.

8.4.5. Free flaps

Distant or free flaps are not contraindicated and definitely have their place in the treatment and reconstruction of facial defects, and we have used them effectively in many patients. However, we prefer to consider them secondarily or as a final resort, preserving them for failed

patients or patients requiring extensive reconstruction of both hard and soft tissues of the face not amenable to local flaps, or for patients with scarred, or ischemic tissues unsuitable for the application of local flaps.

Application of local tissue transfer procedures yield acceptable tissue form, texture, and color match, especially when these procedures are used in combination, and tailored to fit the individual defect moreover, application of these procedures is relatively easy and postoperative morbidity is limited, provided the general condition of the patient is stable, the surgical techniques used have good indications and general flap principles (blood supply, length, size, adequate pedicle and mobilization etc.) have been applied. Form and function of the soft-tissue reconstructed regions usually recover within one year postoperatively. The esthetic results obtained are usually favourable. If the terminal branches of the facial nerve are injured they usually recover (in our cases functional recovery was good).

Author details

Mohammad Hosein Kalantar Motamedi[1], Seyed Hossein Mortazavi[2], Hossein Behnia[2], Masoud Yaghmaei[2], Abbas Khodayari[3], Fahimeh Akhlaghi[3], Mohammad Ghasem Shams[3] and Rashid Zargar Marandi[4]

1 Professor of Oral and Maxillofacial Surgery, Trauma Research Center, Baqiyatallah University of Medical Sciences, and Attending Surgeon, Azad University of Medical Sciences, Tehran, Iran

2 Professor of Oral and Maxillofacial Surgery, Department of Oral and Maxillofacial Surgery, Taleghani Medical Center, Shahid Beheshti University of Medical Sciences, Tehran, Iran

3 Associate Professor of Oral and Maxillofacial Surgery, Department of Oral and Maxillofacial Surgery, Taleghani Medical Center, Shahid Beheshti University of Medical Sciences, Tehran, Iran

4 Neurosurgeon, Department of Neurosurgery, Baqiyatallah University of Medical Sciences. Tehran, Iran

References

[1] Weider, L, Hughes, K, Ciarochi, J, & Dunn, E. Early versus delayed repair of facial fractures in the multiply injured patient. Am Surg (1999). , 65, 790-7.

[2] Motamedi, M. H. Primary treatment of penetrating injuries to the face. J Oral Maxillofac Surg (2007). , 65, 1215-8.

[3] Glapa, M, Kourie, J. F, Doll, D, & Degiannis, E. Early management of gunshot injuries to the face in civilian practice. World J Surg (2007). , 31, 2104-10.

[4] Kincaid, B, & Schmitz, J. P. Tissue injury and healing. Oral Maxillofac Surg Clin North Am (2005). , 17, 241-50.

[5] Ueeck, B. A. Penetrating injuries to the face: Delayed versus primary treatment-considerations for delayed treatment. J Oral Maxillofac Surg (2007). , 65, 1209-14.

[6] Shvyrkov, M. B. Primary surgical treatment of gunshot wounds of facial skeleton. Stomatologiia (Mosk) (2001). , 80, 36-40.

[7] Motamedi, M. H. Primary management of maxillofacial hard and soft tissue gunshot and shrapnel injuries.J Oral Maxillofac Surg. (2003). Dec;, 61(12), 1390-8.

[8] Mclean, J. N, Moore, C. E, & Yellin, S. A. Gunshot wounds to the face-acute management. Facial Plast Surg (2005). , 21, 191-8.

[9] Hollier, L, Grantcharova, E. P, & Kattash, M. Facial gunshot wounds: A 4-year experience. J Oral Maxillofac Surg (2001). , 59, 277-83.

[10] Baig, M. A. Current trends in the management of maxillofacial trauma. Ann R Australas Coll Dent Surg (2002). , 16, 123-7.

[11] Lieblich, S. E, & Topazian, R. G. Infection in the patient with maxillofacial trauma. In: Fonseca RJ, Walker RV, editors. Oral and maxillofacial trauma.Philadelphia: Saunders; (1991). , 1157-1159.

[12] Peleg, M, & Sawatari, Y. Management of gunshot wounds to the mandible.J Craniofac Surg. (2010). Jul;, 21(4), 1252-6.

[13] Vayvada, H, Menderes, A, Yilmaz, M, Mola, F, Kzlkaya, A, & Atabey, A. Management of close-range, high-energy shotgun and rifle wounds to the face. J Craniofac Surg (2005). , 16, 794-804.

[14] Motamedi, M. H, & Behnia, H. Experience with regional flaps in the comprehensive treatment of maxillofacial soft-tissue injuries in warfare victims. J Craniomaxillofac Surg (1999). , 27, 256-9.

[15] Motamedi, M. H, Khatami, S. M, & Tarighi, P. Assessment of severity, causes, and outcomes of hospitalized trauma patients at a major trauma center.J Trauma. (2009). Feb;, 66(2), 516-8.

[16] Motamedi, M. H. Management of firearm injuries to the facial skeleton: Outcomes from early primary intervention. J Emerg Trauma Shock (2011). , 4, 212-6.

[17] Motamedi, M. H, Sagafinia, M, & Famouri-hosseinizadeh, M. Oral and maxillofacial injuries in civilians during training at military garrisons: prevalence and causes.Oral Surg Oral Med Oral Pathol Oral Radiol Endod. (2012). jul:114(1):49-51

[18] Sali Bukhari SG Khan I, Pasha B, Ahmad W. Management of facial gunshot wounds. J Coll Physicians Surg Pak (2010). , 20, 382-5.

[19] Behnia, H. Motamedi MHK: Reconstruction and rehabilitation of short-range, high-velocity gunshot injury to the lower face. J Cranio Maxillofac Surg (1997). , 25, 220-4.

[20] Motamedi, M. H, Hashemi, H. M, Shams, M. G, & Nejad, A. N. Rehabilitation of war-injured patients with implants: analysis of 442 implants placed during a 6-year period. J Oral Maxillofac Surg. (1999). Aug;discussion 914-5., 57(8), 907-13.

[21] Wei-Yung YIH Howerton DW: A regional approach to reconstruction of the upper lip. J Oral Maxillofac Surg (1997).

[22] Taher AA: Management of weapon injuries to the craniofacial skeletonJ Craniofac Surg 9, 371, (1998).

[23] Osborne, T. E. Bays RA: Pathophysiology and management of gunshot wounds to the face: In: Fonseca R J, Walker RV (eds.):Oral and maxillofacial trauma, Philadelphia: WB Saunders, 672, (1991). , 2

[24] Berlin, R, Gerlin, L. E, Jenson, B, et al. Local effects of assault rifle bullets in live tissues. Acta Chir Scand Suppl (1976).

[25] Shelton DW: Gunshot woundsIn: Peterson LJ, Indresano AT, Marciani RD, Roser SM (eds.): Principles of oral and maxillofacial surgery, Philadelphia: JB Lippincott, 596, (1992). , 1

[26] Converse, J. M. Wood-Smith D: Techniques for the repair of defects of the lips and cheeks: In: Converse JM (ed.): Reconstructive Plastic Surgery, Philadelphia: WB Saunders, (1977). , 3, 1547.

[27] Carray, J. H. Vincent MP: Reconstruction of eyelid deformities: In: Georgiade NG, Georgiade GS, Riefkohl R (eds.): Essentials of plastic, maxillofacial and reconstructive surgery. Baltimore, Maryland: Williams and Wilkins, (1987). , 480.

[28] Jackson IT: Local flaps in head and neck reconstructionSt Louis: CV Mosby, 189, (1985).

[29] Kalantar Motamedi MH Comprehensive Management of Maxillofacial Projectile Injuries at the First Operation; “Picking up the Pieces”. Trauma Mon. (2013). , 17(4), 365-6.

Chapter 20

Cleft Lip and Palate Surgery

Koroush Taheri Talesh and
Mohammad Hosein Kalantar Motamedi

Additional information is available at the end of the chapter

http://dx.doi.org/10.5772/55147

1. Introduction

The treatment of cleft lip and palate deformities requires thoughtful consideration of the anatomic complexities of the deformity and the delicate balance between intervention and growth. Comprehensive and coordinated care from infancy through adolescence is essential in order to achieve an ideal outcome, and surgeons with formal training and experience in all of the phases of care must be actively involved in the planning and treatment. Specific goals of surgical care for children born with cleft lip and palate include the following:

- Normalized esthetics of the lip and nose
- Intact primary and secondary palate
- Normal speech, language, and hearing
- Nasal airway patency
- Class I occlusion with normal masticatory function
- Good dental and periodontal health
- Normal psychosocial development

Successful management of the child born with a cleft lip and palate requires coordinated care provided by a number of different specialties including oral/maxillofacial surgery, otolaryngology, genetics, speech pathology, orthodontics, prosthodontics, and others. In most cases care of patients with congenital clefts has become a subspecialty area of clinical practice within these different professions. In addition to surgery for cleft repair, treatment plans routinely involve multiple treatment interventions to achieve the above-stated goals. Because care is provided over the entire course of the child's development, long-term follow-up is critical

INTECH
open science | open minds

© 2013 Talesh and Motamedi; licensee InTech. This is a paper distributed under the terms of the Creative Commons Attribution License (http://creativecommons.org/licenses/by/3.0), which permits unrestricted use, distribution, and reproduction in any medium, provided the original work is properly cited.

under the care of these different health care providers. The formation of interdisciplinary cleft palate teams has served two key objectives of successful cleft care: [1] coordinated care provided by all of the necessary disciplines, and [2] continuity of care with close interval follow-up of the patient throughout periods of active growth and ongoing stages of reconstruction. The best outcomes are achieved when the team's care is centered on the patient, family, and community rather than a particular surgeon, specialty, or hospital. The idea of having an objective team that does not revolve around the desires of one particular individual or discipline is sometimes impeded by competitive interactions between surgical specialties. Historic battles over surgical domains between surgical specialties and economic factors contribute to these conflicts and negatively affect the work of the team. Healthy team dynamic and optimal patient care are achieved when all members are active participants, when team protocols and referral patterns are equitable and based on the surgeons' formal training and experience instead of specialty identity, and when the needs of the child are placed above the needs of the team. [1-3]

2. Prevalence and classification

The occurrence of oral clefts in the United States has been estimated as 1 in 700 births.' Clefts exhibit interesting racial predilections, occurring less frequently in blacks but more so in Asians. Boys are affected by orofacial clefts more often than girls, by a ratio of 3:2. Cleft lip and palate (together) occurs about twice as often in boys as in girls, whereas isolated clefts of the palate (without cleft lip) occur slightly more often in girls. Oral clefts commonly affect the lip, alveolar ridge, and hard and soft palates. Three fourths are unilateral deformities; one fourth are bilateral. The left side is involved more frequently than the right when the defect is unilateral. The cleft may be incomplete, that is, it may not extend the entire distance from lip to soft palate. cleft palate may occur without clefting of the lip. A useful classification divides the anatomy into primary and secondary palates. The primary palate involves those structures anterior to the incisive foramen-the lip and alveolus; the secondary palate consists of those structures posterior to the incisive foramen-the hard and soft palates. Thus an individual may have clefting of the primary palate, the secondary palate, or both.Clefts of the lip may range from a minute notch on the edge of the vermilion border to a wide cleft that extends into the nasal cavity and thus divides the nasal floor. Clefts of the soft palate may also show wide variations from a bifid uvula to a wide inoperable cleft. The bifid uvula is the most minor form of cleft palate, in which only the uvula is clefted. Submucosal clefts of the soft palate are occasionally seen. These clefts are also called occult clefts, because they are not readily seen on cursory examination. The defect in such a cleft is a lack of continuity in the musculature of the soft palate. However, the nasal and oral mucosa is continuous and covers the muscular defect. To diagnose such a defect, the dentist inspects the soft palate while the patient says "ah".This action lifts the soft palate, and in individuals with submucosal palatal clefts, a furrow in the midline is seen where the muscular discontinuity is present. The dentist can also palpate the posterior aspect of the hard palate to detect the absence of the posterior nasal spine, which

http://dx.doi.org/10.5772/55147

is characteristically absent in submucosal clefts. If a patient shows hypernasal speech without an obvious soft palatal cleft, the dentist should suspect a submucosal cleft of the soft palate.[4]

3. Embryology

From an anatomic standpoint the cleft surgeon must have an appreciation forthe failure of embryogenesis that results in clefting. There are critical points in the development of the fetus when the fusion of various prominences creates continuity and form to the lip, nose, and palate. Anomalies occur when the normal developmental process is disturbed between these components. Each of these prominences is made up of ectomesenchyme derived from neural crest tissue of the mesencephalon and rhombencephalon. Mesoderm is also present within these prominences as mesenchymal tissue. The prescribed destiny of each of these cells and tissues is controlled by various genes to alter the migration, development, and apoptosis and form the normal facial tissues of the fetus. At the molecular level there are many interdependent factors such as signal transduction, mechanical stress, and growth factor production that affect the development of these tissues. Currently only portions of this complex interplay of growth, development, and apoptosis are clear. At approximately 6 weeks of human embryologic development the median nasal prominence fuses with the lateral nasal prominences and maxillary prominences to form the base of the nose, nostrils, and upper lip. The confluence of these anterior components becomes the primary palate. When this mechanism fails, clefts of the lips and/or maxilla occur. At approximately 8 weeks the palatal shelves elevate and fuse with the septum to form the intact secondary palate. When one palatal shelf fails to fuse with the other components, then a unilateral cleft of the secondary palate occurs. If both of the palatal shelves fail to fuse with each other and the midline septum, then a bilateral cleft of the palate occurs. Fusion occurs when programmed cell death (apoptosis) occurs at the edges of the palatal shelves. The ectodermal component disintegrates and the mesenchyme fuses to form the intact palate. Soon after this the anterior primary palate fuses with the secondary palate and ossification occurs. At any point, if failure of fusion occurs with any of the above components, a cleft will occur of the primary and/or secondary palates. Clefts may be complete or incomplete based on the degree of this failure of fusion.[5-7]

4. Treatment of cleft lip and palate

The aim of treatment of cleft lip and palate is to correct the cleft and associated problems surgically and thus hide the anomaly so that patients can lead normal lives. This correction involves surgically producing a face that does not attract attention, a vocal apparatus that permits intelligible speech, and a dentition that allows optimal function and esthetics. Operations begin early in life and may continue for several years. In view of the gross distortion of tissues surrounding the cleft, it is amazing that success is ever achieved. However, with modern anesthetic techniques, excellent pediatric care centers, and surgeons who have had a

wealth of experience because of the frequency of the cleft deformity, acceptable results are commonplace.[3]

5. Timing of surgical repair

The timing of the surgical repair has been and remains one of the most debated issues among surgeons, speech pathologists, audiologists, and orthodontists. It is tempting to correct all of the defects as soon as the baby is able to withstand the surgical procedure. The parents of a child born with a facial cleft would certainly desire this mode of treatment, eliminating all of the baby's clefts as early in life as possible. Indeed the cleft lip is usually corrected as early as possible. Most surgeons adhere to the proven "rule of 10" as determining when an otherwise healthy baby is fit for surgery (i.e., 10 weeks of age, 10 lb in body weight, and at least 10 g of hemoglobin per deciliter of blood). However, because surgical correction of the cleft is an elective procedure, if any other medical condition jeopardizes the health of the baby, the cleft surgery is postponed until medical risks are minimal.[8]

Although different cleft teams time the surgical repair differently, a widely accepted principle is compromise.The lip is corrected as early as is medically possible. The soft palatal cleft is closed between 8 and 18 months of age, depending upon a host of factors. Closure of the lip as early as possible is advantageous, because it performs a favorable "molding" action on the distorted alveolus. It also assists the child in feeding and is of psychologic benefit. The palatal cleft is closed next, to produce a functional velopharyngeal mechanism when or before speech skills are developing. The hard palatal cleft is occasionally not repaired at the time of soft palate repair, especially if the cleft is wide. In such cases, the hard palate cleft is left open as long as possible so that maxillary growth will proceed as unimpeded as possible (Fig. 1). [8]

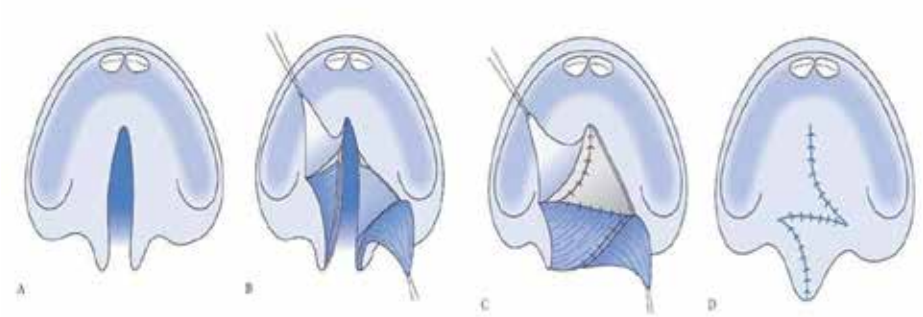

Figure 1. A, Cleft of the secondary palate (both hard and soft) from the incisive foramen to the uvula. B, Furlow double-opposing Z-plasty technique ; Z-plasty flaps developed on the oral and then nasal side. Note the cutbacks creating the nasal side flaps highlighted in blue. C, The flaps are then transposed to lengthen the soft palate. A nasal side closure is completed in the standard fashion anterior to the junction of the hard and soft palate. Generally this junction is the highest area of tension and can be difficult to close. This contributes to the higher fistula rate in this type of repair. D, The oral side flaps are then transposed and closed in a similar fashion completing the palate closure.

http://dx.doi.org/10.5772/55147

Closure of the hard palatal cleft can be postponed at least until all of the deciduous dentition has erupted. This postponement facilitates the use of orthodontic appliances and allows more maxillary growth to occur before scarring from the surgery is induced. Because a significant portion of maxillary growth has already occurred by ages 4 to 5, closure of the hard palate at this time is usually performed before the child's enrollment in school. Removable palatal obturators can be fitted and worn in the meantime to partition the oral and nasal cavities (Table 1).[8]

Staged Reconstruction of Cleft Lip and Palate Deformities

Procedure	*Timing*
Cleft lip repair	After 10 weeks
Cleft palate repair	9–18 months
Pharyngeal flap or pharyngoplasty	3–5 years or later based on speech development
Maxillary/alveolar reconstruction with bone grafting	6–9 years based on dental development
Cleft orthognathic surgery	14–16 years in girls, 16–18 years in boys
Cleft rhinoplasty	After age 5 years but preferably at skeletal maturity; after orthognathic surgery when possible
Cleft lip revision	Anytime once initial remodeling and scar maturation is complete but best performed after age 5 years

Table 1. Staged reconstruction of cleft lip and palate deformities

6. Cleft lip and palate repair

6.1. Presurgical taping and presurgical orthopedics

Facial taping with elastic devices is used for application of selective external pressure and may allow for improvement of lip and nasal position prior to the lip repair procedure. In the authors' opinions these techniques often have greater impact in cases of wide bilateral cleft lip and palate where manipulation of the premaxillary segment may make primary repair technically easier. Although one of the basic surgical tenets of wound repair is to close wounds under minimal tension, attempts at improving the arrangement of the segments using taping methods have not shown a measurable improvement. Some surgeons prefer presurgical orthopedic (PSO) appliances rather than lip taping to achieve the same goals.PSO appliances are composed of a custom-made acrylic base plate that provides improved anchorage in the molding of lip, nasal, and alveolar structures during the presurgical phase of treatment. PSOs also add significant cost and time to treatment early in the child's life. Many appliances require a general anesthetic for the initial impression used to fabricate the device. Frequent appoint-

ments are necessary for monitoring of the anatomic changes and periodic appliance adjustment.[9-12]

7. Cheilorrhaphy

Cheilorrhaphy is the surgical correction of the cleft lip deformity. The cleft of the upper lip disrupts the important circumoral orbicularis oris musculature. The lack of continuity of this muscle allows the developing parts of the maxilla to grow in an uncoordinated manner so that the cleft in the alveolus is accentuated. At birth the alveolar process on the unaffected side may appear to protrude from the mouth. The lack of sphincteric muscle control from the orbicularis oris will cause a bilateral cleft lip to exhibit a premaxilla that protrudes from the base of the nose and produces an unsightly appearance. Thus restoration of this muscular sphincter with lip repair has a favorable effect on the developing alveolar segments.[8]

8. Unilateral cleft lip repair

Clefts of the lip and nose that are unilateral present with a high degree of variability, and thus each repair design is unique. The basic premise of the repair is to create a three-layered closure of skin, muscle, and mucosa that approximates normal tissue and excises hypoplastic tissue at the cleft margins. Critical in the process is the reconstruction of the orbicularis oris musculature into a continuous sphincter. The Millard rotation-advancement technique has the advantage of allowing for each of the incision lines to fall within the natural contours of the lip and nose. This is an advantage because it is difficult to achieve "mirror image" symmetry in the unilateral cleft lip and nose with the normal side immediately adjacent to the surgical site A Z-plasty technique such as the Randall-Tennison repair may not achieve this level of symmetry because the Z-shaped scar is directly adjacent to the linear non-clefted philtrum. Achieving symmetry is more difficult when the rotation portion of the cleft is short in comparison to the advancement segment. Primary nasal reconstruction may be considered at the time of lip repair to reposition the displaced lower lateral cartilages and alar tissues. Several techniques are advocated, and considerable variation exists with respect to the exact nasal reconstruction performed by each surgeon. The primary nasal repair may be achieved by releasing the alar base, augmenting the area with allogeneic subdermal grafts, or even a formal open rhinoplasty (Fig. 2).[13-15]

9. Bilateral lip repair

Bilateral cleft lip repair can be one of the most challenging technical procedures performed in children with clefts. The lack of quality tissue present and the widely displaced segments are major challenges to achieving exceptional results, but superior technique and adequate

http://dx.doi.org/10.5772/55147

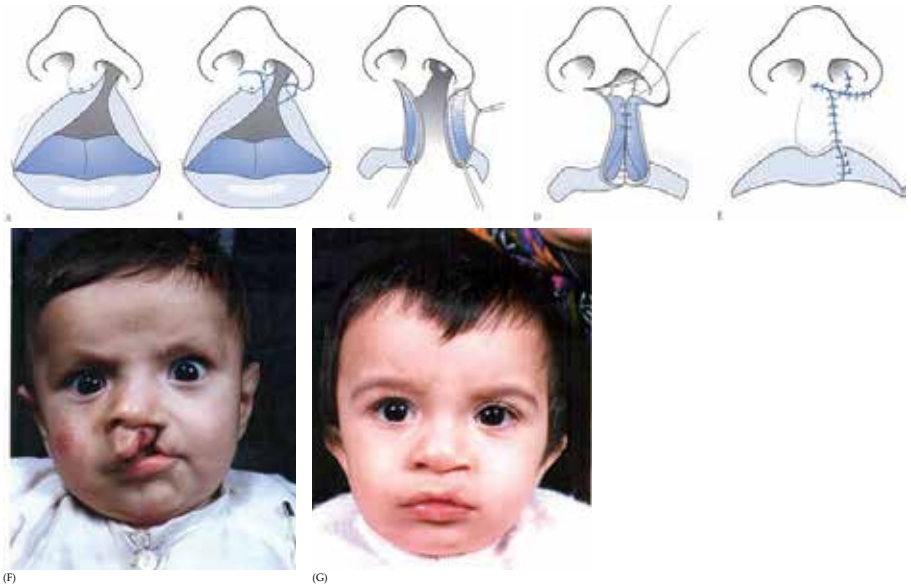

Figure 2. A, Complete unilateral cleft of the lip highlighting the hypoplastic tissue in the cleft site that is not used in the reconstruction. Nasal deformities are typical in the unilateral cleft, including displaced lower lateral nasal cartilages, deviated anterior septum, and nasal floor clefting. B, The typical markings for the authors' preferred repair are shown highlighting the need to excise the hypoplastic tissue and approximate good vermilion and white roll tissue for the repair. C, Once the hypoplastic tissue has been excised, the three layers of tissue are dissected (skin, muscle, and mucosa). It is important to completely free the orbicularis oris from its abnormal insertions on the anterior nasal spine area and lateral alar base. Nasal flaps are also incorporated into the dissection to repair the nasal floor (not shown). D, The orbicularis oris muscle is approximated with multiple interrupted sutures, and the vermilion border/white roll complex is reconstructed. The nasal floor and mucosal flaps are approximated. E, The lateral flap is advanced and the medial segment is rotated downward to create a healing scarline that will resemble the natural philtral column on the opposite side. The incision lines are hidden in natural contours and folds of the nose and lip. F, Four month-old boy with complete unilateral cleft lip and severe step maxillary segment.G, Lip closure was done by Millard II technique.

mobilization of the tissue flaps usually yields excellent esthetic results.Additionally the columella may be quite short in length, and the premaxillary segment may be significantly rotated. Adequate mobilization of the segments and attention to the details of only using appropriately developed tissue will yield excellent results even in the face of significant asymmetry. Some surgeons have used aggressive techniques to surgically lengthen the columella and preserve hypoplastic tissue using banked fork flaps.Early and aggressive tissue flaps in the nostril and columella areas do not look natural after significant growth has occurred and result in abnormal tissue contours. While surgical attempts at lengthening the columella may look good initially, they frequently look abnormally long and excessively angular later in life (Fig. 3).[16]

In severe cleft lip with protruded premaxilla early closure of the cleft and aligning of orbicularis oris muscle and return of lip sphinctric function ultimately cause setbacking of the premaxilla reducing the alveolar cleft gap and step and facilitate anterior palate and alveolar cleft repair (Fig. 4).

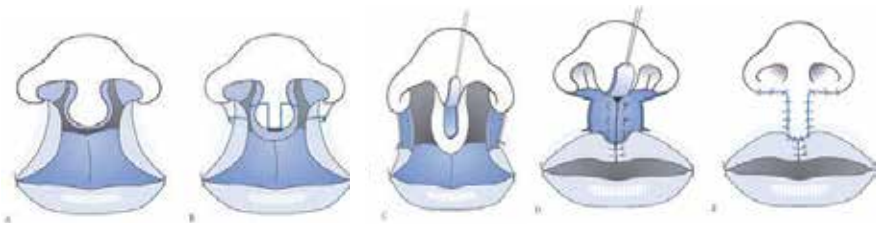

Figure 3. A, Complete bilateral cleft of the lip and maxilla showing hypoplastic tissue along the cleft edges. The importance of the nasal deformity is evident in the shorter columella and disrupted nasal complexes. B, Markings of the authors' preferred repair are shown with emphasis on excision of hypoplastic tissue and approximating more normal tissue with the advancement flaps. C, A new philtrum is created by excising the lateral hypoplastic tissue and elevating the philtrum superiorly. Additionally the lateral advancement flaps are dissected into three distinct layers (skin, muscle, and mucosa). Nasal floor reconstruction is also performed. D, The orbicularis oris musculature is approximated in the midline with multiple interrupted and/or mattress sutures. This is critical in the total reconstruction of the functional lip. There is no musculature present in the premaxillary segment, and this must be brought to the midline from each lateral advancement flap. The nasal floor flaps are sutured at this time as well. The new vermillion border is reconstructed in the midline with good white-roll tissue advanced from the lateral flaps. E, Final approximation of the skin and mucosal tissues is performed leaving the healing incision lines in natural contours of the lip and nose.

Figure 4. A, 20 year-old girl with severe bilateral cleft lip and alveolar cleft with protruded premaxilla. B, After early closure of cleft lip with Veau's technique the protruded premaxilla was corrected.C, After closed Rhinoplasty and columella lengthening.

10. Palatorrhaphy

Palatorrhaphy is usually performed in one operation, but occasionally it is performed in two.In two operation the soft palate closure is usually performed first and the hard palate closure is performed second. The primary purpose of the cleft palate repair is to create a mechanism capable of speech and deglutition without significantly interfering with subsequent maxillary growth. Thus creation of a competent velopharyngeal mechanism and partitioning of the nasal and oral cavities are prerequisites to achieving these goals. The aim is to obtain a long and mobile soft palate capable of producing normal speech. Extensive stripping of soft tissues from bone will create more scar formation.The exact timing of repair of a palate cleft is controversial.

http://dx.doi.org/10.5772/55147

Generally the velum must be closed prior to the development of speech sounds that require an intact palate. On average this level of speech production is observed by about 18 months of age in the normally developing child. If the repair is completed after this time, compensatory speech articulations may result.Repair completed prior to this time allows for the intact velum to close effectively,appropriately separating the nasopharynx from the orophayrynx during certain speech sounds. When repair of the palate is performed between 9 and 18 months of age,the incidence of associated growth restriction affecting the maxillary development is approximately 25%.If repair is carried out earlier than 9 months of age,then severe growth restriction requiring future orthognathic surgery is seen with greater frequency. At the same time proceeding with palatoplasty prior to 9 months of age is not associated with any increased benefit in terms of speech development so the result is an increase in growth related problems with an absence of any functional benefit.Using only the chronologic age it seems that carrying out the operation during the 9 to 18 months timeline best balances the need to address functional concerns such as speech development with the potential negative impact on growth. Many techniques have been described for repair of the palate.The Bardach two-flap palatoplasty uses two large full-thickness flaps that are mobilized with layered dissection and brought to the midline for closure.This technique preserves the palatal neurovascular bundle as well as a lateral pedicle for adequate blood supply. The von Langenbeck technique is similar to the Bardach palatoplasty but preserves an anterior pedicle for increased blood supply to the flaps. This technique is also successful in achieving a layered closure but may be more difficult when suturing the nasal mucosa near the anteriorly based pedicle attachments.The authors do not favor push-back techniques as they may incur more palatal scarring, restrict growth, and do not show ameasurable benefit in speech.Another common technique is the Furlow double-opposing Z plasty,which attempts to lengthen the palate by taking advantage of a Z-plasty technique on both he nasal mucosa and the oral mucosa.This technique can be effective at closing the palate but has been reported by some to have a higher rate of fistula formation at the junction of the softand hard palates where theoretical lengthening of the soft palate may compromise the closure (Fig 5).[17-19]

11. Alveolar cleft grafts

The alveolar cleft defect is usually not corrected in the original surgical correction of either the cleft lip or the cleft palate. As a result, the cleft-afflicted individual may have residual oronasal fistulae in this area, and the maxillary alveolus will not be continuous because of the cleft. Because of this, five problems commonly occur: [1] oral fluids escape into the nasal cavity, [2] nasal secretion drains into the oral cavity, [3] teeth erupt into the alveolar cleft, [4] the alveolar segments collapse, and [5] if the cleft is large, speech is adversely affected. Alveolar cleft bone grafts provide several advantages: First, they unite the alveolar segments and help prevent collapse and constriction of the dental arch, which is especially important if the maxilla has been orthodontically expanded. Second, alveolar cleft bone grafts provide bone support for teeth adjacent to the cleft and for those that will erupt into the area of the cleft. Frequently, the bone support on the distal aspect of the central incisor is thin, and the height of the bone support

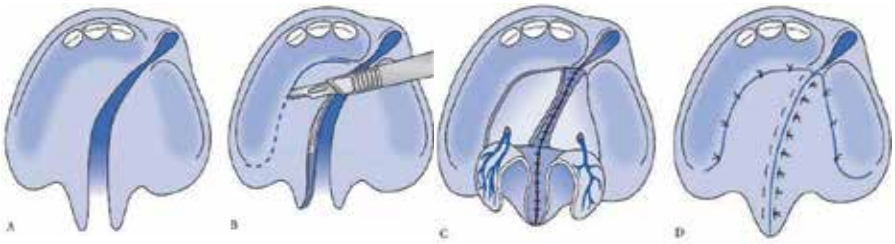

Figure 5. A, Unilateral cleft of the primary and secondary palates with typical involvement from the anterior vestibule to the uvula. B, Bardach palatoplasty technique requires two large full-thickness mucoperiosteal flaps to be elevated from each palate shelf. The anterior portion(anterior to the incisive foramen) of the cleft is not reconstructed until the mixed dentition stage.C, A layered closure is performed in the Bardach palatoplasty by reapproximating the nasal mucosa. The muscle bellies of the levator palatini are elevated off of their abnormal insertions on the posterior palate. They are then reapproximated in the midline to create a dynamic functional sling for speech purposes. D, Once the nasal mucosa and musculature of the soft palate are approximated, the oral mucosa is closed in the midline. The lateral releasing incisions are quite easily closed primarily due to the length gained from the depth of the palate. In rare cases, in very wide clefts a portion of the lateral incisions may remain open and granulate by secondary intention.

varies. These teeth may show slight mobility because of this lack of bone support. Increasing the amount of alveolar bone for this tooth will help ensure its periodontal maintenance. The canine tends to erupt into the Cleft site and, with healthy bone placed into the cleft will maintain good periodontal support during eruption and thereafter. The third benefit of alveolar cleft grafts is closure of the oronasal fistula, which will partition the oral and nasal cavities and prevent escape of fluids between them.[20]

Cleft management should always involve a multidisciplinary team, with the expertise to develop a proper treatment plan. Difficulties may arise when the priorities of one specialty compete with those of another. If the surgical team is faced with an orthodontic provider who feels strongly that it is appropriate to align the maxillary central incisors as soon as they erupt, it will be necessary for the alveolar defect to be grafted earlier to prevent compromise of osseous support for the central incisors. Some orthodontists and surgeons believe that palatal expansion is necessary prior to grafting. These teams may find that it is more appropriate to graft patients at a later age, as it may take months to achieve the desired expansion prior to the graft.

12. Source of bone graft

The selection of the ideal grafting material is somewhat dependent on the timing of the graft. In primary bone grafting, the rib is the only site for adequate quantity of bone with acceptable morbidity. In the mixed dentition stage, the rib is not as appropriate as other sites such as the calvaria or iliac crest. These options would also be possible sources for bone for late secondary grafting, as well as grafts from the mandibular symphysis and possibly the tibia.

http://dx.doi.org/10.5772/55147

13. Iliac crest

Potential advantages of the iliac crest bone graft include low morbidity and high volume of viable osteoblastic cells (cancellous bone); two teams may work simultaneously, and this procedure is well accepted by the patient.

14. Allogeneic bone and bone substitutes

In an effort to eliminate the morbidity and time necessary to harvest bone from any autogenous site, some authors have evaluated allogeneic bone as a potential source of graft material. Studies have shown that allogeneic bone can be used successfully to graft secondary alveolar cleft defects and that results can be compared favorably with those achieved with autogenous bone. However, the demands of bone healing in the alveolar defect where there is potential communication between the graft and the nasal and oral cavity may make this less predictable in large cleft defects or bilateral clefts. In general, bone healing with autogenous bone is biologically different than with allogeneic bone. Autogenous bone grafts initiate an angioblastic response early in the healing process, and some of the transplanted cells remain viable, resulting in a more rapid formation of new bone. In contrast, allogeneic bone grafts demonstrate slower revascularization, as there are no viable cells transferred with the graft. In summary, autogenous bone harvested from the iliac crest remains the most predictable technique.[21]

15. Surgical technique for grafting the cleft alveolus

The ideal technique will meet the following criteria:

1. Predictable closure of the nasal floor produces a watertight barrier between the graft and the nasal cavity
2. Access to closure of residual palatal and labial fistula
3. Keratinized attached tissue is maintained around the teeth adjacent to the cleft and at the site where the yet unerupted lateral incisor and canine will erupt
4. Mobilization of tissue is adequate to close large defects without tension,when such defects are present
5. The vestibule is not shortened, and scarring is not excessive

Given these requirements, the technique most often used employs advancing buccal gingival and palatal flaps. This approach has some disadvantages, including the following:

1. Difficulty obtaining closure in large bilateral clefts, which heal by secondary intention of full-thickness wounds created by the advancement

2. A four-corner suture line that approximates the flaps directly overlying the graft, which may lead to dehiscence

3. The possibility that elevating large full thickness mucoperiosteal flaps leads to growth alteration in young patients.However, when compared with finger flaps and trapezoidal flaps, which can shorten the vestibule and placenonkeratinized tissue around the dentition, this approach remains the best.[21]

In our center we prefer harvesting bone graft orally from the symphysis or anterior border of ramus without changing patient position because of easy access and the rate of success is comparable to other methods.

Author details

Koroush Taheri Talesh[1] and Mohammad Hosein Kalantar Motamedi[2]

1 Oral and Maxillofacial Surgery Tabriz University of Medical Sciences and Azad University of Medical Sciences,Tehran, Iran

2 Oral and Maxillofacial Surgery Baqiyatallah University of Medical Sciences Trauma Research Center,Tehran, Iran

References

[1] Costello, B. J, Ruiz, R. L, & Turvey, T. Surgical management of velopharyngeal insufficiency in the cleft patient. In: Oral and maxillofacial surgery clinics of North America: secondary cleft surgery. Philadelphia (PA): W.B. Saunders; (2002). , 539-551.

[2] Ruiz, R. L, Costello, B. J, & Turvey, T. Orthognathic surgery in the cleft patient. In: Ogle O, editor.Oral and maxillofacial surgery clinics of North America: secondary cleft surgery.Philadelphia (PA): W.B. Saunders; (2002). , 491-507.

[3] Costello, B. J, Shand, J, & Ruiz, R. L. Craniofacial and orthognathic surgery in the growing patient. Selected Readings Oral Maxillofacial Surg (2003). , 11(5), 1-20.

[4] Tolarova, M. M, & Cervenka, J. Classification and birth prevalence of orofacial clefts. Am J Med Genet (1998). , 75, 126-37.

[5] Tolarova, M. Etiology of clefts of lip and/or palate: 23 years of genetic follow-up in 3660 individual cases. In: Pfeifer G, editor. Craniofacial abnormalities and clefts of the lip,alveolus, and palate. Stuttgart: Thieme;(1991). , 16-23.

[6] Gorlin, R, Cohen, M. J, & Levin, L. Syndromes of the head and neck. 4th ed. New York (NY):Oxford University Press; (2003). orofacial clefting. Cleft lip and palate: a physiological approach, Oral Maxillofac Clin North Am 2000;, 12, 379-97.

[7] Shaikh, D, Mercer, N. S, Sohan, K, et al. Prenatal diagnosis of cleft lip and palate. Br J PlastSurg (2001). , 54, 288-9.

[8] Posnick, J. C. The staging of cleft lip and palate reconstruction: infancy through adolescence.In: Posnick JC, editor. Craniofacial and maxillofacial surgery in children and young adults. Philadelphia (PA):W.B. Saunders;(2000). , 785-826.

[9] Poole, R, & Farnworth, T. K. Preoperative lip taping in the cleft lip. Ann Plast Surg (1994). , 32, 243-9.

[10] Shaw, W. C, & Semb, G. Current approaches to the orthodontic management of cleft lip and palate. J R Soc Med (1990). , 83, 30-3.

[11] Ross, R. B. MacNamera MC. Effect of presurgical infant orthopedics on facial esthetics in complete bilateral cleft lip and palate. Cleft Palate Craniofac J (1994). , 31, 68-73.

[12] Grayson, B. H, Santiago, P. E, Brecht, L. E, et al. Presurgical nasoalveolar molding in infants with cleft lip and palate. Cleft Palate Craniofac J (1999). , 36, 486-98.

[13] Randall, P. Long-term results with the triangular flap technique for unilateral cleft lip repair. In: Bardach J, Morris H, editors. Multidisciplinary management of cleft lip and palate. Philadelphia (PA): W.B. Saunders;(1990). , 173.

[14] Millard, D. R. Cleft craft: the evolution of its surgery. Alveolar and palatal deformities. Boston (MA): Little Brown; (1980). , 3

[15] Posnick, J. C. Cleft-orthognathic surgery: the unilateral cleft lip and palate deformity. In:Posnick JC, editor. Craniofacial and maxillofacial surgery in children and young adults. Philadelphia (PA): W.B. Saunders;(2000). , 860-907.

[16] Posnick, J. C. Cleft-orthognathic surgery: the bilateral cleft lip and palate deformity. In: Posnick JC, editor. Craniofacial and maxillofacial surgery in children and young adults. Philadelphia (PA): W.B. Saunders;(2000). , 908-950.

[17] Posnick, J. C. Cleft-orthognathic surgery: the isolated palate deformity. In:Posnick JC, editor. Craniofacial and maxillofacial surgery in children and young adults. Philadelphia (PA): W.B. Saunders; (2000). , 951-978.

[18] Posnick, J. C, & Tompson, B. Cleft-orthognathic surgery. Complications and long-term results. Plast Reconstr Surg (1995).

[19] Dorf, D. S, & Curtin, J. W. Early cleft palate repair and speech outcome: a ten year experience. In: Bardach J,Morris HL.Multidisciplinary management of cleft lip and palate.Philadelphia (PA): W.B. Saunders; (1990). , 341-348.

[20] Sindet-pedersen, S, & Enemark, H. Reconstruction of alveolar clefts with mandibular or iliac crest bone graft: a comparative study. JOral Maxillofac Surg (1990). , 48, 554-8.

[21] Sadove, A. M, Nelson, C. L, Eppley, B. L, et al. An evaluation of calvarial and iliac donor sites in alveolar cleft grafting. Cleft Palate J (1990). , 27, 225-8.

Chapter 21

The Cosmetic Considerations in Facial Defect Reconstruction

Mazen Almasri

Additional information is available at the end of the chapter

http://dx.doi.org/10.5772/52024

1. Introduction

The 21st century is designated by the era of communication, multimedia, hi-tech gadgets and network connection programs that help people share the news, events, pictures and recent advancements throughout the world. The common denominator is the facial profile or image. Moreover, facial cosmetic advertisement, media, and products are taking big share of this phenomenon. Ad's usually display male and female individuals of variable age groups to assure reflecting the best facial and body figure toward the outer world. This goes hand-in-hand with the humanitarian beauty jealousy, the raised professional standards, the increase of sales managements and marketing business, the application of the quality management protocols in working environment, and the increase in self-satisfaction level and confidence. All the aforementioned issues raise the demand for facial cosmetics surgery and better quality of life. Thus, the new era of maxillofacial reconstruction had upgraded the concepts of management. The oral and maxillofacial surgeon may encounter severe panfacial trauma, severe maxillofacial tumors, abnormal congenital defects and secondary facial deformities that require extreme caution while constructing the surgical treatment plan. Such plan should provide the patient not only with better surgical outcome, but also improve the emotional self-satisfaction, family acceptance, quality of life, and easier re-integration into the working society.

Maxillofacial fractures are still a common cause of hospital admission for treatment all over the world [1,2]. Although major advancements in the safety of motor vehicles and traffic regulations traffic accidents (RTAs); are still a major problem in developing countries while alcohol abuse is the major stimulant associated with personal altercations [3]. It is well proved that most of the facial injuries do occur in the second to fourth decades of life, which is usually a studying or a working period in the individuals' life. Thus, although the concept

INTECH
open science | open minds

© 2013 Almasri; licensee InTech. This is a paper distributed under the terms of the Creative Commons Attribution License (http://creativecommons.org/licenses/by/3.0), which permits unrestricted use, distribution, and reproduction in any medium, provided the original work is properly cited.

of reduction and fixation is the main pillar of treating facial fractures, it is still not enough. Facial cosmetics and esthetics are important considerations that merit attention; treatment of the fracture alone is not always enough. Many fracture are associated with facial defects (Figure 1).

Figure 1. An attractive 26 year- old female treated for a right orbital fracture and fixation through transconjuctival approach with lateral canthotomy. Although the results are very good she still feels that the palpebral fissure space on the right eye is smaller than the left eye. (Special gratitude to my colleague Dr E. Elizabeth, McGill University, Canada)

The same concept can be applied in managing maxillofacial defects secondary to large tumors resections. It is extremely common to have patients ask their physicians mainly about the "postoperative scar" rather than the outcome of the tumor resection margin which the treating physician spends a lot of time trying to explain [4]. Although that assuring total tumor resection and free margins can be the surgeons main nightmare in treating such large invasive tumors, restoring facial esthetics is a primary concern that might even change the treatment process accordingly, not to mention the importance of overall health status, safety of treatment, time and cost effectiveness. A thorough discussion of the treatment benefits, alternatives, and risks with the patient himself and the family is essential to construct the best treatment plan and options.

Tumors can occur in young or elderly individuals; each has its individual treatment concept with regard to restoring the quality of life. Younger ambitious individuals dream of full recovery and return to social life, while older individuals think of their family and their postsurgical facial image and how it will affect them and their offspring. Hence, a treatment plan for a 14 year-old girl suffering from invasive mandibular Ewing's sarcoma will not be managed the same way as a mandible pathology in an 89 year-old grandfather. In this chapter, we will discuss some cases with variable facial defects that are treated considering the points mentioned. The cases presented were considered as severe in its category.

In the midst of all the surgical challenges, it is important to realize that achieving the combined goals is not always an easy task. Achieving full function, perfect occlusion and esthetics in a major referral center with a long waiting list of patients can be a busy surgeon's biggest nightmare.

http://dx.doi.org/10.5772/52024

Case 1: Secondary upper lip deformity.

This is a case that discusses a secondary reconstructive operation for a known cleft lip and palate patient who is not satisfied with the results. A 22-year - old female patient treated for cleft lip and palate in various centers across the country. She came to our clinic with a complaint of deformed upper liplocated more posterior than the lower lip. In addition, she did not like how her nose appeared. Clinical exam showed a thin upper lip, inverted, and located posterior to the lower lip. The frontal evaluation showed a thin flat upper lip, undefined white roll, uneven vermilion border, undefined cupids bow and philtrum edges. Further, the lower lip showed more volume and definition. The nose was also deformed and in a very bad condition and displayed poor results of previous rhinoplasty procedures (Figures 2, 3). Several surgeons have met the patient and recommended midface augmentation and possible LeFort 1 osteotomy and advancement inorder to correct the midface deficiency and give her nose some projection and upward rotation. The patient was afraid to go through this procedure and asked me if other treatment options can be offered to her. On clinical and radiographic investigations, its was apparent that the upper lip soft tissue disfigurement comprised a major area of the problem which a Le Fort 1 advancement alone may not be able to correct especially since the patient had an acceptable dental occlusion. Alternatively, the patient was offered the following surgical plan:

1. Upper lip lift and eversion chieloplasty

2. Abdomen fat transfer to the upper lip

3. Delayed reconstructive rhinoplasty and lip border definition

The patient agreed to the surgical plan, and the procedure was accomplished under general anesthesia. The flap design, W-plasty with asymmetric arms to reconstruct the deformed philtrum, philtum edges, cupids bow, and white roll alignment are shown in Figures 4-6. [5]. The patient had a flat asymmetric inverted lip, which made selection of the lifting direction more challenging. The underlying muscle layer was identified and resection of the planned W-skin was made. Minimal flap undermining was done in a caudal direction only and an attempt to evaluate the eversion movement was performed to assess the need of any further excision. After the chieloplasty was accomplished, fat was harvested from the right abdominal area and transferred to the upper lip and vermillion area. Over- correction was performed to compensate for the postoperative fat resorption. Polygalactin 90, 4-0 suture was used to approximate the subcutaneous tissue and nylon 6-0 suture was used to close the skin layer.

The operation went well and the patient was transferred to the ward the day of the operation and was discharged from the hospital in three days. She was prescribed antibiotics, analgesics, and a postoperative instruction sheet that include sun protection advice. The recovery period was uneventful. The postoperative figures showing the lip new look, which was well appreciated by the patient and her family.

Postoperatively the patient was seen and plans were made to pursue the secondary rhinoplasty in 6 months. However, the patient failed to refer for follow up as she got married and moved into another city.

Figure 2. Frontal view showing the severe upper lip inversion, loss of mass, flat architicture and loss of philtum anatomy cupids bow and tuberculum.

Figure 3. profile image showing the severe upper lip retro positioned, flat, and atrophic mass when compared to the upper lip, simulating a midface dificiency condition.

Figure 4. One day postoperatively showing the upper lip improved shape, thickness, and position in relation to the lower lip.

http://dx.doi.org/10.5772/52024

Figure 5. one day postoperatively showing the improved shape and thickness of the upper lip after the fat transfer graft.

Figure 6. days postoperatively

Case 2: Panfacial fracture.

This case, discusses a scenario where flap design should be planned in order to achieve multiple surgical objectives. Here it was prudent to use the primary laceration line, expose the fracture sites, and to obtain soft tissue lifting where needed. An 18 year-old female patient was a victim of a severe road traffic accident. She was admitted to the hospital for general systemic stabilization. She was cleared for operation about one month post-admission. Clinical examination showed right temporal degloving laceration that was sutured in the emer-

gency department. A drooping right eyebrow, and displaced zygomatic prominence into inferior medial position was apparent. The skin showed multiple abrasions of the right side of the face, periorbital region and cheek, which felt to be fibrosed, and fixed to the underlying tissue.The CT scan showed severely displaced right ZMC fracture into inferior-medial-posterior direction with displaced zygomatic arch fracture (Figures 7, 8). After discussing the case with the patient and her family, the plan was to extend the temporal degloving laceration into a coronal and pre auricular flap in order to expose the fractures and the zygomatic arch. Under general anesthesia, the patient underwent the planned flap design, and all the fracture sites were exposed successfully. Open reduction of the fractures and re-orienting the ZMC back to anterior-lateral-superior direction was accomplished concomitantly via fixating the zygomatic arch and facial fractures using plates and screws. Although fracture reduction and fixation was pursued to achieve symmetry with the contralateral side as much as possible, it was clear to the surgical team that soft tissue closure of a defect of such extent will not help the preoperative facial ptosis [6]. Hence, our approach was to give the right facial aspect some brow and facelift through the opened flap. The procedure was attempted in two planes, a deeper plane to the border of the zygomatic prominence just deep to McGregors patch, using 3-0 polygalactin 90 sutures were used to resuspend the deeper structures in an upward and lateral direction. The second plane was more superficial and excess skin and subcutaneous tissue was trimmed and the face and brow were lifted with minor over correction compared to other side to compensate for postoperative fibrosis. The lifting procedure added approximately 30 minutes to the operating time, as the surgical plan and flap design was used simultaneously for common objectives. Final closure was attempted using 3-0 polygalactin 90 suture for the subcutaneous plane and staples for the skin. An external head ribbon dressing was applied to support the lifting procedure (Figures 9-12). The patient returned to the ICU and stayed in the hospital for 4 more weeks before leaving into a neurological rehabilitation center.

The patient was seen couple of months later and the lifting procedure showed acceptable facial symmetry, although she will require further skin rejuvenation procedures for the skin abrasion wounds.

Figure 7. Frontal view of panfacial fracture on day 6 after trauma.

http://dx.doi.org/10.5772/52024

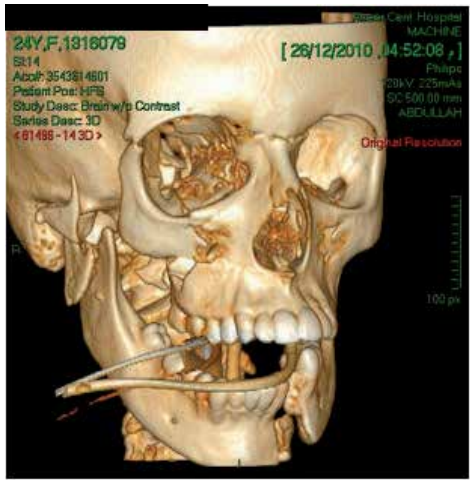

Figure 8. Preoperative 3D CT scan simulation showing the right ZMC complex displaced fracture.

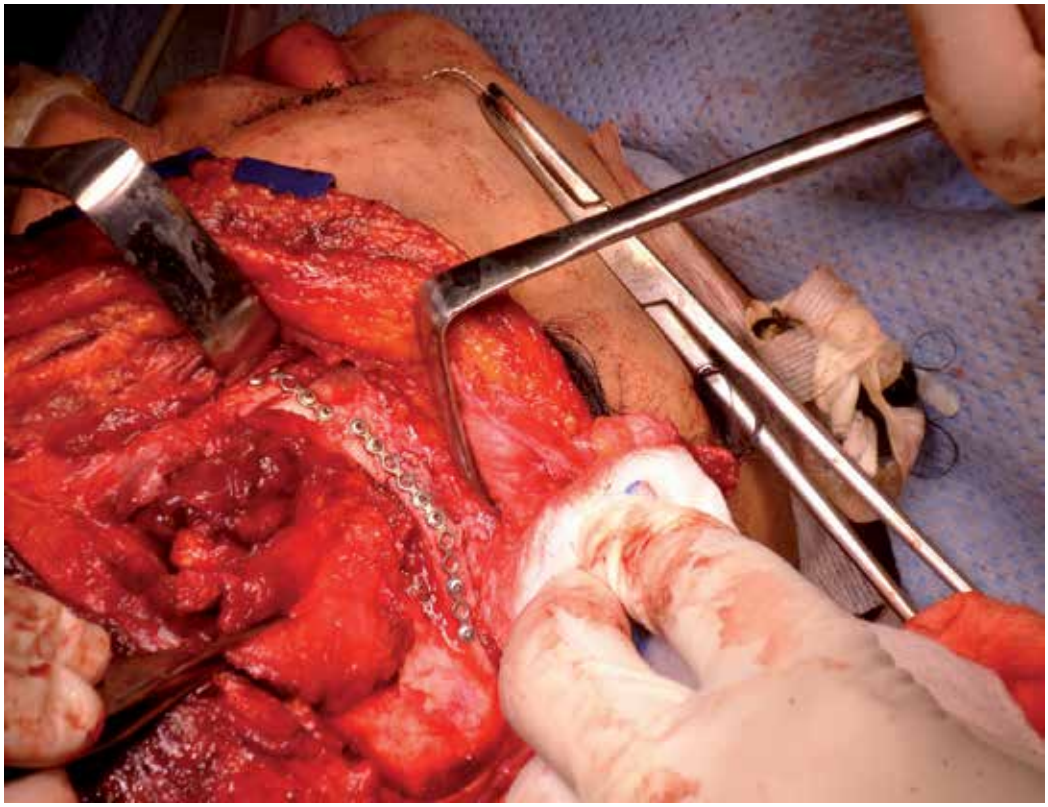

Figure 9. clinical intraoperative figure showing zygomatic arch reduction and fixation.

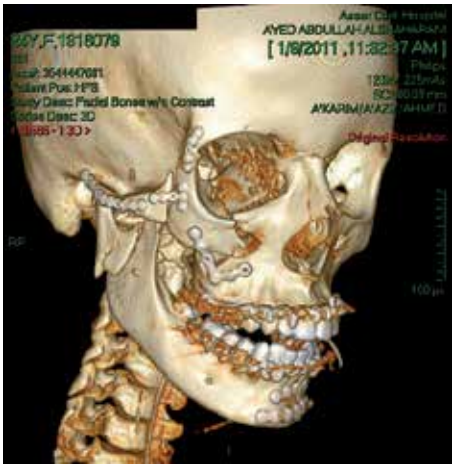

Figure 10. A postoperative 3D CT simulation image showing the perfect fracture reduction and fixation, however, soft management was still needed to optimize the clinical results.

Figure 11. Right eyebrow overcorrection to compensate for future reduction.

http://dx.doi.org/10.5772/52024

Figure 12. Right periorbital scarring.

Case 3: Atrophic mandible fracture secondary to anterior implant placement.

This case discusses the importance of evaluating the skin type and architecture before attempting a transcervical approach to the mandible. Although the intraoral approach does have the advantages of avoiding scar, avoiding the risk of facial nerve injury, and less emotional impact on patients, it is not inapplicable in all cases. Hence, case selection is the main factor to consider to pursue the approach [7]. A 77 year-old female patient came to our clinic after having five anterior dental implants placed in the mandibular interformanial area. Her chief complaint was pain at the right first premolar implant site. The patient had her implants placed 4 days before sensing a crack while eating using her provisional denture. Her clinical and radiographic investigations showed that she had a compound displaced atrophic mandible fracture at the implant site. The patient had a thin overall body architecture and thin skin – subcutaneous envelope in the head and neck region. The elasticity of the skin showed slow return on snap elasticity test.Usually the treatment of atrophic mandible fracture is through a transcervical incision for sufficient exposure and manipulation. Drawbacks of transcervical approach include risk of injury to the marginal mandibular nerve, unesthetic scar, and risk of transcutaneous fistula in elderly patients. However, considering the body and skin quality of the patient, an intra oral approach was considered to mainly reduce the chances of unesthetic scarring, and transcutaneous fistula.

The procedure was explained to the patient and she expressed total interest in avoiding the transcervical approach. An intraoral approach was performed as anticipated and sufficient access for plate fixation at the symphysis and parasymphysis areas while a transbuccal trocar access was used for plate fixation of the body and angle. The incision was placed at the crest of the mandible with two distal vertical releases to elevate a fullthickness flap. The mental nerves were identified and protected throughout the procedure. Re-

duction and fixation of the fracture was done using 2.4 locking plate and screws. To prepare for closure, the flap at the lower lip side was undermined to achieve tension free approximation at the anterior segment. The mentalis muscle and flap were then reapproximated using 3-0 polygalactin 90 suture. An external dressing was placed on the chin and used for 2 weeks (Figures 13-18).

Postoperativeradiographs showed adequate plate and screw positioning. The patient was started on clear fluid diet and was discharged from the hospital on the third postoperative day. At the 1.5 year follow up visit showed cosmetic facial results and the patient is satisfied with the results of treatment.

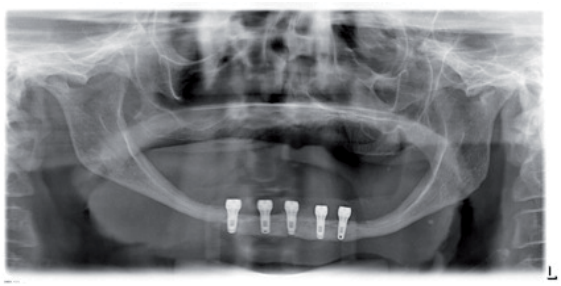

Figure 13. Panormaic radiograph showing the mandible fracture site at the right body region at the right premolar site.

Figure 14. Reconstruction plate is in place and the fracture gap grafted with autogenous bone. Note the integrity of the mental nerve.

http://dx.doi.org/10.5772/52024

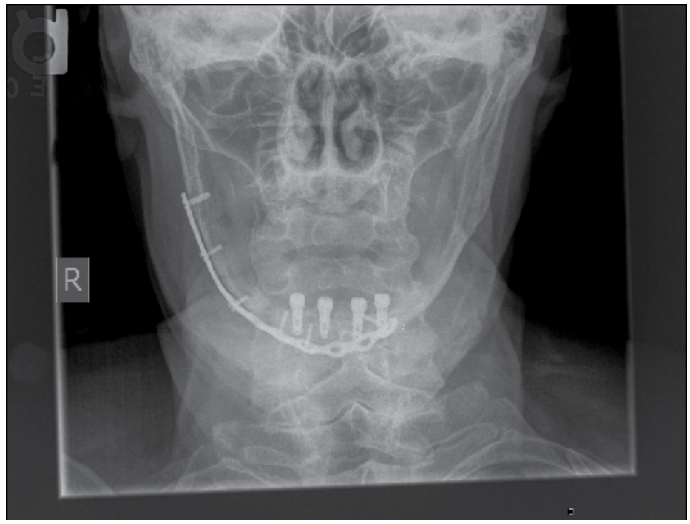

Figure 15. AP radiograph showing the reconstruction plate in place and the challenging screw position in between the implants.

Figure 16. A lateral cephalometric radiograph showing the reconstruction plate in place at the most inferior border of the severely atrophic mandible.

Figure 17. 5 weeks postoperative occlusal picture. Showing good closure of the wound all over including the previously dehisced site on the left implants area.

Figure 18. A clinical picutre of the cervical region 3 months postoperatively showing cosmetically acceptable neck area that was not affected by the surgical intevention.

http://dx.doi.org/10.5772/52024

Case 4: Bilateral cleft lip and palate with severe displacement of the premaxilla in a 17 year-old female (Figures 19-24).

This case shows a rare case of severe facial disfigurement secondary to neglected cleft lip and palate (CLAP) management from birth to the age of 17. This 17 year- old female patient referred to our clinic complaining of her facial deformity that negatively affected her social life and education to such an extent that she had to stop going to school. On clinical and radiographic examination, the patient had bilateral CLAP with severe (3.7cm) premaxillary displacement in an anterior and inferior position. She reported she had not sought professional medical help during the past 17 years of her life [8]. As the facial reconstruction team had to deal with a severe CLAP facial disfigurement in an older patient, the surgical plan mainly focused on accelerating the possibility of having this girl reintegrating back into social life and continuing education. Hence, it was planned to surgically reposition the premaxilla and repair the cleft palatal severe defect concomitantly.

The patient was informed that further reconstructive surgeries such as revision chieloplasty, rhinoplasty, oral rehabilitation, and possibly orthognathic surgeries might be required in the future.

Under general anesthesia, the patient's wide cleft palate was identified and planned for closure of the uvula, soft and hard palate defect using full thickness total palatal flaps (V-Y pushback) and vomerian flaps concomitantly with premaxilla reduction and nasal septum flap management.The wide cleft palate was managed successfully and the protruded premaxilla/septum bone was resected (2.9cm) in semi triangular shape to help in repositioning the premaxilla in back-upward direction. The nasal septum had to be trimmed conservatively and the premax position was secured using 4-0 Prolene sutures fixated at the bony segments of the palate and premaxilla. Minimal gengivo-periosteoplasty adhesion was made at the proximal segment to aid in retaining the new position in tension free fashion.

Figure 19. An occlusal view showing the severe premaxilla displacement.

Figure 20. Lateral Profile view.

Figure 21. Frontal view.

Figure 22. Lateral occlusal view.

http://dx.doi.org/10.5772/52024

Figure 23. One week postoperative profile picture showing that the premaxilla is now enclosed back inside the oral cavity after resecting about 2.9cm of the protruded premaxillary bone and nasal septum reduction.

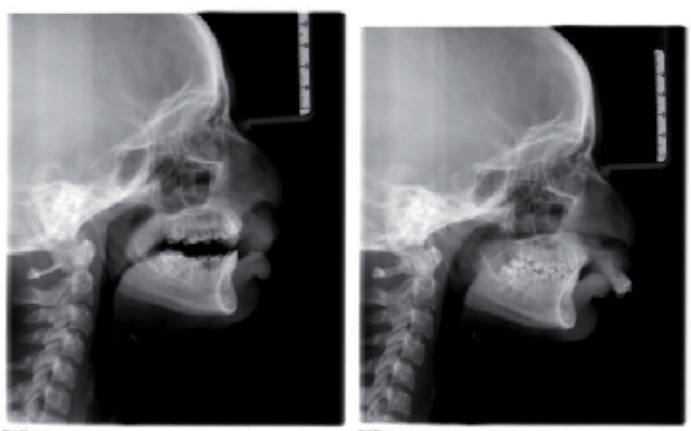

Figure 24. Lateral cephalometric showing the difference between the preoperative position (right) and on the post-operative reduced position (Left).

Case 5: Severe orbital vertical dystopia.

A 20 year- old male patient referred complaining of severe unesthetic vertical dystopia. The patient had a history of RTA few months ago and was in the ICU to control his unstable systemic status. Maxillofacial surgeries were not attempted for him at that time. Clinical examination revealed right orbital vertical dystopia of about 2cm inferiorly, fibrotic skin abrasions at the nasoorbital ethmoidal region, at the cheek, forehead, and lateral orbital regions. Due to the aforementioned, the patient was off school for one year since the patient planed to pursue facial reconstruction before enrolling back to school. Radiographic interpretation revealed orbital floor fracture and inferior displacement into the maxillary sinus by 2cm. ENT consultation was done and interpreted normal functioning status of the maxillary sinus. Management of such cases is challenging since the deformity is secondary to untreated displaced facial fractures a year ago and all the fractures have healed in abnormal alignment pattern. Furthermore, the soft tissue was deformed due to malunion and poor skin texture due to the scarring. The surgical objective was to alleviate the unesthetic vertical dystopia using a block of nonvascularized bone from the anterior iliac crest to support the eyeball superiorly, realign the inferior orbital rim which was posteriorly displaced, lift the right brow upwards and laterally, and canthoplasty for the deformed lateral canthus. Under general anesthesia, a transconjuctival incision with lateral canthotomy was performed to expose the inferior orbital rim and displaced orbital floor [9]. Elevation of the eyeball was attempted and the space of the supporting block was prepared. A second team was harvesting the anterior iliac crest bone graft, which was trimmed and sandwiched under the eyeball with consideration to reconstruct the inferior orbital rim and anteroposterior defect. Next, canthopexy of the lateral canthal tendons was done in a more superior position to compensate for the traumatic inferior displacement. The brow was lifted using the scar revision incision at the superior orbital rim area. (Figures 25-29) Follow up visits were uneventful and showed significant improvement and patient satisfaction. The patient is still planned for further reconstructive surgeries and skin rejuvenation procedures and he is already enrolled back to school.

Figure 25. Right orbital inferior vertical dystopia.

http://dx.doi.org/10.5772/52024

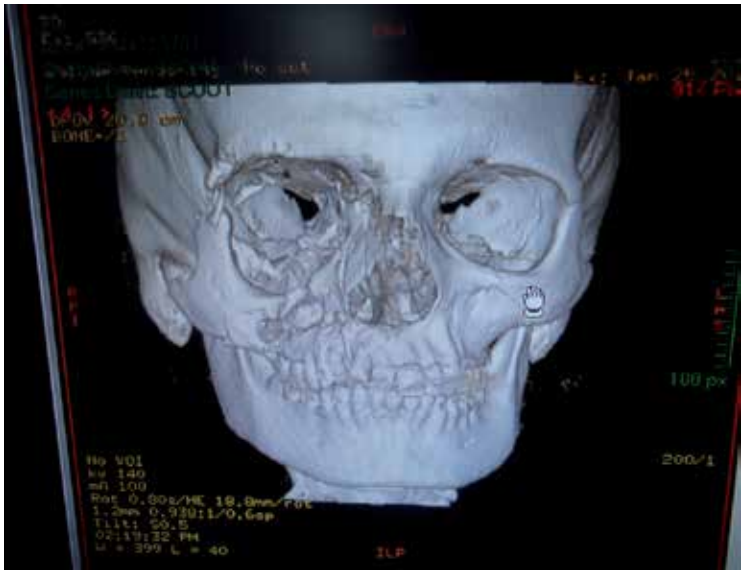

Figure 26. CT 3d simulation showing the magnitude of the inferior right dystopia.

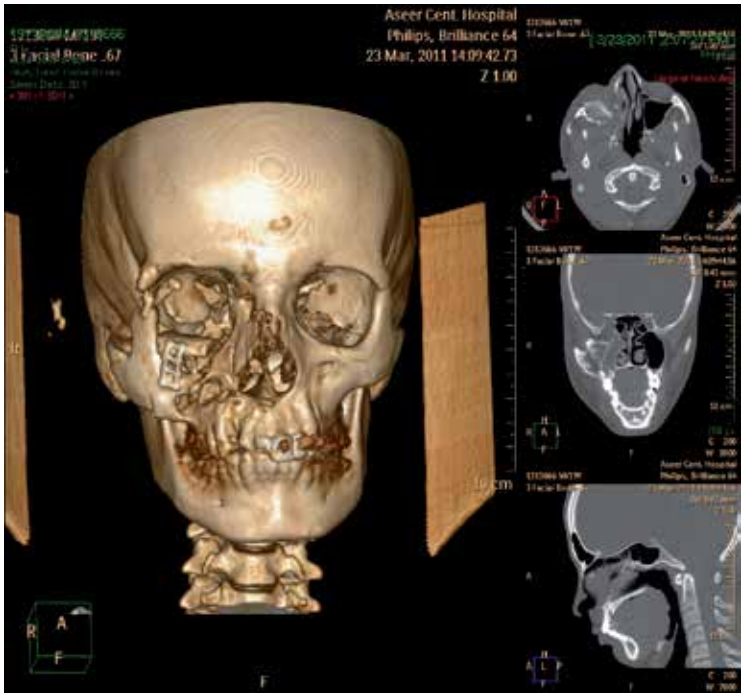

Figure 27. Postoperative 3D CT simulation showing the magnitude of right inferior orbital rim and floor elevation using a non vascularized bone graft from the anterior iliac crest.

Figure 28. a postoperative CT scan of parasagittal cut showing section of the graft material that is elevating the eye ball back into the orbital cavity.

Figure 29. The left view is the preoperative view showing the vertical dystopia while the right showing the postoperative correction of the dystopia and brow lift, as the first stage of treatment. Further corrective surgeries are planned.

2. Conclusion

This chapter presents five cases with facial deformities that are considered "severe". All five cases share the fact that facial esthetics was a significant consideration in the plan of management. Planning the flap design, hard tissue management, and soft tissue management are the basic pillars of treatment. As each of the three pillars of facial reconstruction contribute to the surgical procedure, equal attention should be paid to each. The aim of this chapter was to high-light the importance of this issue in treating oral maxillofacial patients.

http://dx.doi.org/10.5772/52024

Acknowledgements

The author would like to thank Dr. Morai Alqahtani and Dr Bader A. Raouf (Plastic Surgery Department, Saudi Arabia) for their assistance and support towards the Maxillofacial Surgery and Reconstruction Department, Dr Tord Lundgren (Periodontics surgery – USA, Sweden / Saudi Arabia) and Dr Ibrahim Zabani (Anesthesia – Saudi Arabia) for their help in solving the obstacles for treating the facial deformity patients, Dr Joe III Nimatu (Richmond, Virginia, USA) for his continuous insights in the field of facial cosmetics, my deep gratitude to the higher management of Umm Al Qura University – College of Dentistry for the strong support to the field of research, and last but not least "my family; Najiah, Ghena, and Ibrahim" in the beautiful Jeddah city of Saudi Arabia for their patience and support throughout all the working hours outside as well as inside home, thank you all.

Author details

Mazen Almasri

Address all correspondence to: mazen_ajm@yahoo.com

Assistant Professor of Oral Maxillofacial Surgery and Reconstruction Faculty of Dentistry, Umm Alqura University, Saudi Arabia

References

[1] Aksoy, E., Unlü, E., & Sensöz, O. (2002). A retrospective study on epidemiology and treatment of maxillofacial fractures. *J Craniofac surg.*, 13(6), 772-5.

[2] Miloro, Michael. (2004). Peterson's Principle's of Oral and Maxillofacial Surgery. *BC DECKER INC.*, 327.

[3] Ozkaya, O., Turgut, G., Kayali, M. U., Uğurlu, K., Kuran, I., & Baş, L. (2009). A retrospective study on the epidemiology and treatment of maxillofacial fractures. *Ulus Travma Acil Cerrahi Derg.*, 15(3), 262-6.

[4] Binahmed, A., Nason, R. W., & Abdoh, A. A. (2007). The clinical significance of the positive surgical margin in oral cancer. *Oral Oncol.*, 43(8), 780-4.

[5] Waldman, S. R. (2007). The subnasal lift. *Facial Plast Surg Clin North Am.*, 15(4), 513-6.

[6] Ranganath, K., & Hemanth Kumar, H. R. (2011). The correction of post-traumatic pan facial residual deformity. *J Maxillofac Oral Surg.*, 10(1), 20-4.

[7] Almasri, M., & El -Hakim, M. (2012). Fracture of the anterior segment of the atrophic mandible related to dental implants. *Int J Oral Maxillofac Surg.*, 41(5), 646-9, Epub 2012 Feb 5.

[8] Dürwald, J., & Dannhauer, K. H. (2007). Vertical development of the cleft segments in infants with bilateral cleft lip and palate: effect of dentofacial orthopedic and surgical treatment on maxillary morphology from birth to the age of 11 months. *J Orofac Orthop.*, 68(3), 183-97.

[9] Moore, F. O., Thornton, B. P., Zabel, D. D., & Vasconez, H. C. (2004). Autogenous orbital reconstruction in a child with congenital abnormalities of the orbital roof and vertical orbital dystopia. *J Craniofac Surg.*, 15(6), 930-3.

Chapter 22

Current Advances in Mandibular Condyle Reconstruction

Tarek El-Bialy and Adel Alhadlaq

Additional information is available at the end of the chapter

http://dx.doi.org/10.5772/54875

1. Introduction

The temporomandibular joint, like any other synovial joint, can be the subject of severe degenerative pathological conditions as well as fracture and ankylosis. Advanced conditions may require rib or hip grafts, allografts, or total joint replacement. All current approaches suffer from inherent shortcomings and the search continues for a new approach to reconstruct the mandibular condyle with minimal or no side effects. Stem cell-based tissue engineering approach to reconstruct the mandibular condyle has long been introduced; however its potential clinical application requires long and costly dedicated research programs. Other therapeutic physical approaches to enhance tissue regenerative capacity have also been proposed, however their potential application needs further attention and investigation.

2. Clinical indication

Articular joints have a poor innate ability to regenerate following either injury or disease. Among these diseases that affect articular joints is arthritis. In Canada, arthritis is the leading cause of work disability, with an economic cost of $4.4 billion in 1998 alone [1]. Statistics Canada reports estimated that 6 million Canadians will suffer from some form of arthritis by 2026, a significant increase from the current prevalence of four million Canadians [2]. The temporomandibular joint (TMJ) connects the mandible to the skull and is vital for speech, chewing, and swallowing.It is comprised of a mandibular condyle and an articular disk. TMJ is susceptible to arthritis, fractures, ankylosis, and dysfunctional syndromes that affect over 10 million individuals in North America [3-9]. To date, artificial joint replacement is considered the standard therapeutic procedure for degenerated TMJ, but this treatment approach has a

INTECH
open science | open minds

© 2013 El-Bialy and Alhadlaq; licensee InTech. This is a paper distributed under the terms of the Creative Commons Attribution License (http://creativecommons.org/licenses/by/3.0), which permits unrestricted use, distribution, and reproduction in any medium, provided the original work is properly cited.

high cost and non-predictive outcome [10]. According to the Canadian Joint Replacement Registry, a total of 97,671 patients had different joint replacements between years 2007-2010 [11].It has been reported that about 10% showed foreign body response to TMJ metal replacement with allergic reaction to metal [12]. Consequently, developing effective methods to replace articular condyle are of paramount importance to current/modern society. This book chapter discusses in detail contemporary methods and future directions of mandibular condylar reconstruction.

3. Mesenchymal stem cells

Mesenchymal stem cells (MSCs) are increasingly being used in joint tissue engineering research [13-19]. Tissue engineering ofmandibular condyle as a whole has been proposed in the literature; however an in-vivo utilization of this technique is in need of further investigation based upon compelling evidence from pilot data [15-22]. Some limitations to MSCs based therapy include the extended time needed in the laboratory to expand them and differentiate them into chondrogenic and osteogenic lineages. An improved approach to enhance the expansion and differentiation of MSCs is highly demanded. Also, understanding MSCs differentiation process and their characterization must be achieved before they can be used safely and effectively in articular joint replacement.

The current approach used to tissue engineer articular constructs involves conditioning with some type of mechanical stress. Existing mechanical conditioning techniques to enhance engineered tissues are in the form of bioreactors, BioFlex mechanical modulation technologies (Flexercell), and Instron machines. However, these approaches are short of clinical application should the engineered tissue require more mechanical modulation after in-vivo implantation for functional use.

4. Low intensity pulsed ultrasound

Low intensity pulsed ultrasound (LIPUS) therapy stimulates stem cell growth and differentiation [20,23-24]. We have shown in a pilot study in rabbits that LIPUS may enhance tissue engineered mandibular condyles. This compelling preliminary data needs to be validated in a statistically determined study design. Moreover, there is increasing supporting data in the literature that the stimulatory effect of LIPUS on cell expansion and differentiation is dose dependent. The LIPUS is considered the preferred method of mechanical stimulation, also known as “preferred bioreactor” [25].

5. Articular condyle

An articular condyle consists of articular cartilage and subchondral bone (Fig. 1) [20]. Despite a common developmental origin from mesenchyme, the articular cartilage and subchondral

http://dx.doi.org/10.5772/54875

bone have two distinct adult tissue phenotypes with few common morphological features. However, both tissues are structurally integrated and function in harmony to withstand mechanical loading up to several times the body's weight [26].

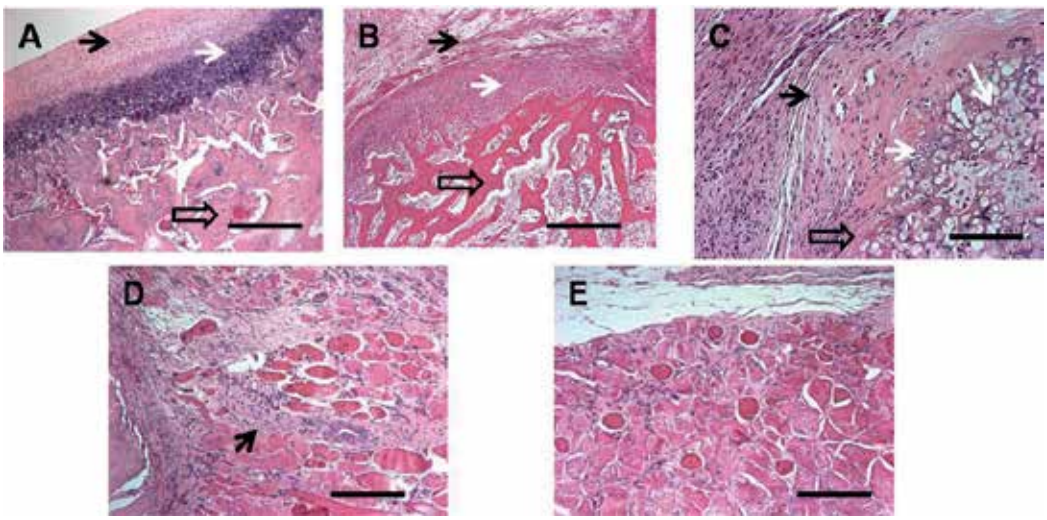

Figure 1. Photomicrographs of the histological examination of normal condyle showing fibrocartilage (black arrow) hypertrophic zone (white arrow) and subchondoral bone (hollow arrow) (Bar =100 µm)[20].

In osteochondral defects, bone regeneration can readily occur in the presence of an adequate blood supply up to a certain bony defect size. In contrast, articular cartilage has a poor capacity for self-regeneration. Furthermore, once articular cartilage is damaged, it undergoes degenerative events such as loss and/or destruction of key structural components, including type II collagen and proteoglycans. The poor capacity of cartilage for self-regeneration is likely attributed to the paucity of tissue-forming cells (i.e., chondrocytes) [27] and the lack of access to systemically available mesenchymal stem cells because the cartilage tissue is avascular. Thus, the self-regenerating capacity of articular cartilage is limited due to the sparsely available chondroprogenitor cells and/or the scant local mesenchymal stem cells that are habitual residents. Importantly, the articular cartilage is devoid of a nerve supply. Thus, articular cartilage injuries are often not accompanied by joint pain until the damage has progressed to involve the subchondral bone, which contains rich nerve supply [28]. In many of these disorders, structural damage of the TMJ necessitates surgical replacement.

6. TMJ replacement

The current TMJ replacement techniques utilize bone/cartilage grafts, muscles and artificial materials [9, 29-30]. Despite certain level of reported clinical success, autografts are associated with donor site morbidity such as discomfort in ambulation, sensorial loss over the donor

region, scars, and contour deformity when bone is harvested from the iliac bone. Also, predictability of clinical outcome of autografts is reported to be substandard with graft overgrowth in 10% of patients and undergrowth in 57% of patients, and a relatively high incidence of re-operation with 23% of patients requiring re-grafting [31-34].Alternatively, alloplastic and xenoplastic grafts are associated with potential transmission of pathogens and immunorejection [35-37].The failure rate of using alloplastic grafts to reconstruct the TMJ has been reported to reach 30% [38]. To date, there is no consistent clinically-effective and safe method to replace the TMJ or mandibular condyle.

7. Biological replacement of mandibular condyle

Biological replacement efforts for reconstruction of the mandibular/articular condyles have included using osteoblasts and chondroblasts/chondrogenic cells from different tissue/cell sources [15-22,38-41]. However, these efforts have been limited by several obstacles including: a) scarcity of stem cells with the capacity to differentiate into chondrogenic and osteogenic cells, b) different bone ingrowth patterns [37], c) different rates of the scaffold degradation compared to matrix production [15], and d) inferior mechanical properties of the regenerative tissue for clinical use [40]. Moreover, the integration of tissue engineered constructs for osteochondral repair requires an inordinate amount of time (3-6 months in rabbit femur heads [21],6-12 months in horses [41], and up to 9 months in sheep [19]). Regeneration of articular joints utilizing a cell-free scaffold by cell homing to the area shows some success [18]. However, this process did not provide full articular condyle replacement. In addition, this proof of principle lasted 9 weeks to obtain some articular joint regeneration in rabbits, which translates to 9 to 12 months in humans, given the difference in metabolism between the two species [42]. This lengthy time of manipulation can be complicated by tissue culture problems such as infection. Another attempt to tissue engineer mandibular condyle using porcine stem cells demonstrated bone formation in-vitro; however there was no attempt or success in translating this technique into in-vivo utilization [43]. A similar recent study demonstrated the possibility of tissue engineering a complete mandibular condyle in-vitro; however in-vivo utilization of this technique has yet to be studied[44]. Interestingly, this study highlighted the importance of bioreactor in stem cell expansion and differentiation [44]. It was first reported that tissue engineered osteochondral constructs from MSCs can be shaped into human-size mandibular condyles while maintaining the shape and size after extended period of in-vivo implantation [15,17,18]. Not only these constructs demonstrate MSCs-driven formation of osteochondral tissue-like histologically, but also both tissue types showed good histological integration attributed to the use of the same scaffolding material in both layers, and thus avoiding the potential fibrous tissue infiltration between the two layers usually observed in composite constructs [15,17,18].Our team was the first to report on the possibility of engineering condyles from stem cells [15,17,18] (Figure 2).

http://dx.doi.org/10.5772/54875

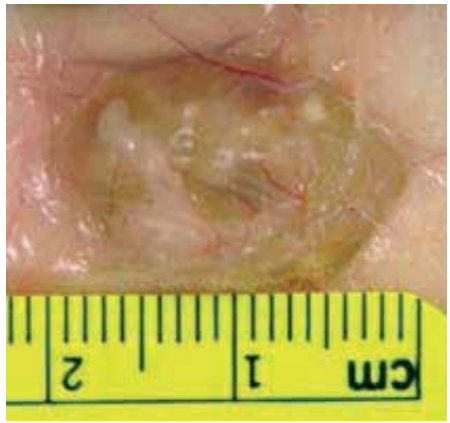

Figure 2. Appearance of a tissue engineered osteochondral construct holding the shape and dimensions of a human mandibular condyle during harvest after 12 weeks of subcutaneous implantation in the dorsum of immunodeficient mouse.

Although most of the recent studies, including ours, are focused on engineering scaffolds in the shape of mandibular or articular condyles [15,17,18,44], future research is needed to implement tissue engineered condyles into clinical application and to demonstrate functional integration. It is well known that inadequate mechanical strength is considered a major impediment to cartilage tissue engineering [45,46]. The material properties of tissue-engineered cartilage constructs are in the range of kilopascals [47], which are orders of magnitude lower than normal articular cartilage (in the range of megapascals) [48-53]. Different techniques have attempted to improve the quality of tissue-engineered articular joints. Pulsed electromagnetic fields (PEMF) have been shown to increase chondrocyte and osteoblast-like cell proliferation [54,55]. Bioreactors including LIPUS enhance the material properties of tissue-engineered cartilage constructs [25,56,57]. Cyclic compressive loading induces phenotypic changes in cartilaginous and osseous tissues in cell culture, scaffolds, and in-vivo [58-70]. Also, mechanical stimulation enhances the expression of vascular endothelial growth factor (VEGF) which is important for angiogenesis and bone formation in the mandibular condyles [71]. These important discoveries support the potential for clinical application of different forms of mechanical stimulation to enhance tissue-engineered joint tissues.

8. Low intensity pulsed ultrasound (LIPUS)

Low intensity pulsed ultrasound (LIPUS) is a form of mechanical stimulation that has been used to enhance healing of fractured bone and other tissues. Details about the current literature and the potential use of LIPUS for better autologous stem cell based mandibular condyle (ASCMC) will be discussed below. It is clear that there is a vital need for an approach to enhance stem cell expansion and differentiation for tissue engineering of articular condyles. LIPUS can be an effective tool to enhance tissue-engineering of mandibular condyles for many reasons.

Importantly, LIPUS is the preferred method of mechanical stimulation, also reported as "preferred bioreactor" [25] as it enhances angiogenesis [20, 72-76].This is especially relevant because vasculature is required to integrate the engineered tissue with the native surrounding tissues [77]. Recent studies showed that LIPUS enhances stem cell expansion and differentiation in tissue culture [78,79]. Also, LIPUS has been shown to enhance periosteal cell expansion [79] and stimulate bone marrow stem cells (BMSCs) expansion and differentiation into chondrogenic lineage [78,80-83].The matrix production and proliferation of the intervertebral disc cells in culture has been shown to be enhance by LIPUS [82]. In addition, LIPUS enhances osteoblast matrix formation [796,83] and minimizes apoptosis of human stem cells in-vitro [84]. The optimum LIPUS application time in bone fracture healing has been identified [85]; however, the optimum LIPUS treatment timing in articular condyle replacement is yet to be studied.Despite recent studies that have shown that the stimulatory effect of LIPUS in tissue culture is dose-dependent (treatment time) [23,24,75,78,86-88], the use of LIPUS has not resulted in any severe adverse events in tissue culture [88], human or animal models [89-92]. Our research has demonstrated that LIPUS can enhance stem cell expansion in monolayers [20-23-24] (Figure 3).There was an increase in cell number after LIPUS application for 20 minutes per day for 3 weeks. A future projectcan aim to optimize using LIPUS to enhance cell proliferation to a significant level that may justify its routine use in tissue engineering.

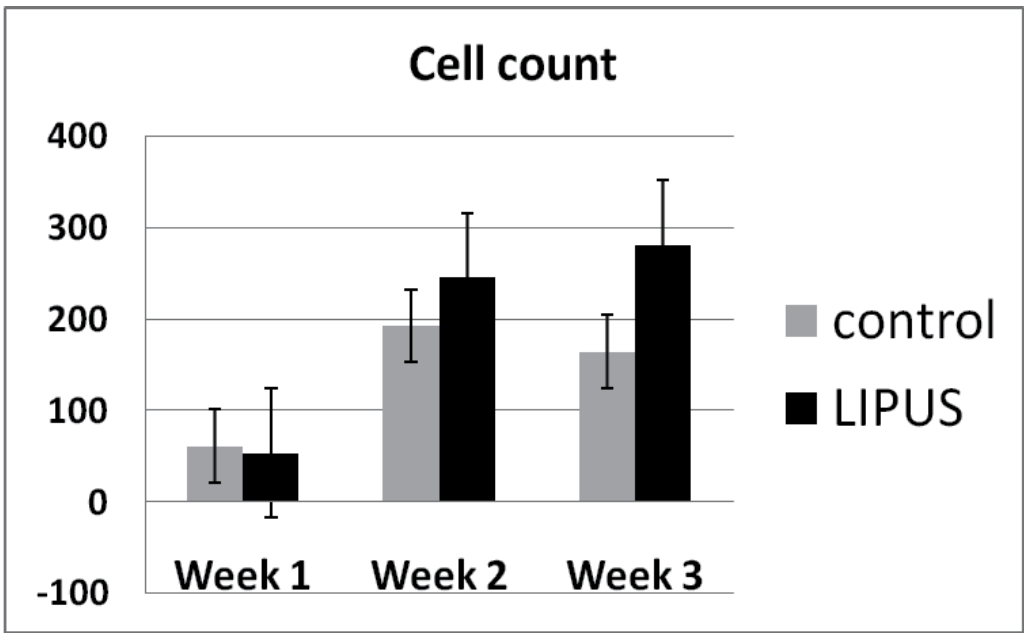

Figure 3. Rat BMSC count after treatment with 20 minutes per day for three weeks.It can be seen that LIPUS enhances cell count compared to untreated BMSCs by (20 minutes per day for three weeks). This reflects that LIPUS stimulates BMSC expansion and this stimulatory effect is treatment time-dependent. This experiment was performed three times and the presented data represents the average and standard error of nine samples [three trials in triplicate]. There is a significant difference in cell number at week 3 between the control and LIPUS treated BMSCs ($P<0.05$) [23].

http://dx.doi.org/10.5772/54875

In addition, LIPUS enhances expression of bone morphogenetic proteins from pluripotent cells [88]. Moreover, we have shown that LIPUS application for 20 minutes per day for 4 weeks increased the expression of collagen II and osteopontin expression in osteogenic-induced differentiation of stem cells (P<0.05)[Figure 4 and Table A] [20].

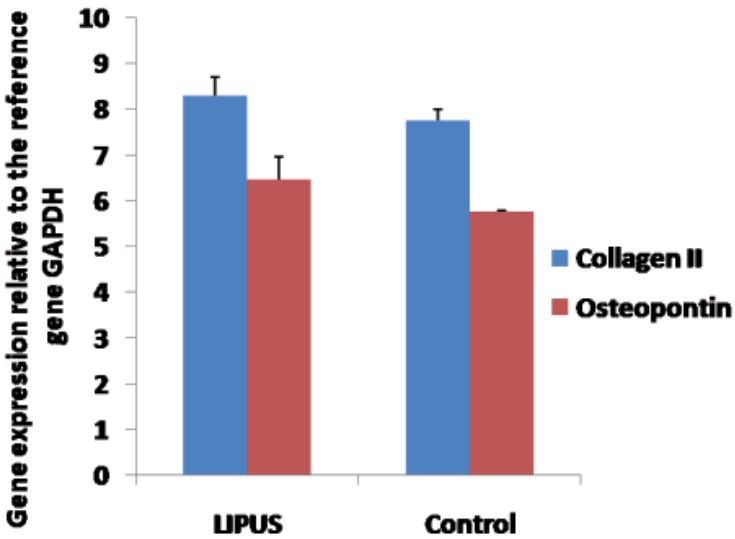

Figure 4. qPCR results of LIPUS treated (20 minutes/day) osteogenic differentiated BMSCs for four weeks and controls. LIPUS treated osteogenic cells expressed more osteopontin and collagen type II genes (normalized to GAPDH) which is indicative of enhancing osteogenic differentiation of BMSCs affected by LIPUS. Both graphs represent results of performing qPCR on nine samples (three trials in triplicate). This increase in Collagen II and Osteopontin by LIPUS is statistically significant (P< 0.005)[20].

Gene of interest	Average + Standard deviation		P
	LIPUS	Control	
Collagen II	8.3 + 0.4	6.4 + 0.5	0.009*
Osteopontin	7.7 + 0.02	5.7 + 0.3	0.004*

Table 1. Collagen II and osteopontin gene expression in vitro as evaluated by qPCR. Gene expression is presented as percentage to the reference gene GAPDH. Non parametric analysis (Mann-Whitney U) shows a statistical significant increase in Collagen II and Osteopontin gene expression by LIPUS when compared to non LIPUS treated samples [20].

Also, LIPUS application to gingival stem cells statistically increased the gene expression of alkaline phosphatase (ALP) in tissue culture (Figure 5) [88].

Figure 5.Alkaline phosphatase (ALP) gene expression was increased by daily treatment of GFs with 10 minutes LIPUS for 4 weeks as evaluated by qPCR. Data represents average of five replicates with the error bar representing standard deviation [885].

Our preliminary data indicated that LIPUS application enhanced osteogenic and chondrogenic differentiation of bone marrow stem cells in collagen sponges in-vitro (Figure 6) as determined by histochemical staining (safranin O for chondrogenic differentiation and von Kossa staining for osteogenic differentiation) [20].

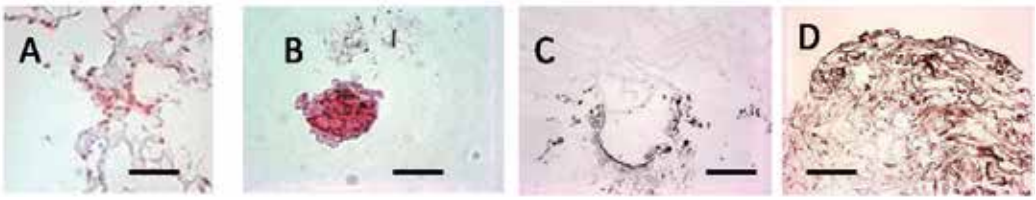

Figure 5. In-vitro chondrogenesis and osteogenesis of BMSCs in samples of collagen scaffolds. A: Positive reaction to safranin O (red staining) of BMSC-derived chondrogenic cell chondrogenic tissue formation in the control [no LIPUS] scaffolds following four-week treatment with chondrogenic medium, B: Increased (red staining) positive reaction to safranin O of the BMSC-derived chondrogenic cells treated with LIPUS and chondrogenic medium for four weeks. C: Positive but weak reaction to Von Kossa silver staining (black staining) of BMSC-derived osteogenic cells in the control [no LIPUS] scaffolds following four-week treatment with osteogenic medium. D: Increased positive reaction to Von Kossa silver staining (black staining) of the BMSC-derived chondrogenic cells treated with LIPUS treatment and osteogenic medium for four weeks. More mineralization nodules are observed with LIPUS treatment. Bar is 100 μm [20].

Finally, we have shown that LIPUS enhances tissue-engineered mandibular condyles in a pilot study invivo [20](Figures 7-13). This was confirmed qualitatively by MicroCT scanning, histological evaluations (safranin O and Von Kossa staining) (Figures 9-12) as well as quantitatively by histomorphometric analysis (Figure 13).

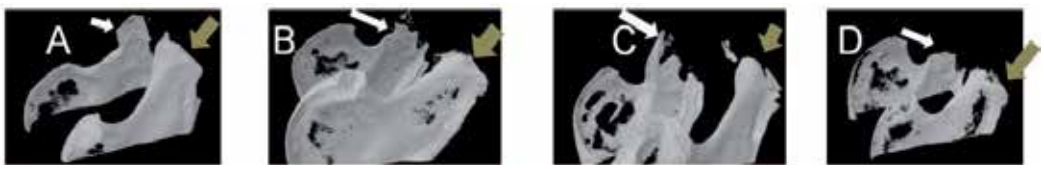

Figure 6. MicroCT scanning of: (A) Group 1 (TEMC + LIPUS); (B) Group 2 (TEMC no LIPUS) (C) Group 3 (scaffold with no cells + LIPUS) and (D) scaffold with no cells and with no LIPUS. In each rabbit, the yellow arrow refers to normal condyle and the white arrow refers to the experimental site (either TEMC or empty scaffold). It can be seen that LIPUS enhanced TEMC as indicated by close morphology of the LIPUS-assisted TEMC compared to the normal condyle (A). The condylar healing was not as pronounced when there were cells present in the scaffold but no LIPUS was applied (B). LIPUS did enhance some healing of the amputated condyle site even without a scaffold (C). The negative control (empty scaffold and no LIPUS) showed no signs of healing (D). Note: TEMC consisted of a scaffold and chondrogenic and osteogenic cells [20].

http://dx.doi.org/10.5772/54875

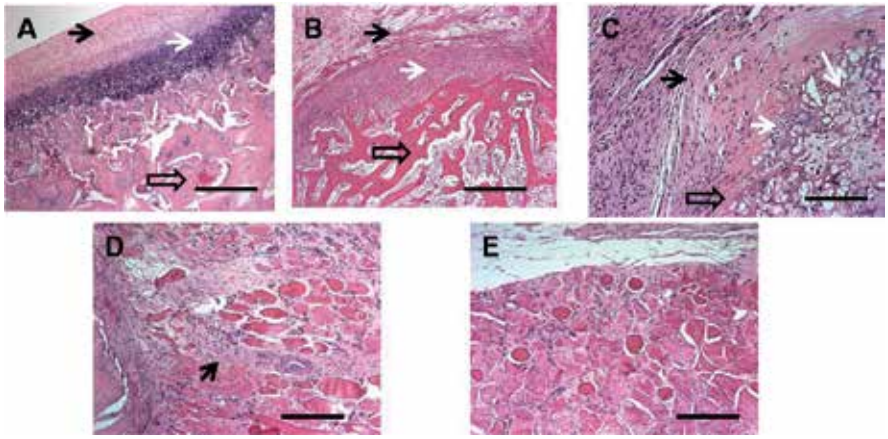

Figure 7. Photomicrographs of the histological examination of (A) normal condyle; (B) LIPUS-assisted TEMC in group 1; (C) TEMC with no LIPUS; (D) empty scaffold with LIPUS; and (E) empty scaffold without LIPUS. The LIPUS-enhanced TEMC (B) has comparable histological features to the normal condyle (A), and TEMC without LIPUS (C) shows some structural integration between the chondrogenic and osteogenic parts of the TEMCs. The empty scaffolds (D, E) show inflammatory cell invasion without bone or cartilage formation. Black arrows refer to fibrocartilage area, white arrows refer to condylarcartilage or new cartilage formed by TEMC areas, and empty arrows refer to condylar bone or new bone formed by the TEMC. Scale bar: 100 mm [20].

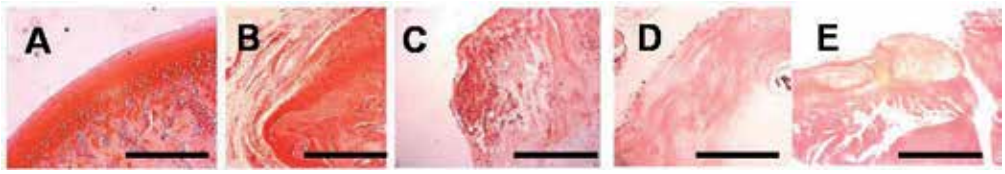

Figure 8. Photomicrographs of safranin O stained histological slides of (A) normal condyle; (B) LIPUS assisted TEMC; (C) TEMC with no LIPUS; (D) Empty scaffold with LIPUS; and (E) empty scaffold without LIPUS. It can be seen that the cartilaginous part of the normal condyle and TEMC have comparable safranin O staining that indicates improved chondrogenesis with LIPUS compared to either empty scaffolds (D and E). TEMC with no LIPUS still shows some reaction to safranin O staining but not like TEMC and LIPUS (Magnification = 16 X) [20].

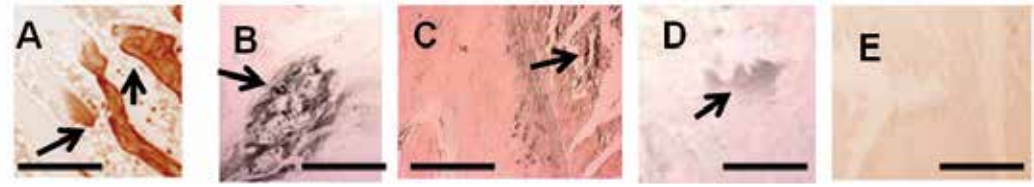

Figure 9. Photomicrographs of Von Kossa stained histological slides of (A) Normal condyle; (B) LIPUS assisted TEMC; (C) TEMC with no LIPUS; (D) Empty scaffold with LIPUS and (E) Empty scaffold without LIPUS.LIPUS assisted TEMC and normal condyle show comparable Von Kossa silver staining of the bone underlying the cartilage/chondrogenic part of the condyle/TEMC. In empty scaffold implanted condyles, minimum or no mineralization nodules can be seen by Von Kossa silver staining. Bar is 100 μm [20].

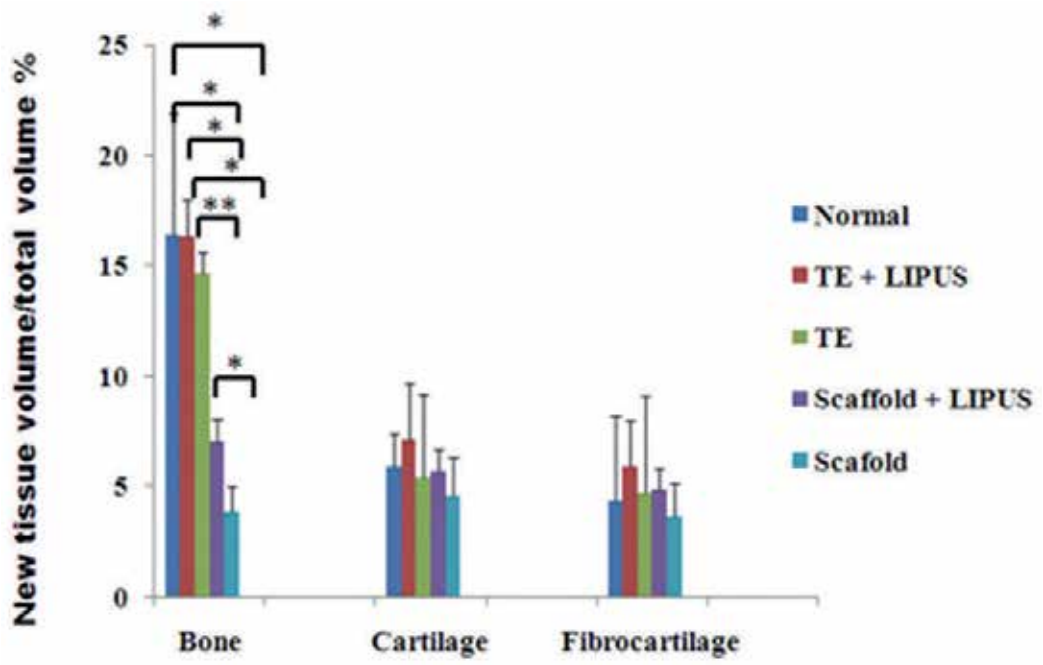

Figure 10. Histomorphomteric Analysis of the TEMC + LIPUS or empty scaffolds + LIPUS [20].



Figure 11. A: Rabbits after condylectomy [white arrow indicates condylectomy site]. B: Condyle after dissection [white arrow refers to the cartilage part and black arrow refers to the bony part of the condyle], C: Collagen sponge containing chondrogenic [white arrow] and osteogenic [black arrow] cells; D: TEMC [black arrow] fixed in place with white bone cement [white arrow]. (Photos from pilot study [20])

Figure 12. LIPUS: application to the rabbit while it is restrained [20].

8.1. Mechanical stress and intracellular signaling

There is growing evidence in the literature that integrins are promising candidates for sensing extracellular matrix-derived mechanical stimuli and converting them into biochemical signals [93-96]. Integrin-associated signaling pathways include an increase in tyrosine phosphorylation of several signaling proteins, activation of serine/threonine kinases, and alterations in cellular phospholipid and calcium levels [97-98]. These events are associated with the formation of focal adhesions, which contain structural proteins such as Src, and Shc. Focal adhesions act as a bridge to link integrin cytoplasmic domain to the cytoskeleton and activate integrin-associated signaling pathways, such as the mitogen-activated protein kinase (MAPK) pathway [99] and the Rho pathway [100-101]. Rho and its downstream target Rho kinase/Rho-associated coiled-coil-containing protein kinase (ROCK) [102] are involved in the reorganization of cytoskeletal components [99], [102-103]. It has been recently reported that β1 integrin plays predominant roles for shear-induced signaling and gene expression in osteoblast-like MG63 cells on FN, COL1, and Laminin (LM) and that αvβ3 also plays significant roles for such responses in cells on fibronectin (FN). The β1 integrin-Shc association leads to the activation of ERK, which is critical for shear induction of bone formation-related genes in osteoblast-like cells [103]. Moreover, α5β1 integrin is expressed by chondrocytes [104] and it plays an important role in mechanically enhanced cartilage tissue engineering. Furthermore, integrins were found to be responsible for ultrasound-induced cell proliferation. It has been suggested that integrins act as mechanotransducers to transmit acoustic pulsed energy into intracellular biochemical signals inducing cell proliferation [105]. It has been reported recently that LIPUS activates the phosphatidylinositol 3 kinase/Akt pathway and stimulates the growth of chondrocytes [106] as well as increases FAK, ERK-1/2, and IRS-1 expression of intact rat bone cells [107]. This has yet to be investigated in MSC derived chondrocytes and in osteoblasts-like cells.

9. Conclusion

The literature supports that mechanical stress, for example LIPUS have a stimulatory effect on stem cell expansion and differentiation as well as enhancing stem cell matrix production in-

vitro and in a pilot study in-vivo in rabbits. However, these results need to be validated in a large scale in-vivo.We are now poised to prove these effects in a large scale study. Although the optimum mechanical stimulation, for example LIPUS treatment time, for bone fracture healing is well documented, the corollary for enhancing autologous stem cell based replacement of mandibular condyles has not been investigated. This represents a major gap of knowledge in the field of tissue engineering considering the numerous positive utilizations of mechanical stimulation as well as LIPUS reported in the literature. Overall, the current literature and knowledge developed through our and others' research has the potential to increase our understanding of the details of LIPUS induced chondrogenesis and osteogenesis and how to utilize LIPUS to enhance articular joint replacement using MSCs. Furthermore, this knowledge could give rise to a novel cell-based therapy for replacement of mandibular condyles as well as other tissue types.

Acknowledgements

This work is sponsored by King Saud University, Riyadh, Saudi Arabia

Author details

Tarek El-Bialy[1*] and Adel Alhadlaq[2]

*Address all correspondence to: telbialy@ualberta.ca; aalhadlaq@hotmail.com

1 Faculty of Medicine and Dentistry, 7-020D Katz Group Centre for Pharmacy and Health Research, University of Alberta, Edmonton, Alberta, Canada

2 College of Dentistry, King Saud University, Riyadh, Saudi Arabia

References

[1] Health C. Health Canada; Economic Impact of Illness in Canada. Ottawa: Public Works and Government Services Canada.Catalogue # H21-136/1998E, 2002. 1998. Ref Type: Internet Communication

[2] Statistics C. Canadian Community Health Survey (CCHS). Public Health Agency of Canada http:,www.phac-aspc.gc.ca/publicat/ac/ac_3e-eng.php, editors. 2000. Ref Type: Internet Communication.

[3] Ribeiro RF, Tallents RH, Katzberg RW, Murphy WC, Moss ME, Magalhaes AC, Tavano O. The prevalence of disc displacement in symptomatic and asymptomatic volunteers aged 6 to 25 years. J Orofac Pain 11:37-47, 1997.

[4] Ferrari R, Leonard MS. Whiplash and temporomandibular disorders: a critical review. J Am Dent Assoc 129:1739-1745,1998.

[5] Israel HA, Diamond B, Saed-Nejad F, Ratcliffe A. Osteoarthritis and synovitis as major pathoses of the temporomandibular joint: comparison of clinical diagnosis with arthroscopic morphology. J Oral Maxillofac Surg 56:1023-1027, 1998.

[6] Sano T, Westesson PL, Larheim TA, Rubin SJ, Tallents RH. Osteoarthritis and abnormal bone marrow of the mandibular condyle. Oral Surg Oral Med Oral Pathol Oral RadiolEndod 87:243-252, 1999.

[7] Stohler CS (1999) Muscle-related temporomandibular disorders. J Orofac Pain 13:273-284,1999. Goddard G, Karibe H. TMD prevalence in rural and urban Native American populations. Cranio 20:125-128, 2002.

[8] Bell RB, Blakey GH, White RP, Hillebrand DG, Molina A. Staged reconstruction of the severely atrophic mandible with autogenous bone graft and endosteal implants. J Oral Maxillofac Surg 60:1135-1141, 2002.

[9] Henning TB, Ellis E 3rd, Carlson DS. Growth of the mandible following replacement of the mandibular condyle with the sternal end of the clavicle: an experimental investigation in Macacamulatta. J Oral Maxillofac Surg 50:1196-1206, 1992.

[10] Westermark A, Koppel D, Leiggener C.: Condylar replacement alone is not sufficient for prosthetic reconstruction of the temporomandibular joint. Int J Oral Maxillofac Surg. 2006 Jun;35(6):488-92.

[11] Data Quality Documentation for Users: Canadian Joint Replacement Registry, 2007–2008 to 2009–2010 Data. http://secure.cihi.ca/cihiweb/products/DQ_CJRR_2007-2010_e.pdf. Ref Type: Internet Communication

[12] Sidebottom AJ, Speculand B, Hensher R.: Foreign body response around total prosthetic metal-on-metal replacements of the temporomandibular joint in the UK. Br J Oral Maxillofac Surg. 2008 Jun;46(4):288-92.

[13] Chen FH, Tuan RS. Mesenchymal stem cells in arthritic diseases. Arthritis Res Ther. 2008;10:223-235.

[14] Goldring MB. Are bone morphogenetic proteins effective inducers of cartilage repair? Ex vivo transduction of muscle-derived stem cells.[comment]. Arthritis & Rheumatism. 2006;54:387-389.

[15] Alhadlaq A, Mao JJ. Tissue-engineered Neogenesis of Human-shaped Mandibular Condyle from Rat Mesenchymal Stem Cells. J Dent Res 82:951-6, 2003.

[16] Alhadlaq A, Mao JJ. Mesenchymal stem cells: isolation and therapeutics. Stem Cells Dev 13:436-48, 2004.

[17] Alhadlaq A, Elisseeff J, Hong L, Williams C, Caplan AI, Sharma B, Kopher RA, Tomkoria S, Lennon DP, Lopez A, Mao JJ. Adult stem cell driven genesis of human-shaped articular condyle. Ann Biomed Eng 32:911-923, 2004.

[18] Alhadlaq A, Mao JJ.: Tissue-engineered osteochondral constructs in the shape of an articular condyle. J Bone Joint Surg Am 87:936-44, 2005.

[19] Pilliar RM, Kandel RA, Grynpas MD, Zalzal P, Hurtig M.: Osteochondral defect repair using a novel tissue engineering approach: sheep model study. Technol Health Care 15(1):47-56, 2007.

[20] El-Bialy, T., Uludag, H., Jomha, N., and Badylak, S.: In vivo ultrasound assisted tissue engineered mandibular condyle: a pilot study in rabbits. Tissue Eng Part C Methods (2010 Dec;16(6):1315-23).

[21] Lee, C.H., Cook, J.L., Mendelson, A., Moioli, E.K., Yao, H., Mao, J.J.: Regeneration of the articular surface of the rabbit synovial joint by cell homing: a proof of concept study. Lancet 376: 440–48, 2010.

[22] Shao X, Goh JC, Hutmacher DW, Lee EH, Zigang G.: Repair of large articular osteochondral defects using hybrid scaffolds and bone marrow-derived mesenchymal stem cells in a rabbit model. Tissue Eng 12(6):1539-51, 2006.

[23] Ang, W.T.; Yu,C.; Chen, J.; El-Bialy, T.H.; Doschak, M.; Uludag, H. and Tsui, Y.: System-on-chip Ultrasonic Transducer for Dental Tissue Formation and Stem Cell Growth and Differentiation, Proceeding of the IEEE, May, 2008.

[24] Aldosary, T.A.; Uludag, H.; Doschak, M.; Chen, J.; Tsui, Y. and EL-Bialy, T.: Effect of Ultrasound on Human Umbilical Cord Perivascular-Stem Cell Expansion. IADR, Toronto, July 2008, Abstract # 873.

[25] Marvel S, Okrasinski S, Bernacki SH, Loboa E, Dayton PA.: The development and validation of a LIPUS system with preliminary observations of ultrasonic effects on human adult stem cells. IEEE Trans UltrasonFerroelectrFreq Control. 2010 Sep;57(9): 1977-84.

[26] Martin, RB, Burr DB, and Sharkey NA. Skeletal Tissue Mechanics. New York: Springer-Verlag, 1998.

[27] Poole AR, Kojima T, Yasuda T, Mwale F, Kobayashi M, Laverty S.: Composition and structure of articular cartilage: a template for tissue repair.Clin Orthop Relat Res. 2001 Oct;(391 Suppl):S26-33.

[28] LeResche L. Epidemiology of temporomandibular disorders: implications for the investigation of etiologic factors. Crit Rev Oral Biol Med 8:291-305, 1997.

[29] MacIntosh RB. The use of autogenous tissues for temporomandibular joint reconstruction. J Oral MaxillofacSurg 58:63-69, 2000.

[30] Canter HI, Kayikcioglu A, Saglam-Aydinatay B, Kiratli PO, Benli K, Taner T, Erk Y.: Mandibular reconstruction in Goldenhar syndrome using temporalis muscle osteofascial flap. J Craniofac Surg. 2008 Jan;19(1):165-70.

[31] Dodson TB, Bays RA, Pfeffle RC, Barrow DL. Cranial bone graft to reconstruct the mandibular condyle in Macacamulatta. J Oral Maxillofac Surg 55:260-267, 1997.

[32] Wolford LM, Karras SC. Autologous fat transplantation around temporomandibular joint total joint prostheses: preliminary treatment outcomes. J Oral Maxillofac Surg 55:245-251, 1997.

[33] Wan DC, Taub PJ, Allam KA, Perry A, Tabit CJ, Kawamoto HK, Bradley JP. Distraction osteogenesis of costocartilaginous rib grafts and treatment algorithm for severely hypoplastic mandibles. PlastReconstr Surg. 2011 May;127(5):2005-13

[34] Mercuri LG. The use of alloplastic prostheses for temporomandibular joint reconstruction. J Oral Maxillofac Surg 58:70-75, 2000.

[35] Meyer RA. Costal cartilage for treatment of temporomandibular joint ankylosis. PlastReconstr Surg 109:2168-2169, 2002.

[36] van Minnen B, Nauta JM, Vermey A, Bos RR, Roodenburg JL. Long-term functional outcome of mandibular reconstruction with stainless steel AO reconstruction plates. Br J Oral Maxillofac Surg 40:144-148, 2002.

[37] Lindqvist C, Söderholm AL, Hallikainen D, Sjövall L. : Erosion and heterotopicbone formation afteralloplastic temporomandibular joint reconstruction. J Oral Maxillofac Surg. 1992 Sep;50(9):942-9;

[38] Poshusta AK, Anseth KS. Photopolymerized biomaterials for application in the temporomandibular joint. Cells Tissues Organs 169:272-278, 2001.

[39] Springer IN, Fleiner B, Jepsen S, Acil Y. Culture of cells gained from temporomandibular joint cartilage on non -absorbable scaffolds. Biomaterials 22:2569-2577, 2001.

[40] Chu TM, Orton DG, Hollister SJ, Feinberg SE, Halloran JW. Mechanical and in vivo performance of hydroxyapatite implants with controlled architectures. Biomaterials 23:1283-1293, 2002.

[41] Barnewitz D, Endres M, Krüger I, Becker A, Zimmermann J, Wilke I, Ringe J, Sittinger M, Kaps C.: Treatment of articular cartilage defects in horses with polymer-based cartilage tissue engineering grafts. Biomaterials 27(14):2882-9, 2006.

[42] Losken, A.; Mooney, M.P., and Siegel, M.I.: A comparative study of mandibular growth patterns in seven animal models. J. Oral MAxillofac. Surg., 50: 490-495; 1992.

[43] Abukawa H, Terai H, Hannouche D, Vacanti JP, Kaban LB, Troulis MJ.: Formation of a mandibular condyle in vitro by tissue engineering. J Oral Maxillofac Surg. 2003 Jan; 61(1):94-100.

[44] Grayson WL, Fröhlich M, Yeager K, Bhumiratana S, Chan ME, Cannizzaro C, Wan LQ, Liu XS, Guo XE, Vunjak-Novakovic G. Engineering anatomically shaped human bone grafts.: ProcNatlAcad Sci U S A. 2010 Feb 23;107(8):3299-304. Epub 2009 Oct 9.

[45] Mow VC, Wang CC.: Some bioengineering considerations for tissue engineering of articular cartilage. Clin Orthop Relat Res (367 Suppl):S204-23, 1999.

[46] Sikavitsas VI, Temenoff JS, Mikos AG. Biomaterials and bone mechanotransduction. Biomaterials 22:2581-2593, 2001.

[47] LeBaron RG, Athanasiou KA. Ex vivo synthesis of articular cartilage. Biomaterials 21:2575-2587, 2000.

[48] Patel RV, Mao JJ.: Microstructural and elastic properties of the extracellular matrices of the superficial zone of neonatal articular cartilage by atomic force microscopy. Front Biosci 8:a18-25, 2003.

[49] Cohen B, Chorney GS, Phillips DP, Dick HM, Buckwalter JA, Ratcliffe A, Mow VC. The microstructural tensile properties and biochemical composition of the bovine distal femoral growth plate. J Orthop Res 10:263-275, 1992.

[50] Hu K, Radhakrishnan P, Patel RV, Mao JJ. Regional structural and viscoelastic properties of fibrocartilage upon dynamic nanoindentation of the articular condyle. J Struct Biol 136:46-52, 2001.

[51] Narmoneva DA, Wang JY, Setton LA. Nonuniform swelling-induced residual strains in articular cartilage. J Biomech 32:401-8, 1999.

[52] Clark PA, Rodriguez T, Sumner DR, Clark AM, Mao JJ. Micromechanical analysis of bone-implant interface using atomic force microscopy. Proceedings of BMES-IEEE 16:304-305, 2002.

[53] Goldstein SA. Tissue engineering: functional assessment and clinical outcome. Ann N Y Acad Sci 961:183-192, 2002.

[54] De Mattei M, Caruso A, Pezzetti F, Pellati A, Stabellini G, Sollazzo V, Traina GC.: Effects of pulsed electromagnetic fields on human articular chondrocyte proliferation. Connect Tissue Res. 42:269-79, 2001.

[55] Hartig M, Joos U, Wiesmann HP.: Capacitively coupled electric fields accelerate proliferation of osteoblast-like primary cells and increase bone extracellular matrix formation in vitro. Eur Biophys J. 29:499-506, 2000

[56] Pei M, Solchaga LA, Seidel J, Zeng L, Vunjak-Novakovic G, Caplan AI, Freed LE. Bioreactors mediate the effectiveness of tissue engineering scaffolds. FASEB J 16:1691-1694, 2002.

[57] Gemmiti CV, Guldberg RE.: Fluid Flow Increases Type II Collagen Deposition and Tensile Mechanical Properties in Bioreactor-Grown Tissue-Engineered Cartilage. Tissue Eng. 12:469-79, 2006.

[58] Vance J, Galley S, Liu DF, Donahue SW.: Mechanical stimulation of MC3T3 osteoblastic cells in a bone tissue-engineering bioreactor enhances prostaglandin E2 release. Tissue Eng. 11:1832-9, 2005.

[59] El Haj AJ, Wood MA, Thomas P, Yang Y.: Controlling cell biomechanics in orthopaedic tissue engineering and repair. Pathol Biol (Paris). 53:581-9, 2005.

[60] Janssen FW, Oostra J, Oorschot A, van BlitterswijkCA.: A perfusion bioreactor system capable of producing clinically relevant volumes of tissue-engineered bone: in vivo bone formation showing proof of concept. Biomaterials. 27:315-23, 2006.

[61] Stevens MM, Marini RP, Schaefer D, Aronson J, Langer R, Shastri VP.: In vivo engineering of organs: the bone bioreactor. ProcNatlAcad Sci U S A. 9;102:11450-5, 2005.

[62] Service RF.: Tissue engineering. Technique uses body as 'bioreactor' to grow new bone. Science.309:683, 2005.

[63] Vunjak-Novakovic G, Meinel L, Altman G, Kaplan D.: Bioreactor cultivation of osteochondral grafts. Orthod Craniofac Res. 8:209-18, 2005.

[64] Haasper C, Colditz M, Kirsch L, Tschernig T, Viering J, Graubner G, Runtemund A, Zeichen J, Meller R, Glasmacher B, Windhagen H, Krettek C, Hurschler C, Jagodzinski M.: A system for engineering an osteochondral construct in the shape of an articular surface: Preliminary results. Ann Anat. 2008;190(4):351-9. Epub 2008 Mar 18.

[65] Davisson T, Kunig S, Chen A, Sah R, Ratcliffe A. Static and dynamic compression modulate matrix metabolism in tissue engineered cartilage. J Orthop Res 20:842-848, 2002.

[66] Mizuno S, Tateishi T, Ushida T, Glowacki J. Hydrostatic fluid pressure enhances matrix synthesis and accumulation by bovine chondrocytes in three-dimensional culture. J Cell Physiol 193:319-327, 2002.

[67] Elder SH, Goldstein SA, Kimura JH, Soslowsky LJ, Spengler DM. Chondrocyte differentiation is modulated by frequency and duration of cyclic compressive loading. Ann Biomed Eng 29:476-482, 2001.

[68] Huang CY, Hagar KL, Frost LE, Sun Y, Cheung HS.: Effects of cyclic compressive loading on chondrogenesis of rabbit bone-marrow derived mesenchymal stem cells. Stem Cells. 22:313-23, 2004.

[69] Butler DL, Juncosa-Melvin N, Boivin GP, Galloway MT, Shearn JT, Gooch C, Awad H. Functional tissue engineering for tendon repair: A multidisciplinary strategy using mesenchymal stem cells, bioscaffolds, and mechanical stimulation. J Orthop Res. 2008 Jan;26(1):1-9

[70] Kinneberg KR, Nirmalanandhan VS, Juncosa-Melvin N, Powell HM, Boyce ST, Shearn JT, Butler DL. Chondroitin-6-sulfate incorporation and mechanical stimulation increase MSC-collagen sponge construct stiffness. J Orthop Res. 2010 Aug;28(8): 1092-9.

[71] Rabie ABM, Shum L, Chayanupatkul A. VEGF and bone formation in the glenoid fossa during forward mandibular positioning.Am J Orthod Dentofacial Orthop. 2002;122:202–209.

[72] Young SR, Dyson M. The effect of therapeutic ultrasound on angiogenesis. Ultrasound Med Biol. 1990;16:261–269.

[73] El-Bialy T, El-Shamy I, Graber TM, Growth modification of the rabbit mandible using therapeutic ultrasound: is it possible to enhance functional appliance results?, Angle Orthod; 73:631-639, 2003.

[74] El-Bialy, T.H., Hassan, A., Albaghdadi, T., Fouad, H.A., and Maimani, A.R., Growth modification of the mandible using Ultrasound in baboons: A preliminary report, Am J Orthod Dentofacial Orthop, 130(4);435e7-14, 2006.

[75] El-Bialy TH, Royston TJ, Magin RL, Evans CA, Zaki Ael-M, Frizzell LA, The effect of pulsed ultrasound on mandibular distraction. Ann Biomed Eng;30:1251-61, 2002.

[76] Peter J. Yang, Johnna S. Temenoff. Engineering Orthopedic Tissue Interfaces. Tissue Eng Part B Rev. 2009 June; 15(2): 127–141.

[77] Yoon JH, Roh EY, Shin S, Jung NH, Song EY, Lee DS, Han KS, Kim JS, Kim BJ, Jeon HW, Yoon KS.: Introducing pulsed low-intensity ultrasound to culturing human umbilical cord-derived mesenchymal stem cells. Biotechnol.Lett. 2009 Mar;31(3):329-335.

[78] Schumann D, Kujat R, Zellner J, Angele MK, Nerlich M, Mayr E, Angele P.: Treatment of human mesenchymal stem cells with pulsed low intensity ultrasound enhances the chondrogenic phenotype in vitro. Biorheology. 2006;43(3-4):431-43.

[79] Leung KS, Cheung WH, Zhang C, Lee KM, Lo HK.: Low intensity pulsed ultrasound stimulates osteogenic activity of human periosteal cells. Clin Orthop Relat Res.(418): 253-9, 2004.

[80] Ebisawa K, Hata K, Okada K, Kimata K, Ueda M, Torii S, Watanabe H.: Ultrasound enhances transforming growth factor beta-mediated chondrocyte differentiation of human mesenchymal stem cells. Tissue Eng. 10(5-6):921-9, 2004.

[81] Cui JH, Park K, Park SR, Min BH.: Effects of low-intensity ultrasound on chondrogenic differentiation of mesenchymal stem cells embedded in polyglycolic acid: an in vivo study. Tissue Eng. 12:75-82, 2006.

[82] Iwashina T, Mochida J, Miyazaki T, Watanabe T, Iwabuchi S, Ando K, Hotta T, Sakai D.: Low-intensity pulsed ultrasound stimulates cell proliferation and proteoglycan

production in rabbit intervertebral disc cells cultured in alginate. Biomaterials. 27:354-61, 2006.

[83] Naruse K, Miyauchi A, Itoman M, Mikuni-Takagaki Y.: Distinct anabolic response of osteoblast to low-intensity pulsed ultrasound. J Bone Miner Res 18:360-9, 2003.

[84] Lee, H.J. Choi, BH, Min, BH and Park, S.R. Low-Intensity Ultrasound Inhibits Apoptosis and Enhances Viability of Human Mesenchymal Stem Cells in Three-Dimensional Alginate Culture During Chondrogenic Differentiation: Tissue Engineering, 13: (5) 1049-1057, 2007.

[85] Tsai CL, Chang WH, Liu TK.: Preliminary studies of duration and intensity of ultrasonic treatments on fracture repair. Chin J Physiol. 1992;35(1):21-6. Erratum in: Chin J Physiol;35:168, 1992.

[86] El-Bialy, T., Hassan, A.H., Alyamani, A. and Albaghdadi, T.: Treatment of Hemifacial Microsomia by therapeutic ultrasound and hybrid functional appliance. A non-surgical approach. Open Access Journal of Clinical Trials, 2, 29-36, 2010.

[87] Chan CW, Qin L, Lee KM, Cheung WH, Cheng JC, Leung KS.: Dose-dependent effect of low-intensity pulsed ultrasound on callus formation during rapid distraction osteogenesis. J Orthop Res. 2006 Nov;24(11):2072-9.

[88] Mostafa, N.Z.; Uludag, H.; Dederich, D.N.; Doschak, M.R.; El-Bialy, T.H.: Anabolic Effects of Low Intensity Pulsed Ultrasound on Gingival Fibroblasts, Archives of Oral Biology, 54 (8), 7 43 - 7 48, 2009.

[89] Hata T, Aoki S, Manabe A, Hata K, Miyazaki K. Three dimensional ultrasonography in the first trimester of human pregnancy. Hum Reprod 1997;12:1800-4.

[90] Blaas HG, Eik-Nes SH. Advances in the imaging of the embryonic brain. Croat Med J 1998;39:128-31.

[91] Turnbull DH, Foster FS. In vivo ultrasound biomicroscopy in developmental biology. Trends Biotechnol 2002;20:S29-33.

[92] Mende U, Zoller J, Dietz A, Wannenmacher M, Born IA, Maier, H. Ultrasound diagnosis in primary staging of head-neck tumors. Radiologe 1996;36:207-16.

[93] Ingber DE.: Mechanosensation through integrins: cells act locally but think globally. 1: ProcNatlAcad Sci U S A. 2003 Feb 18;100(4):1472-4. Epub 2003 Feb 10.

[94] Giancotti FG, Ruoslahti E.: Integrin signaling. Science. 1999 Aug 13;285(5430): 1028-32.

[95] Aplin AE, Howe A, Alahari SK, Juliano RL.: Signal transduction and signal modulation by cell adhesion receptors: the role of integrins, cadherins, immunoglobulin-cell adhesion molecules, and selectins. Pharmacol Rev. 1998 Jun;50(2):197-263.

[96] Schlaepfer DD, Hunter T.: Integrin signalling and tyrosine phosphorylation: just the FAKs? Trends Cell Biol. 1998 Apr;8(4):151-7.

[97] Riveline D, Zamir E, Balaban NQ, Schwarz US, Ishizaki T, Narumiya S, Kam Z, Geiger B, Bershadsky AD.: Focal contacts as mechanosensors: externally applied local mechanical force induces growth of focal contacts by an mDia1-dependent and ROCK-independent mechanism. J Cell Biol. 2001 Jun 11;153(6):1175-86.

[98] Clark EA, King WG, Brugge JS, Symons M, Hynes RO.: Integrin-mediated signals regulated by members of the rho family of GTPases. J Cell Biol. 1998 Jul 27;142(2): 573-86.

[99] Shyy JY, Chien S.: Role of integrins in cellular responses to mechanical stress and adhesion. CurrOpin Cell Biol. 1997 Oct;9(5):707-13.

[100] Kaibuchi K, Kuroda S, Amano M.: Regulation of the cytoskeleton and cell adhesion by the Rho family GTPases in mammalian cells. Annu Rev Biochem. 1999;68:459-86.

[101] Ridley AJ, Hall A.: The small GTP-binding protein rho regulates the assembly of focal adhesions and actin stress fibers in response to growth factors. Cell. 1992 Aug 7;70(3):389-99.

[102] Hotchin NA, Hall A. The assembly of integrin adhesion complexes requires both extracellular matrix and intracellular rho/racGTPases.J Cell Biol. 1995 Dec;131(6 Pt 2): 1857-65.

[103] Lee DY, Yeh CR, Chang SF, Lee PL, Chien S, Cheng CK, Chiu JJ.: Integrin-mediated expression of bone formation-related genes in osteoblast-like cells in response to fluid shear stress: roles of extracellular matrix, Shc, and mitogen-activated protein kinase.J Bone Miner Res. 2008 Jul;23(7):1140-9.

[104] Takashi Nishida, Harumi Kawaki, Ruth M. Baxter, R. Andrea DeYoung, Masaharu-Takigawa, Karen M. Lyons.: N2 (Connective Tissue Growth Factor) is essential for extracellular matrix production and integrin signaling in chondrocytes. J Cell Commun Signal. 2007 June

[105] Zhou S, Schmelz A, Seufferlein T, Li Y, Zhao J, Bachem MG.: Molecular mechanisms of low intensity pulsed ultrasound in human skin fibroblasts.J Biol Chem. 2004 Dec 24;279(52):54463-9. Epub 2004 Oct 12.

[106] Takeuchi, R., Ryo,A., Komitsu, N., Mikuni-Takagaki, Y., Fukui, A., Takagi, Y., Shiraishi, T., Morishita, S., Yamazaki, Y., Kumagai, K., Aoki, I., Saito,T..: Low-intensity pulsed ultrasound activates the phosphatidylinositol 3 kinase/Akt pathway and stimulates the growth of chondrocytes in three-dimensional cultures: a basic science study. Arthritis Res Ther. 2008; 10(4): R77.

[107] ViníciusBuarque de Gusmão, C., Pauli, J.R., AbdallaSaad,M.J., Alves, J.M., Belangero, W.D.: Low-intensity Ultrasound Increases FAK, ERK-1/2, and IRS-1 Expression of In-

http://dx.doi.org/10.5772/54875

tact Rat Bones in a Noncumulative Manner. Clin Orthop Relat Res. 2010 April; 468(4): 1149–1156.

Section 11

Advanced Oral and Maxillofacial Rehabilitation and Implantology

Chapter 23

Concepts in Bone Reconstruction for Implant Rehabilitation

Hany A. Emam and Mark R. Stevens

Additional information is available at the end of the chapter

http://dx.doi.org/10.5772/53401

1. Introduction

The standard of care regarding tooth loss replacement is evolving towards the use of dental implants. The practice of fixed bridges and partial prosthesis can be and are iatrogenic to the existing teeth and bone. Prosthetics in the restoration of partial and complete edentulous conditions with implants has become the most important determinant. Because of this principle the emphasis has focused on optimization of the alveolus to receive a root form implant. Dental implants are a viable treatment option when there is sufficient quantity and quality of bone to achieve the desired functional and esthetic results. The reduction in bone volume has many etiologies. The most common are a result of: Periodontal disease, pneumatization of the maxillary sinus, long term ill-fitting dentures, and the general progression of osteoporosis with aging. Initially, malposition or short implants were used in areas of deficient bone volume. This often resulted in compromised prosthetic design and poor long term treatment outcomes. Today's treatment plans first consider the prosthesis options. This necessitates reconstruction and modifications of the pre-existing anatomy provide the ideal environment needed for optimal implant placement. The deformity is often a composite loss of both bone and soft tissue. The alveolar bone loss frequently occurs in a three dimensional pattern. Multiple options and techniques have been advocated for correction and reconstruction of the atrophied alveolar bones. They include the following: Guided bone regeneration (GBR), onlay bone grafting (OBG), interpositional bone grafting (IBG), distraction osteogenesis (DO), ridge- split (RS), and sinus augmentation techniques (SA). [1-3] The complexity of the defect dictates the selection of the appropriate technique. The reconstruction must also take into account the three dimensional spatial relation of one arch to the opposing arch.

INTECH
open science | open minds

© 2013 Emam and Stevens; licensee InTech. This is a paper distributed under the terms of the Creative Commons Attribution License (http://creativecommons.org/licenses/by/3.0), which permits unrestricted use, distribution, and reproduction in any medium, provided the original work is properly cited.

2. Considerations for reconstruction

2.1. Bone density

The quality of bone in the jaws is dependent on location and position within the dental arches and alveolus respectively. The most dense bone is observed in the anterior mandible, followed by the anterior maxilla and posterior mandible. The least compact bone is typically found in the posterior maxilla. Misch classified these bone densities into a spectrum of four categories, ranging from D1 through D4. D1 bone primarily consists of a dense cortical structure. D4 on the other hand, is the softest, consisting primarily of cancellous bone with a fine trabecular pattern with minimal crestal cortical anatomy. The density of bone is an important quality in the initial stabilization of the implant and in the loading profile of the prosthesis. Literature review of clinical studies from 1981 to 2001 reveals that poor bone density may decrease implant loading survival rates. The decrease survival ranged from 16% to 40 %. The primary cause of these failures was directly attributed to the bone density, strength and a lower percentage of bone to implant contact. Bone in the posterior maxilla was found to be five to ten times weaker in comparison to bone in the anterior when compared to other bone densities. Lesser bone densities also influence stress pattern distribution. Stresses in "soft bone" demonstrate patterns which migrate further towards the apex. Bone loss is more pronounced and occurs along the implant body rather than crestally, as in denser bone. D4 bone exhibits the greatest difference in biomechanical modulus of elasticity when compared with titanium. Therefore, afterload results in higher strain conditions at the bone-implant interface accelerating bone resorption and implant failure (Fig. 1).

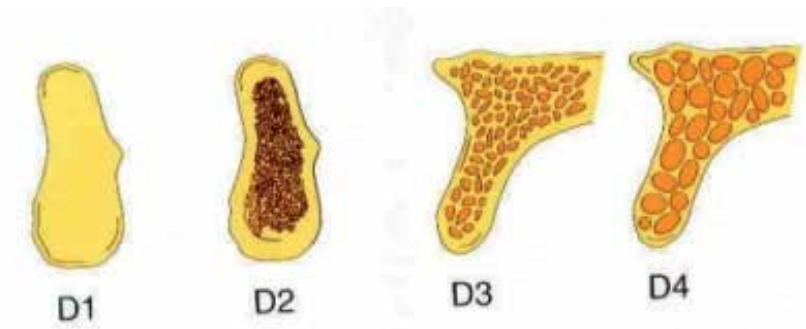

Figure 1. Types of bone densities

2.2. Bone graft materials and mechanism of bone regeneration

Various bone augmentation materials are used for alveolar reconstruction, they include: Autografts, allografts, alloplasts, and xenografts. Autogenous bone grafts can regenerate bone through all three mechanisms: *osteogenesis, osteoinduction, and osteoconduction;* This is the gold standard. Other bone substitute materials form bone from osteoinduction and or osteoconduction in varying degrees.

Osteogenesis is new bone formation. New bone forms from osteoprogenitor cells that are present in the graft. They survive the transplantation, proliferate and differentiate to osteoblasts. *This is termed phase I osteogenesis*. Autogenous bone is the only graft material with osteogenic properties. [4]

Osteoinduction involves new bone formation by stimulation and recruitment of osteoprogenitor cells derived from undifferentiated mesenchymal stem cells at the graft site, *this is called phase II osteogenesis*. The method of recruitment and differentiation occurs through a cascade of events triggered by graft- derived inducing factors called *bone morphogenic proteins* (BMP), which are members of the transforming growth factor-β superfamily. These BMPs are present in the matrix of the graft and are accessed after the mineral content of the graft has been removed by a chemical dissolution process and or osteoclastic activity. It has been shown that osteoinductive materials can induce bone formation even in ectopic sites (subcutaneous tissue). [5]

Osteoconduction is the ingrowth of the vascular tissue and mesenchymal stem cells into the scaffold structure provided by a graft material. Bone formation occurs by resorption or apposition from the existing or surrounding bone. This process is called *creeping substitution*; *and also classified as phase III osteogenesis*. This process must occur in the presence of vital bone or undifferentiated mesenchymal cells. Osteoconductive materials do not grow bone when placed in soft tissue. Instead, the material remains relatively unchanged or resorbs. [6]

2.3. Types of bone grafts

Autografts are grafts harvested from the individual. Autogenous bone uses all three known mechanisms of bone regeneration. They are also non immunogenic and its superiority comes from the transfer of osteocompetent cells. [7]Autogenous bone can be harvested from multiple sites within the body. The most common intra-oral sites are the symphysis, maxillary tuberosity, ramus, coronoid process, and or shavings from osteotomy preparations. The advantage of harvesting intra-orally are, ease of harvesting and the harvest site being within the same reconstruction field. The major disadvantage of intra-oral harvesting is the limited amount and quality of the harvested bone. Extra-oral bone graft harvesting is used to provide large volumes of the material and is indicated for major augmentation procedures. Iliac crests, tibia, fibula, and the cranial bone are common sites for graft harvesting. [8]

Allografts are grafts taken from the same species as the host, but is genetically dissimilar. The grafts are prepared as fresh, frozen, freeze-dried, mineralized and demineralized. There are numerous configurations of allograft bone, including powder, cortical chips, cancellous cubes, cortical struts, and others. Once the grafts are harvested, they are processed through different methods, including physical debridement, ultrasonic washing, treatment with ethylene oxide, antibiotic washing, gamma irradiation for spore elimination, and freeze drying. The goal of these steps is to remove the antigenic component and reduce the host immune response while retaining the biologic characteristics of the graft. However, the mechanical properties of the graft are often weakened (Table 1) [9]

Allogenic bone is principally osteoconductive, although, it may retain some osteoinductive capability. This quality is dependent upon how the material is processed. Urist in 1965

described the process of acid demineralization of bone before implantation by using hydrochloric acid. The organic bone matrix contains bone morphogenic proteins (BMPs). These proteins are responsible for the de novo bone formation. BMP is not acid soluble, however the calcium and phosphate salts of the HA can be removed from the bone in the acid- reducing process. This results in demineralization of the freeze-dried bone (FDB) and an increased exposure of the BMPs with its osteopromotive effect. FDB is primary osteoconductive while demineralized freeze dried bone (DFDB) is believed to be osteoinductive. [10] Results of studies performed using DFDB are conflicting. Controversy still exists about the osteopromotive effects of DFDB. Some reports raise the question of the concentration variability of BMPs in commercially available grafts. Osteoinductive properties of DFDB vary from one cadaver to another. The product fabrication may also have an effect on the osteoinductivity of the allograft where the demineralization process is very technique sensitive. For example, it has been shown that the osteoinductive properties of the grafts are removed, if the calcium content is less than 2% by weight. In addition, controversy persists about the use of ethylene oxide for sterilization of the graft materials and its possible destructive affects on the BMPs. [11]Demineralized cortical bone was found to have higher concentrations of BMPs than trabecular bone. Membranous cortical bone exhibits greater concentration of BMPs than endochondral cortical bone, consequently; the skull and facial bone represent a better source of inductive proteins than the remaining appendicular skeleton.

Routine studies are performed to evaluate the safety of allografts. According to the American association of tissue banks the probability of DFDB to contain HIV virus is 1 in 2.8 billion. When compared with the risk of 1 in 450,000 for blood transfusions, the risk of infection from allografts seems infinitesimal. Rigorous background checks are performed on the donor and his/her family before the donor is accepted into the program. Occasionally biopsy specimens of sites containing allograft from human patients sometimes show chronic inflammatory cells. These histologic appearances of a non-specific inflammatory condition cannot be attributed to an immune reaction with certainty.[6]

Xenografts are derived from the inorganic portion of bone of a genetically different species than the host. One of the most popular used xenografts is the bovine bone. It is a good bone bank material. The process requires complete de-proteinization at high temperature, (1100 °c). This results in total removal of the residual organics that might provoke an immune response (Table 2). [12]

A concern over the risk of disease transmission from cattle to humans through the bone graft material derived from bovine bone used for dental implants has been suggested. The recent incidents of *bovine spongiform encephalopathy* (BSE) in human have underscored this likelihood. Results from analysis conducted by the German Federal Ministry of Health and by the Pharmaceutical Research and Manufacturers Association of America showed that the risk of disease transmission was negligible and could be attributed to the stringent protocols followed in sourcing and processing of the raw bovine bone used in the commercial products. [13] One of the best known xenografts is *Bio-Oss* (Osteohealth, Shirley, NY). It has been treated by having all its organic material removed. This leaves a crystal structure that practically matches human cancellous bone in structure. In 1992, Klinge and colleagues, noted total resorption of Bio-Oss

http://dx.doi.org/10.5772/53401

granules at 14 weeks after placement in rabbit skulls. [14] However, Skoglund and colleagues reported that granules were present even after 44 months [15].

Another popular alternative xenograft is *coralline hydroxyapatite*, which is made from ocean corals. This material was created with the intension of producing a graft material with a more consistent pore size. Coral, which is composed mainly of calcium carbonate, is processed to remove most of the organic content. Then it is subjected to high pressure and heat in the presence of an aqueous phosphate solution. When this process is completed, the calcium carbonate skeleton is totally replaced with a calcium phosphate skeleton (hydrothermal exchange). The material is concurrently sterilized in this process. [16] The generation of biomimetic microenvironments, using scaffolds containing cell recognition sequences in combination with bone cells, offers tremendous potential for skeletal tissue regeneration. *PepGen P15* (DENTSPLY Friadent CeraMed, Lakewood, CO) is the first man engineered collagen I binding domain for potential osteoblasts and is able to multiply the complete regeneration cascade (Figs. 2,3). It is a combination bone replacement graft material composed of natural anorganic bovine-derived hydroxyapatite matrix (ABM) coupled with a synthetic cell-binding peptide (P-15). [17]

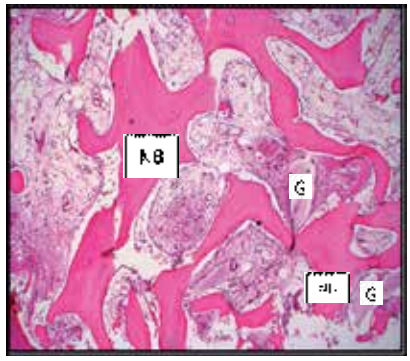

Figure 2. Microphotograph (16 weeks 5x 1.25 OP H&E) showing newly formed bone (NB) in an interconnecting trabecular pattern (bone bridging) surrounding the remaining graft particles G. (PepGen P-15).

Alloplasts are synthetic bone substitutes that posses osteoconductive potential. The ideal synthetic graft material should be biocompatible and elicit minimal fibrotic changes. The graft should support new bone growth and undergo remodeling. Other preferred attributes would include similar toughness, modulus of elasticity, and compressive strength compared to that of the host cortical or cancellous bone. Many synthetic materials are available including: Bioactive glasses, glass ionomers, aluminum oxide, calcium sulphate, calcium phosphates as α and β tricalcium phosphate (TCP), synthetic hydroxyapatite (HA), and synthetic absorbable polymers. [16] Synthetic bone substitutes offer many advantages; however, the greatest is the unlimited supply and avoidance of a secondary surgical procedure. The main disadvantage is the material's lack of the osteoinductive capabilities, experienced in autogenous grafts. Clinicians may prefer performing grafting procedures using *combination grafts*. This will combine the osteogenic potential of autogenous bone with the unlimited supply offered by

Figure 3. Microphotograph (8 weeks 5x 1.6 OP Paragon) showing the newly formed bone (NB) in an interconnecting trabecular pattern (bone bridging-arrows) surrounding the remaining graft particles G (PepGen P-15) supporting a dental implant.

bone substitutes which act as *expanders* or *fillers*. Combination grafts also minimize donor site morbidity that occurs more frequently when harvesting larger volumes of autogenous bone (Table 3).

Allografts				
Material	**Commercial source**	**composition**	**Bone Growth Method**	**Resorption time**
DFDB (Demineralized)	Pacific Tissue Bank Grafton MTF DynaGraft	Collagen + Growth factors	Mainly Osteoinduction varies based upon processing method	+/- 6 months
FDB (Mineralized)	MinerOss Puross	Minerals + Collagen	Mainly Osteoconduction	1 Yr +

Table 1.

Xenografts		
Material	**Brand name**	**Structure**
Deprotenized bovine bone mineral	Bio-Oss	Cancellous or cortical
Anorganic bovine HA+ cell binding peptide	PepGen P-15	Peptide + microporous HA
	Osteograft N	Micro + Macroporous
Coral (Ca carbonate)	Biocoral Interpore 200 (Coralline)	Natural coral

Table 2.

http://dx.doi.org/10.5772/53401

Alloplasts	
Ceramics	**Polymers**
β-tricalcium phosphate (β-TCP)	Methylmethacrylate (HTR synthetic bone)
Hydroxyapatite (HA), (Bone source, Norian)	Poly- α- hydroxy acids (PLA,PLGA)
Ca2So4 (Plaster of paris)	
Calcium phosphate cements (Ceredex, α-BSM)	
Bioactive glass (PerioGlass, BioGran)	

Table 3.

2.4. Properties of graft materials

It is important to consider the physical and chemical properties of the graft materials used in the augmentation procedures. *Physical properties* include the surface area or form of the product (block, particle), porosity (dense, macroporous, microporous), and crystallinity (crystalline, amorphous). *Chemical properties* are related to calcium –to- phosphorous ratio, element impurities (such as carbonate), and the pH of the surrounding region. These properties play a role in the rate of resorption and clinical applications of the material.[7] The larger the particle size, the longer the material will remain at the augmentation site. It was also reported that the greater the porosity, the more rapid the resorption of the graft material as this will give the chance for committed cells and blood vessels (bone modeling unit) to invade the spaces between the graft particles replacing the graft with the newly formed bone. However, dense HA may lack any micro or macro porosity within the particles with long resorption rate since the osteoclasts only attack the surface and cannot penetrate the dense material. With respect to crystallinity, the higher the crystalline structure the harder for the body to break down and absorb it.[7] The resorption of bone substitutes may be cell or solution- mediated. Cell mediated resorption requires living cells of the body to resorb the material mainly osteoclasts. A solution –mediated resorption is a chemical process; impurities like calcium carbonate permit solution – mediated resorption, which then increases the porosity of the graft. The pH in the region also affects the rate of graft resorption. As the pH decreases (due to infection) the HA components resorb by a solution – mediated resorption. Bone, dense HA, macroporous HA, microporous HA, crystalline HA, or amorphous HA may all resorb within a two-week period (Fig. 4).[7]

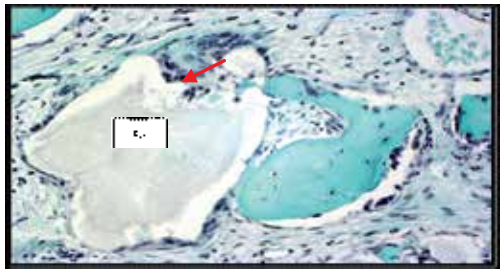

Figure 4. Showing the cell - mediated resorption of multinucleated cells (arrow) on the surface of the graft particle (G).

Close matching of the resorption rate to the bone deposition rate is important. Selection of graft material should be based on location of graft site, soft tissue environment, and its possible role in promoting and supporting future implant osseous integration. A rapidly resorbing scaffold might reestablish a void filled with connective tissue, whereas one that resorb too slowly, or not at all, would impede bone deposition and limit creeping substitution. There are, however clinical indications in which resorption is not desired, but rather, a permanent implant is preferred, such as craniofacial onlays for cosmetic augmentation.

2.5. Bone growth factors

The term growth factors comprises a group of polypeptides of approximately 6-45 KD (kilo Dalton) which are involved in cellular proliferation, differentiation and morphogenesis of tissues and organs during embryogenesis, postnatal growth, and adulthood. [18] Factors that are involved in the regeneration and induction of bone tissue have attracted attention as they possibly can facilitate skeletal reconstruction. These factors include platelet derived growth factor (PDGF), vascular endothelial growth factor (VEGF), insulin like growth factors (IGF), transforming growth factor β (TGF β), bone morphogenic proteins (BMPs), and platelet rich plasma (PRP).

Bone morphogenic proteins (BMPs), particularly BMP2, BMP4 and BMP7, appear to be the most reliable factors of all growth factors currently discussed with regard to enhancement of bone regeneration in reconstruction of the facial skeleton (Table 4). BMPs stimulate angiogenesis, migration, proliferation, and differentiation of mesenchymal stem cells into bone forming cells in the area of bone injury. Although a high washout effect of BMP during the first few hours in most of the carriers used has to be taken into account, this short-term signal appears to be sufficient for the initial induction of the cascade of endochondral bone formation to provide bone regeneration in the defects of the various models. Recombinant techniques are now used to provide large amounts of BMPs which are normally present in very small quantities within the organic matrix of bone (accounting for only approximately 0.1% of the mass of the organic matrix). [19] Bioactive Proteins, GEM 21S® is a combination of a bioactive proteins (highly purified recombinant human platelet derived growth factor, rhPDGF-BB) and a biocompatible osteoconductive matrix (beta-tricalcium phosphate, β-TCP). It is presently being used for periodontal regeneration procedures and offers a greater amount of growth factors as normally found in Platelet Rich Plasma (PRP).

The apparent strong desire of clinicians for the use of growth factors to facilitate reconstructive surgical procedures by obviating the need for procurement of autogenous grafts is contrasted by their limited availability for clinical application. This has prompted the application of autogenous growth factors by using *platelet rich plasma (PRP)* derived from the patient's own blood. This preparation has come widely into use recently, despite the fact that currently there is controversial scientific evidence about the benefit of using this preparation, especially, in reconstructive and preprosthetic bone grafting. According to the characteristics of the growth factors that are present in PRP and assigned for its biological activity, the use of PRP is supposed to increase proliferation of undifferentiated mesenchymal cells and to enhance angiogenesis, which then can support bone graft incorporation by enhancing of osteoproge-

nitor cells in the graft. It may as well improve soft tissue healing by increasing proliferation and matrix synthesis. [20] Recently, inorder to improve the handling characteristics of the graft materials to facilitate its use in several clinical situations, several commercial suppliers have begun to provide several matrices and delivery systems as carriers. The addition of the carrier changed the consistency of the material from a particulate consistency to a more coherent hydrogel form (flow) or clay like (putty) form with ease in handling during surgical application. The carrier must be nontoxic and biocompatible and should not impede any of the steps of the bone-forming cascade. Also, when used with growth factors they must first bind to them, permit their timed release, facilitate invasion of blood vessels and enable cellular attachment, finally promoting the deposition of new bone. Sodium hyaluronate, carboxymethylcellulose, poly-α- hydroxy acids, absorbable collagen sponges (ACS) and Lecithin are among the carrier materials used. In addition to the handling characteristics, it is assumed that the carrier material when added to a particulate graft will provide spaces between these particles (lower packing density), facilitating the capillary in-growth and the creeping substitution process leading to proper healing with optimum new bone formation in a shorter period of time.

BMPs approved for clinical use and indications
rhBMP-2 (Wyeth/Medtronic)
InductOs (CHMP approved)
Open tibia fracture, 2002
Interbony spinal fusion, 2005
INFUSE Bone Graft (FDA approved)
Interbony spinal fusion, 2002
Open tibia fracture, 2004
Oral/Maxillofacial, 2007
rhOP-1 (Stryker)
OP-1 Implant (FDA HDE & CHMP approved)
Recalcitrant long bone nonunions, 2001/2004
OP-1 Putty (FDA HDE approved)
Osteolateral (intertransverse) lumbar spinal fusion revision, 2004.
Bioactive proteins Gem 21S (Osteohealth), Periodontal defects

Table 4.

3. Treatment plan for bone augmentation

The treatment planning sequence for implant dentistry begins with the design of the final prosthesis. After the determination of the type of restoration, number and position of teeth to be restored and the patients force factors are then evaluated. The bone density in the region of the implant placement is then considered. The key implant positions and the number and ideal implant sizes are then selected. Finally the available bone volume is evaluated for implant placement according to the proposed treatment plan. Previous studies have shown that the

most common cause of implant failures are stress-related failures especially after loading. Mechanical stress can have both positive and negative consequences for bone tissue and, thereby, also for maintaining osseointegration of oral implants. Dental implants function to transfer occlusal loads to the surrounding biological tissues. If occlusal loads are within the bone physiologic tolerance zone, osseointegration will be maintained. On the other hand, if occlusal loads are excessive and beyond the bone physiologic tolerance limit, bone will ultimately resorb and failure of osseointegration result. Thus, as a general rule the goal of treatment planning should be to minimize and evenly distribute the mechanical stress in the implant system and the surrounding bone. [21] The magnitude of stress depends on two variables which are: The *force magnitude* that is hard to control by the dentist and the *functional cross-sectional area* which participate in load bearing and stress dissipation. This area should be considered when executing the treatment plan, where it should be adequate to allow optimum stress distribution and prevent stress concentration around dental implants. There are three types of forces may be imposed on dental implants within the oral environment namely compression, tension and shear forces. Bone is strongest when loaded via compression, 30% weaker when loaded via tension and 65% weaker when loaded with shear forces. Considering the *direction* of applied occlusal loads during implant placement is important; implants should be aligned in the oral cavity to convert these loads into more favorable compressive loads at the bone-implant interface. Therefore, in the treatment plan, implants should be oriented to receive axial forces parallel to the long axis of the implants as much as possible to avoid the destructive effects of angled forces. [22], [23]

3.1. Rationale for bone augmentation

From the previous discussion sufficient amount of bone volume should be available to provide the optimum biomechanical foundation for implant placement. Sufficient bone volume will allow placement of wide diameter implants with sufficient length and number as needed by the treatment plan instead of using small sized, short implants that were only used because of insufficient bone volume compromising the treatment outcome. Adequate bone volume allows placement and alignment of implants with optimum axial inclination to receive occlusal forces in a more favorable axial direction. In addition to providing optimum bone volume, bone augmentation procedures offered a solution in the avoidance of injuring vital structures that were present as obstacles when considering implant therapy as a treatment option, such as close proximity to the inferior alveolar canal and the maxillary sinus. It is worth mentioning that proper selection of the implant design is of paramount importance in achieving long term success. [24] Some areas in the oral cavity require special considerations, like the poor density maxillary posterior edentulous area. Wide diameter, threaded implants with optimum length should be used to increase the bone to implant contact ratio and the surface area, allowing proper stress distribution at the bone implant interface. This can only be done in the presence of sufficient bone volume to accommodate the selected implants otherwise bone augmentation procedures are mandatory. When considering esthetics, sufficient bone volume is also necessary to achieve the desirable aesthetic outcome especially in the aesthetic (anterior) zone. The emergence profile is greatly dependant on the bone surrounding dental implants allowing optimum soft tissue drape around the abutments for ideal esthetic results. Also, the presence

http://dx.doi.org/10.5772/53401

of sufficient bone volume allows flexibility in choosing the properly sized implant for better abutment emergence profile. [25]

4. Bone augmentation techniques

4.1. Socket preservation/ Guided bone regeneration

Physiologic bone resorption results in unpredictable loss of bone following teeth extraction. This can lead to less than ideal bone volume available for implant placement especially in prolonged cases of edentulism. Multiple types of grafting materials have been used to fill the extraction sockets immediately after extraction in order to maintain the space of the extraction site and prevent its collapse. This will allow for more organized bone healing maintaining the bone height and width necessary for implant placement. Following grafting the socket, barrier membranes are used to provide guided bone regeneration by protecting the underlying grafted site during healing from undesirable cellular population from the overlying soft tissues that might compromise the outcome (Figs. 5,6).

Figure 5. Socket preservation following teeth extraction.

Figure 6. Grafting particulate bone

4.2. Block bone grafting technique

Block grafting approaches can be used to reconstruct significant deficiency in the vertical and horizontal dimensions of the alveolar ridge. Autogenous block grafting procedures remain the gold standard for ridge augmentation. However, donor site morbidity associated with graft harvest has turned the attention to using allogenic grafting materials. The locations for harvesting intraoral block grafts include the external oblique ridge of the posterior mandible (ramus), symphysis. With bone defects >2 cm, an extraoral donor site is warranted for harvesting larger bone volumes. The iliac crest (anterior and posterior), cranium, or tibia is often used as extraoral harvest sites. The detailed description of the harvesting techniques is beyond the scope of this chapter. Case reports have demonstrated success with FDBA and DFDBA block graft material. However, further research is warranted to evaluate the healing of these blocks histologically (Figs. 7-12).

Figure 7. Ramus bone harvest

Figure 8. Symphysis bone harvest

http://dx.doi.org/10.5772/53401

Figure 9. Calvarial bone harvest

Figure 10. Anterior iliac crest bone harvest

Figure 11. Mandibular bone augmentation using block. grafts. Two screws are used to prevent rotation.

Figure 12. Maxillary ridge augmentation.

4.3. Ridge expansion (split) technique

With a narrow ridge, splitting the alveolar bone longitudinally, using chisels, osteotomes, or peizosurgical devices, can be performed to increase the horizontal ridge with, provided the facial and lingual plates are not fused and some intervening bone is present. With adequate stability of the mobile segment, sufficient interpositional grafting and soft tissue protection, comparable results to alternate techniques can be obtained. The decision to place the implants simultaneously with the split procedure or delayed placement following bone healing depend on the degree of stability of the expanded segment and the volume of remaining bone (Figs. 13-17).

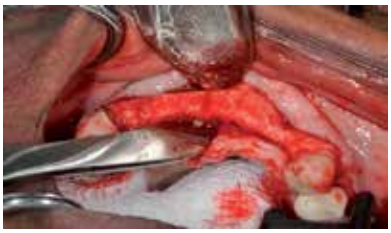

Figure 13. Narrow maxillary ridge.

Figure 14. Osteotomy of the ridge

Figure 15. Ridge splitting.

http://dx.doi.org/10.5772/53401

Figure 16. Interpositioning graft between the buccal and the palatal plates of bone. Collagen membrane is used to cover the expanded site

Figure 17. The augmented maxillary ridge 5 weeks postoperatively

4.4. Sinus augmentation

The most commonly used technique use to access the maxillary sinus is the lateral window technique modifying the Caldwell-Luc operation, also called the hinge osteotomy technique, originally described by Tatum then first published by Boyne and James.

A window is then created using a round bur on the lateral wall of the sinus till the bluish hue of the sinus membrane reveals itself. Using specially designed sinus elevation curettes the sinus membrane is elevated from the bony floor and is freed anteriorly, posteriorly and medially to create a tension free elevation to minimize the possibility of perforation. The trap door (window) is intruded medially forming the new sinus floor and the space created below it is then grafted to provide the platform for implant placement. The flap is then repositioned and closed. Implants are placed either simultaneously with the graft (one- stage) or after a delayed period of up to 8 months to allow for graft maturation (two- stage). The decision about the two options mainly depends on the preexisting residual amount of bone required for initial primary stability of an implant. It was found that if the bone thickness is 4 mm or less, initial implant stability would be jeopardized. In 1994, Summers published a new less invasive conservative technique for sinus floor elevation using osteotomes in an attempt to overcome the drawbacks of the lateral window approach. The technique begins with a crestal incision to expose the alveolar ridge. An osteotome of the smallest size is then tapped into place by a mallet into the bone just shy from the sinus membrane fracturing and moving the sinus floor superiorly. Osteotomes of increasing sizes are introduced sequentially to expand the alveolus

and with each insertion of a larger osteotome, bone is compressed, pushed laterally and apically. Summers stated that the very nature of this technique improved the bone density of the posterior maxilla. Bone graft material is then introduced via the osteotomy followed by implant fixture insertion. The implant fixture should be slightly larger in diameter than the osteotomy site "tenting" the elevated maxillary sinus membrane. A minimally invasive antral membrane balloon elevation (MIAMBE) which is a modification of the osteotome technique has also been introduced with satisfactory results. It comprises the introduction of a balloon into the osteotomy site which is then slowly inflated to elevate the sinus membrane. This procedure showed predictable results and required a short learning curve. Recently, some authors have reported the use of a piezoelectric device in maxillary sinus surgery. Ultrasound has been increasingly used in many fields of medicine such as tumor enucleation, fragmentation of renal calculi and lithotripsy of gall bladder stones. Ultrasonic dissection has been classified as tissue-selective technique that might improve the efficiency of dissections and at the same time reduces the morbidity rate resulting from iatrogenic injuries. In addition, ultrasound energy can induce a cavitational effect in water containing tissues, which can in turn facilitate the tissue separation (Figs. 18,19).

Figure 18. Showing the lateral window approach

Figure 19. Sinus augmentation with immediate implant placement

4.5. Distraction osteogenesis

Distraction Osteogenesis (DO) uses the phenomenon that new bone fills in the gap defect created when two pieces of bone are slowly separated under tension. Distraction of the segment can be achieved in a vertical and /or horizontal direction on the basic principles involved in distraction which include a latency period of 7 days for initial soft callus formation,

http://dx.doi.org/10.5772/53401

a distraction phase during which the 2 segments of bone undergo incremental gradual separation at a rate ~ 1 mm per day to stretch the formed soft callus, and a consolidation phase that allows healing of the regenerated bone between the 2 segments. The prerequisites for optimal bone augmentation of defects using DO are minimum of 6-7 mm of bone height above vital structures, such as neurovascular bundles or air passages/sinus cavities, a vertical ridge defect of > 3 -4 mm, and an edentulous span of three or more missing teeth (Figs. 20,21).

Figure 20. Alveolar distraction of the anterior maxillary region

Figure 21. Note: the vertical osteotomy cuts should be divergent to avoid obstructing the path of distracting the transport segment.

4.6. Tent- Pole technique

Marx et al in 2002 advanced the approach of soft tissue matrix expansion using corticocancellous bone grafting with dental implants to treat severely resorbed mandibles that were shorter than 6 mm. Using this transcutaneous submental approach, 4 to 6 dental implants were placed to act as "tent poles" to maintain the height of the overlying mucosal soft tissue and prevent it from sagging around the iliac crest graft (Figs. 22, 23). [2]

Figure 22. Implant placement in the severely atrophic mandible through a submental approach

Figure 23. Corticocancellous bone graft around the implants tenting the soft tissue

4.7. Bone ring technique

Three dimensional bone augmentations with immediate dental implant placement can be done using this technique. Using trephine burs corresponding to the extraction socket diameters, bone rings can be harvested from the chin or iliac crest regions. The harvested rings can then be secured to the extraction socket using the dental implants restoring the deficient bone at the crestal portion in a 3D fashion (Figs. 24,25). [27]

Figure 24. Three dimensional crestal bone augmentation using bone rings.

Figure 25. Immediate implant placement in the anterior maxilla

4.8. Reconstruction of segmental bony defects

Ablative loss of both bone and associated soft tissue from treatment of neoplastic or other pathologic processes represent a far different task from loss of bone from physiologic resorption, trauma or infection. The goals of reconstruction are to restore jaw continuity, provide

http://dx.doi.org/10.5772/53401

morphology and position of the bone in relation to its opposing jaw, provide adequate height and width of bone, and provide facial contour and support for soft tissue structures.

Graft malpositioning result in occlusal problems and presents a formidable task to the restorative dentist. The site of the graft harvest depends mainly on the size of the residual defect (Figs. 26-28).

Figure 26. Reconstruction plate in place.

Figure 27. Free fibula graft.

Figure 28. Reconstruction of mandibular segmental bone defect using free fibula.

4.9. Combination grafts

In large defects, the use of grafting materials from different sources can be beneficial. Some techniques aim to combine the osteogenic potential of autogenous bone with the osteoconductive and space maintaining properties provided by the allogenic or alloplastic sources. Allogenic materials can provide constructs that are close in morphology as the resected part providing superior esthetic outcome following the grafting procedure (Fig. 29,30).

Figure 29. Hemimandibular reconstruction using a cadaveric mandible in combination with cancellous bone graft harvested from the iliac crest.

Figure 30. Graft in position.

4.10. Future augmentation approaches

Future bone augmentation approaches likely will use molecular, cellular, and genetic tissue engineering technologies. Gene therapy is a relatively new therapeutic modality based on the potential for delivery of altered genetic material to the cell. Localized gene therapy can be used to increase the concentration of desired growth or differentiation factors to enhance the regenerative response. Cellular tissue engineering strategies that include the in vitro amplification of osteoprogenitor cells grown within three dimensional constructs is currently of particular interest. The use of mesenchymal stem cell for construct seeding showed promise for bone regeneration. These approaches may lead to further refinement and improvement in alveolar bone augmentation techniques.

http://dx.doi.org/10.5772/53401

5. Surgical caveats for bone grafting

There are several factors that may improve the success and predictability of bone graft procedures, they include the following:

5.1. Surgical asepsis and absence of infection

Contamination of bone grafts due to endogenous bacteria, lack of aseptic surgical technique, inadequate soft tissue closure and salivary exposure may lead to infection with subsequent lowering of the pH. Solution –mediated resorption will follow with resultant graft loss. Some clinicians prefer including antibiotics locally within the graft materials to guard against bacterial contamination as no blood supply is present early in the graft. Primary soft tissue closure is also mandatory for the success of the grafting procedure. It allows healing by primary intension protecting the graft from any surrounding contamination until healing. Dehiscence with graft loss is one of the most common complications in bone grafting procedures. Therefore, careful surgical flap planning which ensures adequate blood supply to the site with minimal trauma and primary soft tissue closure without tension are required.

5.2. Space maintenance

Creation of a desired contoured space for bone formation is very important in the grafting procedure. If the graft material resorbs too rapidly compared with the time required for bone formation, the site may fill with connective tissue rather than bone. Therefore, the space must be maintained long enough without collapse for bone to fill the desired area. Titanium-reinforced barrier membranes, tent screws elevated above the bone at the desired height covered by a membrane, block grafts (covered by membrane or not) are all used to create and maintain space for bone growth.

5.3. Graft stability

For predictable bone augmentation, graft stability is a paramount. Bone remodeling and graft healing requires rigid interface for blood clot adhesion with its associated growth factors. If a graft become mobile its vascularity will be compromised followed by fibrous encapsulation and often sequestrate. If block grafts are used fixation can be achieved using titanium screws or the graft can be fixed using the inserted implants itself. If particulate graft is used, it can be covered with a barrier membrane fixed with membrane tacks to avoid dislodgement of the graft particles.

5.4. Regional acceleratory phenomenon (RAP)

The host site during bone augmentation procedures should be decorticated to establish bleeding points in the cortical bone prior to graft placement. This procedure will provide access for trabecular bone vessels, encourage revascularization, bring growth factors to the graft site and increase the availability of osteogenic cells promoting graft union and shorten the healing time.

Acknowledgements

The authors would like to extend their gratitude and acknowledgement to **Drs. Solon Kao DDS and Henry "Butch" Ferguson DMD**, for allowing the use of several clinical surgical cases. Their photographic documentation of specific bone grafts and regenerative techniques was instrumental in providing comprehensive examples of implant site reconstructions.

Author details

Hany A. Emam[1,2] and Mark R. Stevens[1]

*Address all correspondence to: hemam@georgiahealth.edu; mastevens@georgiahealth.edu

1 Oral and Maxillofacial Surgery Department, Georgia Health Sciences University, Augusta, Georgia, USA

2 Oral and Maxillofacial Surgery, Cairo University, Egypt

References

[1] Aghaloo, T. L, & Moy, P. K. Which hard tissue augmentation techniques are the most successful in furnishing bony support for implant placement? Int J Oral Maxillofac Implants (2007). Suppl:, 49-70.

[2] Jensen, J, Sindet-pedersen, S, & Oliver, A. J. Varying treatment strategies for reconstruction of maxillary atrophy with implants: results in 98 patients. J Oral Maxillofac Surg (1994). discussion 16-8., 52(3), 210-6.

[3] Isaksson, S, & Alberius, P. Maxillary alveolar ridge augmentation with onlay bone-grafts and immediate endosseous implants. J Craniomaxillofac Surg (1992). , 20(1), 2-7.

[4] Giannoudis, P. V, Dinopoulos, H, & Tsiridis, E. Bone substitutes: an update. Injury (2005). Suppl 3:S, 20-7.

[5] Browaeys, H, Bouvry, P, & De Bruyn, H. A literature review on biomaterials in sinus augmentation procedures. Clin Implant Dent Relat Res (2007). , 9(3), 166-77.

[6] Khan, S. N, & Cammisa, F. P. Jr., Sandhu HS, Diwan AD, Girardi FP, Lane JM. The biology of bone grafting. J Am Acad Orthop Surg (2005). , 13(1), 77-86.

[7] Misch, C. E, & Dietsh, F. Bone-grafting materials in implant dentistry. Implant Dent (1993). , 2(3), 158-67.

[8] Clavero, J, & Lundgren, S. Ramus or chin grafts for maxillary sinus inlay and local onlay augmentation: comparison of donor site morbidity and complications. Clin Implant Dent Relat Res (2003). , 5(3), 154-60.

[9] Marx, R. E. Bone and bone graft healing. Oral Maxillofac Surg Clin North Am (2007). v., 19(4), 455-66.

[10] Wikesjo, U. M, Sorensen, R. G, Kinoshita, A, & Wozney, J. M. RhBMP-2/alphaBSM induces significant vertical alveolar ridge augmentation and dental implant osseointegration. Clin Implant Dent Relat Res (2002). , 4(4), 174-82.

[11] Zhang, M, & Powers, R. M. Jr., Wolfinbarger L, Jr. Effect(s) of the demineralization process on the osteoinductivity of demineralized bone matrix. J Periodontol (1997). , 68(11), 1085-92.

[12] Kao, S. T, & Scott, D. D. A review of bone substitutes. Oral Maxillofac Surg Clin North Am (2007). vi., 19(4), 513-21.

[13] Sogal, A, & Tofe, A. J. Risk assessment of bovine spongiform encephalopathy transmission through bone graft material derived from bovine bone used for dental applications. J Periodontol (1999). , 70(9), 1053-63.

[14] Klinge, B, Alberius, P, Isaksson, S, & Jonsson, J. Osseous response to implanted natural bone mineral and synthetic hydroxylapatite ceramic in the repair of experimental skull bone defects. J Oral Maxillofac Surg (1992). , 50(3), 241-9.

[15] Skoglund, A, Hising, P, & Young, C. A clinical and histologic examination in humans of the osseous response to implanted natural bone mineral. Int J Oral Maxillofac Implants (1997). , 12(2), 194-9.

[16] Moore, W. R, Graves, S. E, & Bain, G. I. Synthetic bone graft substitutes. ANZ J Surg (2001). , 71(6), 354-61.

[17] Nguyen, H, Qian, J. J, Bhatnagar, R. S, & Li, S. Enhanced cell attachment and osteoblastic activity by peptide-coated matrix in hydrogels. Biochem Biophys Res Commun (2003). , 15.

[18] Schilephake, H. Bone growth factors in maxillofacial skeletal reconstruction. Int J Oral Maxillofac Surg (2002). , 31(5), 469-84.

[19] Wikesjo, U. M, Huang, Y. H, Polimeni, G, & Qahash, M. Bone morphogenetic proteins: a realistic alternative to bone grafting for alveolar reconstruction. Oral Maxillofac Surg Clin North Am (2007). vi-vii., 19(4), 535-51.

[20] Marx, R. E, Carlson, E. R, Eichstaedt, R. M, Schimmele, S. R, Strauss, J. E, & Georgeff, K. R. Platelet-rich plasma: Growth factor enhancement for bone grafts. Oral Surg Oral Med Oral Pathol Oral Radiol Endod (1998). , 85(6), 638-46.

[21] Isidor, F. Influence of forces on peri-implant bone. Clin Oral Implants Res (2006). Suppl , 2, 8-18.

[22] Misch, C. Contemporary Implant Dentistry. Mosby Inc., Elsevier (2008). Third Edition., 200-229.

[23] Bidez, M. W, & Misch, C. E. Issues in bone mechanics related to oral implants. Implant Dent (1992). , 1(4), 289-94.

[24] Rieger, M. R, Adams, W. K, Kinzel, G. L, & Brose, M. O. Finite element analysis of bone-adapted and bone-bonded endosseous implants. J Prosthet Dent (1989). , 62(4), 436-40.

[25] Jivraj, S, & Chee, W. Treatment planning of implants in the aesthetic zone. Br Dent J (2006). , 201(2), 77-89.

[26] Marx, R. E, Shellenberger, T, Wimsatt, J, et al. Severely resorbed mandible: Predictable reconstruction with soft tissue matrix expansion (tent pole) grafts. J Oral Maxillofac Surg 60:8, (2002).

[27] Stevens, M. R, et al. Implant bone rings. One-stage three-dimensional bone transplant technique: a case report. J Oral Implantol, (2010). , 69-74.

Chapter 24

Outfracture Osteotomy Sinus Graft: A Modified Technique Convenient for Maxillary Sinus Lifting

Jeong Keun Lee and Yong Seok Cho

Additional information is available at the end of the chapter

http://dx.doi.org/10.5772/53301

1. Introduction

Edentulous alveolar ridges always demonstrate atrophy when left alone without dental treatment, making rehabilitaion of masticatory function in this atrophic ridge in need of auxilliary augmentation procedures. This is always challenging in posterior maxillary edentulous area because local anatomical condition of this region is easily hampered as masticatory force in the posterior dentition and maxillary sinus is three times greater and the antrum is always subject to pneumatization; thus, facilitating the alveolar bone resorption of the maxillary sinus floor. The best way for a functional rehabilitation of the edentulous alveolar ridge is a dental implant; augmentation sinus surgery can circumvent the anatomical problems (i.e. lack of bone) associated with implant fixture installation.

Tatum introduced a surgical technique to approach the maxillary sinus [1] in 1976, when he first suggested the trapdoor approach; a new method of opening a bony window inward using a top hinge in the lateral maxillary sinus wall. Most maxillary sinuses can be accessed with this inward osteotomy technique with the exception of anatomical variations such as the presence of sinus septum in the operation field or a thick lateral maxillary sinus wall. We however, instead of inward opening, choose to move the osteotomized bony window completely out of the original site to access the Schneiderian membrane of the maxillary sinus (Fig 1). The outfractured bony segment is saved in the normal saline which will be repositioned to the original site after the completion of sinus grafting. The authors experienced excellent treatment results with this modified "outfracture osteotomy sinus grafting (OOSG)" technique which is presented herein.

INTECH
open science | open minds

© 2013 Lee and Cho; licensee InTech. This is a paper distributed under the terms of the Creative Commons Attribution License (http://creativecommons.org/licenses/by/3.0), which permits unrestricted use, distribution, and reproduction in any medium, provided the original work is properly cited.

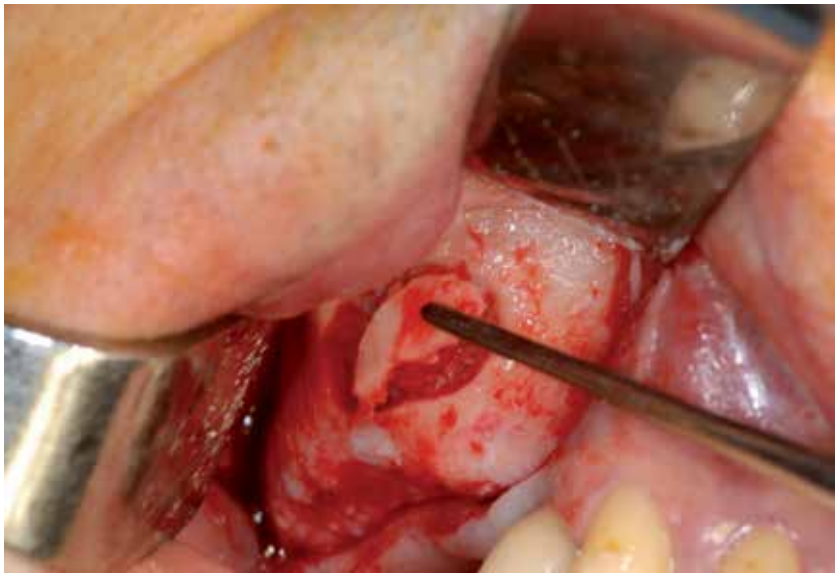

Figure 1. Outfracture osteotomy sinus grafting. The entrance to the lateral sinus wall is prepared by complete outward removal of the bony window which was carefully osteotomized by a rotary device.

2. Concept of the Outfracture Osteotomy Sinus Grafting (OOSG) technique

2.1. Conventional method

In contrast to the structural basal bone, alveolar bone is a labile bone implying it has a functional role of it which gradually degenerates following the loss of the teeth [2]. The floor of the maxillary sinus, forming the roof of the maxillary posterior alveolar bone, is always expanding downward through pneumatization especially when the alveolar bone becomes edentulous [3]. For the above two reasons, the maxillary alveolar bone is prone to atrophy when adequate tooth support is lost making problems for dentists to rehabilitate this region.

The first to introduce sinus surgery for prosthodontic preparation was Dr. Tatum. However, in 1980 Boyne and James [4] first published the detailed surgical technique and its results was for preprosthetic surgery prior to conventional prosthodontic treatment. It involved osteotomy of the lateral maxillary wall and inward fracture of the bony window with a top hinge (Fig 2). The Schneiderian membrane is elevated with this inward movement of the bony segment. It was in 1996 a consensus conference was held on sinus grafting; it was agreed that sinus grafting is an efficacious procedure and an adjunctive procedure for implant-supported restorations in the posterior maxilla [5]. Most cases are treatable with this conventional technique with the exception of some conditions.

http://dx.doi.org/10.5772/53301

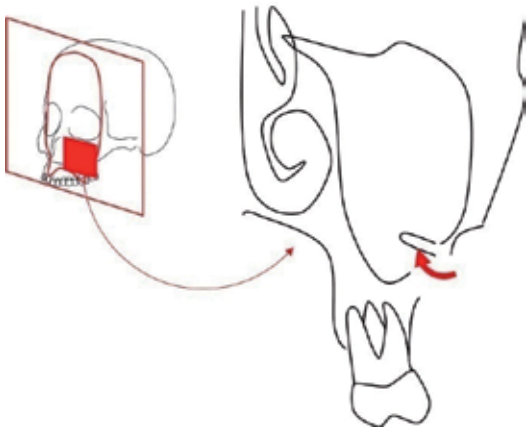

Figure 2. Concept of the original sinus approach method. It involves osteotomy of the lateral maxillary wall and inward fracture of the bony window with a top hinge.

2.2. New concept

When the lateral maxillary wall is thick enough to resist the inward force of the bony segment, sinus surgery is difficult with the conventional technique. The Schneiderian membrane may tear with excessive uncontrolled force applied to counteract this resistance. In case of sinus septae in the operative field, they may stand in way of infracture of the bony segment. The authors modified the technique to completely remove the osteotomized bony segment of the lateral wall instead of infracture and inward hinge movement. The outfractured bony segment is placed in normal saline during sinus grafting and is replaced to its original position when grafting is complete (Fig 3).

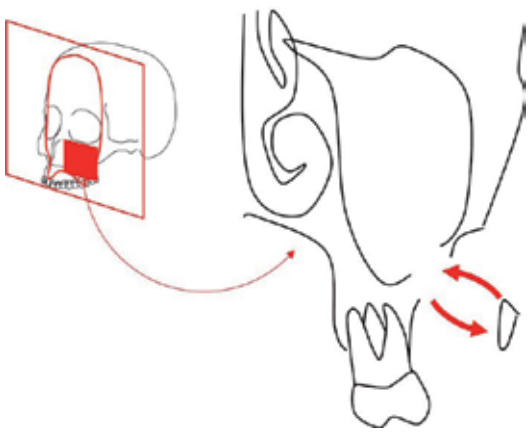

Figure 3. Concept of the outfracture osteotomy sinus grafting method. Bony window is completely removed from the lateral maxillary wall and the outfractured bony segment is placed in the normal saline during sinus grafting and is replaced to its original position before soft tissue closure.

3. Advantages and Indications of the OOSG Technique

Outfracture osteotomy sinus grafting technique is advantageous in the below situations:

1. In cases with both height and width problems
2. Sinus septum resisting infracture of the bony window
3. Thick lateral sinus wall accompanying intrabony bleeding

3.1. Solution to width, as well as height problems

Essentially sinus grafting is a solution to alveolar height problems in installation of dental implant fixtures in the posterior maxillary edentulous alveolar ridges. One of the most influencing factors on the survival of the installed implant fixtures is known to be the height of the remaining alveolar bone [6]. Usually alveolar bone goes atrophic not only vertically but also transversely causing width problems in addition to height problems. In complicated cases of both height and width problems, outfracture osteotomy sinus grafting technique provides a good solution to both problems [7]. The width problem is resolved by transverse augmentation with cortical bone blocks. Outfracturing of the bony segment will secure an access to the lateral maxillary wall after elevation of the Schneiderian membrane, which will provide room for fixation screws for augmentation using cortical bone blocks (Fig 4).

Figure 4. Outfracture osteotomy sinus grafting can be a solution to cases of both height and width problems. Complete outfracturing of the bony segment helps provide room for both sinus floor elevation and screw fixation of the cortical bone block. This patient underwent sinus grafting with OOSG technique simultaneously with a block bone graft from the mandibular ramus. Outfractured bone segment was put back to its original position before soft tissue closure.

http://dx.doi.org/10.5772/53301

3.2. Anatomical considerations

All cases of conventional sinus surgery are also indicated for the outfracture osteotomy sinus graft especially those with anatomic variations such as maxillary septae or a thick lateral maxillary wall. Presurgical evaluation of the computerized tomography (CT) is useful for the information essential to sinus surgery. Intraosseous arterial structures can be visualized in the CT crosscut in up to 64.5 % of all maxillary sinuses [8]. Sinus septae and thick lateral walls of the maxillary sinus is also easily visualized with CT scans, which is a good indication for outfracture osteotomy sinus grafting.

4. Surgical technique

In preparation for the simultaneous installation of the fixtures, the lateral maxillary wall is usually accessed via crestal incision with adequate vertical extension over the buccal surface (Fig 5). Periosteal elevation is followed by a gentle osteotomy, with the borders of the maxillary sinus imagined in mind. Osteotomy line is outlined 2mm away from the imaginary anterior and lower borders. The osteotomy line is extended with the image in mind that antero-posteral and vertical dimension of the window is designed to be 10 mm and 5 mm, respectively (Fig 6). Instead of usual osteotomy, the author intends a thin osteotomy line minimizing the lost bone to help reposition the bony segment to the original position after graft material is placed in. The usual rotary instrument is a No. 2 round carbide bur which is adequate for minimizing bone loss (Fig 7).

Figure 5. Lateral maxillary wall is exposed via elevation of the flap after vertical extension of the buccal side of the aimed site which is usually accessed by crestal approach for simultaneous installation of the fixtures.

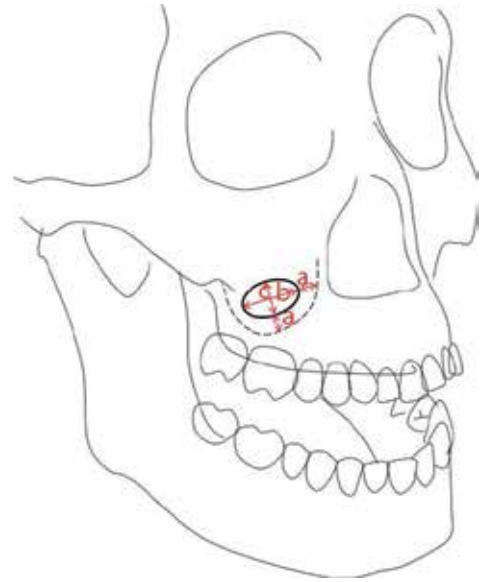

Figure 6. Osteotomy design. Imaginary border of the maxillary sinus (dashed line) is outlined based on the panoramic radiograph. Osteotomy line is designed 2mm away from the imaginary anterior and lower borders (a). The osteotomy line is extended with the image in mind that antero-posteral and vertical dimension of the window is designed to be 10 mm and 5 mm, respectively (b and c).

Figure 7. Exposure of the lateral maxillary wall is followed by a gentle osteotomy with rotary instrument using No. 2 round carbide bur which is adequate for minimizing bone loss. A thin osteotomy line is preferred for minimizing the lost bone to help reposition of the bony segment to the original position.

A bluish grey color beneath the osteotomy line indicates the exposure of the Schnederian membrane which must be extended along the whole osteotomy line. Usually Schneiderian membrane is identified along the osteotomy line as a bluish grey line, a landmark to stop further bone reduction not to invade the membrane surface (Fig 8). This is difficult in case of thick lateral sinus wall (to identify the bluish grey color) but instead of inward force, light outward force induces slice fragmentation of the thick lateral wall partially, just like onion

http://dx.doi.org/10.5772/53301

skin peeling out without exposure of the Schneiderian membrane as a whole. In view of underlying remaining bone after slice outfracture, remaining bone is still thick to be removed further repeatedly until Schneiderian membrane can be seen definitely. For detailed information, please see section 5.2. and Fig 14.

Figure 8. Osteotomy is continued until a bluish grey line is visible not to invade the Schneiderian membrane.

Outward leverage action beneath the formed bony window causes it to separate. The bony segment of the window is preserved in normal saline solution and the Schnederian membrane is undermined to separate it from the sinus floor (Fig 9). The most vulnerable stage for membrane tears is in this stage. The best way to prevent membrane perforation is to keep the tip of the sinus elevator in intimate contact with the bony floor of the maxillary sinus. The room created is filled with adequate bulk of the graft material and the bony fragment which was kept in normal saline solution is secured without any plate or screws (Fig 10). The flap is closed as usual with 4-0 Vicryl and pressure dressing for minimizing postoperative swelling.

Figure 9. The Schneiderian membrane is undermined to be separated it from the sinus floor with curved sinus elevators. The elevator must be kept in contact with the bony sinus floor to prevent perforation of the Schneiderian membrane.

Figure 10. After the graft material is filled over the sinus floor, the bony window fragment is put back to its original position without any plate or screws followed by flap approximation with 4-0 vicryl sutures.

5. Considerations

5.1. Septum crossing the maxillary sinus

The first article on the prevalence of the septae in the maxillary sinus was in 1910 by Underwood reporting 33.0 % in 45 cadavers [9] which was an anatomical study. Varying degrees of the incidence of sinus septae, namely Underwood septae, were reported ranging from 9 % to 33.2 % [10,11,12,13,14] in clinical studies using CT scanning. Anatomical studies using cadavers demonstrated 31.7 % to 40 % of incidences [15,16,17]. Septal direction is usually buc-

http://dx.doi.org/10.5772/53301

copalatal, obstructing the inward path of the bony window in approaching the maxillary sinus (Fig 11) [14,17]. Outfracture of the bony segment can evade this problem and adequate approach becomes possible. Either two separate windows (Fig 12) or one large opening (Fig 13) can be made on the lateral wall without concern of tearing the underlying Schneiderian membrane, for there is outward leverage force instead of inward hinge movement.

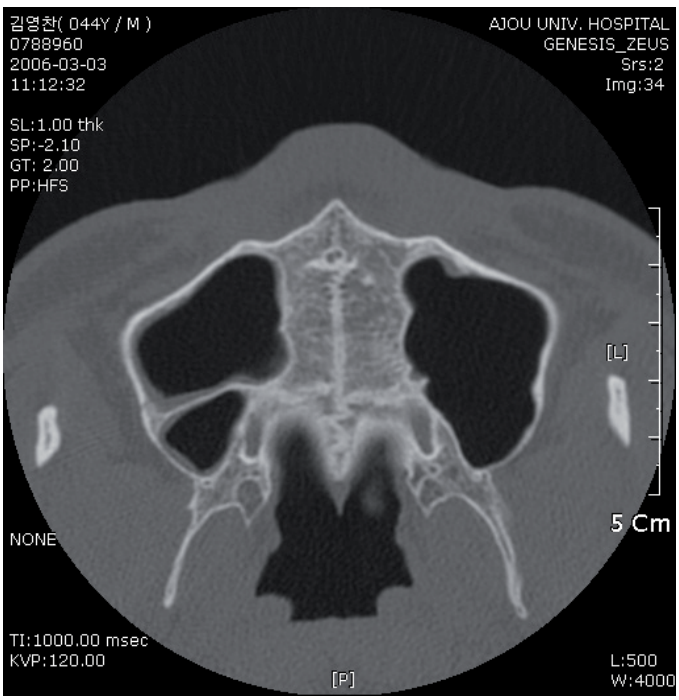

Figure 11. Typical septal structure crossing the maxillary sinus in the buccopalatal direction. It will stand in the way of sinus entry with the conventional method of inward fracturing of the bony window.

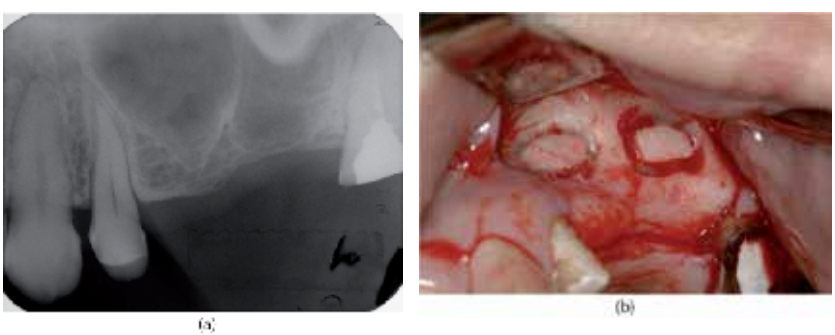

Figure 12. Sinus septum seen on a standard periapical radiograph (a), and two separate windows sinus approach (b). Separate windows can be utilized with respective outfracturing.

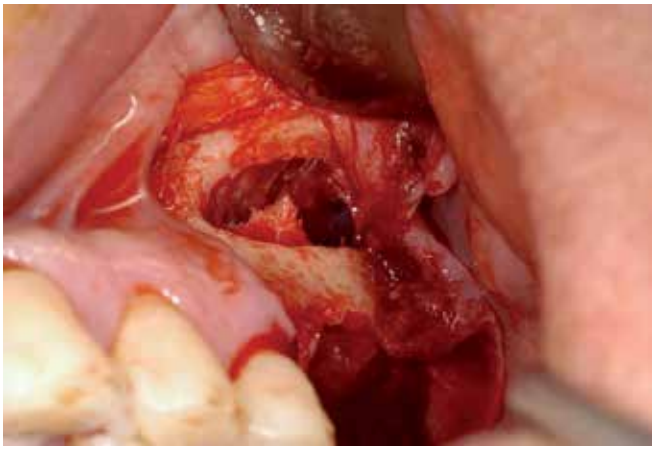

Figure 13. One large window can be utilized because of the outward, not inward vector of the segment fracturing. Septal anatomy can be identified without concerns about membrane tearing with the outfracture technique.

5.2. Thick lateral wall of the maxillary sinus

Thick lateral maxillary wall which resists inward movement is easily removed outward with only a gentle pressure. In extreme cases, the wall is fragmented out a couple of times just like onion skin peeled out one by one (Fig14 a through d). Outfracture of the thick bony segment is repeated until complete exposure of the Schneiderian membrane without concern of tearing.

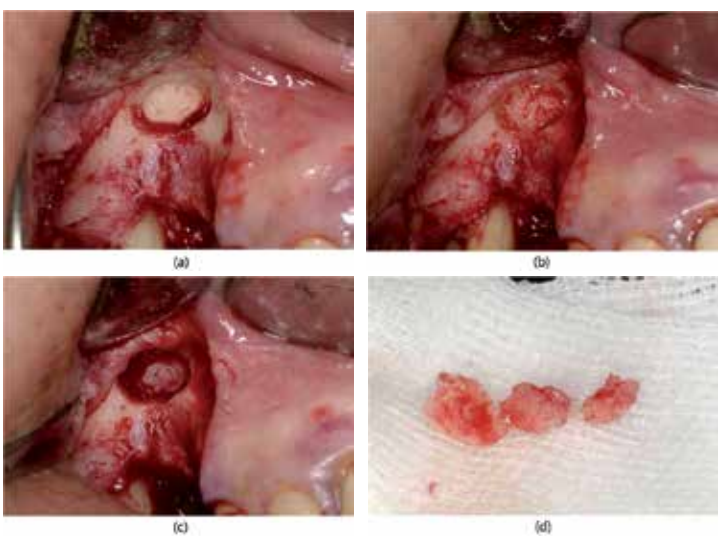

Figure 14. Repeated outfracture of the bony segments in thick lateral maxillary wall. Initial outfracture osteotomy (a) didn't succeed in revealing Schneiderian membrane (b), but continued osteotomy (c) lead to exposure of the Schneiderian membrane and left three pieces of osteotomized segments (d).

http://dx.doi.org/10.5772/53301

5.3. Bone bleeding during sinus approach

Head and neck structures have a high vascularity enhancing the healing capacity of this region. Extended from the external carotid artery, the internal maxillary artery feeds the maxillary sinus with its branches, infraorbital artery (IOA) and posterior superior alveolar artery (PSAA) anastomosing on the lateral maxillary wall. In a study using 100 CT scans, 94 out of 200 (47 %) examined sinuses demonstrated well-defined bony canals in the areas of sinus surgery to be done, whereas intra-osseous anastomoses of the IOA and PSAA was found by dissection in a total of 30 cadaveric maxillary sinuses [18]. Another study revealed that 52.9 % of the intraosseous branches of PSAA can be visualized on the CT scans and its average distance from the alveolar crest was demonstrated to be 16 ± 3.5 mm [19]. Typical coronal crosscut image of the CT shows the passage of the arterial structure on the lateral maxillary sinus wall as a notching inside of it (Fig 15). Adequate design of the surgical planning based on this radiographic anatomy will help prevent bleeding with outfracture osteotomy sinus graft technique because of its technical convenience.

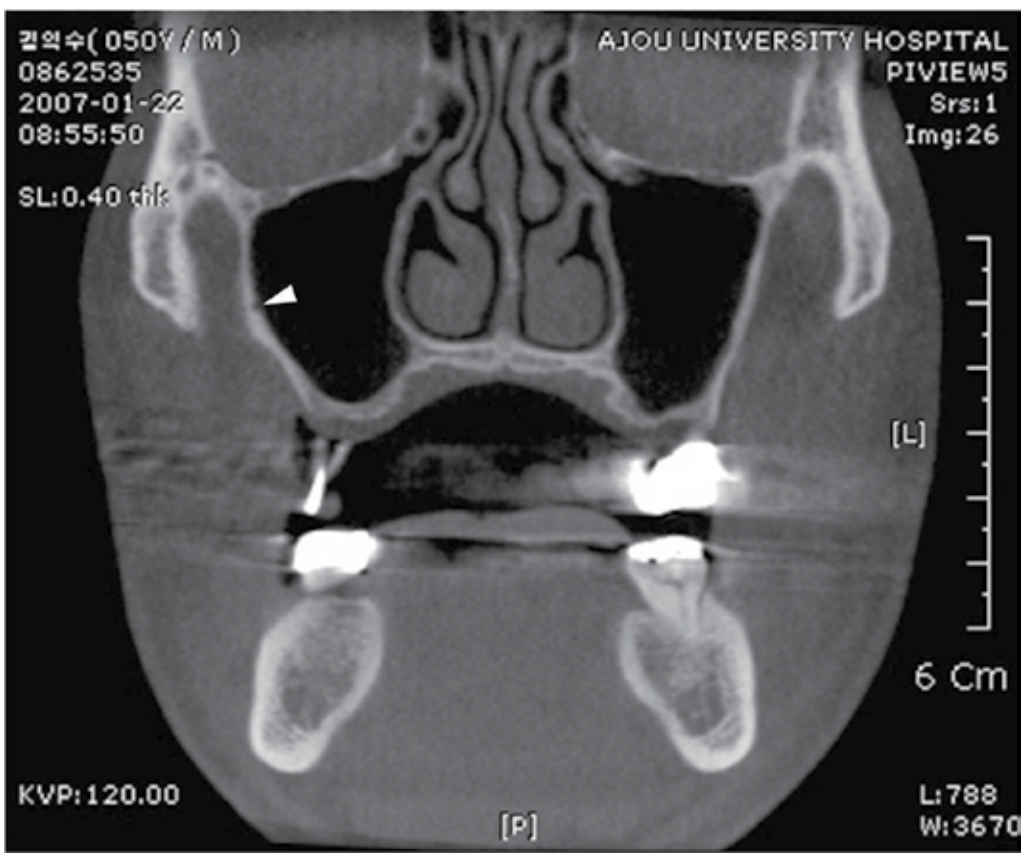

Figure 15. Crosscut image showing the notch inner cortical side of the lateral maxillary sinus wall revealing the arterial structure passing over the Schneiderian membrane (white arrowhead).

There was no vessel visible or no vessel present in most cases (120 sinuses, i.e. 89.5 %) in the cadaveric and radiographic study of 134 maxillary sinuses [20]. The other 14 cases demonstrated its appearance in two thirds of the lateral wall of the maxillary sinuses, 12 of which (85.7 %) showing vessels in the middle third. Another study showed bony canal in 114 (55 %) out of 208 CT scans in surgical planning of the maxillary sinus [21]. Because the anastomosis of the IOA and PSAA is usually in the surgical field as in these studies, surgeons approaching lateral maxillary wall encounter these vessels occasionally. During the conventional sinus approach intrabony bleeding is more difficult to deal with in the thick lateral sinus wall, for inward mobilization of the bony segment; this will be possible only after the complete reduction of the thick lateral wall. By contrast, outfracturing immediately reveals any bleeding in the surgical field. Sometimes, large arterial feature running across the surgical field can be visible after outfracturing of the bony window (Fig 16). Even in the case of thick lateral wall it may cause slice fragmentation just like an onion skin, which will not hide the bleeding in the surgical field. Surgical approach can be done with adequate bleeding control in the course of the sinus window opening.

Figure 16. Large artery running across the surgical field is visible after complete removal of the bony window segment outward (white arrowhead).

http://dx.doi.org/10.5772/53301

5.4. Most natural covering membrane

Covering membrane is used to block access window after completion of the sinus graft procedure. In a clinical study comparing the effect of barrier membrane in the bilateral sinus floor elevation, Tarnow concluded that the barrier membrane tends to increase vital bone formation and recommended membrane placement in all sinus elevation procedures [22]. Although many kinds of barrier membranes are commercially available, outfractured bony segment functions as a covering membrane instead of artificial membrane [7,23]. It can participate in the bone remodeling procedure, for it is of self origin functioning as a natural covering membrane. It's rather a free bone graft and most of the repositioned bony segment is to take part in remodeling procedure absorbed in healing process with consolidation of graft material.

5.5. Grafting materials

Success of the bone graft depends more upon the condition of the recipient site than the kinds of the graft materials. There is little difference of success rate among various kinds of graft materials with the result of the materials used is all acceptable [5]. There are a lot of studies demonstrating many kinds of grafting materials in sinus augmentation either in animal experiment [2425] or human studies using peripheral blood [26], absorbable gelatin sponge [27], and autologous fibrin-rich block with concentrated growth factors28. Antral ossification was also reported even after Schneiderian membrane elevation without graft material in experimental studies in rabbits [24, 25]. New bone formation was also confirmed clinically, radiographically, and histologically in a human study with elevation of the Schneiderian membrane without graft material [29]. We are now grafting a material derived from autogenous teeth, the effect of which is confirmed in in-vivo study using miniature pigs [30] and by the histologic result of a human study [31].

Despite of the diverse range of treatment results of the graft materials, the overall effect of the various materials used in the sinus graft seems to be acceptable [5]. It means maxillary sinus is anatomically acceptable for graft procedure irrespective of the materials used. Maxillary sinus is a confined cavity with excellent cortical housing adequate for immobilization of the graft material, a prerequisite for an optimal healing that can induce new bone formation.

6. Fixture survival rate with outfracture osteotomy sinus graft technique

The survival of the installed implant fixture is most dependant on the initial stability of the fixture [32] and the quality of bone that takes the fixtures and not on the graft materials [33]. The conventional sinus graft technique has no advantage over the outfracture osteotomy technique, for bone segment which is trapped in is not stable to take the installed fixture.

The author has been performing sinus graft at Ajou University Hospital Dentofacial Center in Suwon, Korea when the posterior maxillary alveolar ridge is inadequate for fixture

installation. All patients needing augmentation sinus surgery by lateral approach technique underwent outfracture osteotomy sinus grafting. As an independent procedure, our department has recorded 97.2 % (174 out of 179 fixtures involved in sinus graft) 5-year implant survival rate in 2009 [34]. Our overall total implant survival rate in our department was 97.9 % (751 out of 767 fixtures) with fixtures 3.75 mm in their diameters after 4.5 years [35].

As a continuing study following the previous one, a retrospective study was done on the cumulative survival rate of the fixtures. One hundred and fifty- six patients with loss of teeth and atrophy of posterior maxilla underwent augmentation sinus surgery with outfracture osteotomy sinus grafting. One hundred and fourty two out of 156 patients received simultaneous or delayed fixture installation according to our diagnostic criteria. Fixture installations were not done for the 14 patients whose implant treatments were done at respective local dental clinics. Three hundred and fourty two fixtures were installed in 142 patients and 320 fixtures were selected which fulfilled the inclusion criteria of follow-up period over 4 months. The time for follow-up ranged from a minimum of 4.2 months to a maximum of 88.2 months (average 26.8 months). The total number that underwent sinus graft surgery with outfracture osteotomy sinus graft technique was 171 (113 unilateral and 29 bilateral cases in 142 patients). Fourteen fixtures were recorded as failures, making the total cumulative survival rate 95.6 % (306 out of 320 fixtures) (Table 1). Although the cumulative survival rate was slightly less compared to the previous study [34], 171 sinuses exhibited good results without a case of major complications such as graft failure.

Age Tooth No.	Under 10	11-20	21-30	31-40	41-50	51-60	61-70	Over 70	Total
#17	0	0	0	5	20	14(1)	7	1	47(1)
#16	0	0	2	6	27(2)	17(2)	9	2	63(4)
#15	0	0	1	2	11	6	3	1	24
#14	0	0	1	1	3	4	2	0	11
#13	0	0	0	0	1(1)	1	0	0	2(1)
#23	0	0	0	0	1	1	0	0	2
#24	0	0	2	2(1)	8(1)	9	3	0	24(2)
#25	0	1	1	2	12	11	3	0	30
#26	0	0	4	11(2)	24(3)	30	7	2	78(5)
#27	0	0	2	4	13	14(1)	4	2	39(1)
Total	0	2	12	31	126	106	36	8	321

Failure cases were designated in the parentheses in relevant column.

Table 1. Total implant fixtures installed in the atrophic maxillary alveolar bone with OOSG technique.

7. Conclusion

Sinus augmentation surgery is an established procedure effective for implant-supported restorations in the posterior maxilla. Although the lateral approach to the maxillary sinus can be done with conventional inward trapdoor method using upper hinge, the authors recommend the new method of outfracture osteotomy and repositioning of the bony window. So called outfracture osteotomy sinus graft is technically easy and convenient for coping with intraoperative complications such as marrow bleeding. It is a versatile method enabling the lateral approach of the maxillary sinus even in anatomical difficulties such as the presence of antral septae.

Author details

Jeong Keun Lee[1] and Yong Seok Cho[2]

1 Department of Dentistry Oral and Maxillofacial Surgery, Ajou University School of Medicine, Suwon, Korea

2 Apseon Dental Hospital, Seoul, Korea

References

[1] Tatum H Jr. Maxillary and sinus implant reconstructions. Dental Clinics of North America 1986;30(2) 207-209

[2] Lee J.K. Bone biology for implant dentistry in atrophic alveolar ridge- theory and practice. In: Turkyilmaz I. (ed) Implant Dentistry: A Rapidly Evolving Practice. Rijeka: InTech; 2011. P413-434. Available from http://www.intechopen.com/books/implant-dentistry-a-rapidly-evolving-practice/bone-biology-for-implant-dentistry-in-atrophic-alveolar-ridge-theory-and-practice (accessed 15 August 2012).

[3] Sharan A, Madjar D. Maxillary Sinus Pneumatization Following Extractions: A Radiographic Study. International Journal of Oral and Maxillofacial Implants 2008;23(1) 48-56

[4] Boyne PJ, James R. Grafting of the maxillary sinus floor with autogenous marrow and bone. Journal of Oral Surgery 1980;38(8) 613-616

[5] Jensen OT, Shulman LB, Block MS, Iacono VJ. Report of the sinus consensus conference of 1996. International Journal of Oral and Maxillofacial Implants 1998;13(Suppl) 11-45

[6] Froum SJ, Tarnow DP, Wallace SS et al.: Sinus floor elevation using anorganic bovine bone matrix (OsteoGraf/N) with and without autogenous bone: a clinical, histologic,

radiographic, and histomorphometric analysis--Part 2 of an ongoing prospective study. International Journal of Periodontics and Restorative Dentistry 1998;18(6): 528-543

[7] Lee JK. Outfracture osteotomy on lateral maxillary wall as a modified sinus graft technique. Journal of Oral and Maxillofacial Surgery 2010;68(7) 1639-1641

[8] Güncü GN, Yildirim YD, Wang HL, Tözüm TF. Location of posterior alveolar artery and evaluation of maxillary sinus anatomy with computerized tomography: a clinical study. Clinical Oral Implants Research 2011;22(10) 1164-1167

[9] Underwood AS. An inquiry into the anatomy and pathology of the maxillary sinus. Journal of Anatomy and Physiology 1910;44(4) 354-369

[10] Lee DH, Lee SH, Hwang JH, Lee JK. Clinical study on the Korean posterior maxillae related to dental implant treatment. Journal of Korean Association of Maxillofacial Plastic and Reconstructive Surgeons 2010;32(1) 27-31

[11] Lee WJ, Lee SJ, Kim HS. Analysis of location and prevalence of maxillary sinus septa. Journal of Periodontal Implant Science 2010;40(2) 56-60

[12] Kim MJ, Jung UW, Kim CS, Kim KD, Choi SH, Kim CK, Cho KS. Maxillary sinus septa: prevalence, height, location, and morphology. A reformatted computed tomography scan analysis. Journal of Periodontology 2006;77(5) 903-908

[13] Park YB, Jeon HS, Shim JS, Lee KW, Moon HS. Analysis of the anatomy of the maxillary sinus septum using 3-dimensional computed tomography. Journal of Oral and Maxillofacial Surgery 2011;69(4) 1070-1078

[14] Neugebauer J, Ritter L, Mischkowski RA, Dreiseidler T, Scherer P, Ketterle M, Rothamel D, Zöller JE. Evaluation of maxillary sinus anatomy by cone-beam CT prior to sinus floor evaluation. International Journal of Oral and Maxillofacial Implants 2010;25(2) 258-265

[15] Ulm CW, Solar P, Krennmaier G, Matejka M, Watzek G. Incidence and suggested surgical management of septa in sinus-lift procedures. International Journal of Oral and Maxillofacial Implants 1995;10(4) 462-465

[16] Ella B, Noble RDa, Lauverjat Y, Sédarat C, Zwetyenga N, Siberchicot F, Caix P. Septa within the sinus: effect on evaluation of the sinus floor. British Journal of Oral and Maxillofacial Surgery 2008;46(4) 464-467

[17] Rosano G, Taschieri S, Gaudy JF, Lesmes D, DelFabbro M. Maxillary sinus septa: a cadaveric study. Journal of Oral and Maxillofacial Surgery 2010;68(6) 1360-1364

[18] Rosano G, Taschieri S, Gaudy JF, Weinstein T, Del Fabbro M. Maxillary sinus vascular anatomy and its relation to sinus surgery. Clinical Oral Implants Research 2011;22(7) 711-715

[19] Elian N, Wallace S, Cho SC, Jalbout ZN, Froum S. Distribution of the maxillary artery as it relates to sinus floor augmentation. International Journal of Oral and Maxillofacial Implants 2005;20(5) 784-787

[20] Ella B, Sédarat C, Noble RDa C, Normand E, Lauverjat Y, Siberchicot F, Caix P, Zwetyenga N. Vascular connections of the lateral wall of the sinus: surgical effect in sinus augmentation. International Journal of Oral & Maxillofacial Implants 2008;23(6) 1047–1052

[21] Mardinger O, Abba M, Hirshberg A, Schwartz-Arad D. Prevalence, diameter and course of the maxillary intraosseous vascular canal with relation to sinus augmentation procedure: a radiographic study. International Journal of Oral and Maxillofacial Surgery 2007;36(8) 735-738

[22] Tarnow DP, Wallace SS, Froum SJ, Rohrer MD, Cho SC. Histologic and clinical comparison of bilateral sinus elevations with and without barrier membrane placement in 12 patients: Part 3 of an ongoing prospective study. International Journal of Periodontics and Restorative Dentistry 2000;20(2) 117-125

[23] Cho YS, Park HK, Park CJ. Bony window repositioning without using a barrier membrane in the lateral approach for maxillary sinus bone graft; clinical and radiologic results at 6 months. International Journal of Oral and Maxillofacial Implants 2012;27(1) 211-217

[24] Sohn DS, Kim WS, An KM, Song KJ, Lee JM, Mun YS. Comparative histomorphometric analysis of maxillary sinus augmentation with and without bone grafting in rabbit. Implant Dentistry 2010;19(3) 259-270

[25] Sohn DS, Moon JW, Lee WH, Kim SS, Kim CW, Kim KT, Moon YS. Comparison of New Bone Formation in the Maxillary Sinus With and Without Bone Grafts; Immunochemical Rabbit Study. International Journal of Oral and Maxillofacial Implants 2011;26(5) 1033-1042

[26] Moon JW, Sohn DS, Heo JW, Shin HI, Jung JK. New bone formation in the maxillary sinus using peripheral venous blood alone. Journal of Oral and Maxillofacial Surgery 2011;69(9) 2357-2367

[27] Sohn DS, Moon JW, Moon KN, Cho SC, Kang PS. New bone formation in the maxillary sinus using only absorbable gelatin sponge. Journal of Oral and Maxillofacial Surgery 2010;68(6) 1327-1333

[28] Sohn DS, Heo JU, Kwak DH, Kim DE, Kim JM, Moon JW, Lee JH, Park IS. Bone Regeneration in the Maxillary Sinus Using an Autologous Fibrin-Rich Block With Concentrated Growth Factors Alone. Implant Dentistry 2011;20(5) 389-395

[29] Sohn DS, Lee JS, Ahn MR, Shin HI. New bone formation in the maxillary sinus without bone grafts. Implant Dentistry 2008;17(3) 321-331

[30] Jeong HR, Hwang JH, Lee JK. Effectiveness of autogenous tooth bone used as a graft material for regeneration of bone in miniature pig. Journal of the Korean Association of Oral and Maxillofacial Surgeons 2011;37(5) 375-379

[31] Kim YK, Kim SG, Byeon JH, Lee HJ, Um IU, Lim SC, Kim SY. Development of a novel bone grafting material using atogenous teeth. Oral Surgery, Oral Medicine, Oral Pathology, Oral Radiology, and Endodontology 2010;109(4) 496-503

[32] Albrektsson T, Brånemark PI, Hansson HA, Lindström J. Osseointegrated titanium implants. Requirements for ensuring a long-lasting, direct bone-to-implant anchorage in man. Acta Orthopaedica Scandinavica 1981; 52(2) 155-170

[33] Molly L. Bone density and primary stability in implant therapy. Clinical Oral Implants Research 2006;17(Suppl 2) 124-35

[34] Song SI, Jeong HR, Kim HM, Lee JK. Clinical investigation on the feasibility of outfracture osteotomy sinus graft technique. Journal of the Korean Association of Oral and Maxillofacial Surgeons 2009;35(5) 367-371

[35] Ko SM, Lee JK, Eckert SE, Choi YG. Retrospective Multicenter Cohort Study of the Clinical Performance of 2-stage Implants in South Korean Populations. International Journal of Oral and Maxillofacial Implants 2006;21(5) 785-788

Chapter 25

Inferior Alveolar Nerve Transpositioning for Implant Placement

Ali Hassani,
Mohammad Hosein Kalantar Motamedi and
Sarang Saadat

Additional information is available at the end of the chapter

http://dx.doi.org/10.5772/52317

1. Introduction

Premature loss of posterior teeth in the mandible, failure to replace lost teeth as well as systemic factors may result in progressive resorption of the alveolar ridge. At present, oral and maxillofacial surgeons aim to reconstruct the lost bone and masticatory function via posterior mandibular grafting and/or implants. However, anatomic limitations such as the inferior alveolar nerve (IAN) may limit this. Various treatment methods are available for treatment of patients with posterior mandibular atrophy presenting with a superficial IAN; each has its own merits and drawbacks. [1,2] Use of removable or fixed prosthetics and reconstruction of the dentoalveolar system by dental implants are among the available treatment options; a superficial IAN often precludes use of the latter. Implant-based reconstruction has several advantages i.e. allows for placement of longer implants, bone preservation, better functionality etc. and is gaining more proponents. However, certain conditions should be met in order for an implant to be placed. The most important condition is the quality and quantity of the bone. The amount of resorption, density of the bone and level of the nerve may limit implant placement. Reconstruction and rehabilitation of the dentoalveolar system in cases with alveolar ridge atrophy is a challenge for maxillofacial surgeons and prosthodontists. To date, several treatment options such as augmentation techniques with bone grafts [3], cartilage [4] or hydroxylapatite [5], vestibuloplasty [6] and several osteotomy techniques [7] have been suggested. Such treatments are still indicated as alternatives for cases in which for some reason dental implants cannot be placed [8]. In order to place an implant, we need adequate bone volume (both mediolaterally and mesiodistally) with optimal bone density.

INTECH
open science | open minds

© 2013 Hassani et al.; licensee InTech. This is a paper distributed under the terms of the Creative Commons Attribution License (http://creativecommons.org/licenses/by/3.0), which permits unrestricted use, distribution, and reproduction in any medium, provided the original work is properly cited.

This condition is usually not met in atrophic areas of the posterior mandible especially in patients that have been edentulous for some time. As the alveolar ridge becomes atrophied, the bony height from the crest of ridge to IAN decreases and the bone height in this area is often not enough to place an implant. Due to the increasing demand of patients for dental implants, strategies have been presented to overcome the obstacle of deficient alveolar bone height. These include guided bone regeneration (GBR), onlay bone graft, inter-positional sandwich bone graft, distraction osteogenesis (DO), all-on-four technique, use of short implants, lateral (or Lingual) positioning of implants and nerve transpositioning. Each of the aforementioned treatment options has its inherent advantages and disadvantages as well as indications and contraindications. In this chapter we discuss nerve transpositioning.

2. Nerve transpositioning

2.1. History

The first case of inferior alveolar nerve repositioning was reported by Alling in 1977 to rehabilitate patients with severe atrophy for dentures [9]. Jenson and Nock in 1987 carried out IAN transposition for placement of dental implants in posterior mandibular regions [10]. In 1992, Rosenquist performed the first case series study on 10 patients using 26 implants. He reported an implant survival rate of 96% for this procedure [11] and therefore, this technique was accepted as a treatment modality for reconstruction of the dentoalveolar system with dental implants in the posterior mandible. Consequently, research studies started to evaluate various surgical techniques developed for this procedure; their advantages, disadvantages, pitfalls and methods for preventing or decreasing complications were presented. As a result, this technique constantly improved. When looking at the history of different treatment modalities and surgical techniques in various academic fields we notice that most of them had limitations and complications at first but significantly improved with time and advancement of technology. Nerve transposition is a young procedure that needs further refinements in terms of technique and instrumentation to decrease complications.

2.2. Anatomy of the inferior alveolar nerve

The inferior alveolar nerve (IAN) is a branch of the mandibular nerve (V3) which is itself the third branch of the cranial nerve V (Figure 1). It runs downward on the medial aspect of the internal pterygoid muscle and passes inbetween the sphenomandibular ligament and the mandibular ramus entering through the mandibular foramen into the inferior alveolar canal innervating the teeth posterior to the mental foramen. At the mental foramen, the IAN divides into two branches namely the incisal and mental nerves (Figure 2). The incisal nerve is often described as the extension of the IAN innervating mandibular canines and incisors by passing through the bone [12].

http://dx.doi.org/10.5772/52317

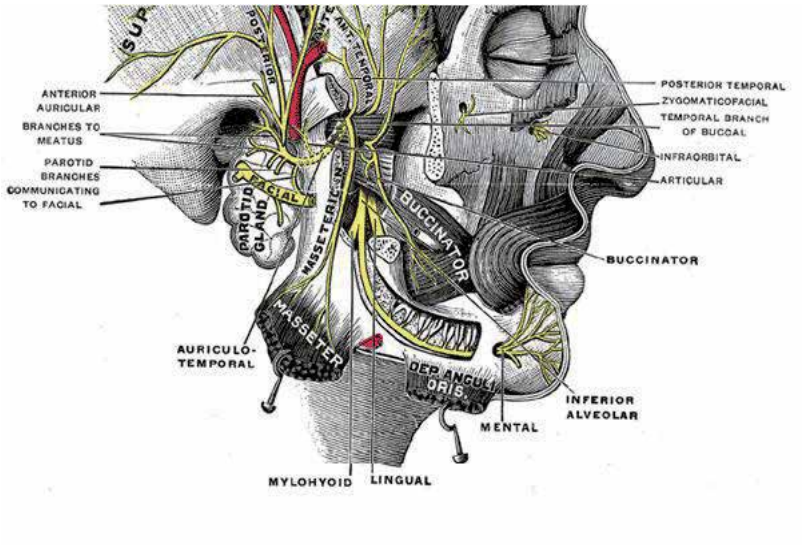

Figure 1. Inferior alveolar nerve path.

The inferior alveolar nerve gives off 3 branches inside the canal: Ramus Retromandibularis, Rami Molares or Molar Branch and Ramus Incisivus or Incisal Branch.

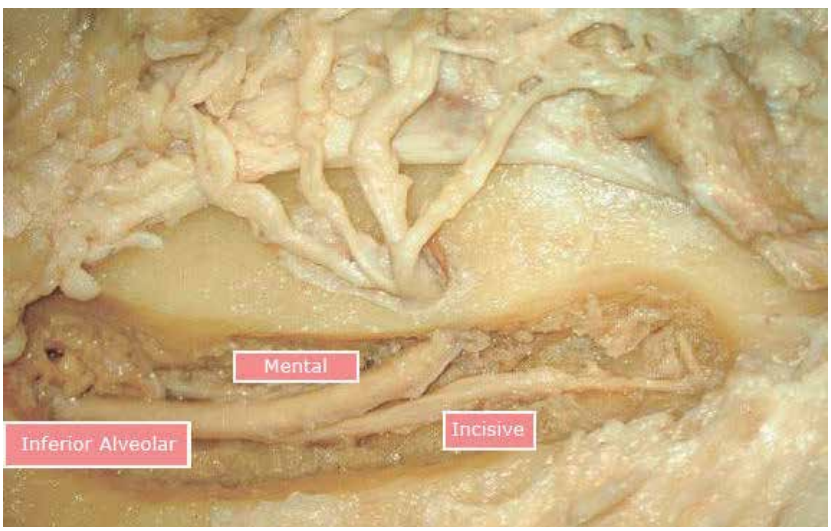

Figure 2. Branching of the inferior alveolar nerve into mental and incisive nerves at the mental foramen.

In some cases, the IAN canal is unilaterally or bilaterally bifid [13,14]. Thus, it is necessary to pay close attention to radiographic and CT examinations before nerve transposition in order to detect such cases and decrease the related risks (Figure 3).

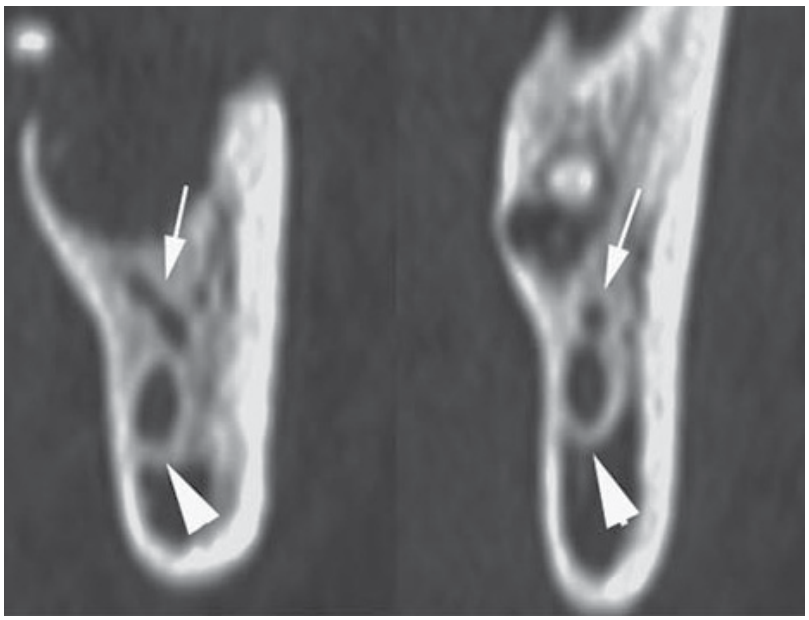

Figure 3. A coronal CT scan of a patient with a bifid mandibular nerve canal

2.2.1. Inferior alveolar nerve canal in edentulous patients

On panoramic radiographs of edentulous patients, the IAN canal in the body of the mandible is not very clear; thus, its path through the ramus and the opaque lines above and below the canal may not be clearly visible. Also, the closer we get to the mental foramen, the less visible the canal becomes [15,16]. Cesar et.al in their studies offered 2 types of classification for the IAN canal in edentulous patients. Vertically, the canal is located either in the upper or in the lower half of the mandible. In 73.7% of males and 70% of females the nerve is located in the lower half of the mandible (therefore, presence of the canal in the inferior half of the mandible is the most common occurrence). Branching of the IAN in edentulous patients falls into one of the following patterns: Type 1: Presence of one single trunk with no branching. Type 2: Presence of a series of separate nerve branches (most common type). Type 3: Presence of a molar plexus. Type 4: Presence of proximal and distal plexuses. Type 2 is the most prevalent pattern where a main trunk along with several single branches is directed towards the superior border of the mandible. The second most prevalent pattern is the presence of a small molar plexus at the proximal half of the IAN or Type 3 (Figure 4) [17].

http://dx.doi.org/10.5772/52317

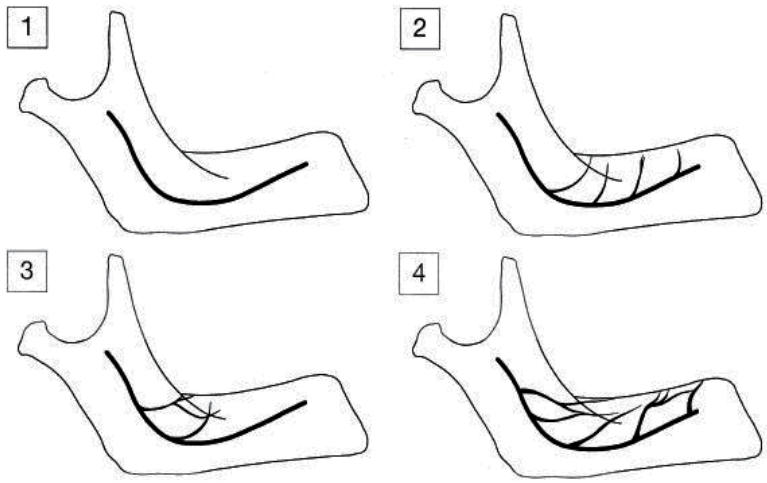

Figure 4. Variations of inferior alveolar nerve types in an edentulous mandible

2.2.2. The mental nerve

The mental nerve emerges at the mental foramen and divides beneath the depressor anguli oris muscle into 3 branches namely a descending branch that innervates the skin of the chin and 2 ascending branches innervating the skin and mucous membrane of the lower lip [13]. The patterns of emergence of the mental nerve at the mental foramen follows 1 of 3 patterns. Knowledge of these patterns is necessary for the surgeon before operating on this area. Type 1: The neurovascular bundle traverses anteriorly and then loops back to exit the mental foramen (anterior loop). Type 2: The nerve runs forward and exits the foramen along the canal path (absence of anterior loop). Type 3: The nerve exits the foramen perpendicular to the canal axis (absence of anterior loop). Type 1 is the most common pattern (61.5%) followed by type 2 (23.1%) and type 3 (15.4%) [18].

2.2.3. Contents of the mandibular canal and their location

Placing implants in areas adjacent to the IAN has increased significantly. Therefore, it is extremely important to know the contents of the canal and the exact location of components of the neurovascular bundle. According to histological examinations and MRI imaging, the inferior alveolar artery is located coronal to the nerve bundles inside the canal. Before entering the mandibular foramen, the artery is located inferior and posterior to the nerve. After entering the canal it changes its path at the mid length of the canal and runs superior and slightly medial to the nerve [18-20].The IAN usually has a round or oval cross section with a mean diameter of 2.2 mm. The mean diameter of the artery is 0.7 mm. The mean closest distance of the artery to a tooth apex is about 6 to 7 mm at the second molar area [20]. Yaghmaie et al. in 2011 confirmed the presence of lymphatic vessels in conjunction with the nerve trunks and blood vessels in all directions [21].The neurovascular bundle and its branches are responsi-

ble for sensation of pain, temperature, touch, pressure and proprioception of their innervated areas. The nerve is comprised of 1 or multiple fascicles. A collection of nerve fibers forms a fascicle. Microscopic examination of neurovascular bundles usually shows 2 to 8 axon bundles. Each fascicle contains about 500 to 1000 nerve fibers. Epineurium wraps around the fascicles, protects them and contains blood vessels for nutrition (Figure 5) [18-20].

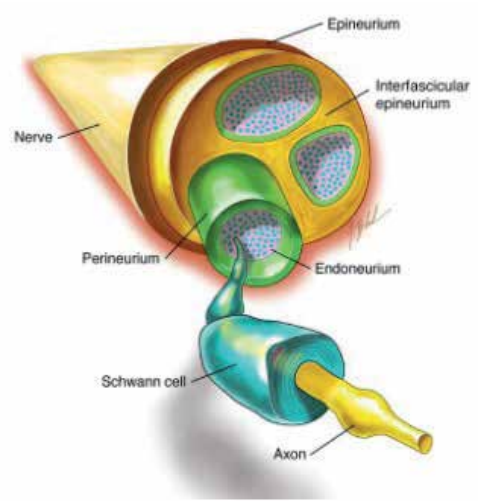

Figure 5. Schematic cross-section of the nerve. Nerve fascicles and fibers can be seen. Components in an orderly fashion from the outermost layer to the inner most include epineurium, perineurium, endoneurium and Schwann cells surrounding the axon.

2.2.4. Fascicular patterns

There are 3 fascicular patterns: The mono-fascicular pattern includes one big fascicle along with perineurium and epineurium layers surrounding it (i.e. the facial nerve). The oligo-fascicular pattern includes 2 to 10 fascicles each covered by perineurium. Fascicles are interconnected through the epineurium layer inbetween them; in this pattern, fascicles are usually of the same size (nerve roots C6 and C7 have the oligo-fascicular pattern). The poly-fascicular pattern includes more than 10 fascicles of various sizes i.e. inferior alveolar and lingual nerves (Figure 6) [18-20].

As mentioned earlier, the IAN has a poly-fascicular pattern. The outer nerve fibers of the bundle are called "mantle bundle". They usually innervate the proximal areas (molars). Following the administration of local anesthesia, this area is affected sooner and more efficiently since it is close to the side of the nerve bundle; whereas, core bundles innervate distal areas (central and lateral) and are affected later and less efficiently by local anesthetics. Various senses are affected when administering local anesthetics depending on the nerve diameter and presence or absence of a myelin sheath. For instance, signal transmission is slower in thinner non-myelinated nerve fibers. These fibers are affected more efficiently and more quickly by the local anesthetics than large diameter, myelinated fibers that have faster signal

http://dx.doi.org/10.5772/52317

transmission. Non-myelinated fibers (sympathetic C fibers responsible for vascular tonicity and slow transmission of pain) and partially myelinated fibers (A delta fibers, fast transmission of pain) are affected sooner by the local anesthetics and also return to their normal state more quickly. On the contrary, thicker myelinated fibers (like A alpha and A Beta) that transmit deep sensations, pressure and proprioception are affected by local anesthetics later. In conclusion, general senses are affected clinically by the local anesthetics in the following order: First cold sensation through the autonomic nerves, then heat, pain, touch, pressure, vibration and eventually proprioception. Contents of the canal are responsible for innervation of dental pulps, periodontium, dental alveoli and soft tissues anterior to the mental foramen. Dental pulps receive unmyelinated sympathetic nerve fibers from the superior cervical trunk which enter the pulp accompanied by arterioles. Dental pulps also receive A delta myelinated sensory nerve fibers as well as unmyelinated nerve fibers (both from the trigeminal ganglion); together they form a large plexus below the odontoblastic layer in the pulp (Raschkow's plexus). In the Raschkow's plexus myelinated fibers lose their myelin sheath and penetrate into the odontoblastic layer. Today, they consider the phenomenon of fluid mobility inside the odontoblastic tubes (hydrodynamic theory) to be responsible for stimulation of nerve endings and sensing pain [12]. There are 2 aspects in the sensation of pain namely, a physiologic aspect and a psychological aspect which together create the unpleasant psycho-physiologic and complex experience of pain. From the physiologic point of view, stimulation of specific nerves (like A delta and C fibers) and transmission of the signal to the trigeminal ganglion is called "transduction". Passing over the signal from this site to upper centers (thalamus and cortex) is called "transmission" and "modulation". The three mentioned pathways comprise the physiologic aspect of pain that combined with the psychological aspect (previous experience, cultural behaviors, psychological state and medical status) create the unpleasant complex experience of pain [12].

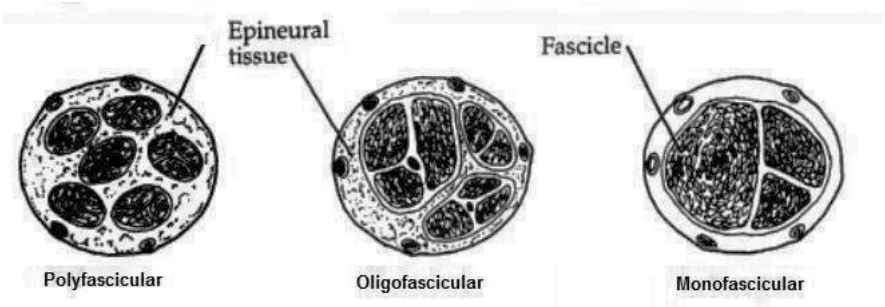

Figure 6. The three fascicular patterns. From right to left: Mono-fascicular, oligo-fascicular and poly-fascicular

2.2.5. Inferior alveolar nerve injury

Various factors can traumatize the IAN ranging from simple accidents like trauma from a needle during injection, bleeding around the nerve and even the local anesthetic drug itself, to maxillofacial traumas, pathologic lesions and surgical operations. Generally, the main nerve injuries are usually due to trauma or surgical operations among which, the most frequent ones are surgical extraction of mandibular third molars, endodontic treatment, implant placement, osteotomies (visor, sagittal, body of the mandible and subapical osteotomies), genioplasty, resection of mandibular cysts and tumors, partial mandibulectomy, fracture of the angle, ramus or body of the mandible, D.O. and IAN transpositioning. The nerve trunk is composed of 4 connective tissue sheaths. These membranes from the outermost to the innermost include mesoneurium, epineurium, perineurium and endoneurium. The mesoneurium suspends the nerve trunk within the soft tissue and contains vessels. The epineurium is a dense irregular connective tissue that protects the nerve against mechanical stress. The larger the epineurium (it usually measures 22 to 88% of the nerve diameter), the higher the nerve resistance against compressive forces compared to tensile forces. It should be mentioned that most nerve injuries are usually of a transient nature and will recover partially or completely. Epineural tissue wraps around nerve bundles and protects them against mechanical stress. Also, in many cases pressure due to severe inflammation or retention of fluid around the nerve trunk and subsequent development of transient ischemia in the epineurium cause clinical symptoms of neural dysfunction and disturbances. It is worth noting that the IAN is a poly-fascicular nerve. The smaller the number of nerve fascicles and the thicker the epineurium the more resistant the nerve is to pressure and vice versa (the greater the number of fascicles and the thinner the epineurium, the less resistant the nerves are towards pressure)[12,21-23]. It should be mentioned that poly-fascicular nerves like the IAN have a large number of small fascicles and therefore are more resistant to tensile forces compared to mono-fascicular or oligo-fascicular nerves [22].Perineurium wraps around the axon, Schwann cells and endoneurial sheath ; each nerve fiber is covered by the endoneurium sheath. Schwann cells are necessary for the axon to stay alive. They are the most sensitive cells to ischemia and radiation [12] (Figure 5).

2.2.6. Classification of nerve injury

There are 2 classifications available for nerve injury. The first was introduced by Seddon in 1943. He classified nerve injury into 3 types: Neuropraxia, Axonotmesis and Neurotmesis (from minor to major injury)[24]. The other classification was described by Sunderland [25] in 1987. He categorized 5 degrees of nerve injury : First degree where the axon and the covering sheath are intact. Epineural ischemia is probably the cause of the conduction block. Recovery is usually complete. Second degree where the axon is injured but endoneurium, perineurium and epineurium are intact. Recovery is often satisfactory. Third degree where the axon is injured but endoneurium is disrupted. However, of recovery. Fifth degree where there is complete transection with loss of continuity and less chance of spontaneous epineurium and perineurium are intact. Partial recovery may be achieved. Fourth degree where the axon, endoneurium and perineurium are all interrupted. However, epineurium is intact. There is a small chance recovery. Microscopic surgery is recommended (Table 1) [23].

http://dx.doi.org/10.5772/52317

Classification	Cause	Response	Recovery	Microscopic surgery
Neuropraxia(Sedd.) Grade 1 (Sunderland)	Compression, traction, small burn, acute infection	Neuritis, paresthesia, conduction block, no structural damage	Spontaneous recovery in less than 2 months	Not necessary unless a foreign body interrupts the process of nerve repair
Axonotmesis (Sedd.) Grade 2 (Sunder.)	Partial crushing, traction, burn, chemical trauma, hematoma, chronic infection	Intact epineurium, isolated axon loss, episodic dysesthesia	Spontaneous recovery within 2-4 months	Not indicated unless for decompression due to a foreign body or perineural fibrosis
Grade 3 (Sunder.)	Traction, crushing, contusion, burn, chemical trauma	Wallerian degeneration of axon, some internal fibrosis, peripheral pain	Poor sensory recovery, neuropathy for more than a year	Decompression and repair in case of poor function and continuous pain for 3 months
Grade 4 (Sunder.)	Complete crushing, severe traction, severe burn, direct chemical trauma	Neuroma-in-continuity, hypoesthesia, triggered hyperpathia	Permanent damage, minimal spontaneous recovery	Repair, resection of neuroma in case of unbearable pain after 3 months
Neurotmesis (Sedd.) Grade 5 (Sunder.)	Transverse incision on the nerve, laceration, laceration of the main nerve trunk	Neuroma at the site of incision, anesthesia, evolving deafferentation pain	Permanent damage, low spontaneous recovery	Resection of neuroma by neurorrhaphy or graft in case of poor function and lasting neuropathic pain

Table 1. Classification of nerve injury (Comparison of Sunderland and Seddon classifications)

2.2.7. Nerve changes following injury

Changes in central nervous system (CNS): The onset of such changes is 3-4 days or maximally 10-20 days after the injury. The neurons are in an anabolic state of protein synthesis. In humans, this can continue for years. The more proximal the location of injury, the higher the metabolic demand of the neuron. If the neuron is unable to supply such demand, cell death will occur. The best time for surgical repair when necessary is within 14 to 21 days after injury. After regeneration, the neuron gradually returns to its normal size and function.

Changes proximal to the site of injury: About an hour after trauma, a swelling develops within 1 cm proximal to the site of injury causing the area to enlarge up to 3 times its normal diameter. This swelling stays for a week or longer and then gradually subsides. On day 7, the proximal axon stump sprouts buds. These buds usually develop within a few millimeters distance from the site of injury from an intact node of Ranvier directed towards the dis-

tal end of the nerve. They cross the lesion on day 28, reconnect with the distal portion on day 42 and grow into it and advance (unless fibrous or scar tissue has formed). The more proximal the location of the injury, the longer it takes for a sprout to cross the lesion as the result of a more extensive inflammatory reaction.

Changes at the site of injury: During the next few hours after injury, proliferation of macrophages, perineural and epineural fibroblasts and Schwann cells occurs. On days 2 and 3, cell proliferation is seen proximal and distal to the site of injury. On day 7, Schwann cells play the major role. Fibrosis at the site of injury and imperfect positioning of regenerative fibers can result in formation of a neuroma.

Changes distal to the site of injury: Wallerian degeneration is the major characteristic of such changes in this area preparing the location for axonal sprouts budding out from the proximal stump. Death of all cellular components distal to the injury site is the key initiating event for Wallerian degeneration. On day 7 post-injury, the majority of cells at the distal portion disintegrate. This process is facilitated by the action of enzymes. By day 21, most cellular debris is engulfed and phagocytosed by Schwann cells. This cellular debridement is usually completed by day 42. Endoneurial tube becomes smaller, shrunken or even obstructed due to cell proliferation and excessive collagen formation. Its diameter is decreased by 50% after 3 months and only 10 to 25% of its primary diameter may be left open after 12 months. This phenomenon is called distal atrophy when the entire nerve trunk distal to the site of injury is shrunken and atrophied. Tubules formed by Schwann cells and surrounded by collagen guide the sprouts distally. Although the number of sprouts is various and may be up to 4 times the normal number, during regeneration volume and number of sprouts decrease and the final number will end up to be smaller than the original number and the diameter of the new axon will be smaller as well. When a sprout reaches the distal tube, the metabolic activity of the Schwann cells increases again and myelin is reproduced by the Schwann cells. However, the quality of the newly formed myelin is not as good as the quality of the primary myelin. The new axon has a smaller diameter and is placed in thinner endoneurial tubes. The new myelin is not similar to the old one. The nodes of Ranvier are shorter and therefore cause a decrease in nerve conduction velocity in this area. Axon regeneration speed is different in various circumstances but it is on average 1 to 3 mm a day.

Changes in the target organ: At the target sensory organ, receptors suffer from progressive deformities but following reinnervation even after several years the target organ will have no sensory impairment or disturbances. For skin flaps as well, reinnervation resumes pain, temperature and touch sensations perfectly. For target motor organs however, reinnervation of the respected muscle does not occur even 12 months after nerve transection. This is not because of changes in neuromuscular junction end plate but probably due to irreversible interstitial fibrosis in muscle fibers [13].

Clinical examination of sensory impairment of the lower lip following IAN injury:

Before discussing the clinical examinations, we explain the definition of common clinical terms (Table 2).

http://dx.doi.org/10.5772/52317

Anesthesia	Absence of any sensation
Paresthesia	Abnormal sensation even spontaneously or for no reason
Analgesia	No pain in response to a normally painful stimulus
Dysesthesia	An unpleasant abnormal sensation that can be spontaneous or for a reason
Hyperalgesia	Hypersensitivity to harmful stimuli
Hyperesthesia	Hypersensitivity to all stimuli except for special senses
Hypoalgesia	Decreased sensitivity to stimuli
Hypoesthesia	Decreased sensitivity to all stimuli except for special senses
Allodynia	Pain due to a stimulus that does not normally cause pain
Neuralgia	Pain that is distributed in one or several nerve fibers
Deafferentation pain	Pain due to decreased sensory afferents into the CNS
Neuropathic pain	Pain due to a primary lesion or nervous system dysfunction
Causalgia	Burning pain immediately or several months after injury
Anesthesia dolorosa	Pain felt in an area which is completely numb to touch
Synesthesia	Stimulation of one sensory or cognitive pathway leads to experience in a second cognitive or sensory pathway due to misdirected axonal buds resulting in misperception of the location of touch or pain
Central pain	Pain due to a primary lesion or central nervous system dysfunction
Hyperpathia	A painful syndrome characterized by hyper-responsiveness to a stimulus. Hyperpathia may be associated with hyperesthesia, hyperalgesia or dysesthesia

Table 2. Frequently used terms during clinical examination of neurosensory disturbances

2.2.8. Clinical tests

Static light touch: For this test a bunch of nylon filaments with same length and different thickness mounted on a plastic handle is used. The patient closes his eyes and says "yes" whenever he feels a light touch to the face and points to the exact spot where he felt the touch. Brush directional discrimination: For this test, the finest nylon filaments from the previous test or a brush with more filaments are used. The patient states if any sensation is detected and in which direction the filament or brush moved. **Two point discrimination**: In this test the distance between two points is altered. With the patient's eyes closed the test is initiated with the points essentially touching so that the patient is able to discriminate only one point. **Pin pressure nociception**: For this test the most common instrument is the algesimeter which is a simple instrument made from a no.4 Taylor needle and an orthodontic strain gauge. The sharp point of the needle is used to test nociception and the blunt end to test for pressure detection and hyperpathia. The needle is placed vertically on the skin. The pressure is increased every few seconds until the patient feels the sharpness (usually with 15 to 25 g) and then the needle is gently removed. The same is done for the affected area as well. No response to pin pressure up to 100 g is defined as anesthesia. An exaggerated response to pin pressure relative to an unaffected area is defined as hyperalgesia and a reduced response to touch relative to an unaffected area is considered as hypoalgesia. **Thermal discrimination**: This is an adjuvant test and is not es-

sential. Minnesota Thermal Disks are the most common instruments used for this assessment. Ice, ethyl chloride spray, acetone, and water are also used. The simplest method is to use an applicator dipped into acetone or ethyl chloride. When pain is a symptom of nerve injury, diagnostic nerve blocks using local anesthesia can be very helpful in deciding whether or not micro-reconstructive surgery is indicated. It is important to start with low concentrations of anesthetic drug. Injections should be performed starting from the periphery towards the center to ease the pain. If the pain is not alleviated there is a chance that collateral sprouts from the other side are present. If the persisting pain is aggravated by cold, is spontaneous, and of burning type and long lasting, then allodynia, hyperpathia, causalgia and sympathetic pain should considered in the differential diagnosis. In such cases, diagnostic stellate ganglion block is helpful in differentiating causalgia from sympathetic pain [10,12,24]. There are various causes of pain following traumatic nerve injury including nerve compression, neuroma, anesthesia dolorosa, causalgia and sympathetic pain, central pain and deafferentation, nerve laceration, nerve ischemia and chemical stimulation.

Clinical and radiographic evaluation. For clinical assessment of a patient who is a candidate for dental implants and suffers from atrophic mandibular alveolar ridge should first prepare study casts and then the occlusal relationship should be recorded. The following points should also be considered:

The area of the edentulous atrophic alveolar ridge: If the edentulous area extends interiorly up to the canine the surgeon should consider mental nerve transpositioning.[1]. In edentulous patients, absence of incisal sensation following nerve distalization does not cause problems but in patients with incisal teeth this can result in an unpleasant sensation in the anterior segment which is usually described as a sense of dullness in these teeth. The distance between the occlusal surface of maxillary teeth and mandibular alveolar ridge. In some cases, despite alveolar ridge resorption there is not enough space between the occlusal surface of the maxillary teeth and the mandibular ridge which is required for placing the implant prosthesis. It is usually due to the patient's previous occlusion (mainly in deep bite cases) or over-eruption of the opposing teeth. Augmentative methods often cannot be used (Figure 7]. In such cases, the only available option seems to be nerve transpositioning [3,22,26].

Evaluation of the relationship between the mandibular alveolar ridge and maxillary alveolar ridge in the horizontal plane: The necessity of lateral augmentation simultaneous with nerve transposition or vertical augmentation should also be evaluated by clinical examination and study of the patient's casts.

Radiographic evaluation: Every patient who is a candidate for nerve transposition is required to obtain panoramic radiography and CBCT scans (Figure 7).

The length of bone above the canal, anomalies, distance of the canal from the buccal cortex and also thickness of the cortex for ostectomy are all evaluated on panoramic radiography. Exact location and precise anatomy of the mental foramen and anterior loop can also be evaluated [27]. In rare cases, the IAN canal may be completely attached to the medial or lat-

http://dx.doi.org/10.5772/52317

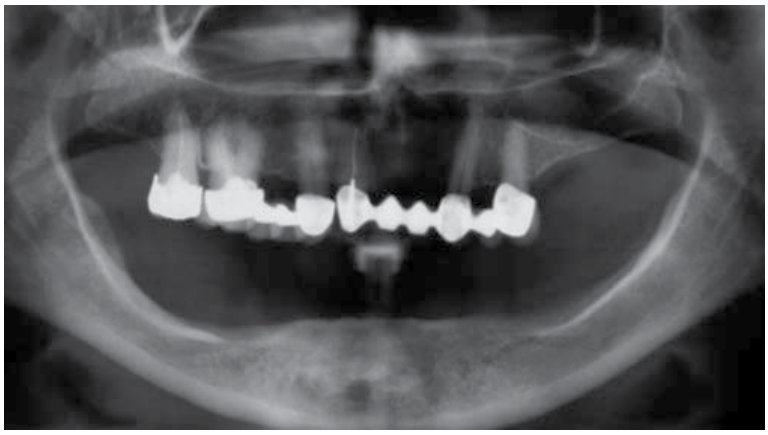

Figure 7. Panoramic radiography of an atrophic posterior mandible. Note the inadequate length of bone over the canal for implant placement.

eral cortex on CBCT. In such cases, implants can be easily placed buccally or lingually to the canal with no need for extensive surgery. Additionally, by analysis and reconstruction of scanned images using CAD-CAM, it is feasible to determine the path of the canal and place the implants in atrophic areas.

2.3. Indications, contraindications and limitations

Babbush mentioned several indications for nerve transpositioning; namely placement of removable prosthetics, stabilizing the remaining anterior teeth, stabilizing the temporomandibular joint, and establishing muscular balance following reconstruction of the dentoalveolar system. He also discussed some related limitations. This procedure is technically difficult and requires adequate expertise. The surgeon should have adequate experience, sufficient anatomical knowledge and necessary skills to fully manage peri-operative and post-operative complications. Accordingly, the most significant risk of surgery is nerve injury due to surgical manipulations and the surgical procedure itself. Although rare, mandibular fracture should also be considered as a risk factor especially in cases with severe mandibular atrophy (Figure 8) [28].

Resenquise et al. in their studies on nerve transpositioning procedure mentioned the following indications and contraindications for this operation:

Indications: Less than 10-11 mm bone height above the canal, when the quality of the spongy bone does not provide sufficient stability for implant placement

Contraindications: Height of bone over the canal is less than 3 mm. The patient has thick cortical bone buccally and thin neurovascular bundle. The patient is susceptible to infection or bleeding. Limitation in accessing the surgical site [9-11,29,30]

According to author's personal experience, nerve transpositioning in cases where the bone height over the canal is less than 3 mm is still feasible. We can transpose the nerve from the

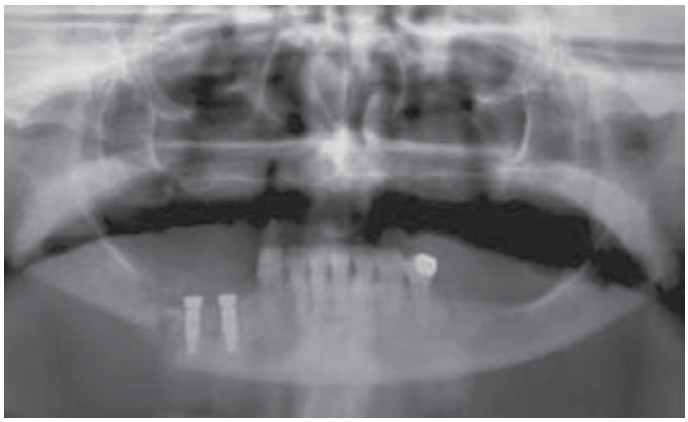

Figure 8. Mandibular fracture in a patient with severe mandibular atrophy following nerve transpositioning.

alveolar crest laterally, and after placing the implant with bone graft material. More details in this regard will be discussed subsequently.

2.4. Surgical procedure of nerve transpositioning

Pre-operative consultation: Before choosing nerve transpositioning, we should first scrutinize the required criteria. According to the literature, 100% of patients who undergo nerve transposition develop various degrees of sensory nerve dysfunction of the lips. Therefore, the patient and his/her family members should be well informed relevant to the phases of treatment, duration of surgery, post-operative general complications and most importantly provided with knowledge about the post-operative lip paresthesia which will definitely occur and may last for up to 6 months and in some cases it lasts longer or is very severe may require microscopic surgery [10,31-33]. Despite the above mentioned explanations, the patient may not fully comprehend what paresthesia actually feels like. In such cases, we recommend performing an inferior alveolar nerve block for the patient using bupivacaine for anesthesia so that the patient can experience anesthesia and paresthesia for 8 to 12 hours. We should also explain the advantages of this treatment modality for the patient including shorter treatment duration, no need for autogenous bone grafts and no donor site morbidity, minimum use of bone replacement material and obviating the need for additional surgery [9,10,33].

2.4.1. Technique

Inferior alveolar nerve transpositioning for implant placement is usually performed by 2 techniques: **IAN transpositioning without mental nerve transpositioning or involvement of mental foramen:** This is usually employed when the edentulous area and alveolar ridge resorption does not include the premolars. This technique has been called nerve lateralization in some articles (Figure 9-12 A). **IAN transpositioning with mental nerve transpositioning or involvement of mental foramen:** In cases where the edentulous area and ridge

http://dx.doi.org/10.5772/52317

resorption include the premolar teeth: there is a need for transpositioning of mental neurovascular bundle and even transection of incisal nerve and transposing the nerve distally (associated with mental nerve and mental foramen involvement). This method has also been called nerve distalization by some [1,9,28,34] (Figure 12 B).

Phases of surgery: Nerve transpositioning can be performed under local anesthesia alone, local anesthesia along with sedation or under general anesthesia based on the patient's condition. Local anesthesia includes inferior alveolar nerve block plus local infiltrating anesthesia in the form of lidocaine plus vasoconstrictor at the buccal mucosa. 1-Incision is made on the alveolar crest starting from the anterior border of the ramus forward. At the mesial surface of the mandibular canine a releasing incision is made anteriorly and towards the vestibular sulcus in order to avoid injuring mental nerve branches. In cases where the treatment plan includes placement of dental implants in the same surgical step, soft tissue incision should be made in a way that part of keratinized gingiva is placed in the buccal and part of it on the lingual side of the healing abutment (Figures 10 and 11) [1,31-35].

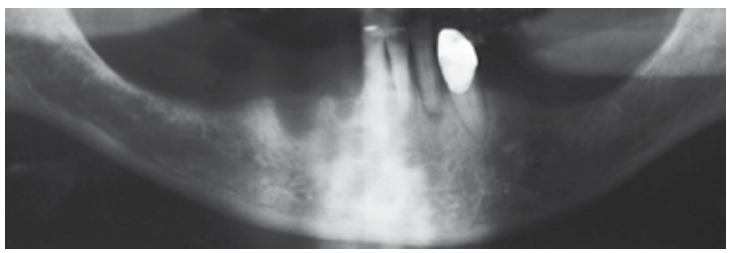

Figure 9. A patient with edentulous posterior mandibular region along with bone resorption who is a candidate for nerve transposition surgery.

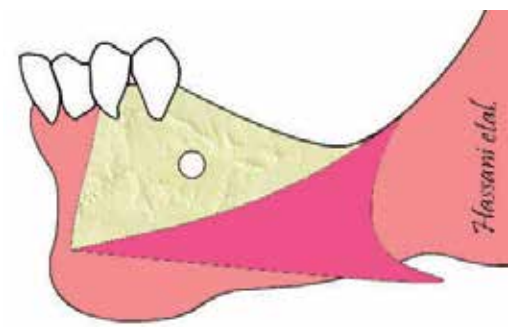

Figure 10. Flap design: An incision is made on the alveolar crest along with a releasing incision at the mesial of mandibular canine.

2-Retracting the mucoperiosteal flap is done so that the mental foramen is totally exposed and the dissection is extended towards the inferior border. Considering the radiographic and CBCT evaluations along with the fact that the neurovascular canal is usually located 2 mm below the mental foramen, it is necessary to expose the lateral surface of the body of the

mandible and release the periosteum around the mental nerve (Figure 10) [1,36]. 3-Bone removal on the lateral surface of the canal is done while preserving the maximum thickness of buccal bone as this especially important. Presence of adequate bone thickness in this area results in better and faster healing of the bone defect adjacent to the implant where nerve transposition has been performed. Bone can be removed using a diamond round bur or piezosurgery device [1,6].

In the first technique which is usually performed for treatments other than dental implants a piece of bone is removed as a block and then the canal is exposed. This method can be indicated for simultaneous implant surgery when there is adequate bone height over the canal. In such cases, even after resecting a bone block, a sufficient amount of bone still remains at the lateral side of the implant [26]. Rosenquist reported that in this method, it is difficult to maintain a proper angulation when placing the implant because a great extent of buccal bone has been removed for nerve transposition and accessing the canal [30]. In patients who are candidates for implants, cortical bone preferably should not be removed as a block because in such patients there is limited amount of bone available in the superior and lateral sides of the canal which should be preserved. If the surgical technique does not include manipulation of the mental nerve, bone is removed using a round bur number 700 or 701, a straight handpiece and copious normal saline for irrigation or a piezosurgery device. Bone removal is initiated 3-4 mm distal to the mental foramen and follows the canal path posteriorly and superiorly. Bone removal should extend 4-6 mm posterior to the intended location of the last implant. We should try to remove the smallest amount of bone possible from the buccal cortex. Excessive bone removal along with extensive drilling for implant placement can result in temporary mandibular weakening followed by increased risk of mandibular fracture which has been reported in the literature. Bone preservation helps in primary and final implant stability and shortens the recovery time. After removing the cortical bone, a curette may be used for removal of spongy bone and cortical layer of the canal in cases where the cortical layer surrounding the canal is not dense or thick. A special instrument (Hassani nerve protector) is required to protect the nerve while the cortical layer has to be removed using surgical burs or piezosurgery device. Bone removal in close vicinity to the neurovascular bundle should be performed patiently and thoroughly. This is usually performed using special curettes parallel to the surface of nerve bundles in an antero-posterior direction. Tiny bone spicules around the nerve should be removed. The area should be thoroughly irrigated so that the nerve bundle can be clearly seen (Figure 11 A - D) [1,2,4,9,10].

Another method that has been suggested is drilling the bone surrounding the canal using a hand piece and a round bur. The surgeon carefully enters a probe (round end with no sharp edge) into the canal through the mental foramen and determines the canal path. Then according to this test and after evaluating the canal path on the radiographs, the surgeon inserts the tip of the nerve protector into the canal. This instrument has been designed, patented and manufactured by the author (Hassani nerve protector). This instrument should be placed in between the nerve and the bone in order to protect the nerve. The buccal bone is drilled using a bur. By directing the bur distally, the nerve protector is also moved distally inbetween the nerve and bone to protect the nerve at all times. The bone chips are collected

http://dx.doi.org/10.5772/52317

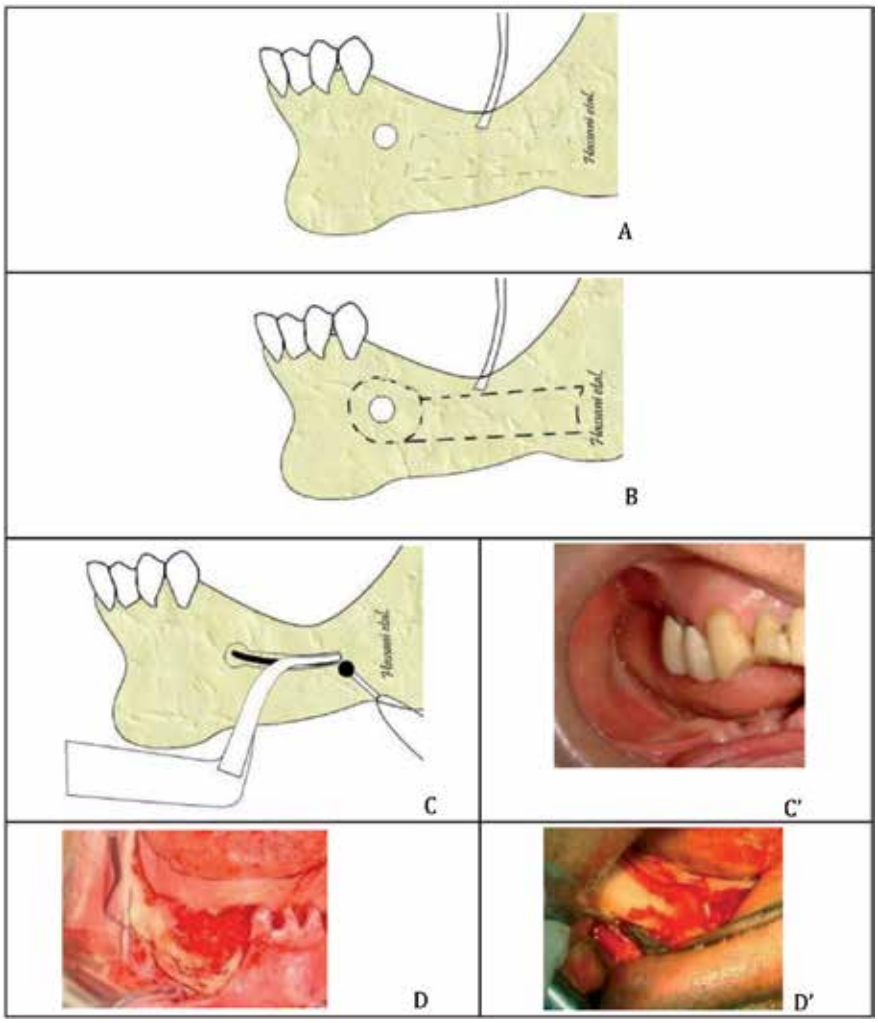

Figure 11. Different designs of osteotomy A: Method of removing bone block without the involvement of mental foramen: In this technique, a bur is used to outline the location of bone block on mandibular buccal cortex by a distance from the inferior border of mandible and alveolar crest. The mesial incision should be made in 3-4 mm away from the mental foramen. Then the buccal bone surrounding the canal is removed carefully by reciprocal motion using an osteotome (Chisel). The remaining spongy bone around the canal is collected while protecting the nerve and stored for bone grafting. At this time the nerve is exposed. This method is associated with the risk of losing the buccal bone. B: Removal of bone block along with mental foramen involvement: Similar to the previous method, a bur is used to outline the bone block area. An osteotome (chisel) is used to remove the bone block and the spongy bone is removed using a curette. In this technique, the preparation design includes the surroundings of the mental foramen. While keeping an adequate distance from mental foramen a circle is drawn with the center being the foramen using a round bur and the cortical bone is resected. By doing so, we have 2 bone blocks one posterior to the mental foramen and the other one around it through which the nerve has passed. This mesial segment with the nerve passing through it is put aside with great caution and when operation is over it is put back in its original location. This technique is indicated when the edentulous atrophic area has extended and involved the premolar area and there is a need for replacing the lost premolar teeth. This method carries the risk of incisal nerve transection by the surgeon. This method has been called nerve distalization. C-D: Oral views.

by a bone collector in the process. In this technique, while the nerve is protected minimum amount of bone is removed from the buccal cortex and the maximum amount of bone is preserved in an atrophic ridge for implant placement which results in maximum primary stability of the implant. Also, mandibular bone weakening is minimal in this method which is a great advantage of this technique. The neurovascular bundle inside the canal is freed using special curettes and is moved laterally using a nerve hook (Figure 12). Then a 10 mm wide gauze cord or elastic band is passed below it retracting the nerve away from the surgical site decreasing ischemic trauma to the nerve. It also retracts the nerve away from the surgical site during the operation reducing the risk of nerve damage (Figure 13) [9,34,24,35].

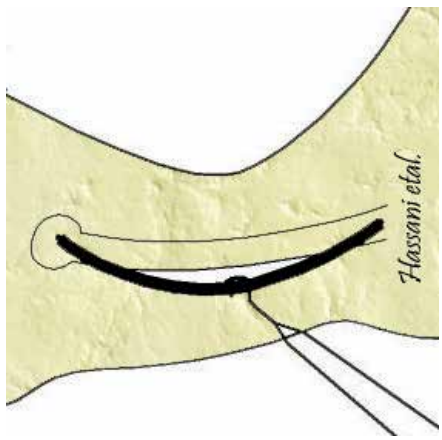

Figure 12. Spongy bone surrounding the nerve is removed using a spoon shaped curette. The nerve is released and slowly retracted from the canal using a nerve hook. The hook should be rounded at the end and polished.

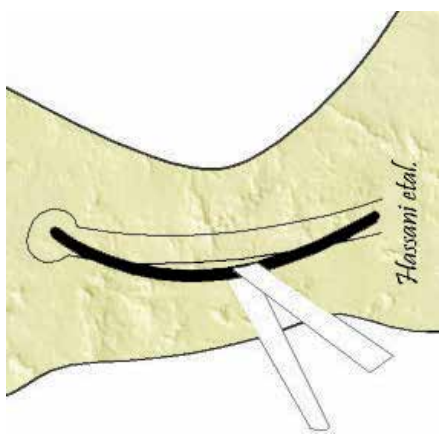

Figure 13. The nerve is retracted from the site using a gauze band 10 mm wide or elastic band in order to protect it from any damage during implant placement. The advantage of elastic band is that if it is pulled during surgery the traction is neutralized by the band and not transferred to the nerve.

http://dx.doi.org/10.5772/52317

Some studies recommend piezosurgery for bone removal in nerve transposition surgery. This device causes vibrations in the range of 20-200 micrometers and cuts through the mineralized tissue completely and smoothly. If soft tissue or the neurovascular bundle comes in contact with this device it stops to function because the device is made in a way that it stops working when it is in contact with unmineralized tissue. This device is especially beneficial when a small osteotomy is going to be performed [9]. Among the disadvantages of this device we can mention the long duration of time that it takes to remove bone. Also, there is still controversy regarding the indications of this device and some believe that vibrations may damage the nerve. Further investigations are required regarding indications of using this device in nerve transposition surgery [9,10].

Preparing the implant placement site and implant positioning: In this phase, the mucoperiosteal flap and nerve are raised and the surgeon starts drilling. The implant should be long enough to pass the canal and engage the basal below the canal to achieve sufficient primary stability. Then, the implant is inserted (Figures 14 and 15) [1,9,31].

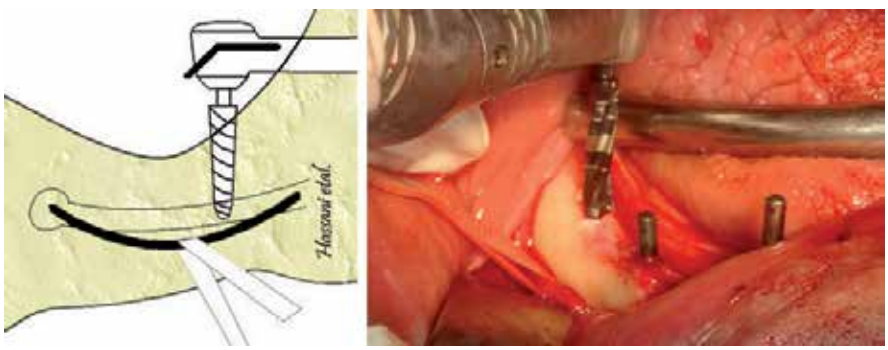

Figure 14. Cavity preparation and bone drilling when the nerve is retracted from the site using a umbilical tape 10 mm wide or elastic band in order to protect it from any damage during drilling or implant placement.(Surgical Drill, Dentium Co.)

Repositioning the neurovascular bundle inside the canal: Before this phase, the surgeon should decide whether or not to place materials between the implant and the nerve. There is a lot of controversy in this regard and some studies have been performed on animal models in this respect. In a study by Yoshimoto et al. on rabbits, no difference was observed microscopically after placing and not placing a membrane between the implant and the nerve bundle [37]. However, on animal model studies clinical signs and symptoms of nerve stimulation cannot be assessed and only microscopic evaluation is feasible. The author's preference is to place a collagen membrane or bone material in between the implant and nerve. A potential advantage of bone over a membrane is that if proper healing occurs in the area, the contact area of implant and bone will increase (Figure 16). Before releasing the nerve from the elastic band, the mentioned material must be inserted in between the nerve and implant. This way the nerve will be in a vent that is adjacent to implants medially and covered by the mucoperiosteal flap. Alternatively, the nerve may be left to lie passively outside of the canal.

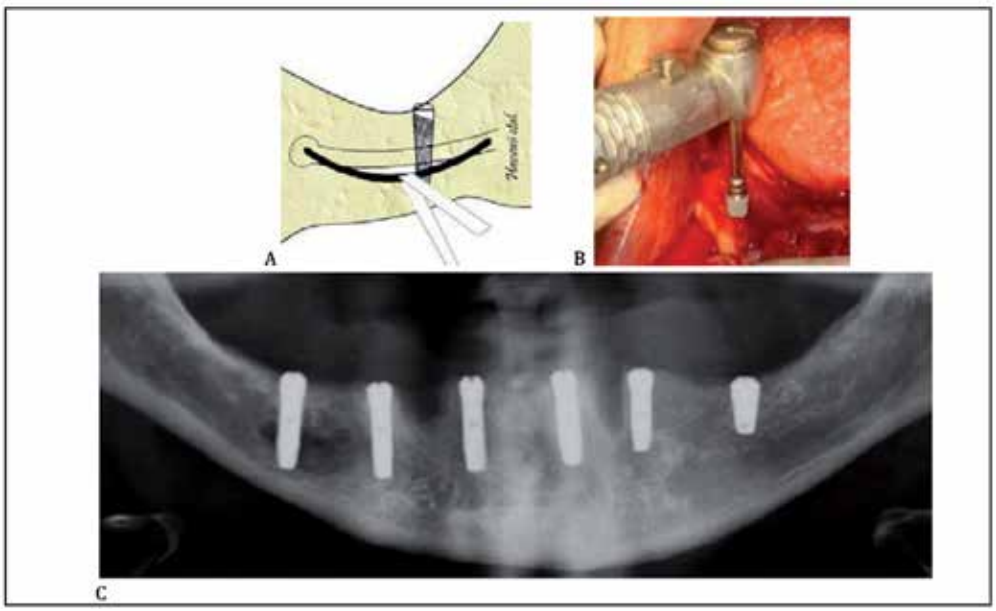

Figure 15. A-C: Implant is placed into the bone. Implant can be seen by the surgeon in part of its insertion path when passing the empty nerve canal. Therefore, the surgeon can insert the implant a few centimeters below the canal into the basal bone and benefit from the advantages of a bicortical implant such as adequate primary stability and shorter recovery time.(Implantium Implants,Dentium Co.)

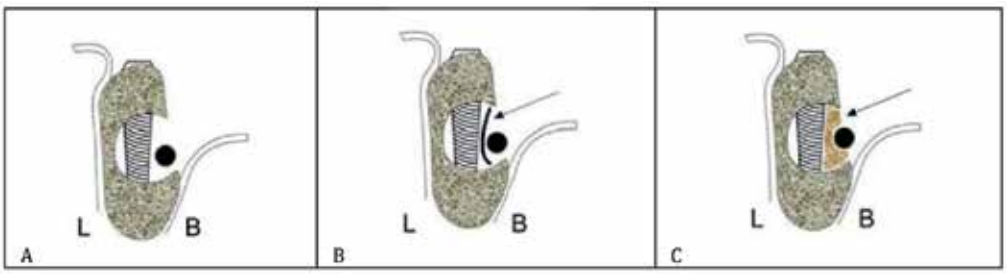

Figure 16. Replacing the nerve inside the canal and different viewpoints in this regard: A: Some believe that there is no need for placing a membrane or any material to prevent contact of implant and nerve. The nerve is placed inside the canal alone. B: Some believe that it is necessary to place a membrane (arrow) between the implant and the nerve to prevent risk of sensory disturbances in the future. C: Inserting bone dust (arrow) collected by bone collector between the implant and nerve (based on the author's experience this way the nerve is not in direct contact with the implant and bone dusts also enhances the process of bone regeneration and repair resulting in formation of more bone around the implant). Alloplast or xenograft bone powder may also be used.

Suturing and closing the wound: The decision to submerge the implant using a cover screw or using a healing abutment for single phase implant surgery should be made based on the condition of surgical site, presence of adequate amount of bone at alveolar crest and type of implant used. The surgical wound is then sutured (Figure 17 and 18).

http://dx.doi.org/10.5772/52317

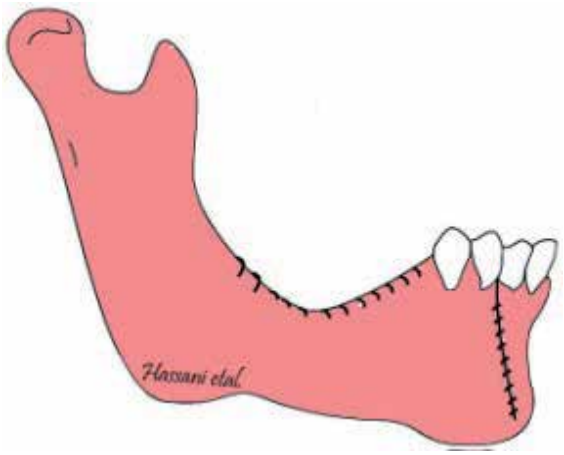

Figure 17. Gingival flap is put back in its location and sutured.

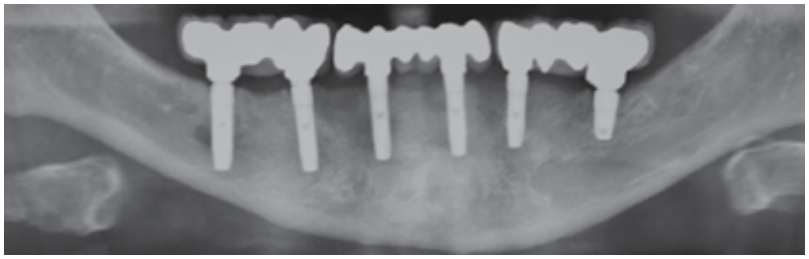

Figure 18. Same patient in Figure 16; Two years after loading the implants. Note the bone level. (Implantium Implants, Dentium Co.)

In patients with an atrophic alveolar ridge involving the premolar area or those with an edentulous mandibular ridge along with alveolar crest atrophy who need implant placement IAN transposition in the posterior mandible and mental nerve transposition is also necessary most of the time. This transposition is usually associated with incisal nerve transection. In such cases, the patients will not have any problems related to incisal nerve transection but in cases where transposition of the nerve is intended and the patient has vital anterior mandibular teeth, nerve transection may result in patient having an unpleasant sensation in these teeth. In some cases, even root canal therapy may be required. However, several studies have reported that no problems related to anterior mandibular teeth were seen [1,9,35].

Sectioning the incisal branch of the inferior alveolar nerve, releasing the neurovascular bundle and moving it backwards in order to avoid traction is called nerve distalization [9]. Based on the author's experience, in many cases it is possible to transpose the mental nerve without sectioning the incisal nerve. In the method of nerve transposition without releasing the mental nerve, great traction force is exerted on the nerve when keeping it out of the surgical site. According to the literature, the highest number of nerve injuries occurs during an-

terior osteotomy because the nerve trunk becomes thinner at mental foramen and is therefore more susceptible to injury. That is why nerve transposition without involving the mental foramen has the least sensory complications and side effects. According to the literature, by preserving 3-4 mm bone distal to the mental foramen during nerve transposition we can reduce inferior alveolar nerve damage because the nerve is thinner and more susceptible to injury at this specific location [32].

Vasconcelos et al. believes that at least 5 mm bone height above the canal is necessary in case selection for nerve transposition whereas, Kahnberg and colleagues believe that 2 to 3 mm bone thickness above the canal is adequate [9,10]. In cases where minimum requirement of bone height above the canal does not exist some authors suggest to do a bone graft before nerve transposition and implant placement [9]. However, fixing the grafts especially blocks of autogenous bone to the limited remaining bone above the canal is difficult and is associated with a risk of nerve injury by the screws. Based on the author's experience in such cases we can transpose the nerve from the alveolar crest laterally. Bone is removed from the alveolar crest, and when the nerve is exposed we move it upward and outward and start drilling for implant placement from inside the canal while the nerve is retracted laterally from the buccal cortex. Bone graft is placed inside the canal anterior and posterior to the implant. The nerve is placed into a newly formed groove from the posterior area of the last implant (Figure 19).

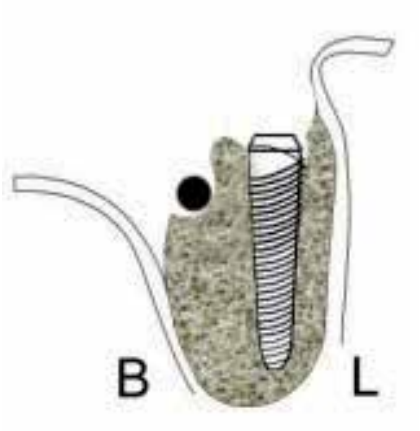

Figure 19. The IAN is located at the alveolar crest following ridge atrophy. The nerve is removed from the crest, implant hole is prepared from inside the canal, the implant is positioned and finally the nerve is repositioned in the lateral cortex of the mandible.

Histological findings associated with nerve transposition and implant placement. Yoshimoto and colleagues evaluated the condition of tissues surrounding the implant 8 weeks after nerve transposition surgery and simultaneous implant placement; they observed that none of the implants were exposed and all were perfectly stable. No infection or inflammation was observed at the site. In all cases bone formation between the implant and neurovascular bundle was observed and no direct contact was seen between them.

Research demonstrates that bone formation around the implant surface sand blasted with aluminum oxide was 2.5 times greater than a smooth titanium surface. Bone formation around the neurovascular bundle prevents the implant from having direct physical contact with the bundle and therefore the nerve structure will be protected from mechanical or thermal trauma. Microscopic sections show the formation of a vascular network in the adjacent tissues which proves that there is no need for placing a barrier or any kind of graft material to separate the nerve from the implant [35].

In Kahnberg et al. study on a dog, healing was not complete after 14 weeks but none of the implants were exposed. Histological examination showed that in cases where membrane had not been placed a small contact was present between the nerve bundle and the implant. Plasma cells, macrophages, polymorphonuclears, and granulocytes were alternately seen next to the membrane. Several giant cells and macrophages were also seen. Vascular buds were seen where membrane had been placed (compared to areas where no membrane had been used). In some cases, a capsule with less than 10 μm thickness was seen in some areas between the implant and the nerve. When membrane is used the distance between the nerve bundle and the implant will be 4 to 8 times greater. The mean distance between the implant and the nerve was 348.3 μm when using a membrane and 39.8 μm when not using it. There is no contact between the nerve and the implant when using a membrane but the bone was not seen around the implant either [38].

2.5. Important considerations in nerve transposition surgery

2.5.1. Patient selection

The surgical process is complicated and occurrence of sensory disturbances is definite. Therefore, the surgeon should evaluate the patient's mental condition. Some people are stressed out and over sensitive even towards the smallest surgical complications. Such patients do not have tolerance and compatibility skills and therefore are not good candidates for nerve transposition surgery. Providing data and acquainting the patient with phases of surgery and probable complications: Thorough explanation should be provided for the patient in an understandable and comprehendible manner regarding surgical and neural complications. The sense of anesthesia that may occur should be well described for the patient and it also should be mentioned that the anesthesia may be permanent and irreversible.

1. CBCT should be obtained for precise evaluation of the canal and bone thickness around it.
2. Dexamethasone should be administered before the surgery
3. The surgeon should have full knowledge regarding anatomy and physiopathology of nerve injury and be able to evaluate the clinical course of nerve dysfunction after the surgery.
4. The surgeon's skill and expertise are very important and magnification loops should be used.

5. Delicate instruments required for this type of surgery should be available (for minimal injury). Also, the surgeon should have the knowledge and skills for repairing the nerve in case serious damage is done to the nerve during surgery.
6. In cases where the canal is located in the center or lingually on CBCT, the surgeon should expect a more complex surgery.
7. In cases where the nerve transposition surgery extends further posterior and involves the 2nd molar area, the surgery can be more complicated due to the thicker cortical bone and limited access to the area.
8. Using low level laser after surgery reduces the inflammation and improves recovery.
9. The surgeon should be familiar with and have adequate skills regarding nerve reconstruction surgery and the instruments required for it.

2.5.2. Post-operative measures

Antibiotic therapy and administration of analgesics and NSAIDs post-operatively are similar to that of implant surgery and there are no specific recommendations in this regard in the literature. Antibiotic and corticosteroid prophylaxis is recommended because of the extensiveness and duration of surgery. Using corticosteroids pre- and post-operatively helps in decreasing the symptoms. However, there is no consensus in this regard but since inflammation can be among the causes of nerve dysfunction, corticosteroid therapy can be beneficial.

The most common sensory complications following nerve transposition are hypoesthesia, paresthesia and hyperesthesia. The most common causes of nerve dysfunction include the mechanical trauma to the nerve and ischemia following extracting the bundle from the canal, nerve traction during surgery, edema and probable hematoma and or chronic compression after the surgery [9,10]. According to Hirsch and Branemark, the main cause of sensory disturbances is nutritional impairment of the nerve due to injury to the microvascular circulation of nerve fibers as the result of mechanical trauma. Thermal and pain sensation nerve fibers are more resistant to compressive traumatic forces and ischemia than larger fibers responsible for touch sensation [1]. Therefore, great attention should be paid during and after surgery to minimize the factors responsible for ischemia and mechanical trauma such as;

1. Avoiding exerting too much traction upon the nerve and when lateralizing the nerve and during nerve transposition, try to transform the contact point to a contact area.
2. During ostectomy care must be taken not to injure the nerve with rotary instruments, curette or elevator. When removing the bone cortex over the nerve, the author recommends using the nerve protector designed specifically for this purpose by the author himself; it fits inside the nerve canal over the nerve (Figure12 C and D'). Direct contact of rotary or other surgical instruments with the nerve is among the most serious injuries in this type of surgery.
3. In order to lateralize the nerve, use instruments with minimal traction and prevent ischemia to the nerve. Instruments that have large contact area with the nerve and mini-

http://dx.doi.org/10.5772/52317

mum thickness are preferred to be placed between the nerve and the location of drilling for implant placement.

4. The retracted bundle should be constantly moistened by normal saline.

5. Prevent development of hematoma because it applies pressure on the nerve trunk.

6. After inserting the implant, autogenous bone powder or collagen membrane should be placed between the implant and the nerve bundle (as discussed earlier).

7. Use of anti-inflammatory drugs before and after surgery: Some articles have recommended administration of corticosteroids pre- and post-operatively or high dose ibuprofen 800 mg TDS for 3 weeks [39].

8. Using vitamin B complex supplements (studies have shown that B complex and vitamin E supplementation improves nerve function and decreases neuropathy. Vitamin B family especially B1 and B12 can prevent nerve injury and improve natural growth of the nerve by preserving and protecting the lipid-rich covering of nerve terminals. Alcohol consumption causes vitamin B deficiency and therefore should be avoided [40].

9. Use of low level laser (LLL) immediately after surgery 4 times a week for 10 sessions. Studies suggest using LLL as a non-invasive non-surgical method for faster recovery from paresthesia may obviate the need for surgery in nerve injuries. Use of GaA1As laser causes the patient's subjective and objective symptoms to disappear. Low level laser increases nerve function and capacity of myelin production [10,41]. Bleeding inside the canal can cause a hematoma or compartment syndrome [42]. The incidence of post-operative neuropraxia, permanent anesthesia and paresthesia decreases when only the thicker parts of the neurovascular bundle are manipulated compared to the manipulation of thinner parts or terminal branches. Therefore, although nerve transposition in more posterior areas like the 2nd molar area is technically more complex, it is usually associated with smaller risk of serious and long term injuries to the nerve because the neurovascular bundle is thicker in this region. Regeneration process of nerve following mild compression or crushing takes several weeks to 6 months [10]. If recovery does not occur in this time period, we should consider the possibility of permanent anesthesia. Some researchers believe that sensory changes following implant placement and nerve transposition should be considered as a normal consequence of treatment and not a sequel or complication [10,43].

2.5.3. Pharmaceutical therapy and treatment of traumatic nerve injuries

Course of nerve recovery and symptoms vary based on the type and severity of the primary injury. In most cases, only time and regular patient visits are required. Other cases may need drug therapy or microscopic reconstructive neural surgery (**Algorithm 1**). In case of nerve transection, we can suture the free ends without traction but primary and simultaneous graft should never be performed. If the nerve is under traction, greater fibrosis will develop at the site of repair. In cases with nerve compression or traction, the surgeon should release the nerve and eliminate the traction or compression and prevent ischemia due to mechanical

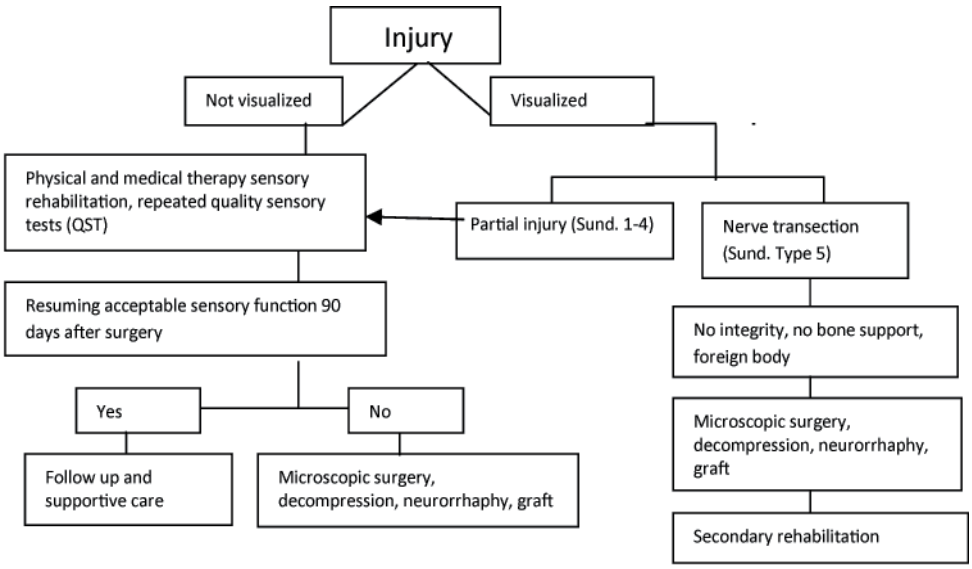

Algorithm 1. How to decide about the treatment and management of inferior alveolar nerve injury

trauma [12]. After nerve repair, clinical tests should be performed weekly during the first month and then monthly for 5 months. It is especially important to do the test in the first month to diagnose if neuroma or neuropathic pains develop [39]. In case of presence of neuropathic pains, primary management includes nerve block by local anesthetics, use of analgesics and nerve stimulation through the skin (30 min a day for 3 weeks). If post traumatic neural pains do not alleviate pain after 3-4 weeks, administration of various drugs have been recommended [12].

Some of the medications used for neuropathic pain control:

1. Fluphenazine 1 mg, 3 times a day along with Amitriptyline 75 mg before bedtime
2. Doxepin (tricylic antidepressant) 25 mg 3 times a day
3. Carbamazepine up to 100 mg/day
4. Baclofen up to 80 mg/day
5. For sympathetical pain we can do injections for stellate ganglion block. Alpha 2 adrenergic blockers (clonidine 0.1 to 0.3 mg/day based on tolerance) 5 times a week for 3 weeks; sympathectomy can also be used.
6. In case of acute pains fast-acting anticonvulsants (like clonazepam) 2 to 10 mg/day may be useful.
7. Titrated Gabapentin anticonvulsant 600 to 3000 mg is beneficial for chronic pains following traumatic injuries. If the patient also suffers from sleep disorders, antidepressants may be used at bedtime.

http://dx.doi.org/10.5772/52317

8. Anti-inflammatory drugs, analgesics, anti-anxiety medications and sleeping pills can also be used in addition to the above mentioned medications.

9. Topical lidocaine gel (for mucus membrane) and 5% lidocaine patches (for skin) which are released slowly within 12 hours are used for the mucous membrane and skin of the irritated areas or trigger zones.

10. Intravenous injection of lidocaine may be used sometimes for diagnostic purposes. In such cases, first normal saline is injected as a placebo and then the patient's symptoms are evaluated and then 1 mg/kg lidocaine is slowly injected intravenously within 2 minutes and the patient is asked about its effects every 30 seconds. Pain relief (more than 30%) indicates the effectiveness of intravenous lidocaine injection which shows the neuropathic origin of the pain and we should consider the probable efficacy of medications with central effects such as anticonvulsants [12, 22].

Nerve reconstruction

In case of requiring inferior alveolar nerve reconstructive surgery, it is important to maintain the integrity of the nerve. First, the nerve is exposed and the surrounding tissues are released so that the extensiveness of injury is evident. Compression injuries result in development of fibrosis. In such cases, first lactate ringer's solution is subcutaneously injected in the fibrotic area with a 30 gauge needle to separate the epineurium from the fascicles and determine the extension of fibrous tissue. Then the fibrous tissue is eliminated by a fine longitudinal incision over the epineurium. If the fibrous tissue is extensive and has penetrated into the fascicles we have to dissect this area and suture the free ends of the nerve together. Inferior alveolar nerve is usually composed of 12 to 30 small fascicles with scattered epineurium wrapped around them. Therefore, extensive fibrosis between the fascicles rarely occurs unless in case of major injury. If there is a neuroma, similar to extensive fibrosis the lesion has to be removed and the two free ends should be sutured together. No traction should be applied to the free ends when suturing in order to avoid future fibrous formation. Approximation of the two ends of the nerve regardless of the direction of fascicles and placing the fascicles alongside each other is called coaptation. Since inferior alveolar nerve is a sensory nerve, often only approximation is sufficient. Sutures are applied to the epineural layer. If neural graft is intended, the most similar nerve to the inferior alveolar nerve in terms of diameter and consistency is the sural nerve and the second most similar is the greater auricular nerve [12,22].

Surgical intervention for a patient suffering from nerve injury has 2 main objectives: resuming the sensory function and managing the pain and discomfort due to nerve injury.

Indications of explorative surgery and nerve reconstruction include:

1. Visible injury

2. Presence of foreign body around the nerve

3. No change in anesthesia or hypoesthesia 2 months after nerve injury

4. Uncontrollable neuropathic pain

Contraindications of explorative surgery and nerve reconstruction include:

1. Signs of improved sensory function based on quantitative sensory testing (QST) which is a method for determining the exact threshold of sensory stimulation with the use of oscillatory, touch, thermal or painful stimuli)
2. Patient admission based on remaining dysfunction or present discomfort
3. Signs of central sensitivity (regional dysesthesia, secondary hyperalgesia)
4. Presence of clinical symptoms with autonomic origin (erythema, swelling, hypersensitivity, burning sensation) which are indicative of autonomic nerve dysfunction rather than sensory nerve injury)
5. Old age, presence of an underlying systemic or neuropathic disease
6. A long time has passed since the injury
7. Patient has unrealistic expectations (demands immediate full recovery or resuming of sensory function with no pain)
8. Neural pains that are not alleviated by local anesthesia [22]

Primary care of a patient with nerve injury includes:

The main goal of primary treatment of nerve injury is to eliminate the progressive cause, and prevent secondary nerve injury to allow formation of a peripheral tissue for maximum recovery of the nerve and avoid secondary neuropathic hypersensitivity. If the injured nerve is exposed, pressure from the foreign body, bony and dental chips, toxic materials or implant if present should be eliminated. The exposed nerve should be washed with isotonic solution and sutured with temporary epineural sutures. Infection and inflammation should be controlled precisely both locally and systemically. Anti-inflammatory medications, opioid analgesics and sedatives should be extensively used in order to control anxiety and minimal stimulation of the CNS. An appropriate method for this purpose is administration of a long acting local block anesthesia. A course of systemic corticosteroids like dexamethasone 8 to 12 mg/day can decrease the perineural inflammation in the first week following surgery [44]. Fast acting anticonvulsants like clonazepam in divided doses of 2 to 10 mg/day can further protect the CNS [45]. Topical lidocaine in the form of gel or 5% patch which is released and absorbed subcutaneously within 12 hours can also be used [46]. Basic examinations should be performed using QST and the injured nerve should be under follow up. The patient should be informed about the nature of nerve injury, importance of tests and examinations, constant and immediate care, possibility of requiring secondary consultation and microscopic reconstructive surgery and possibility of prolonged recovery.

Nerve surgery is categorized into 3 types based on the time of surgery following nerve injury:

1. Primary and immediate surgery: within the first few hours following injury.
2. Delayed surgery: within 14 to 21 days after injury.
3. Secondary surgery: 3 weeks after injury.

http://dx.doi.org/10.5772/52317

Primary surgery is indicated when the nerve is exposed and becomes injured. It is usually performed in cases of trauma, orthognathic surgery, implant surgery, dentoalveolar pathologies and some cases of 3rd molar surgeries. From the biologic point of view, immediate primary surgery is preferred over other types. Despite limitations, primary repair is feasible even in the office. Use of surgical loop is recommended.

Delayed surgery following primary surgery, may also be require which is performed a few weeks following injury when the acute post-op condition of the area has subsided and the site is ready for the definite operation of nerve exposure and microscopic surgery.

Secondary surgery is done for invisible trigeminal nerve injury; this injury is not an uncommon event and requires secondary reconstructive surgery under controlled conditions following informing the patient about the indication of surgery, and explaining the situation according to clinical conditions and repeated QSTs. There is controversy regarding the optimal time for conduction of secondary surgery among researchers [47]. There are 3 reasons why the earlier reconstructive surgery within the first week following injury is preferred:

1. The high capacity for maximum recovery within the first week after surgery
2. Quick intervention can prevent traumatic neuroma from extension and subsequent chronic neuropathic hypersensitivity or fibrosis
3. Technical simplicity of the reconstruction (after a long delay, microscopic surgery would be very difficult due to the contraction and progressive atrophy of the nerve segments, increased collagen precipitation inside and outside the nerve and scarring of Schwann cells)

The first phase of nerve reconstruction includes:

1. Decompression of the injured nerve by extracting the foreign bodies and releasing the scar tissues and other tissues compressed around the nerve.
2. Detection of the injured area, incision and transection of the traumatic neuroma
3. Repair with microscopic sutures through neurorrhaphy (repeated direct anastomosis)
4. Reconstruction through an interstitial graft if neurorrhaphy is not feasible due to the extensive loss of nerve tissue.

Nerve graft: In some cases of severe injury, reconstruction through direct neurorrhaphy is not feasible. Clinical experience shows that distances wider than 15 to 20 mm cannot be repaired through neurorrhaphy and suturing without tension. In such cases, nerve grafting is indicated.

Autogenous graft: Our first choices for a nerve graft are the sural nerve, great auricular nerve, and anti-brachial skin nerve. All these donor nerves are easily accessible and provide sufficient length of the tissue (more than 6 cm)[48-50].In order to avoid tissue fragility, minimum number of sutures should be used. It would be ideal if the nerve is wrapped in a protective biodegradable barrier. The main complications in autogenous grafts are development of a sense of numbness and anesthesia/dysesthesia, and formation of a neuroma at the donor site. In cases where sural nerve is used, there is a risk of defect and difficulty along with hyperesthesia at the lateral

and posterior surface of the foot where is in contact with shoes and in the ankle. When the greater auricular nerve is used the patient may experience paresthesia at the lateral side of the neck and at the angle of mandible. This is especially troublesome in patients who have trigeminal neuropathy adjacent to this location. Another problem related to greater auricular nerve is the various diameters of this nerve [51].The greatest technical problem in autogenous nerve graft is the incompatibility in shape, size and number of fascicles between the grafted nerve and the inferior alveolar nerve. The inferior alveolar nerve has an average 2.4 mm diameter and is cylindrical. In comparison, the sural nerve has approximately 2.1 mm diameter versus 1.5 mm diameter of great auricular nerve. Both of these nerves have a significantly smaller number of fascicles than the inferior alveolar nerve [52]. It is not feasible to completely match the fascicles at the time of nerve grafting which amplifies the disorganized regeneration of the axon in between the grafted area [53].

Alternative strategies for autogenous grafts:

An alternative strategy for nerve graft is to use skeletal muscles [54]. To date, there is no definite report regarding the level of sensory recovery of the inferior alveolar nerve. Also, use of arteries and veins has been reported with varying levels of success clinically [55]. Use of vasculature for grafting has been considered because of the minimum tissue invasion and ease of access. However, this method has not shown acceptable results thus far. At present, some have suggested using alloplastic grafts which have caught great attention for their availability and avoiding the morbidity of the donor site. Their biocompatibility and efficacy are for the short grafts only. However, acceptable results have not been reported in this regard either.

Management of sensory function after nerve transposition surgery:

Inferior alveolar nerve transposition for implant placement almost in 100% of cases results in sensory impairment immediately after surgery [10,31,32]. Sensory disturbances are resolved in 84% of cases and in only 16% of patients may this complication be permanent and irreversible [10,24,32,33]. The important issue in management of nerve injury is to inform and educate the patient in this respect. The patient should be educated before and after the surgery and should be well aware that nerve reconstruction may take a long time and he/she may experience paresthesia or dysesthesia for a long period of time. The patient may be taught to massage the area (with lanolin or a moisture absorbing ointment). Massage should be started with mild movements and then the intensity is increased to improve the sense of touch. Massaging is indicated 4 to 6 times a day for 10 to 15 minutes. The first sense that resumes is the sense of cold followed by pain. At this time the patient still has paresthesia in the area. After 4 to 5 months, the patient would be able to differentiate between cold and heat sensations and feels the sharpness of needle with 25 to 30 g pressure. After 6 months, touch, pain and thermal sensations will resume more efficiently [12]. All patients should undergo treatment with low level laser for 10 sessions (4 times a week). The sessions start from the day of surgery. The sensitive area is detected using a simple anesthesia needle and is controlled monthly. The percentage of recovery is calculated by the proportion of the primary area suffering from paresthesia to the final area after 6 months. Researches indicate that chance of spontaneous recovery of the nerve is smaller in women compared to men

[10]. As mentioned earlier, most surgeons believe that sensory disturbances should be considered as a normal predictable state following nerve transposition surgery and not a complication or sequel of treatment [10,32].

Author details

Ali Hassani[1], Mohammad Hosein Kalantar Motamedi[2] and Sarang Saadat[3]

1 Oral and Maxillofacial Surgery, Azad University of Medical Sciences, Tehran, Iran

2 Oral and Maxillofacial Surgery, Trauma Research Center, Baqiyatallah University of Medical Sciences, Tehran, Iran

3 Craniomaxillofacial Research Center, Tehran University of Medical Sciences, Tehran, Iran

References

[1] J.M. Hirsch, P.I. Branemark. Fixture stability and nerve function after transposition and lateralization of the inferior alveolar nerve and fixture installation. Br J Oral Maxillofac Surg.1995;33(5):276-281.

[2] Thoma Kh, Holland DJ. Atrophy of the mandible.Oral Surg Oral Med Oral Pathol. 1951;4(12):1477-95.

[3] Rocchietta I, Fontana F, Simion M. Clinical outcomes of vertical bone augmentation to enable dental implant placement: a systematic review.Clin Periodontol. 2008;35:203-15.

[4] Boyne PJ, Cooksey DE. Use of cartilage and bone implants in restoration of edentulous ridges.J Am Dent Assoc. 1965;71(6):1426-35.

[5] Chang CS, Matukas VJ, Lemons JE.Histologic study of hydroxylapatite as an implant material for mandibular augmentation.J Oral Maxillofac Surg. 1983;41(11):729-37.

[6] Jensen OT. Combined hydroxylapatite augmentation and lip-switch vestibuloplasty in the mandible..Oral Surg Oral Med Oral Pathol. 1985;60(4):349-55.

[7] Egbert M, Stoelinga PJ, Blijdorp PA, de Koomen HA. The "three-piece" osteotomy and interpositional bone graft for augmentation of the atrophic mandible.J Oral Maxillofac Surg. 1986;44(9):680-7.

[8] Matras H. A review of surgical procedures designed to increase the functional height of the resorbed alveolar ridge.Int Dent J. 1983;33(4):332-8.

[9] Vasconcelos Jde A, Avila GB, Ribeiro JC, Dias SC, Pereira LJ. Inferior alveolar nerve transposition with involvement of the mental foramen for implant placement.Med Oral Patol Oral Cir Bucal.2008;13(11):E722-5.

[10] Jensen O, Nock D.Inferior alveolar nerve repositioning in conjunction with placement of osseointegrated implants: a case report.Oral Surg Oral Med Oral Pathol. 1987;63(3):263-8.

[11] Rosenquist B.Fixture placement posterior to the mental foramen with transpositioning of the inferior alveolar nerve.Int J Oral Maxillofac Implants. 1992;7(1):45-50.

[12] Yaghmaei M.Mandibular Canal (clinical Aspects).1st ed.Tehran: Karvar Publishers; 2010.

[13] Hu KS, Yun HS, Hur MS, Kwon HJ, Abe S, Kim HJ. Branching patterns and intraosseous course of the mental nerve. J Oral Maxillofac Surg. 2007;65(11):2288-94.

[14] Sanchis JM, Peñarrocha M, Soler F.Bifid mandibular canal. J Oral Maxillofac Surg. 2003;61(4):422-4.

[15] Stella JP, Tharanon W.A precise radiographic method to determine the location of the inferior alveolar canal in the posterior edentulous mandible: implications for dental implants. Part2: Technique.Int J Oral Maxillofac Implants. 1990;5(1):23-9.

[16] Stella JP, Tharanon W.A precise radiographic method to determine the location of the inferior alveolar canal in the posterior edentulous mandible: implications for dental implants. Part 1: Technique.Int J Oral Maxillofac Implants. 1990;5(1):15-22

[17] Kieser J. Kieser D. Hauman T.The Course and Distribution of the Inferior Alveolar Nerve in the Edentulous Mandible. J Cranio fac Surg..2005;16(1):6-9.

[18] Chrcanovic BR, Custodio AL. Inferior alveolar nerve lateral transposition. Oral Maxillofac Surg. 2009;13(4):213-9.

[19] Wadu SG, Penhall B, Townsend GC.Morphological variability of the human inferior alveolar nerve. Clin Anat. 1997;10(2):82-7.

[20] Choukas NC, Toto PD, Nolan RF.A histologic study of the regeneration of the inferior alveolar nerve.J Oral Surg. 1974;32(5):347-52.

[21] Yaghmaei M, Mashhadiabbas F, Shahabi S, Zafarbakhsh A, Yaghmaei S, Khojasteh A. Histologic evaluation of inferior alveolar lymphatics: an anatomic study. Oral Surg Oral Med Oral Pathol Oral Radiol Endod. 2011 Feb 16.

[22] Van Geffen GJ, Moayeri N, Bruhn J, Scheffer GJ, Chan VW, Groen GJ.Correlation between ultrasound imaging, cross-sectional anatomy, and histology of the brachial plexus: a review. Reg Anesth Pain Med. 2009;34(5):490-7.

[23] Hupp J.R. Ellis E.Tucker M.R.Contemporary Oral and Maxillofacial surgery.5th ed.Missouri:Mosby Elsevier;2008.p.281,285,620-622.

[24] Seddon HJ.A Classification of Nerve Injuries. Br Med J. 1942 Aug 29;2(4260):237-9.

[25] Sunderland S.A classification of peripheral nerve injuries producing loss of function. Brain.1951;74(4):491-516.

[26] Poort LJ, van Neck JW, van der Wal KG. Sensory testing of inferior alveolar nerve injuries: a review of methods used in prospective studies.J Oral Maxillofac Surg. 2009;67(2):292-300.

[27] Kahnberg KE, Ridell A. Transposition of the mental nerve in orthognathic surgery. J Oral Maxillofac Surg. 1987;45(4):315-8.

[28] Lindh C, Petersson A.Radiologic examination for location of the mandibular canal: a comparison between panoramic radiography and conventional tomography.Int J Oral Maxillofac Implants.1989;4(3):249-53.

[29] Babbush CA,Hahn JA,Krauser JT,Rosenlicht JL.Dental Implants:The Art and Science, 2th Ed. London:Saunders Elsevier ; 2010,232-250.

[30] Rosenquist Bo.Implant Placement in Combination With Nerve Transpositioning: Experiences With the First 100 Cases.Int J Oral Maxillofac Implants.1994: 9(5):522-531.

[31] Rosenquist BE.Nerve transpositioning to facilitate implant placement. Dent Econ. 1995;85(10):92-3.

[32] Kan JY, Lozada JL, Goodacre CJ, Davis WH, Hanisch O. Endosseous implant placement in conjunction with inferior alveolar nerve transposition: an evaluation of neurosensory disturbance.Int J Oral Maxillofac Implants. 1997;12(4):463-71.

[33] Peleg M, Mazor Z, Chaushu G, Garg AK. Lateralization of the inferior alveolar nerve with simultaneous implant placement: a modified technique.Int J Oral Maxillofac Implants2002;17(1):101-6.

[34] Friberg B, Ivanoff CJ, Lekholm U. Inferior alveolar nerve transposition in combination with Branemark implant treatment. Int J Periodontics Restorative Dent. 1992;12(6):440-9.

[35] Hashemi HM.Neurosensory function following mandibular nerve lateralization for placement of implants.Int J Oral Maxillofac Surg. 2010;39(5):452-6.

[36] Smiler DG. Repositioning the inferior alveolar nerve for placement of endosseous implants: technical note.Int J Oral Maxillofac Implants. 1993;8(2):145-50.

[37] Yoshimoto M, Konig B Jr, Allegrini S Jr, de Carvalho Lopes C, Carbonari MJ, Liberti EA, Adami N Jr. Bone healing after the inferior alveolar nerve lateralization: a histologic study in rabbits (Oryctolagus cuniculus).J Oral Maxillofac Surg. 2004;62:131-5.

[38] Kahnberg KE, Henry PJ, Tan AE, Johansson CB, Albrektsson T.Tissue regeneration adjacent to titanium implants placed with simultaneous transposition of the inferior dental nerve: a study in dogs. Int J Oral Maxillofac Implants. 2000;15(1):119-24.

[39] Brasileiro BF, Van Sickels JE.A modified sagittal split ramus osteotomy for hemimandibular hyperplasia and simultaneous inferior alveolar nerve repositioning. J Oral Maxillofac Surg. 2011 Dec;69(12):e533-41

[40] Kraut RA, Chahal O. Management of patients with trigeminal nerve injuries after mandibular implant placement. J Am Dent Assoc. 2002;133(10):1351-4.

[41] Kubilius R. Sabalys G. Juodzbalys G.Gedrimas V.Traumatic Damage to the Inferior Alveolar Nerve Sustained in Course of Dental Implantation.Possibility of Prevention.Stomatologija,Baltic Dent Maxillofac.2004; 6:106-10.

[42] Khullar SM, Brodin P, Barkvoll P, et al: Preliminary study of low-level laser for treatment of long-standing sensory aberrations in the inferior alveolar nerve. J Oral Maxillofac Surg 54:2, 1996

[43] Matsen FA,Winquist RA,Krugmire RB. Diagnosis and management of compartment syndromes. J bone joint surg Am.1980;62(2):286-291.

[44] Seo K et al..Efficacy of steroid treatment for sensory impairment after orthognathic surgery. Oral Maxillofac surg 2004; 62:1193.

[45] Bartusch SL. Et al..Clonazepam for the treatment of lancinating phantom pain. Clin J Pain 1996;12:59.

[46] Rowbotham MC et al.Lidocaine patch: double-blind controlled study of a new treatment method for postherpetic neuralgia.J Pain.1996;65: 39.

[47] Davis H, Ohrnell LO, Larson C, et al. Lateralizing of the inferior alveolar nerve to allow fixture placement. Proceedings of the UCLA Symposium on Implants in the Partially Edentulous Patient. Los Angeles, 1990:28–31.

[48] Susarla SM et al..Dose early repair of lingual nerve injuries improve functional sensory recovery?. J oral maxillofac surg;2007:65:1070.

[49] Brammer JP, Epker BN. Anatomic-histologic survey of the sural nerve: implications for inferior alveolar nerve grafting.J Oral Maxillofac Surg. 1988;46(2):111-7.

[50] Eppley BL, Snyders RV Jr. Microanatomic analysis of the trigeminal nerve and potential nerve graft donor sites.J Oral Maxillofac Surg. 1991;49(6):612-8.

[51] McCormick SU, Buchbinder D, McCormick SA, Stark M. Microanatomic analysis of the medial antebrachial nerve as a potential donor nerve in maxillofacial grafting.J Oral Maxillofac Surg. 1994;52(10):1022-5.

[52] Takasaki Y, Noma H, Kitami T, Shibahara T, Sasaki K. Reconstruction of the inferior alveolar nerve by autologous graft: a retrospective study of 20 cases examining donor nerve length.Bull Tokyo Dent Coll. 2003;44(2):29-35.

http://dx.doi.org/10.5772/52317

[53] Pogrel MA, Renaut A, Schmidt B, Ammar A. The relationship of the lingual nerve to the mandibular third molar region: an anatomic study.J Oral Maxillofac Surg. 1995;53(10):1178-81.

[54] Rath EM. Skeletal muscle autograft for repair of the human inferior alveolar nerve: a case report.J Oral Maxillofac Surg. 2002;60(3):330-4

[55] Pogrel MA, Maghen A. The use of autogenous vein grafts for inferior alveolar and lingual nerve reconstruction.J Oral Maxillofac Surg. 2001;59(9):985-8.

[56] Miloro M, Stoner JA. Subjective outcomes following sural nerve harvest. Oral Maxillofac Surg. 2005;63(8):1150-4.

Section 12

Orthognathic Surgery of Maxillofacial Deformities

Chapter 26

Basic and Advanced Operative Techniques in Orthognathic Surgery

F. Arcuri, M. Giarda, L. Stellin, A. Gatti, M. Nicolotti,
M. Brucoli, A. Benech and P. Boffano

Additional information is available at the end of the chapter

http://dx.doi.org/10.5772/51762

1. Introduction

Orthognathic surgical procedures have been developed to reposition the jaws and have been traditionally used in the dentate patient to correct a skeletal malocclusion; these procedures are usually carried out with orthodontic control of the dentition to produce the best results. The majority of the clinical cases of maxillary deformities can be solved by three basic osteotomies: the LeFort I type maxillary osteotomy (LFI), the bilateral sagittal split osteotomy of the mandible (BSSO) and the horizontal sliding osteotomy of the mandibular symphysis (genioplasty).The LeFort I osteotomy, as described by Obwegeser in 1965, manages the midface; it can be performed as a single-piece monobloc technique or it can be executed as a multisegment procedure or with a distraction approach such as SARPE (Surgically Assisted Rapid Palatal Expansion). The BSSO and the genioplasty, described by the same author in 1955 and in 1957, respectively, allows the surgeon to modify the mandible.[1-3]

Orthognathic surgery can require the execution of codified subapical osteotomies to manage peculiar dento-alveolar discrepancies such as: the segmental anterior maxillary osteotomy according to Wassmund, the segmental posterior maxillary osteotomy according to Schuchardt and the segmental anterior mandibular osteotomy according to Köle.[4-6]Moreover, there are osteotomy well described in the scientific literature but now rarely used in the common practice such as: the intraoral vertical subcondylar osteotomy (Hebert, 1970), the median mandibular osteotomy, the maxillary-zygomatic osteotomy and the quadrangular Le Fort I osteotomy.[7-9]Historically, orthognathic surgery is used to correct dento-facial malocclusion and it is a common practice in maxillo-facial surgery; however, based on an extensive review associated with our experience, we report peculiar clinical scenarios, different from simple malocclusion, where orthognathic surgery is a precious tool.

INTECH
open science | open minds

© 2013 Arcuri et al.; licensee InTech. This is a paper distributed under the terms of the Creative Commons Attribution License (http://creativecommons.org/licenses/by/3.0), which permits unrestricted use, distribution, and reproduction in any medium, provided the original work is properly cited.

2. Obstructive sleep apnea syndrome

Continuous positive airway pressure therapy (CPAP) is the first line treatment for patients affected by Obstructive Sleep Apnea Syndrome (OSAS). CPAP prevents upper airway collapse, relieves symptoms such daytime sleepiness and decreases the cardiovascular accidents events. However, this treatment has poor patient compliance. An alternative approach to CPAP is upper airway surgery. The goal of surgery is to increase the posterior airway space and decrease the resistance to airflow, removing the site or sites of upper airway collapse.

Different surgical approaches have been proposed in the literature: tracheostomy, uvulopalatopharyngoplasty, hyoid suspension, partial glossectomy, lingual suspension, tongue base resection, genioglossus advancement and maxillomandibular advancement (MMA). Scientific literature considers MMA as the most effective surgical treatment for the management of adult OSAS. Surgical success and long-term stability confirms the efficacy and safety of this procedure. Tracheostomy is the surgical treatment for OSA patients with a success of 100% because it bypasses the site of collapse; however, it is indicated as a treatment of last resort after the failure of other surgical procedures. The reported surgical success rate for soft tissue surgical procedures is approximately 40-60%. MMA enlarges the pharyngeal space by expanding the skeletal framework; MMA is currently the most effective surgical treatment for the management of OSAS in adults.

To assess the surgical success and the long term stability both objective and subjective parameters are generally considered before surgery (T0), at 6 months after surgery (T1) and at follow up (T2). Objective examinations are commonly evaluated by upper airway fibroscopy during the Mueller's manoeuvre, by lateral cephalometry and by polysomnography. Subjective examinations can be evaluated by Epwhorth Sleepiness Scale (ESS) questionnaire.

With upper airway endoscopic evaluation performed by flexible fiberoptic endoscope in supine position during the Mueller's manoeuvre, it can be assessed:

1. the localization of collapse (N: Nose, O: Oropharynx, H: Hypopharynx);
2. the pattern of collapse (c: Circular, t: Transversal, AP: Antero-Posterior);
3. the grade of collapse (grade 0, 1, 2, 3, 4) (NOH classification).[10-12]

With lateral cephalometry, performed on latero-lateral teleradiography by the same operator, it is possible to evaluate the sskeletal relationship by angular measurements (SNA, SNB) and the posterior air space (PAS) between the base of the tongue and the posterior wall of the pharynx. With polysomnography it can be possible to evaluate the average number of apneas and hypopneas per hour during sleep (AHI), the average number of oxyhemoglobin desaturation per hour during sleep (ODI) and the average time spent with oxyhemoglobin saturation below 90% during sleep (SaO_2< 90).

Results of OSA surgical treatment are divided into "surgical success" and "surgical cure". Surgical success is defined as an AHI < 20 events/hour. Surgical cure is defined as an AHI < 5 events/hour after surgical procedure. Holty and Guilleminault performed a meta-analysis

http://dx.doi.org/10.5772/51762

regarding the clinical efficacy of MMA in treating OSAS. Six hundred twenty- seven adults with OSAS underwent to MMA. The mean AHI decreased from 63.9 events/h to 9.5 events/h following surgery. The surgical success and cure rates were 86 ± 30.9% and 43.2 ± 11.7% respectively. Also they observed the maintenance of surgical success rate at 44 months after surgery.[13, 14]

The analysis of skeletal cephalometric values (SNA and SNB) at T1 and at T2 does not show generally significant differences, confirming the long-term stability of skeletal advancement. According to the literature, the postoperative PAS (T1) has commonly an increase. At T2 the PAS maintains stable values. The skeletal advancement is commonly 1 cm for each jaw. Lye et al. found a statistically significant correlation between the degree of maxillary advancement and reduction in AHI. However, others have reported no association between the degree of maxillary advancement and improvement in AHI after MMA. MMA is generally safe with a reported major surgical complication maxillary (ischemic necrosis, cardiac complication) rate of 1%, minor complication (mandibular relapse, facial paresthesia, temporomandibular joint disorder) rate of 3.1% and no reported deaths.

OSAS is a chronic disease, so the treatment goal is the control of the symptoms and the control of OSAS-related risks by reducing the severity of the disorder. Surgical success and long term stability of outcomes confirm the efficacy and safety of MMA for treatment of OSAS. However a continuous follow up of these patients is necessary to control their lifestyle and to detect any possible relapse.[15] (Fig. 1 a-d)

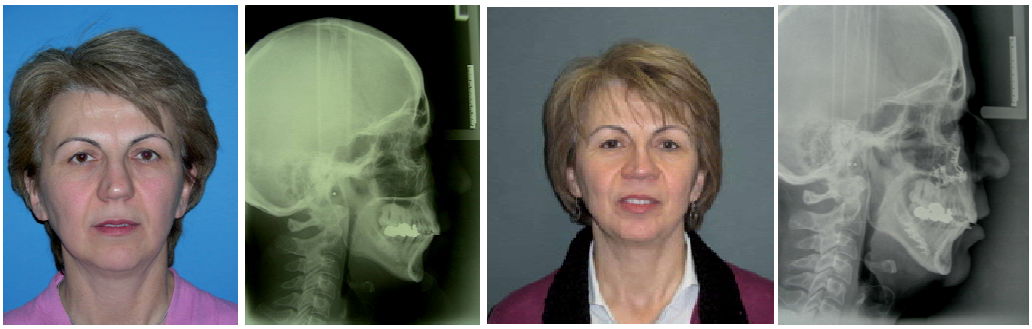

Figure 1. a) Preoperative frontal view. b) Preoperative radiographic examination. c) Photograph after bimaxillary surgery for advancement. d) Postoperative radiograph demonstrating successful advancement.

3. Preprosthetic technique in orthognathic surgery

Orthognathic surgery can be performed on the edentulous patient to correct discrepancies between the jaws, followed by the placement of implants to rehabilitate the maxillary bones; different surgical approaches and technical variations have been proposed.

This reconstructive method has the advantages over other commonly used preprosthetic techniques of simultaneously allowing the placement of osseointegrated implants, while correcting an unfavourable intermaxillary relationship and improving facial esthetics. [16-18]

Since the 1970s osseointegrated implants have played an important role in oral and maxillofacial reconstruction. Although the success of this method for edentulous jaws with sufficient bone height, patients with an atrophic maxilla and mandible continue to be difficult cases for an optimal outcome in terms of esthetics and function. This condition is characterized by the lack of bone for implants and a reverse maxillomandibular relationship; the progressive loss of alveolar bone height leads to less volume available for the implants with a high rate of surgical failure. Vertically directed resorption increases the interarch space; the projection of the maxilla diminishes in the sagittal plane with change of the intermaxillary relationships and a pseudoprognathism. The combination of loss of projection and diminished vertical bone height results in collapse of the soft tissues of the midface resulting in a more aged face.

Orthognathic surgical procedures have been initially described to reposition the jaws and have been traditionally used in the dentate patient to correct a skeletal malocclusion; these procedures are usually carried out with orthodontic control. Moreover, these procedures are used on the edentulous patient to correct the discrepancies between the maxilla and the mandible associated with the placement of implants to rehabilitate the oral cavity.[19-21] This reconstructive method has the advantages over other commonly used preprosthetic techniques of simultaneously allowing the placement of osseointegrated implants while correcting an unfavourable intermaxillary relationship and reversing facial aging. However, LeFort I osteotomy as a preprosthetic procedure for the atrophic edentulous maxilla is a technically demanding procedure and there are some complications such as infection, hemorrhage, aseptic and avascular necrosis, fractures of the maxilla, bone exposure and oroantral fistulas.

LeFort I osteotomy with interpositional and onlay bone grafts followed by implants' placement is one of the most common methods to manage a deficient vertical and horizontal maxillary dimension. However, this is a two-step procedure involving significant surgery with considerable morbidity at the donor site with a high rate of bone graft resorption. Recently surgeons use a computer-assisted software, which enables them to insert implants after a digital analysis of the residual alveolar and basal bone. This method offers surgeons the possibility of visualizing anatomic structures, evaluating implant position and inclination and to accurately insert implants. Implant-prosthetic rehabilitation can be difficult and affords both functional and psychological improvement. Computer assisted surgery can be the treatment of choice for these conditions; and the insertion of implants in the presence of marked bony defects can be simplified (Fig. 2 a-g).[22, 23]

http://dx.doi.org/10.5772/51762

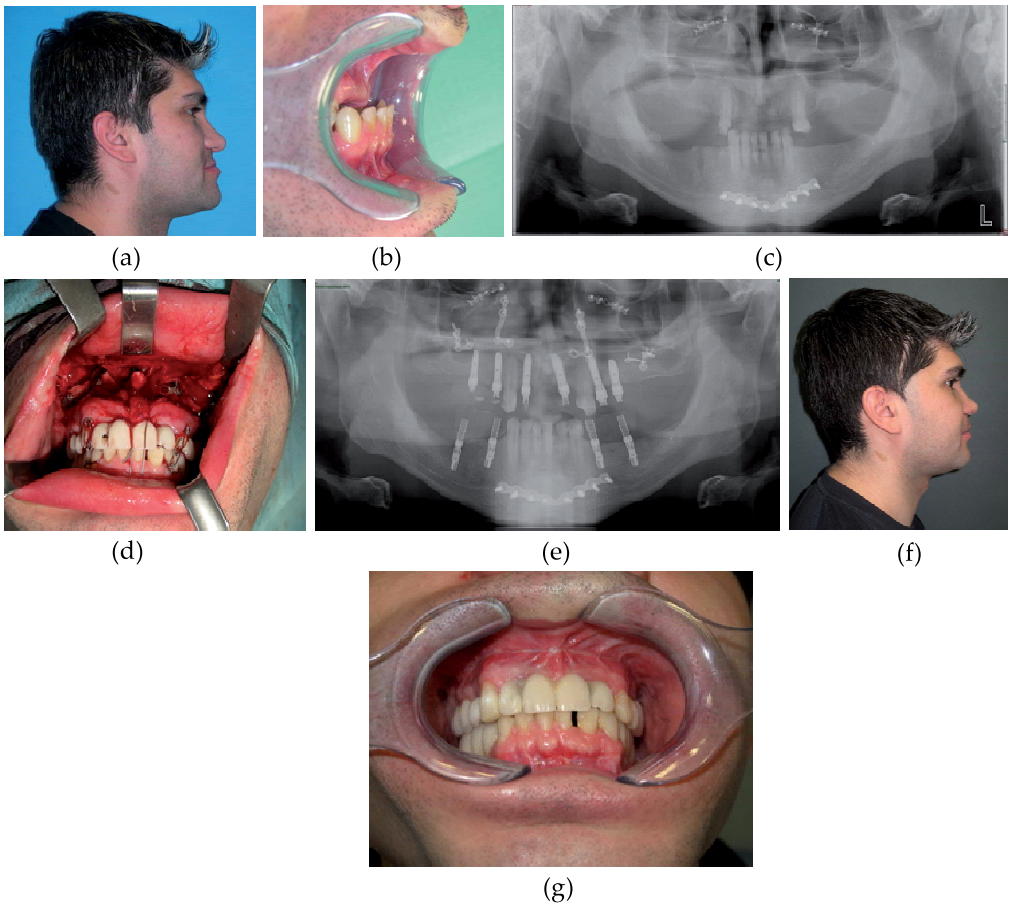

Figure 2. a) Clinical examination demonstrating a prognathic and reverse maxillary relationship. b) Clinical view revealing partial edentulism of the maxillary and mandibular arches with a severe atrophy of the upper jaw. c) Preoperative orthopantomograph showing the osteosynthesis plates after craniofacial trauma. d) Photograph demonstrating a sequence of the LeFort 1 osteotomy. e) Postoperative radiographic examination showing the adequate osteosynthesis after LeFort I osteotomy and dental implants. f) Postoperative lateral view demonstrating an adequate morphology. g) Occlusal view showing an optimal healing of the intraoral tissues.

4. Post-traumatic malocclusion

Facial fractures must be reduced as soon as possible to ensure a proper result; despite a careful surgical technique skeletal and soft-tissue deformities can persist. Orbito-zygomatic, nasal and occlusion problems can occur and result in an unsatisfactory outcome. Orthognathic surgery can be used to manage dentofacial post-traumatic deformities, coordinated with orthodontic and prosthodontic techniques. Management follows the basic rules for correcting primary malocclusion such as: preoperative detailed analysis with clinical records and cephalometric evaluation, well-established orthognathic surgical procedures and postoperative care.

Post-traumatic malocclusion can occur as a result in delayed treatment for unfavourable clinical conditions of the patient such as neurological, abdominal and thoracic injuries; otherwise it can be the squeal of a bad surgical outcome after a primary surgical treatment. Although post-traumatic deformities of the midface are managed with osteotomy in the lines of fracture such as in the malpositioned zygoma, orthognathic surgery, along with preoperative and postoperative orthodontic treatment, reposition the maxilla and the mandible in the preoperative three-dimensional position. Unsatisfactory outcomes of primary management of complex midfacial fractures can result in displacement of the jaws in the three planes of the space, resulting in altered dental and skeletal relationships.

According to the basic rules of orthognathic surgery, LeFort I single or multisegmental osteotomy and bilateral sagittal split osteotomy are indicated, eventually with bone grafts to support the movement of the jaws in the sagittal, vertical, and transverse planes. Treatment planning include endodontics assessment, orthodontic therapy, prosthodontic rehabilitation. Preoperative records such as dental casts, clinical photographs and radiographs, should be obtained to guarantee a satisfactory result. Mandibular or maxillary non-union is commonly managed with debridement of the original fracture with realignment of the occlusion, autologous bone grafting and osteosynthesis with miniplates and screws.

Post-traumatic maxillary deformities after LeFort fractures show midface retrusion, low facial height, anterior open bite, and mandibular overclosure for posterior displacement of the maxilla; moreover anterior cephalic telescoping of the mandible can be found from inferior pull of the pterygoid musculature on the pterygoid plates. LeFort I osteotomy to correct the malocclusion is often the easiest solution, regardless of the primary fracture. Moreover, if occlusal correction is planned, attention to the transverse dentoalveolar relationships should be addressed to determine if maxillary segmental osteotomies are required or preoperative orthodontic therapy is needed.[24]

Conversely, the most common fracture of the mandible which leads to post-traumatic malocclusion is related to the condyle. Discussion about the primary indication for surgery or closed treatment both in children and in adult patients is beyond the scope of this chapter. However, post-traumatic malocclusion with asymmetry caused by unilateral condylar process fractures can be managed with an osteotomy on the affected side or sometimes on both sides. A symmetric anterior open bite caused by bilateral condylar process fractures presents a surgical dilemma. It can be corrected with maxillary and/or mandibular osteotomies, according to dental, skeletal and esthetics issues. Finally, masticatory dysfunction is primarily related to the post-traumatic malocclusion. However, diminished mandibular movement can also lead to oral dysfunction. Trismus may be the result of temporomandibular joint (TMJ) dysfunction. TMJ dysfunction needs to be managed by a variety of techniques such as: occlusal splints, physiotherapy, and surgical procedures of the TMJ.[25] (Fig. 3 a-d)

http://dx.doi.org/10.5772/51762

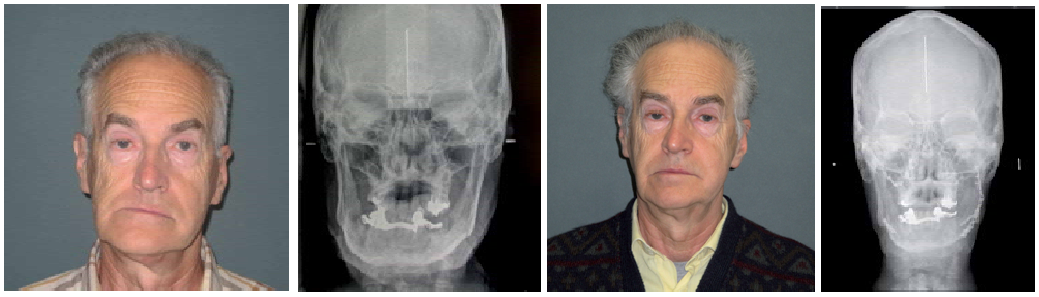

Figure 3. a) Clinical view of a post-traumatic mandibular laterodeviation. b) Radiographic evaluation. c) Postoperative condition showing facial balance. d) Postoperative control radiograph.

5. Maxillofacial approach

There are peculiar clinical circumstances where orthognathic surgery can solve the problem. Extraction of deeply located impacted inferior wisdom molars in close relationship with the inferior alveolar nerve (IAN)[26] or large cysts can be successfully removed by a bilateral sagittal split osteotomy (BSSO) of the mandible.[27]

Although enucleation and/or curettage together with bone removal is the treatment of choice for deeply located mandibular cysts, BSSO can be considered as a valid alternative to the conventional surgical approaches to achieve an adequate exposure of the region of the angle. In this region, the bone between the nerve and the external cortex is thick; therefore, bone removal by a buccal approach can be troublesome, increasing the risk of nerve injury.

The same discussion can be addressed for deeply located wisdom molars where the standard buccal approach poses an unacceptable risk to damage the IAN with excessive bone removal. However, although BSSO guarantees a wide exposure of the IAN, the dental roots and the cystic wall, it is still associated with complications such as: neurosensory disturbances, nonunion, malocclusion, unfavourable fractures, infections and hemorrhage.

Moreover, the mandibular osteotomy can be used as a decompressive technique in case of endodontic overfilling involving the mandibular canal with a potential risk of permanent IAN's injury.[28] Iatrogenic injury to the IAN after endodontic treatment of the posterior mandibular teeth is a well described complication which may lead to sensory disturbances such as pain, hypoesthesia, paresthesia, and dysesthesia of the chin and the lower lip. Two mechanisms are involved in the damage of the nerve: the chemical neurotoxicity of the components of the endodontic material and the mechanical pressure of the material injected into the mandibular canal.

Although decortication in association to apicectomy is considered the treatment of choice for removing endodontic paste, BSSO is also an adequate alternative. In the region of the man-

dibular angle, the bone is thick and the view is poor; then, decortication with apicectomy removes bone, while increasing the risk of nerve injury with a "blind" approach. However, as the degree of nerve injury increases with time, early surgical decompression of the IAN must be performed, regardless of the surgical approach.

LeFort I osteotomy and its variations are extensively used to approach nasal, paranasal and skull base regions. The removal of cranio-cervical lesions from the sphenoid to the fourth cervical vertebra between the carotids can be relatively easy with the transmaxillary approach.

Lesions that are intrasellar (pituitary tumors, craniopharyngiomas, Rathke's cysts) are frequently approached endoscopically. However, when an extensive exposure is needed, the transmaxillary approach gives a wider access to the clival lesions with superior and inferior extension for both benign neoplasms (angiofibroma, chordoma, fibrous dysplasia meningocele, aneurysm) and malignant tumours (malignant acinic cell, adenocarcinoma, adenoid cystic carcinoma, chondrosarcoma, olfactory neuroblastoma, sarcoma).Complications related to the transmaxillary approach include: injury of the infraorbital nerve, dental roots, tooth buds and lacrimal duct. Moreover avascular and aseptic necrosis of the soft-tissue, bone, and teeth, along with malocclusion, oronasal fistula and velopharyngeal dysfunction are well described.[29]

6. Clefts and craniofacial syndromes

Craniofacial morphology of patients affected by lip and palate cleft is characterized by a retrusion of the maxilla. The maxilla shows a various degree of skeletal, soft tissue, and dental deficiency. Maxilla shows clockwise rotation, with an increase of the anterior height of the mandible and a decrease in the posterior height of the maxilla. The severity of the malocclusion and the facial asymmetry indicates the surgical and orthodontic therapy. Surgical procedures performed during childhood are lip and palate clefts reconstruction, alveolar cleft repair and pharyngeal flap. Mild discrepancies of the jaws may be camouflaged by the orthodontic therapy during childhood; however, at the end of the skeletal growth, orthognathic surgery can be the treatment of choice for some cases.[30, 31]

Orthognathic surgery can be performed for the correction of malocclusion in patients with craniofacial syndromes (Crouzon, Apert, Treacher Collins, Hemifacial microsomia, Goldenhar syndrome). Treacher Collins syndrome is characterized by agenesis of the zygomatic bone and hypoplasia of the greater wings of the sphenoid. The zygomatic arch can be absent or hypoplastic; the maxilla and the mandible show a various degree of hypoplasia. Early correction of mandibular defects can be performed with distractors; however, bilateral sagittal split osteotomy (BSSO) and/or LeFort I osteotomy (LFI) at a later age may be needed. LFI addresses the vertical and anterior-posterior defects (open bite); BSSO associated with the horizontal sliding osteotomy of the mandibular symphysis corrects the mandibular defect.

Goldenhar syndrome is a bilateral disease, which is characterized by a degree of agenesis and hypoplasia of the mandibular ramus, mandibular condyle, tragus, helix, antihelix, and

http://dx.doi.org/10.5772/51762

temporomandibular joint (TMJ). The chin shows a degree of deviation and the margin of the mandible of the affected side is higher than the contralateral. The occlusion is Class II and the lower midline is displaced to the affected side. It should be treated by bilateral sagittal split osteotomy (BSSO) or mandibular osteodistraction based on the degree of severity and the experience of the surgeon. In case of severe deformity such as a serious joint involvement, BSSO may be indicated early around 9 years of age and it can be used with bone grafts for the restoration of the integrity of the ramus. However, the surgical correction of malocclusion occurs mostly in cases at the end of growth.

Figure 4. a) Preoperative frontal view showing the craniofacial malformation. b) Occlusal view demonstrating the open bite. c) Acrylic model with maxillary titanium plates adapted preoperatively to reproduce the LeFort I osteotomy. d) Intraoperative sequence showing the frontonasal surgical procedure. e) Intraoperative view of the LeFort I osteosynthesis. f) Postoperative photograph demonstrating an acceptable result. g) Postoperative radiographic control after surgery.

Apert and Crouzon syndrome are diseases characterized by synostosis of multiple sutures of the skull and the face; these diseases show a severe maxillary retrusion with a Class III malocclusion and open bite. The mandible has a normal shape. Common features are a narrow/high-arched palate, posterior bilateral crossbite, hypodontia, and crowding of teeth. The treatment begins early in the neonatal period if there are signs and symptoms of increased intracranial pressure. The first procedure is the advancement of the fronto-orbital complex to restore the cranial shape. The second step begins at around 6 years of age. The facial complex is osteotomized according to the Le Fort III line, eventually with a median osteotomy creating a facial bipartition. At the end of growth in many patients there is still a malocclusion. Surgical procedures depend on the defects; however, LFI is used to advance the maxilla, while correcting the open bite.[32] (Fig. 4 a-g)

7. Reverse facelift

The physiopathological basis of the aging face is not completely understood; however three factors contribute to the development of the aforementioned problem: soft tissue laxity, soft tissue atrophy and skeletal resorption. The aging face is characterized by multiple signs affecting the upper third (brow ptosis, excess of upper eyelid skin, forehead furrows, herniation of the orbital fat pad, glabellar frown lines); the middle third (accentuation of the parabuccal fat pad and development of the nasojugal fold) and the lower third (evidence of the labiomental fold, formation of the facial jowls and accentuation of the submental fat pad).[33-36]

Facelift procedures and fat grafting have been developed to restore a younger face and address the laxity and the atrophy of the soft tissue; the classic concept is that during life the force of gravity pulls the facial teguments down; facelift procedures pull the tissues up, both conventionally and more recently endoscopically. Moreover structural fat grafting accentuates the atrophic facial soft tissue and recreates the lost young tension.[37-39]

It is a common belief that the maxillofacial skeleton atrophies with the aging process, leading to a reduction of the facial height and depth; maxillary and mandibular bone resorption leads to a loss of support of the mouth and the nose. Maxillomandibular advancement (MMA) by orthognathic surgery restores the lost space dimension, providing projection to the cheeks, the jaws and the nose. In relation to the satisfactory esthetic results of orthognathic procedures performed on OSAS patients, the concept of "reverse face lift" started to arise. Maxillomandibular advancement is a very powerful tool to mask the physiological bone atrophy. It restores the space dimension by projecting the nose, the cheeks and the mouth.

The effect of bimaxillary manipulation on the facial soft tissue for dentofacial deformities has long been studied; conversely, the resultant facial changes of patients treated by MMA for OSAS has not been adequately described and the concept of "reverse face lift" has not been investigated in the scientific literature. Simultaneously MMA changes the skeletal framework of the face, improving soft tissue support and resulting in rejuvenation of the middle and the lower third of the face.

http://dx.doi.org/10.5772/51762

Figure 5. a) Lateral photograph of an aging face. b) Postoperative view after bimaxillary surgery of advancement showing the effects of reverse facelift.

Preoperative analysis of facial proportions with cephalometric measures, as performed with standard orthognathic cases, is of paramount importance before performing MMA for OSAS. Eventual unesthetic facial changes must be preoperatively discussed with the patient and the necessity of clockwise/counterclockwise rotation of the occlusal plane needs to be assessed in order to obtain a satisfactory result in terms of esthetics and functionality. Reverse facelift via bimaxillary advancements is a surgical procedure that may be combined with facelift procedures and structural fat grafting, can be indicated for a selected group of middle-aged patients, very motivated to an extreme rejuvenation. (Fig. 5a, b) [40-43]

8. Transgender surgery

Transsexualism is the extreme side of a wide spectrum of disorders called gender identity disorder (GID). It occurs when the anatomic gender of a person is opposite of his or her psychological gender. Epidemiological studies in the United States and Great Britain declare a prevalence of transsexualism of 1:50,000.

There are essential differences between male and female faces with regard to the skeleton and the soft tissues of the face. They have been extensively studied. The male forehead is flat and the supraorbital ridges are prominent. Females have a higher forehead with a more convex curvature. The orbits of the women are larger and higher. The zygomas of men are larger but less prominent. The mandible of men is larger, with a more prominent gonial angle and a rectangular chin.[44-46]

Gender reassignment requires both medical and surgical treatments. Hormonal therapy must be initiated early in the transgender process in order to change the physical features. The need for facial surgery to pass as a member of the other sex occurs in a significant percentage of transsexuals.

Facial feminization surgery (FFS) is referred as a group of surgical techniques devoted to change the features of a face from male to female. FFS was pioneered by Dr. Douglas Ousterhout from San Francisco, CA, USA in the 1980s. Facial feminization surgery (FFS) occurs more frequently than facial skeletal masculinisation and it is considered technically less demanding. Orthognathic surgery is a precious tool for a facial sexual reassignment surgical program.[47-50]Maxillary and mandibular osteotomies with clockwise rotation of the bimaxillary complex decreases the projection of both the chin and the mandibular angle region. Preoperative and postoperative orthodontic treatment is of paramount importance for the treatment plan. Le Fort I osteotomy (LFI) in association to a bilateral sagittal split osteotomy (BSSO) changes the geometry of the maxillo-mandibular complex.

The upper jaw can be placed forward in combination with a posterior vertical impaction. Although the mandibular angle does not change position with the BSSO and the dental occlusion remains unchanged, this clockwise rotation of the lower half of the face results in a more convex profile of the face with a less prominent chin which lead to a more feminine facial skeleton.

Orthognathic surgery is frequently associated with other procedures such as:

1. Mandibular angle reshaping to reduce the lower facial width;
2. Chin reduction to reshape the stigmata of the masculine chin;
3. Zygoma osteotomies with or without autogenous grafts/alloplastic implants to increase the mid-facial prominence;
4. Forehead recontouring to eliminate the frontal bossing;
5. Rhinoplasty to correct the stigmata of the male midface;
6. Browlift and scalp advancement to feminize the upper third of the face;
7. Lip lift, fat grafting and thyroid cartilage shave as ancillary procedures.[51] (Fig. 6 a-f)

9. Ethnic orthognathic surgery

There are certain differences in dental, skeletal, and soft-tissue facial morphology between Afro-American, Asian, Caucasian and Latin patients; orthognathic surgery must be adapted to each peculiar ethnic case. Meticulous planning ad careful execution of the osteotomies according to the preoperative surgical plan is essential to ensure an optimal outcome. Ethnic differences are related to the shape and the proportions of the skeletal framework, the soft tissue, and the texture of the skin. Individuals of all races, all over the world, desire to have an esthetically-ideal face. It is essential to understand the ethnic concepts of beauty for an optimal result.

Latin patients descend from the European immigrants and from the native population. For historical reasons, there is a Mongoloid component in their facial shape, making the same criteria of maxillofacial surgery applicable even for Asian populations. Because of similarities in anatomic characteristics such as skin thickness, wide bigonial angle and bimaxillary

http://dx.doi.org/10.5772/51762

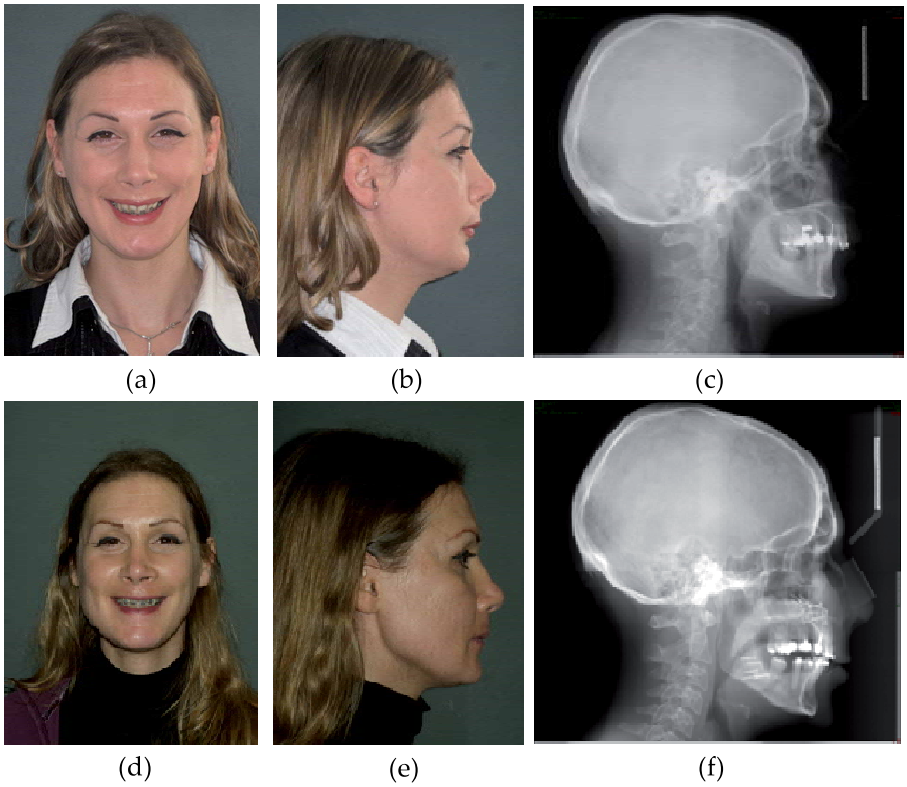

Figure 6. a) Preoperative frontal view. b) Preoperative lateral view. c) Preoperative radiographic examination. d) Postoperative smile after bimaxillary surgery. e) Lateral photograph demonstrating a feminine appearance. f) Teleradiography demonstrating orthognathic surgery.

protrusion, basic concepts can be applied even for some individuals of African origin. [52]A common characteristic is the protrusion of the dental arches, which lead to the projection of the lips with an acute nasolabial angle and the absence of the sublabial sulcus. The gingival display is excessive and the lip strain is exaggerated; the nasal spine appears receded and the paranasal areas appear depressed. The chin is located in a normal position; however it frequently appears receded because of the prominence of the dental arches; this feature augments the facial convexity. Standard surgical procedures include: Lefort I osteotomy to correct the midfacial deformities, bilateral sagittal split osteotomy to adapt the mandible, and subapical osteotomies to manage peculiar dento-alveolar discrepancies.

Surgical approach to alveolar protrusion requires careful planning and preoperative orthodontics. Model surgery needs to be performed in order to coordinate the dental arches after segmental surgery; finally intraoperative occlusal plates are fabricated. Two splints are necessary if bimaxillary protrusion is managed in a single stage as double-jaw surgery. Sophisticated studies about the vascularity of the maxilla and surgical refinements regarding the osteotomies lines have guaranteed predictable outcomes with minimal morbidity. Segmen-

tal osteotomies need to be performed without injuring adjacent teeth, while preserving the blood supply from the mucosa to the osseous segments.

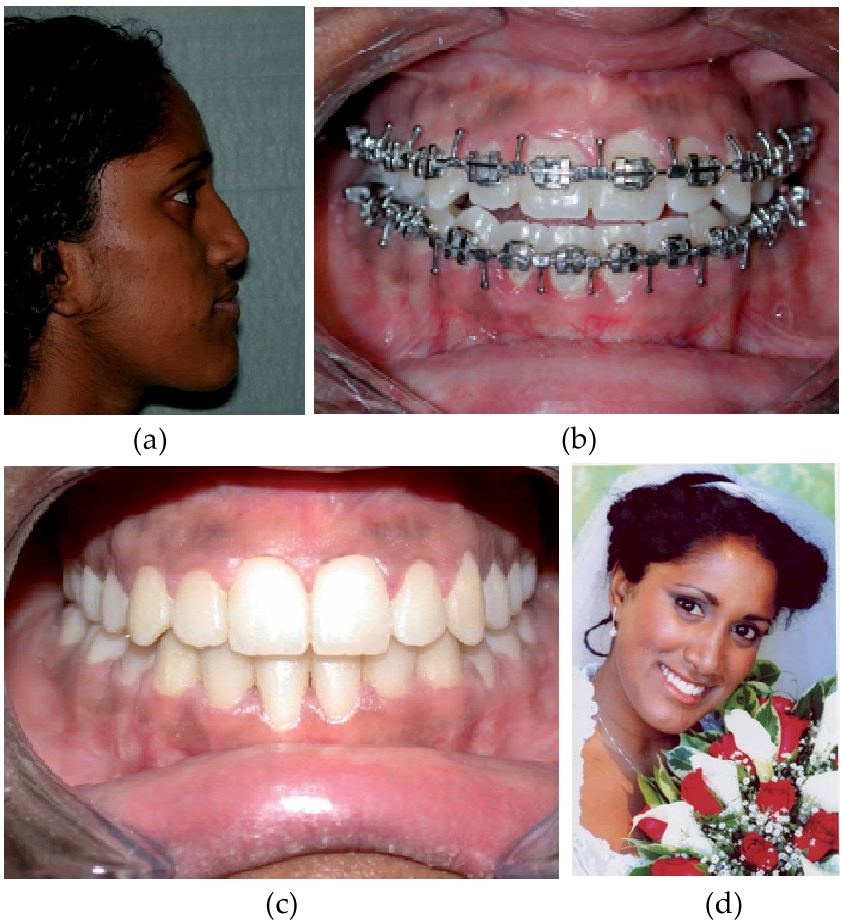

Figure 7. a) Preoperative frontal view. b) Preoperative malocclusion III class. c) Postoperative smile demonstrating a satisfactory result. d) Postoperative occlusal view.

The procedure can be managed by general or local anaesthesia. A vertical incision is performed on each side of the upper arch from the alveolus of the first premolar, which is extracted, toward to the vestibular sulcus. A segment of bone is removed from the palatine process and from the alveolar arch in order to displace the premaxilla backward. Osteosynthesis is performed with titanium plates and screws eventually associated to orthodontic bar.

Deformity of the mandibular dental arch is managed in a similar fashion. The incision is placed vertically in the mucosa from the first premolar toward the vestibular cul-de-sac. Then, subperiosteal dissection of the buccal and lingual cortex of the mandible is executed. One vertical osteotomy for each side of the arch is extended beyond the dental roots. Then, a

http://dx.doi.org/10.5772/51762

horizontal osteotomy is made joining the aforementioned osteotomies. The excess of bone is resected. The segment is mobilized and with the occlusal bite in place osteosynthesis is done with plates and screws.

Orthognathic procedures for correcting skeletal deformities can be used in association with maxillary and mandibular osteotomies. Frequently, skeletal surgery is combined with adjunctive procedures such as: forehead lift, facelift, rhinoplasty and fat grafting to augment facial beauty.[53,54] (Fig. 7a–d)

10. Reoperative orthognathic surgery

Although orthognathic surgery is considered a routine procedure in the common practice of oral and maxillofacial surgery, problems can arise at any point of the orthodontic-surgical process: the preoperative diagnosis and planning, the orthodontic therapy and the surgical phase. Complications can be divided into: airway, vascular, neurologic, infectious, dental, skeletal and cosmetic. Complications which require reoperation can occur; problems must be careful identified and solved to obtain an optimal result in terms of esthetics and functionality.

A full description based on an extensive literature review regarding the incidence of the complications among the different orthognathic procedures is beyond the scope of this chapter. However, intraoperative and/or postoperative hemorrhage, hypoesthesia /anaesthesia of the trigeminal branches, lesion of the cranial nerves and the skull base, maxillary avascular and aseptic necrosis and bone or soft tissue infection can occur at any time even for the most experienced surgeon.

Reoperative orthognathic surgery is required when the results obtained after the initial treatment are not satisfactory in terms of esthetics or functionality. Complications which require reoperation can occur during the surgery, in the initial postoperative phase, and after weeks/ months from the initial treatment.

The proper position of the condyle in the glenoid fossa is a manoeuvre which tremendously affects the final dental and skeletal occlusion. Condylar sag can be classified as central, peripheral type I and peripheral type II from maxillary or mandibular surgery. Central condylar sag can occur if the condyle is positioned inferiorly in the glenoid fossa without bone contact with the fossa. After removal of the intraoperative maxillo-mandibular fixation (IMMF), the condyle will move superiorly, causing an anterior open bite if the problem is bilateral. If only 1 side is affected, the lower dental midline will move toward the affected side and the occlusion of the affected side will be class II.

Peripheral condylar sag type II occurs when excessive pressure is placed on the proximal segment during osteosynthesis which leads to a superolateral movement of the condyle. If it occurs bilaterally, the final occlusion will be a posterior open bite; if it occurs only on 1 side, the occlusion will be a posterior bite only on the affected side and the lower dental midline will move toward to the opposite side of the affected side.[55]

Central condylar sag may also occur after Le Fort I osteotomy. Condyles may be inferiorly distracted from the glenoid fossa due to posterior bony interference of the maxilla. When IMMF is applied, the mandible will rotate counter clockwise with the posterior teeth as a fulcrum. When IMMF is removed, a class II anterior open bite can result. This event can occur both intraoperatively or in the immediate postoperative period.

Late postoperative complications which require orthognathic surgery can be due to unexpected postoperative growth, idiopathic condylar resorption or peripheral condylar sagging type I. Unexpected late facial growth may take place months or years after the surgical procedure. This is a very challenging issue for the surgeon to determine if the mandibular growth continues and if it should be treated orthodontically or surgically.

Idiopathic condylar resorption is related to the effects of chronic excessive loading of the mandibular condyle. It affects bilaterally and symmetrically the condyle of women between the age of 15 and 30 years. The resorption is progressive and painless, leading to a gradual loss of the ramus height, with a class II anterior open bite. A technetium 99m bone scan will determine if the bone activity is active. Occlusion should be stable for a minimum of 1 year. Patients can be treated by means of orthognathic surgery or with replacement of the mandibular condyle with a total-joint temporomandibular joint prosthesis in cases of severe functional and esthetic problems.

Peripheral condylar sag type I occurs when excessive pressure is placed on the mandibular condyle during osteosynthesis of the fragments which lead to an inferiorly sliding of the condyle with bone contact. This provides stability to the occlusion, and the problem can not be identified at the time of surgery. Resorption of the lateral pole of the condyle can make the problem become apparent even months after surgery. This resorption will cause the condyle to slide superiorly into the fossa; the mandible will relapse posteriorly on the affected side.

Finally, after 6-12 months after surgery, any unsatisfactory esthetic results are analyzed and corrective surgery can be eventually scheduled for soft tissue problems (nasal, midface, lip esthetics) and hard tissue concerns (facial asymmetry, anteroposterior and vertical discrepancies).[56]

Author details

F. Arcuri[1*], M. Giarda[1], L. Stellin[1], A. Gatti[1], M. Nicolotti[1], M. Brucoli[1], A. Benech[1] and P. Boffano[2]

*Address all correspondence to: fraarcuri@libero.it

1 Department of Maxillo-Facial Surgery, Novara Major Hospital: University of Eastern Piedmont “Amedeo Avogadro”, Novara, Italy

2 University of Turin, Italy

http://dx.doi.org/10.5772/51762

References

[1] Obwegeser, H. (1965). Surgery of the maxilla for the correction of prognathism. *Schweizerische Montatsschrift fur Zahnheilkunde*, 75, 365-74.

[2] Obwegeser, H. (1964). The indications for surgical correction of mandibular deformity by the sagittal splitting technique. *Br J Oral Surg*, 2, 157-71.

[3] Trauner, R., & Obwegeser, H. (1957). The surgical correction of mandibular prognathism and retrognathia with consideration of genioplasty: Part I. Surgical procedures to correct mandibular prognathism and reshaping of the chin. *Oral Surg*, 10, 667.

[4] Bell, W.H. (1977). Correction of maxillary excess by anterior maxillary osteotomy. A review of three basic procedures. *Oral Surg Oral Med Oral Pathol*, 43(3), 323-32.

[5] Lachard, J., Blanc, J. L., Lagier, J. P., Cheynet, F., Le Retraite, C., & Saban, Y. (1987). Köle's operation. *Rev Stomatol Chir Maxillofac*, 88(5), 306-10.

[6] Ermel, t., Hoffmann, J., Alfter, G., & Göz, G. (1999). Long-term stability of treatment results after upper jaw segmented osteotomy according to Schuchardt for correction of anterior open bite. *J Orofac Orthop*, 60(4), 236-45.

[7] Hebert, J. M., Kent, J. N., & Hinds, E. C. (1970). Correction of prognathism by intraoral vertical subcondylar osteotomy. *J Oral Surg*, 28, 651-665.

[8] Abubaker, A. O., & Sotereanos, G. C. (1991). Modified Le Fort I (Maxillary-Zygomatic) osteotomy: rationale, basis, and surgical technique. *J Oral Maxillofac Surg*, 49, 1089-1097.

[9] Keller, E.E, & Sather, A.H. (1990). Qadrangular Le Fort I osteotomy: surgical technique and review of 54 patients. *J Oral Maxillofac Surg*, 48, 2-11.

[10] Mc Ardle, N., Devereux, G., et al. (1999). Long term use of CPAP therapy for sleep apnea/hypopnea syndrome. *Am J Respir Crit Care Med*, 159, 1108-14.

[11] Lin, H. C., Friedman, M., Chang, H. W., & Gurpinar, B. (2008). The efficacy of multilevel surgery of upper airway in adults with obstructive sleep apnea/hypopnea syndrome. *Laryngoscope*, 118, 902-908.

[12] Fairburn, S. C., Waite, P. D., Vilos, G., et al. (2007). Three-dimensional changes in upper airways f patients with obstructive sleep apnea following maxillomandibular advancement. *J Oral Maxillofac Surg*, 65, 6-12.

[13] Lye, K. W., Waite, P. D., Meara, D., & Wang, D. (2008). Quality of life evaluation of maxillo-mandibular advancement surgery for treatment of obstructive sleep apnea. *J Oral Maxillofac Surg*, 66, 968-972.

[14] Holty, J. C., & Guilleminault, C. (2010). Maxillomandibular advancement for treatment of obstructive sleep apnea: a systematic review and meta analysis. *Sleep Med Rev*, 14, 287-297.

[15] Giarda, M., Brucoli, M., Arcuri, F., Braghiroli, A., Aluffi, P., & Benech, A. (2012). Proposal of a presurgical algorithm for patients affected by obstructive sleep apnea syndrome. *J Oral Maxillofac Surg*, Jan 27, Epub ahead of print.

[16] Branemark, P. I., Hansson, B. O., Adell, R., et al. (1977). Osseointegrated implants in the treatment of the edentulous jaw. Experience from a 10-year period. *Scand J Plast Reconstr Surg Suppl*, 16, 1-132.

[17] Albrektsson, T. (1988). A multicenter report on osseointegrated oral implants. *J Prosthet Dent*, 60, 75-84.

[18] Adell, R., Lekbolm, U., Rockier, B., et al. (1981 A). A 15-year study of osseointegrated implants in the treatment of the edentulous jaw. *Int J Oral Surg*, 10, 387-416.

[19] Sailer, H.F. (1989). A new method of inserting endosseous implants in totally atrophic maxillae. *J Craniomaxillofac Surg*, 30, 299-305.

[20] Cawood, J. I., & Stoelinga, P. J. (2000). International Research Group on Reconstructive Preprosthetic Surgery. Consensus report. *Int J Oral maxillofac Surg*, 29, 159-162.

[21] Malo, P., de Araujo, Nobre. M., & Lopes, A. (2007). The use of computer-guided flapless implant surgery and four implants placed in immediate function to support a fixed denture: preliminary results after a mean follow-up period of thirteen months. *J Prosthet Dent*, 97, S26-S34.

[22] Johansson, B., Friberg, B., & Nilson, H. (2009). Digitally planned, immediately loaded dental implants with prefabricated prostheses in the reconstruction of edentulous maxillae: a 1-year prospective, multicenter study. *Clin Implant Dent Relat Res*, 11, 194-200.

[23] Yerit, K. C., Martin, P., Guserl, U., Turhani, D., Schopper, C., Wanschitz, F., Wagner, A., Watzinger, F., & Ewers, R. (2004). Rehabilitation of the severely atrophied maxilla by horseshoe Le Fort I osteotomy (HLFO). *Oral Surg Oral Med Oral Pathol Oral Radiol Endod*, 97, 683-692.

[24] Yang, R. S., Salama, A. R., & Caccamese, J. F. (2011). Reoperative midface trauma. *Oral Maxillofac Surg Clin North Am*, 23(1), 31-45.

[25] Imola, MJ, Ducic, Y., & Adelson, R. T. (2008). The secondary correction of post-traumatic craniofacial deformities. *Otolaryngol Head Neck Surg*, 139(5), 654-60.

[26] Jones, T. A., Garg, T., & Monaghan, A. (2004). Removal of a deeply impacted mandibular third molar through a sagittal split ramus osteotomy approach. *Br J Oral Maxillofac Surg*, 42(4), 365-8.

[27] Scolozzi, P., Lombardi, T., & Jaques, B. (2007). Le Fort I Type Osteotomy and Mandibular Sagittal Osteotomy as a Surgical Approach for Removal of Jaw Cysts. *J Oral Maxillofac Surg*, 65, 1419-1426.

[28] Scolozzi, P., Lombardi, T., & Jaques, B. (2004). Successful inferior alveolar nerve decompression for dysesthesia following endodontic treatment: report of 4 cases treated by mandibular sagittal osteotomy. *Oral Surg Oral Med Oral Pathol Oral Radiol Endod*, 97(5), 625-31.

[29] Girish, Rao. S., Sudhakara, Reddy. K., & Sampath, S. (2012). Lefort I access for juvenile nasopharyngeal angiofibroma (JNA): a prospective series of 22 cases. *J Craniomaxillofac Surg*, 40(2), e 54-8.

[30] Heliövaara, A., Ranta, R., Hukki, J., & Rintala, A. (2002). Skeletal stability of Le Fort I osteotomy in patients with isolated cleft palate and bilateral cleft lip and palate. *Int J Oral Maxillofac Surg*, 31(4), 358-63.

[31] Wolford, L. M., Cassano, D. S., Cottrell, D. A., El Deeb, M., Karras, S. C., & Goncalves, J. R. (2008). Orthognathic surgery in the young cleft patient: preliminary study on subsequent facial growth. *J Oral Maxillofac Surg*, 66(12), 2524-36.

[32] Kahnberg, K. E., & Hagberg, C. (2010). Orthognathic surgery in patients with craniofacial syndrome. I. A 5-year overview of combined orthodontic and surgical correction. *J Plast Surg Hand Surg*, 44(6), 282-8.

[33] Arcuri, F, Brucoli, M, Benech, R, Giarda, M, & Benech, A. (2011). Maxillomandibular advancement in obstructive sleep apnea syndrome patients: a surgical model to investigate reverse face lift. *J Craniofac Surg*, 22(6), 2148-52.

[34] Sherris, D. A., & Larrabee, W. F. Jr. (1996). Anatomic considerations in rhytidectomy. *Facial Plast Surg*, 12(3), 215-22.

[35] Ramirez, O.M. (2000). The central oval of the face: tridimensional endoscopic rejuvenation. *Facial Plast Surg*, 16(3), 283-98.

[36] Coleman, S. R. (1998). Structural fat grafting. *Aesthet Surg J*, 18(5), 386-388.

[37] Arnett, G. W., & Gunson, M. J. (2010). Esthetic treatment planning for orthognathic surgery. *J Clin Orthod*, 44(3), 196-200.

[38] Hwang, S. J., Haers, P. E., Seifert, B., & Sailer, H. F. (2004). Non-surgical risk factors for condylar resorption after orthognathic surgery. *J Craniomaxillofac Surg*, 32(2), 103-11.

[39] Pessa, J. E., Zadoo, V. P., Mutimer, K. L., Haffner, C., Yuan, C., De Witt, A. I., & Garza, J. R. (1998). Relative maxillary retrusion as a natural consequence of aging: combining skeletal and soft-tissue changes into an integrated model of midfacial aging. *Plast Reconstr Surg*, 102(1), 205-12.

[40] Riley, R. W., Powell, N. B., & Guilleminault, C. (1993). Obstructive sleep apnea syndrome: A review of 306 consecutively treated surgical patients. *Otolaryngol Head Neck Surg*, 108, 117-25.

[41] Abramson, Z., Susarla, S., August, M., Troulis, M., & Kaban, L. (2010). Three-dimensional computed tomographic analysis of airway anatomy in patients with obstructive sleep apnea. *J Oral Maxillofac Surg*, 68(2), 354-62.

[42] Joss, C. U., Joss-Vassalli, I. M., Bergé, S. J., & Kuijpers-Jagtman, A. M. (2010). Soft tissue profile changes after bilateral sagittal split osteotomy for mandibular setback: a systematic review. *J Oral Maxillofac Surg*, 68(11), 2792-801.

[43] Jensen, A. C., Sinclair, P. M., & Wolford, L. M. (1992). Soft tissue changes associated with double jaw surgery. *Am J Orthod*, 101, 266.

[44] Shams, M. G., & Motamedi, M. H. (2009). Case report: feminizing the male face. *Eplasty*, 9, e2, Epub Jan 9.

[45] Cohen-Kettenis, P. T., & Gooren, L. J. (1999). Transsexualism: a review of etiology, diagnosis and treatment. *J Psychosom Res*, 46, 315-33.

[46] Hoenig, J., & Kenna, J. C. (1974). The prevalence of transsexualism in England and Wales. *Br J Psychiatry*, 124, 181-90.

[47] Monstrey, S., Hoebeke, P., Dhont, M., et al. (2001). Surgical therapy in transsexual patients: a multidisciplinary approach. *Acta Chir Belg*, 101, 200-9.

[48] Ousterhout, D.K. (1987). Feminization of the forehead: contour changing to improve female anesthetics. *Plast Reconstr Surg*, 79, 701.

[49] Mommaerts, M. Y., Abeloos, J. V. S., Calix, A. S., et al. (1995). The ''sandwich'' zygomatic osteotomy: technique, indications and clinical results. *J Craniomaxiliofac Surg*, 23, 12-9 .

[50] Ousterhout, D.K. (2011). Dr. Paul Tessier and facial skeletal masculinization. *Ann Plast Surg*, 67(6), 10-5.

[51] Becking, A. G., Tuinzing, D. B., Hage, J. J., & Gooren, L. J. (1996). Facial corrections in male to female transsexuals: a preliminary report on 16 patients. *J Oral Maxillofac Surg*, 54(4), 413-418.

[52] Beugre, J. B., Sonan, N. K., Beugre-Kouassi, A. M., & Djaha, F. (2007). Comparative cephalometric study of three different ethnic groups of black Africa with normal occlusion. *Odontostomatol Trop*, 30(117), 34-44.

[53] Chew, M.T. (2006). Spectrum and management of dentofacial deformities in a multiethnic Asian population. *Angle Orthod*, 76(5), 806-9.

http://dx.doi.org/10.5772/51762

[54] Clemente-Panichella, D., Suzuki, S., & Cisneros, G. J. (2000). Soft to hard tissue movement ratios: orthognathic surgery in a Hispanic population. *Int J Adult Orthodon Orthognath Surg*, 15(4), 255-64.

[55] Reyneke, J.P. (2011). Reoperative orthognathic surgery. *Oral Maxillofac Surg Clin North Am*, 23(1), 73-92.

[56] Chow, L. K., Singh, B., Chiu, W. K., & Samman, N. (2007). Prevalence of postoperative complications after orthognathic surgery: a 15 -year review. *J Oral Maxillofac Surg*, 65(5), 984-92.

Chapter 27

Rigid Fixation of Intraoral Vertico-Sagittal Ramus Osteotomy for Mandibular Prognathism

Kazuma Fujimura and Kazuhisa Bessho

Additional information is available at the end of the chapter

http://dx.doi.org/10.5772/53303

1. Introduction

The standard surgical treatment for mandibular prognathism is sagittal split ramus osteotomy (SSRO) if the proximal and distal segments of the ramus require fixing with screws or metal plates. In this procedure, however, it is frequently difficult to avoid neurosensory disturbance (NSD) of the inferior alveolar nerve (IAN) when the posterior margin of the ramus curves inward or when the ramus is thin (Fig 1A,B).

This report describes a new alternative procedure, intraoral vertico-sagittal ramus osteotomy (IVSRO) reported by Choung in 1992. [1] It is a modification of SSRO and intraoral vertical ramus osteotomy (IVRO). It is supposed that IVSRO is more suitable for, mandibles with a 'V' shape seen in adult Asians as compared to mandibles of Caucasians who have 'U' shaped mandibles. One of the main advantages of IVSRO is that it avoids IAN damage, because the ramus can be split parallel to the original sagittal plane posterior to the point between the mandibular canal and the lateral cortical bone plate immediately in front of the antilingular prominence. In this method the anterior border of the proximal segment is partially removed at the beginning of the osteotomy procedure as described by Kitajima et al. in 1989. [2] Another advantage of IVSRO is that the area in which screws can be inserted is relatively large; the subcoronoid area on the distal segment and subcondylar area on the proximal segment are engaged. These segments can be fixed in these areas with bicortical bone screws, without a cheek incision (Fig 1AC). This chapter introduces this procedure and the technique of rigid fixation of IVSRO for treatment of mandibular prognathism.

INTECH
open science | open minds

© 2013 Fujimura and Bessho; licensee InTech. This is a paper distributed under the terms of the Creative Commons Attribution License (http://creativecommons.org/licenses/by/3.0), which permits unrestricted use, distribution, and reproduction in any medium, provided the original work is properly cited.

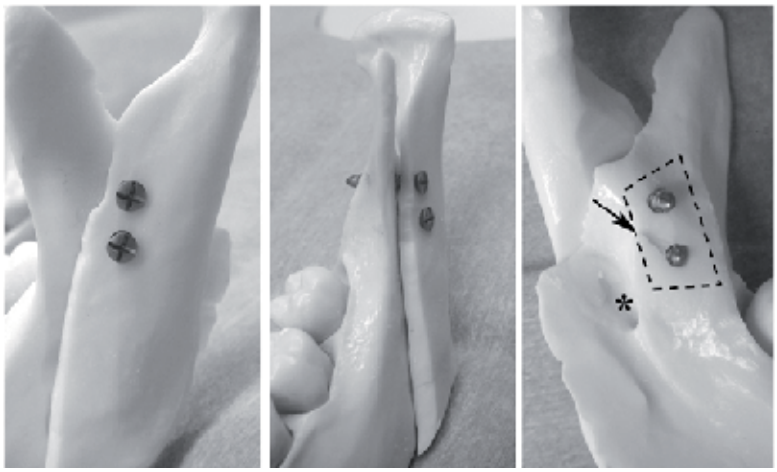

Figure 1. (a) Rigid fixation of intraoral vertico-sagittal ramus osteotomy using a mandibular model. Left mandibular ramus lateral view showing bone overlap and bicortical screw engagement. Screws can be inserted into the subcoronoid area on the distal segment in the subcondylar area on the proximal segment; (b) Left mandibular ramus frontal view showing bicortical engagement of screws; (c) Left mandibular ramus medial view showing relatively large area for screw insertion (*dashed rectangular area*). *Arrow* indicates lingula of mandible. *Asterisk* indicates mandibular foramen.

2. Technique

Osteotomy of the ramus via IVSRO is a modified version of the 'straight IVSRO'. [1] Briefly, the lateral aspect of the ramus is exposed from the sigmoid notch to the antegonial notch. To avoid damaging the IAN and the maxillary artery, the medial aspect of the ramus may also be exposed carefully from the sigmoid notch area to the lingula and the posterior border of the ramus, as in SSRO. [3] To avoid a fracture or bad split, the full thickness of the sigmoid notch is cut with a fissure bur, reciprocating saw, oscillating saw or ultrasonic surgical device inferiorly along the planned decortication line until the bone marrow is exposed. This process, full-thickness cutting of the sigmoid notch, is the most important and most technically difficult step of the IVSRO procedure. A wedge-shaped decortication of the lateral aspect of the ramus from the sigmoid notch to the antegonial notch is performed using a flat-top, cylindrical fissure bur parallel to the original sagittal plane until the bone marrow is exposed. [4] A bone spatula and an osteotome are used for vertical osteotomy along almost the entire sagittal plane to the medial posterior border of the ramus. The distal segment is then repositioned posteriorly, and intermaxillary fixation (IMF) is performed. The inner aspect of the decorticated distal segment is spontaneously overlapped on the proximal segment. The subcoronoid area and the subcondylar area in each segment also overlap. These segments can be fixed using bicortical bone screws. A 90° screw driver system (eg, angled drilling system and insertion screws with a 12mm screw length) is used with an intraorally (Fig 1 A–C).

http://dx.doi.org/10.5772/53303

When the two segments are fixed rigidly, IMF is usually not required after surgery. However, a favorable outcome is usually obtained with IMF for about 3 days to prevent postoperative bleeding and to aid in wound healing. To stabilize the occlusion postoperatively, intermaxillary elastics are applied for about 2-3 months after release of IMF.

3. Discussion

The main advantage of rigid fixation IVSRO over SSRO in treating prognathism, when the posterior margin of the ramus curves inward or the ramus is thin, may be the decreased risk of postoperative NSD. The incidence of long-term NSD of the lower lip and chin in IVSRO is 0% to 6% [1,5,6] compared with 39% to 85% [7-11] for SSRO. Although the osteotomy plane is between the mandibular canal and the lateral cortical plate of the ramus as in SSRO, damage to the IAN can be avoided because the osteotomy is performed from a point in front of the foramen between the mandibular canal and the immediately medial lateral cortical bone.[1, 2] making it possible to strip the lateral cortical bone from the bone marrow. Although a low incidence of NSD is also observed with IVRO, [10,12] rigid fixation with screws or bone plates has several disadvantages, including technical difficulty [10,13] and rotation of the condyle to the laterally.[1] IVSRO is distinguished by flat and larger contact areas of segments and more favorable healing of the medulla to the cortex than the cortex-to-cortex healing of IVRO. [1] In SSRO, the excess overlap of the anterior edge of the proximal segment must be removed to fit the two segments and/or prevent distal rotation of the proximal segment. [14] In IVSRO, there is no excess overlap of the proximal segment. It is easy to check the position of the distal segment after osteotomy because the anterior area of the proximal segment is removed beforehand; hence, the subcoronoid area of the distal segment and the subcondylar area of the proximal segment can be used for insertion of screws. The area available for screw insertion is relatively large and the ends of the inserted screws may be viewed at the medial aspect of the distal segment because, at the internal oblique ridge, the bone thickness of this subcoronoid area in the distal segment is relatively thin compared with the retromolar areas as in SSRO. Therefore, in many patients, a 90° angle screwdriver system with 12-mm length screws can be used without drilling through a trocar inserted through the skin (Fig 2 A–C).

4. Conclusion

When planning rigid fixation using IVSRO, the following conditions are preferable: Mandibular setback (about ≧5 mm) and counterclockwise rotation. Because this osteotomy procedure has a large contact area between the proximal and distal segments, compared with IVRO, the segments are usually fixed with screws in only the setback side for horizontal rotation for mandibular asymmetry (Fig 2C). Additional studies including the development of osteotomy instruments and drilling systems to simplify the surgical procedure of IVSRO are needed to validate the advantages of this procedure.

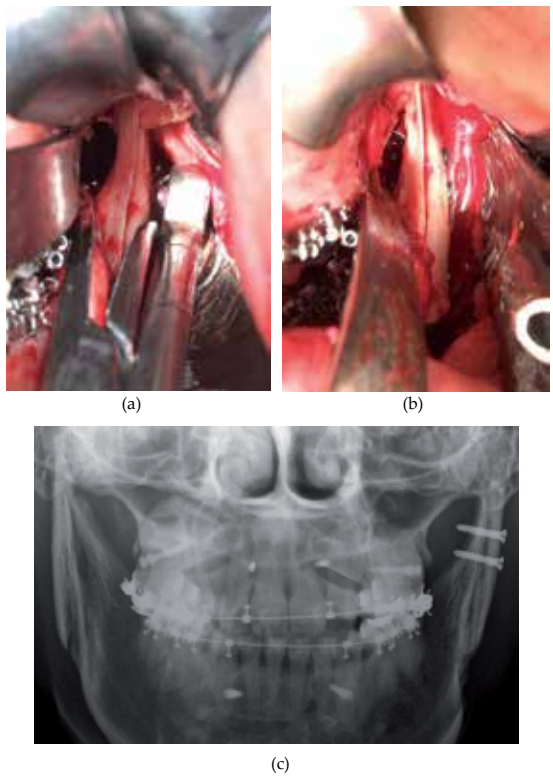

Figure 2. (a) Intraoral vertico-sagittal ramus osteotomy of the left ramus (frontal view). A 90° angled screwdriver drilling system and insertion screws, 12-mm in length; (b) Two 12-mm screws 2.4 mm in diameter inserted intraorally.

Author details

Kazuma Fujimura and Kazuhisa Bessho

*Address all correspondence to: fujimura@kuhp.kyotou.ac.jp

Department of Oral and Maxillofacial Surgery, Graduate School of Medicine, Kyoto University, Kyoto, Japan

References

[1] Choung PH: A new osteotomy for the correction of mandibular prognathism: Techniques and rationale of the intraoral verticosagittal ramus osteotomy.J Craniomaxillofac Surg 20:153, 1992

http://dx.doi.org/10.5772/53303

[2] Kitajima T, Handa Y, Naitoh K: A modification of the sagittal splitting technique ensuring that the osteotomy split lies immediately medial to the lateral cortex. J Craniomaxillofac Surg 17:53, 1989

[3] Fujimura K, Segami N, Kobayashi S: Anatomical study of the complications of intraoral vertico-sagittal ramus osteotomy. J Oral Maxillofac Surg 64:384, 2006

[4] Fujimura K, Segami N, Sato J, et al: Advantages of intraoral verticosagittal ramus osteotomy in skeletofacial deformity patients with temporomandibular joint disorders. J Oral Maxillofac Surg 62:1246, 2004

[5] Lima Júnior SM, Granato R, Marin C, et al: Analysis of 40 cases of intraoral verticosagittal ramus osteotomies to treat dentofacial deformities. J Oral Maxillofac Surg 67:1840, 2009

[6] Hashemi HM: Evaluation of intraoral verticosagittal ramus osteotomy for correction of mandibular prognathism: A 10-year study. J Oral Maxillofac Surg 66:509, 2008

[7] Walter JM Jr, Gregg JM: Analysis of postsurgical neurologic alteration in the trigeminal nerve. J Oral Surg 37:410, 1979

[8] MacIntosh RB: Experience with the sagittal osteotomy of the mandibular ramus: A 13-year review. J Maxillofac Surg 9:151, 1981

[9] Nishioka GJ, Zysset MK, Van Sickels JE: Neurosensory disturbance with rigid fixation of the bilateral sagittal split osteotomy. J Oral Maxillofac Surg 45:20, 1987

[10] Hall HD: Mandibular prognathism, in Bell WH (ed): Modern Practice in Orthognathic and Reconstructive Surgery. Philadelphia, PA, WB Saunders, 1992, p 2111

[11] Westermark A, Bystedt H, von Konow L: Inferior alveolar nerve function after mandibular osteotomies. Br J Oral Maxillofac Surg 36:425, 1998

[12] van Merkesteyn JP, Groot RH, Van Leeuwaarden R, et al: Intra-operative complications in sagittal and vertical ramus osteotomies. Int J Oral Maxillofac Surg 16:665, 1987

[13] Ghali GE, Sikes JW Jr: Intraoral vertical ramus osteotomy as the preferred treatment for mandibular prognathism. J Oral Maxillofac Surg 58:313, 2000

[14] Sickels JEV, Jeter TS, Aragon SB: Orthognathic surgery, in Bell WH (ed): Modern Practice in Orthognathic and Reconstructive Surgery. Philadelphia, PA, WB Saunders, 1992, p 1980

Chapter 28

Soft-tissue Response in Orthognathic Surgery Patients Treated by Bimaxillary Osteotomy – Cephalometry Compared with 2-D Photogrammetry

Jan Rustemeyer

Additional information is available at the end of the chapter

http://dx.doi.org/10.5772/51416

1. Introduction

During recent decades, orthognathic surgery has become widely accepted as the preferred method of correcting moderate-to-severe skeletal deformities including facial esthetics. Recognition of esthetic factors and prediction of the final facial profile play an increasingly important role in orthognathic treatment planning, since the facial profile produced by orthognathic surgery is highly significant for patients [1-3]. Many studies have attempted to evaluate the relationship between hard-tissue surgery and its effect on the overlying soft tissue for predicting facial changes [4-6]. Three-dimensional (3-D) imaging techniques, including computer tomography, video imaging, laser scanning, morphanalysis, 3-D sonography, and, recently, 3-D photogrammetry [7-13] have been developed to highlight the relationship between hard- and soft-tissue movements, but details of this relationship, particularly in the vertical direction, have varied and not been fully clarified [14]. However, the assessment of visible volume changes with an optical 3-D sensor can be carried out with considerable accuracy and provides the opportunity to complete cephalometric analysis in cases of midfacial distractions and asymmetric craniofacial situations [15].

For routine orthognathic surgery cases, cephalometry and 2-D photogrammetry are common and less expensive tools that may have the potential to analyze and predict the resulting profile. However, it is remarkable that no recent report offers a comparison between both conventional methods of indirect anthropometry. Therefore, the objective of this study was to assess the facial soft-tissue response in skeletal Class II and III patients treated by bimaxillary orthognathic surgery both cephalometrically and with 2-D photogrammetry and

INTECH
open science | open minds

© 2013 Rustemeyer; licensee InTech. This is a paper distributed under the terms of the Creative Commons Attribution License (http://creativecommons.org/licenses/by/3.0), which permits unrestricted use, distribution, and reproduction in any medium, provided the original work is properly cited.

to compare their ability to predict postoperative outcomes. Hence, the relevant questions were whether both methods have the capacity to complement one another or not and in which cases.

2. Patients and methods

Patients` sample

Twenty-eight patients who had undergone bimaxillary surgery for a Class II relationship (mean age, 24.5 ± 4.9 years; 18 females, 10 males) and 33 patients who had undergone bimaxillary surgery for a Class III relationship (mean age, 23.4 ± 3.7 years; 20 females, 13 males) were selected from adult treatment records. Bimaxillary surgery consisted of LeFort I osteotomy with maxillary advancement and/or impaction and bilateral sagittal split ramus osteotomy carried out for mandibular setback or advancement. Setback of the maxilla was not done. No additional surgical procedures were performed on the midface or chin, such as infraorbital augmentation, distraction, rhinoplasty, or genioplasty. Exclusion criteria to avoid any bias were patients' findings that exceeded routine orthognathic planning. These were patients with an anterior open bite of more than 1 cm, facial asymmetry with occlusal cants in the frontal plane, midline deviations and mandibular border asymmetry, matured cleft lip and palate, severe congenital facial deformity, and posttraumatic deformity.

All subjects had available both a lateral cephalogram and a lateral photogram in the natural head position (NHP) taken before orthodontic appliances were applied and nine months postsurgery, after removal of the orthodontic appliances and osteosynthesis materials (median follow-up: 9.4 ± 0.6 month).

Lateral cephalometry

Subjects were positioned in the cephalostat (Orthoceph, Siemens AG, Munich, Germany), and then the head holder was adjusted until the ear rods could be positioned into the ears without moving the patient. All radiographs were taken in the NHP with teeth together and lips in repose and with a metric ruler in front of the midfacial vertical line. No occipital supplement was used. According to cephalometric standards, the film distance to the X-ray tube was fixed at 150 cm and the film distance to the midsagittal plane of the patient's head at 18 cm.

Tracings were done for all cephalograms. After loading the cephalogram into a PC, the ruler was used to size the cephalogram image in the software program (Adobe Photoshop version 7.0, Adobe Systems, San Jose, CA, USA), so that 1 mm on the rule represented 1 mm of actual scale (life-size) in the software program. The landmarks were identified manually by a single examiner using the photographic software. Soft- and hard-tissue landmarks of the cephalograms were traced using a modified version of the analysis of Legan and Burstone [16] and Lew et al [17] (Figs. 1 and 2). Therefore, the horizontal

http://dx.doi.org/10.5772/51416

reference line was constructed by raising a line 7° from sella-nasion, and a line perpendicular to this at nasion was used as the vertical reference line. Movement of hard- and soft-tissue landmarks from pre- to postsurgery was measured in millimeters to the horizontal and vertical reference lines. The corresponding angles were constructed and measured in degrees in the presurgical and postsurgical cephalograms. Differences were recorded as the surgical change.

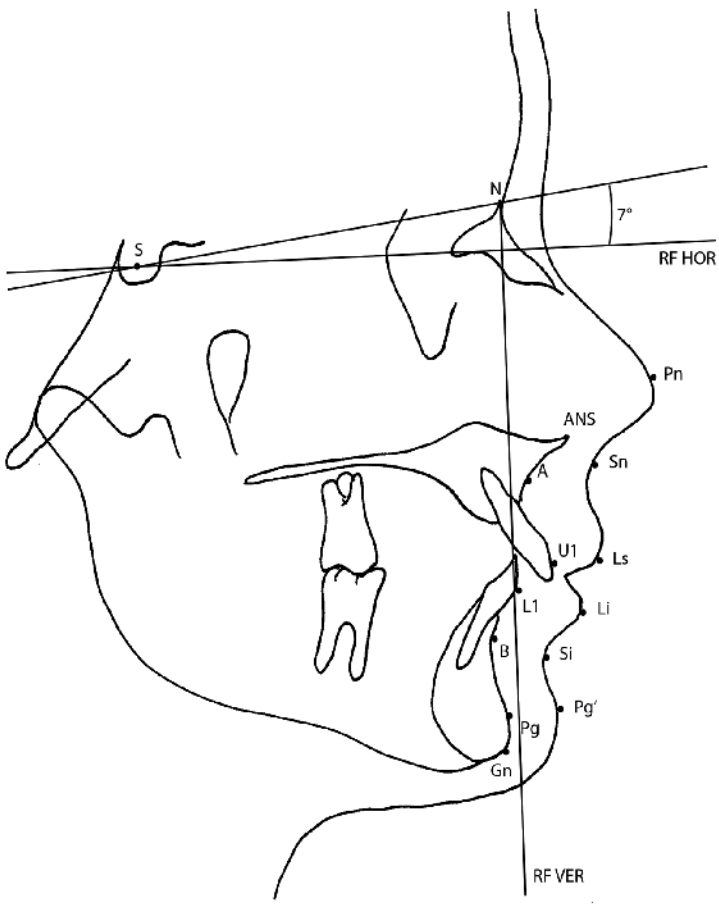

Figure 1. Hard and soft tissue landmarks and reference lines for tracing cephalograms.(N) = Nasion; (S) = Sella; (A) = Point A; (B) = Point B; (L1) = Lower incisor, (U1) = Upper incisor; (Gn) = Gnathion; (Pg) = Pogonium); (ANS) = Anterior nasal spine; (Pn) = Pronasale; (Sn) = Subnasale; (Ls) = Labrale superius; (Li) = Labrale inferius; (Si) = Labiomental sulcus; (Pg`) = Soft tissue pogonion; (RF HOR) = Horizontal reference line; (RF VER) = Vertical reference line.

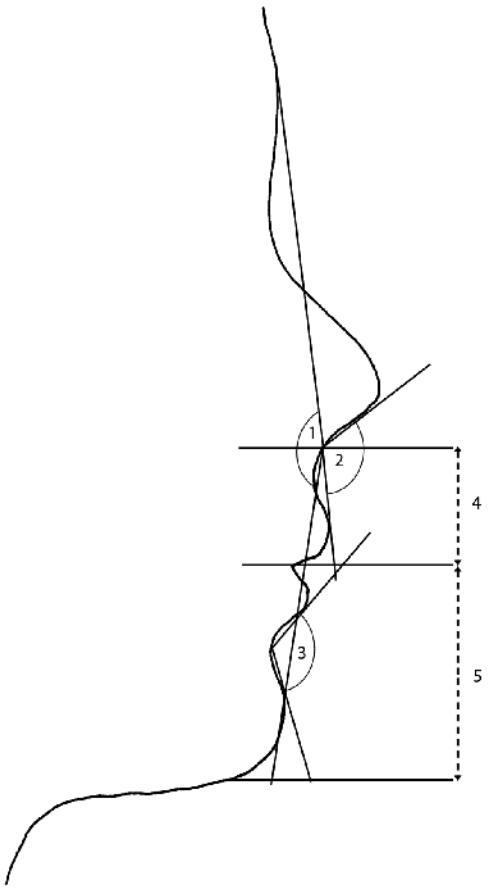

Figure 2. Soft-tissue angles and distances for tracing cephalograms and photograms. 1: Facial Convexity; 2: Nasolabial angle; 3: Labiomental angle; 4: Upper lip length; 5: Lower lip length.

2-D photogrammetry

Subjects were asked to sit on a chair in front of a pale blue background, maintain a straight back, and look straight ahead with a relaxed facial expression and eyes fully open, lips gently closed, and not smiling. A neck holder was then adjusted to help the subjects fix their NHP. For reproducibility, a simple, indirect light source on the ceiling was used, consisting of four 60-W fluorescent tubes to eliminate undesirable shadows from the contours of the facial profile. The subjects' faces were photographed in right lateral view, together with a metric scaled ruler in front of the midfacial vertical line (true vertical, TV). A high-resolution digital camera with a flash (Canon 450D, Tokyo, Japan) was firmly mounted on a photo stand 1 m in front of the subject. All photographs were taken at 2048 × 1536 pixels resolution

http://dx.doi.org/10.5772/51416

and saved in JPEG file format. Images were stored on the PC's hard drive and then transferred into the photographic software program. The lateral photographs were adjusted to life-size according to the cephalogram adjustment as above. Soft-tissue landmarks, distances, and angles were traced with the tools of the software. Additionally, TV on nasion and true horizontal (TH, perpendicular to TV through the tragus) were constructed as reference lines for horizontal and vertical landmark movements. Pre- and postsurgical distances of each landmark toward reference lines were measured and differences were recorded as the vertical and horizontal surgical change, respectively (Figs. 2 and 3).

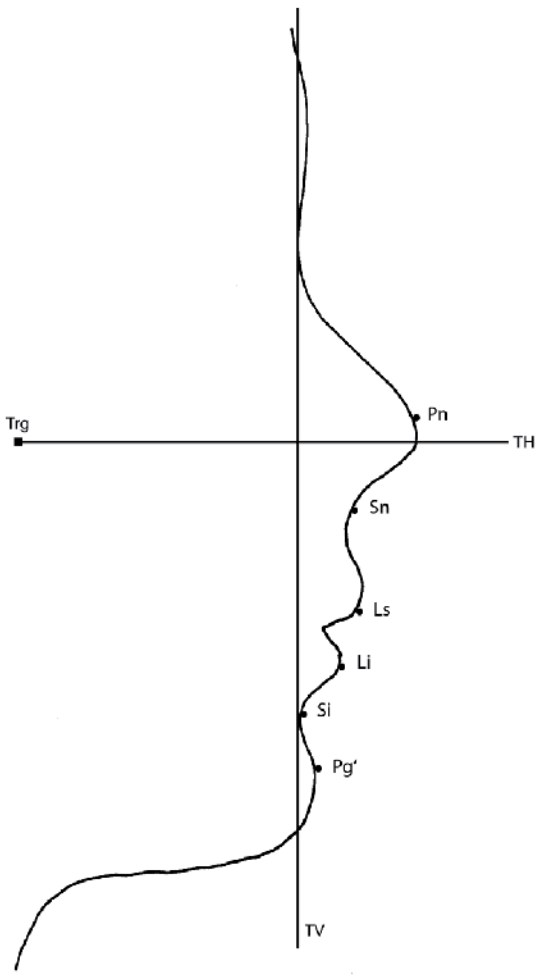

Figure 3. Soft- tissue landmarks and reference lines for tracing photograms.

(TV) = True Vertical; (TH) = True Horizontal; (Trg) = Tragus. Further abbreviations as given in Table 1.

Statistics and reliability of measurements

The collected data were subjected to statistical analysis using the PASW statistical software package, version 18.0 (SPSS, Chicago, IL, USA). Differences between groups were evaluated using the paired *t* test. Results were considered significant if $p < 0.05$ and highly significant if $p < 0.01$. Pearson`s correlation analysis was used to assess the degree of correlation between soft- and-hard tissue changes. The adjusted coefficient of determination (Adj R^2) was used to assess the predictability of landmark movements (ranging from 0 = no prediction possible to 1 = accurate prediction possible).

Reliability of measurements was determined by randomly selecting 10 cephalograms and 10 lateral photograms to repeat the tracings by a second senior examiner. The method error was calculated using the formula $\sqrt{\sum (x_1 - x_2)^2} \Big/ 2n$ in which X_1 was the first measurement, X_2, the second measurement, and n, the number of repeated records. All respective values of method error calculation for the linear measurements ranged between 0.32 and 0.48 mm for cephalometry and between 0.35 and 0.51 mm for 2-D photogrammetry, for angular measurements between 1.4° and 5.2° and between 1.6° and 4.9°, respectively. Significant differences between the reliability of photogrammetry and cephalometry could not be obtained.

3. Results

General findings

Significant differences between females and males could not be obtained cephalometrically or photogrammetrically, nor with respect to angular or distance measurements, pre- or postoperative, nor landmark movements. Therefore, gender was not considered further.

Hard-tissue angles assessed by cephalometry changed significantly from pre- to postsurgery in Class II and Class III patients (SNA, $p_{\text{Class II}} = 0.041$, $p_{\text{Class III}} = 0.015$; SNB, $p_{\text{Class II}} = 0.009$, $p_{\text{Class III}} = 0.008$; ANB, $p_{\text{Class II}} = 0.016$, $p_{\text{Class III}} < 0.001$; NAPg, $p_{\text{Class II}} = 0.043$, $p_{\text{Class III}} < 0.001$).

Soft tissue angles and distances

Significant differences between pre- and postsurgical measurements could be found for facial convexity, labiomental angle, and lower lip length by cephalometric and photogrammetric analyses (Table 1). Pre- to postsurgical changes of facial convexity in Class III patients and changes of lower lip length and labiomental angle in Class II patients revealed high significance ($p < 0.01$, Fig. 4). No significant changes from pre- to postsurgery could be found for the nasolabial angle or upper lip length.

http://dx.doi.org/10.5772/51416

		Photogrammetry			Cephalometry		
		presurgery	postsurgery		presurgery	postsurgery	
Parameter	**Class**	**Mean ± SD**	**Mean ± SD**	**p**	**Mean ± SD**	**Mean ± SD**	**p**
Facial convexity (°)	II	159.1 ± 4.8	165.9 ± 5.1	*0.023**	159.8 ± 2.3	163.5 ± 3.4	*0.015**
	III	178.8 ± 5.9	172.1 ± 6.1	*< 0.001***	178.8 ± 5.9	170.8 ± 7.3	*< 0.001***
Nasolabial angle (°)	II	111.2 ± 7.4	109.2 ± 9.2	0.671	111.4 ± 10.1	111.2 ± 7.5	0.976
	III	105.4 ± 12.4	104.6 ± 13.3	0.835	102.1 ± 14.2	103.2 ± 14.7	0.804
Labiomental angle (°)	II	119.1 ± 11.9	135.9 ± 9.8	*0.013**	120.8 ± 7.4	134.2 ± 9.9	*0.021**
	III	132.8 ± 14.6	121.1 ± 15.8	*0.013**	127.4 ± 12.9	115.5 ± 13.8	*0.004***
Upper lip length (mm)	II	13.5 ± 1.7	13.9 ± 1.3	0.621	13.9 ± 1.9	13.8 ± 1.9	0.533
	III	12.4 ± 1.6	13.1 ± 1.6	0.134	12.5 ± 2.1	13.1 ± 1.8	0.317
Lower lip length (mm)	II	24.7 ± 3.1	30.5 ± 3.3	*0.006***	29.9 ± 2.3	29.9 ± 2.3	*0.007***
	III	31.2 ± 3.4	28.8 ± 3.9	*0.029**	31.6 ± 2.9	28.4 ± 2.7	*0.003***

Table 1. *significant at the level $p < 0.05$, ** significant at the level $p < 0.01$. Pre- and postsurgical measurements of soft-tissue angles and distances.

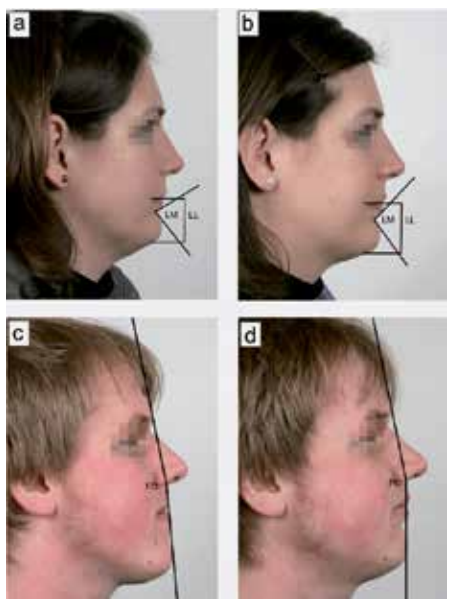

Figure 4. Screenshots of traced lateral photograms. Pre- to postsurgical changes of lower lip length (LL) and labiomental angle (LM) in Class II patients (a = presurgery, b = postsurgery) and changes of facial convexity (FC) in Class III patients (c = presurgery, d = postsurgery) revealed high significance.

Soft-tissue landmarks

			Photogrammetry	Cephalometry	
			Movement	Movement	p
Dimension	**Landmark**	**Class**	**Mean ± SD**	**Mean ± SD**	
Horizontal	Pn	II	0.9 ± 0.8	0.6 ± 0.5	0.251
		III	1.4 ± 2.6	1.1 ± 0.9	0.761
	Sn	II	2.1 ± 0.8	2.2 ± 0.9	0.883
		III	2.4 ± 1.6	1.2 ± 3.1	0.784
	Ls	II	2.5 ± 0.5	2.3 ± 1.7	0.831
		III	2.2 ± 1.6	1.1 ± 2.5	0.874
	Li	II	2.5 ± 0.8	2.2 ± 1.3	0.441
		III	-3.2 ± 2.1	-4.8 ± 3.1	0.376
	Si	II	2.7 ± 0.5	2.3 ± 0.8	0.421
		III	-5.4 ± 2.9	-5.9 ± 3.4	0.776
	PG`	II	2.5 ± 1.1	3.3 ± 1.2	0.232
		III	-6.8 ± 4.1	-6.1 ± 4.3	0.769
Vertical	Pn	II	0.1 ± 0.8	0.3 ± 0.5	0.451
		III	0.6 ± 1.1	0.4 ± 0.5	0.736
	Sn	II	0.2 ± 0.9	-0.2 ± 0.7	0.525
		III	0.6 ± 0.4	0.2 ± 0.4	0.688
	Ls	II	-0.5 ± 1.6	0.2 ± 0.9	0.418
		III	1.2 ± 0.8	1.4 ± 2.5	0.807
	Li	II	-0.6 ± 0.8	0.3 ± 1.2	0.187
		III	1.2 ± 2.1	2.5 ± 2.6	0.411
	Si	II	-1.3 ± 1.6	-0.2 ± 1.3	0.205
		III	1.8 ± 1.9	2.6 ± 1.9	0.283
	PG`	II	-1.2 ± 0.8	-0.7 ± 0.7	0.204
		III	1.4 ± 1.8	1.8 ± 2.3	0.199

Table 2. Pre- to postsurgical movements (mm) of soft-tissue landmarks in horizontal and vertical dimensions assessed by photogrammetry and cephalometry.

The measurements of pre- to postsurgical soft-tissue landmark movements did not differ significantly between photogrammetry and cephalometry (Table 2). In Class III patients, the greatest movements were found photogrammetrically and cephalometrically for Pg′ in the

http://dx.doi.org/10.5772/51416

horizontal and for Si in the vertical dimension. In Class II patients, Si movements assessed by photogrammetry and Pg′ movements assessed by cephalometry revealed the greatest movements in both horizontal and vertical directions.

Correlations between soft- and hard-tissue changes

Significant correlations between soft- and hard-tissue changes (Table 3) occurred cephalometrically only in Class III patients. Highly significant correlations were found between facial convexity and SNB, ANB, and NAPg and between lower lip length and SNB, ANB, and NAPg. Photogrammetrically significant correlations occurred in Class II patients for labiomental angle and SNB, ANB, and NAPg and in Class III patients for facial convexity and NAPg; for nasolabial angle and SNA; and for lower lip length and NAPg. Significant correlations for both Class II and III patients could be shown between lower lip length and ANB.

	Parameters[a]	Class	SNA	SNB	ANB	NAPg
Cephaloametry	Facial convexity	II	ns	ns	ns	ns
		III	ns	*0.003***	*<0.001***	*<0.001***
	Upper lip lenght	II	ns	ns	ns	ns
		III	ns	ns	*0.032**	*0.010**
	Lower lip lenght	II	ns	ns	ns	ns
		III	ns	*0.002***	*<0.001***	*0.003***
Photogrammetry	Facial convexity	II	ns	ns	ns	ns
		III	ns	ns	ns	*0.036**
	Nasolabial angle	II	ns	ns	ns	ns
		III	*0.034**	ns	ns	ns
	Labiomental angle	II	ns	*0.038**	*0.037**	*0.030**
		III	ns	ns	ns	ns
	Lower lip lenght	II	ns	ns	*0.027**	ns
		III	ns	ns	*0.032**	*0.047**

Table 3. [a] only parameters revealing at least one significance were considered ns: indicates not significant; * significant at the level $p < 0.05$, ** significant at the level $p < 0.01$. Significance of correlations between soft- and hard-tissue changes

Correlations of hard- and soft-tissue movements between pre- and postoperative corresponding landmarks in the horizontal and vertical planes revealed significance for both cephalometry and 2-D photogrammetry in Class II and III patients (Table 4). Correlations could be found for both methods between Sn and A, Si and B, and Pg′ and Pg in the hori-

zontal plane for Class II and III patients. In the vertical plane for Class II patients, correlations could be shown cephalometrically only for Sn and A, and photogrammetrically only for Pg′ and Pg. In Class III patients, cephalometry and 2-D photogrammetry revealed both significant correlations between vertical movements of Sn and A, Ls and U1, and Pg′ and Pg. In cases of significant correlation, Adj R^2 was above the 0.7 level, representing a satisfactory accuracy for prediction.

Soft tissue parameter[a]	Hard tissue parameter[a]	Class	$p_{Sceph; H}$	Adj. R^2	$p_{Sphoto; H}$	Adj. R^2
Horizontal						
Sn	A	II	*0.046**	0.717	*0.011**	0.792
		III	*0.044**	0.718	*0.010**	0.891
Si	B	II	*0.023**	0.707	*0.038**	0.725
		III	*0.034**	0.762	*0.030**	0.778
Pg`	Pg	II	*0.032**	0.752	*0.015**	0.757
		III	*0.010**	0.894	*0.044**	0.720
Vertical						
Sn	A	II	*0.036**	0.732	ns	0.121
		III	*0.043**	0.721	*0.016**	0.821
Ls	U1	II	ns	0.044	ns	0.044
		III	*0.044**	0.721	*0.018**	0.701
Pg`	Pg	II	ns	0.183	*0.041**	0.712
		III	*0.010**	0.889	*0.030**	0.782

Table 4. [a] only parameters revealing at least one significance were considered.$p_{Sceph; H}$: significance of correlation between *cephalometrically* assessed soft- tissue landmark movement and corresponding hard-tissue landmark movement.$p_{Sphoto; H}$: significance of correlation between *photogrammetrically* assessed soft-tissue landmark movement and corresponding hard-tissue landmark movement.Adj. R^2: adjusted coefficient of determination.ns: indicates not significant; * significant at the level $p < 0.05$.Significances between hard- and soft-tissue landmark movement correlations .

Soft-to-hard tissue movement ratios

Soft-to-hard tissue movement ratios in the horizontal and vertical planes for corresponding landmarks displayed a soft-tissue response following hard-tissue movement (Table 5). No

http://dx.doi.org/10.5772/51416

significant difference could be obtained between cephalometry and 2-D photogrammetry with respect to the soft- to hard-tissue movement ratios.

Soft- tissue parameter (S)	Hard- tissue parameter (H)	Class	Ratio S(ceph): H	Ratio S(photo): H
Horizontal				
Pn	ANS	II	0.33	0.73
		III	0.25	0.35
Sn	A	II	1.83	1.73
		III	0.39	0.59
Ls	U1	II	1.11	1.76
		III	0.27	0.60
Li	L1	II	0.88	1.09
		III	0.03	0.56
Si	B	II	1.27	1.35
		III	1.20	1.13
Pg`	Pg	II	1.13	1.09
		III	0.98	1.15
Vertical				
Pn	ANS	II	0.33	0.33
		III	0.40	0.60
Sn	A	II	0.06	0.03
		III	0.20	0.80
Ls	U1	II	0.25	0.35
		III	0.60	0.80
Li	L1	II	0.25	0.15
		III	0.33	0.07
Si	B	II	0.25	0.37
		III	1.37	0.83
Pg`	Pg	II	0.33	0.57
		III	1.49	0.57

Table 5. Soft-to-hard tissue movement ratios in horizontal and vertical dimensions for corresponding landmarks .

4. Discussion

The results of this study showed that maxillary and mandibular movements with bimaxillary osteotomy were effective on soft tissues both in vertical and horizontal directions, and they improved facial convexity to approximate esthetic norms. Arnett and Bergman [18,19] described the facial profile according to the angle of facial convexity in Class I (165°–175°), Class II (<165°), and Class III profiles (> 175°). Following this classification, in our study postsurgical Class I facial convexity was achieved in Class II and III patients and was assessed by 2-D photogrammetry as well as by cephalometry. However, cephalometric and photogrammetric changes of the labiomental angle could be obtained only in Class II patients. Fernández-Riveiro et al [20] found that the labiomental angle should be evaluated with caution because of its high method error and variability. In this study as well, photogrammetrically and cephalometrically defined labiomental angle measurements revealed the highest variability of all measurements.

Whereas horizontal movement of soft-tissue landmarks in Class II and III patients—with the exception of labrale superius and inferius—were strongly correlated cephalometrically and 2-D photogrammetrically with hard-tissue landmark movements, vertical movements of landmarks were mostly hard to predict. One reason might be that vertical mandibular movements in our patients were only minimal and beneath the capability of cephalometric and 2-D photogrammetric analyses, since patients with massive vertical deficits were excluded to avoid any bias in this study. Accordingly, Lin and Kerr [21] also found in their cohort that these may account for the increased difficulty in accurately predicting a change in the vertical dimension. In comparison, in the study of Nkenke et al. [15] using optical 3-D images for analysing soft-tissue advancement in patients undergoing midfacial distraction at 6 and 24 months postsurgically, means of vertical advancement of Sn (1.0 ± 1.0 mm; 0.4 ± 0.9 mm, respectively) and labrale superius (0.4 ± 1.1 mm; -0.2 ± 0.5 mm, respectively) were within the scope of the data assessed in this study by 2-D photogrammetry and cephalometry for Class II and III patients. Hence, adequate accuracy of determination of vertical movements could be achieved with both methods in this study and referring to the study of Nkenke et al. [15], the level of validity is acceptable. However, further studies are warranted to evaluate the concept of vertical changes in patients with extensive vertical discrepancies.

Findings in this study suggest that cephalometric and 2-D photogrammetric analyses complement one another in predicting soft-tissue changes in orthodontic surgery patients. For the combination of both methods, at least one parameter for the maxilla (Sn-A) and one for the mandible (Pg′-Pg) became predictable for the vertical dimension with an acceptable adjusted coefficient of determination. Special attention should be given to soft-tissue changes in Class II patients, which cephalometrically revealed no significant correlation with hard-tissue angular changes, whereas correlations could be obtained with 2-D photogrammetry. We therefore recommend supplementary 2-D photogrammetry for evaluating soft- to hard-tissue changes and cephalometric prediction, especially in Class II patients.

Previous cephalometric findings have shown mandibular skeletal movement for the soft-tissue chin at a ratio of between 0.9:1 and 1:1 [22,23]. The results of this study support this his-

http://dx.doi.org/10.5772/51416

torical observations cephalometrically as well as 2-D-photogrammetrically for Class II and Class III patients. However, the labrale inferius (Li) in our study responded at a ratio of 0.88:1 cephalometrically and 1.09:1 photogrammetrically to the corresponding hard-tissue movements in the horizontal plane in Class II patients, but only at ratios of 0.03:1 and 0.56:1 in Class III patients, respectively. This is cephalometrically much lower than the ratio found in other investigations in Class III patients, which ranged from 0.6:1 to 0.75:1 [22, 23]. In comparison, with 2-D photogrammetry the lower border of this range was nearly reached.

Standard-error calculation suggests that standards presented in this study for cephalometry and 2-D photogrammetry set-ups are ready for routine evaluation of soft-tissue changes after orthognathic surgery. However, all ratios presented in this study and in the literature suggest that even a mathematically accurate prediction may involve bias [24]. This means that prediction and soft- to hard-tissue movement ratios must be evaluated on an individual basis and that they depend at least partly on the experience of the surgeon in his or her hand-setting of the maxilla during bimaxillary surgery. Furthermore, various types of operations—as well as the morphology of the anatomic structures—must be considered in predicting the outcome of facial surgery [25]. In comparison to data reported in another study from Nkenke et al. [26] using pre- and postsurgical 3-D facial surface images in patients undergoing LeFort I osteotomy, advancements of Sn and Ls were within the range of the results obtained in this study for horizontal movements of these parameters assessed with cephalometry and 2-D photogrammetry. Furthermore, the ratio of advancement between labrale superius and incision superius reported by Nkenke et al. [26] was 80 ± 94 % and comparable with our findings. In accordance to the ratios of vertical advancement and referring to the method of Nkenke et al. [26] again, validity of at least this ratio of horizontal advancement is adequate in our study. However, the 3-D facial surface images analysis possesses moreover the ability to predict volume increases or decreases especially in the malar- midface region and could therefore improve the predictability of esthetic soft tissue results. Future studies may reveal which orthognathic surgery cases are best suited for 3-D imaging techniques. The data of this study might be helpful.

5. Conclusion

This study revealed that cephalometry and 2-D photogrammetry provide the option to complement one another to enhance accuracy in predicting soft-tissue changes in orthodontic surgery, especially in Class II patients.

Acknowledgements

We gratefully acknowledge Ilknur Tetik, B.A., School of Architecture, Bremen, Germany, for her contribution to photogrammetric set-up.

Author details

Jan Rustemeyer*

Address all correspondence to: janrustem@gmx.de

Department of Oral and Maxillofacial Surgery, Klinikum Bremen-Mitte, School of Medicine of the University of Göttingen, Germany

The authors declare they have no conflict of interest.

References

[1] Jacobson, A. (1984). Psychological aspects of dentofacial esthetics and orthognathic surgery. *Angle Orthod*, 54, 18-35.

[2] Kiyak, H. A., West, R. A., Hohl, T., & Mc Neill, R. W. (1982). The psychological impact of orthognathic surgery: a 9-month follow-up. *Am J Orthod*, 81, 404-412.

[3] Rustemeyer, J., Eke, Z., & Bremerich, A. (2010). Perception of omprovement after orthognathic surgery: the important variables affecting patient satisfaction. *Oral Maxillofac Surg*, 14, 155-162.

[4] Chou, J. I., Fong, H. J., Kuang, S. H., Gi, L. Y., Hwang, F. Y., Lai, Y. C., Chang, R. C., & Kao, S. Y. (2005). A retrospective analysis of the stability and relapse of soft and hard tissue change after bilateral sagittal split osteotomy for mandibular setback of 64 Taiwanese patients. *J Oral Maxillofac Surg*, 63, 355-361.

[5] Enacar, A., Taner, T., & Toroglu, S. (1999). Analysis of soft tissue profile changes associated with mandibular setback and double-jaw surgeries. *Int J Adult Orthod Orthognath Surg*, 14, 27-35.

[6] Koh, C. H., & Chew, M. T. (2004). Predictability of soft tissue profile changes following bimaxillary surgery in skeleta1 Class III Chinese patients. *J Oral Maxillofac Surg*, 62, 1505-1509.

[7] McCance, A. M., Moss, J. P., Fright, W. R., & Linney, A. D. (1997). Three-dimensional analysis technique-Part 3: Color-coded system for three-dimensional measurement of bone and ratio of soft tissue to bone: the analysis. *Cleft Palate Craniofac J*, 34, 52-57.

[8] Nanda, R. S., Ghosh, J., & Bazakidou, E. (1996). Three-dimensional facial analysis using a video imaging system. *Angle Orthod*, 66, 181-188.

[9] Moss, J. P., Mc Cance, A. M., Fright, W. R., Linney, A. D., & James, D. R. (1994). A three-dimensional soft tissue analysis of fifteen patients with class II, division I malocclusions after bimaxillary surgery. *Am J Orthod Dentofac Orthop*, 105, 430-437.

http://dx.doi.org/10.5772/51416

[10] Rabey, G. (1971). Craniofacial morphanalysis. *Proc R Soc Med*, 64, 103-111.

[11] Hell, B. (1995). 3D sonography. *Int J Oral Maxillofac Surg*, 4, 84-89.

[12] Deli, R., Di Gioia, E., Galantucci, L. M., & Percoco, G. (2010). Automated landmark extraction for orthodontic measurement of faces using the 3-camera photogrammetry methodology. *J Craniofac Surg*, 21, 87-93.

[13] Plooij, J. M., Swennen, G. R., Rangel, F. A., Maal, T. J., Schutyser, F. A., Bronkhorst, E. M., Kuijpers-Jagtman, A. M., & Bergé, S. J. (2009). Evaluation of reproducibility and reliability of 3D soft tissue analysis using 3D stereophotogrammetry. *Int J Oral Maxillofac Surg*, 38, 267-273.

[14] Okudaira, M., Kawamoto, T., Ono, T., & Moriyama, K. (2008). Soft-tissue changes in association with anterior maxillary osteotomy: a pilot study. *Oral Maxillofac Surg*, 12, 131-138.

[15] Nkenke, E., Langer, A., Laboureux, X., Benz, M., Maier, T., Kramer, M., Häusler, G., Kessler, P., Wiltfang, J., & Neukam, F. W. (2003). Validation of in vitro assessment of facial soft-tissue volumne changes and clinical application in midfacial distraction: a technical report. *Plast Reconstr Surg*, 112, 367-380.

[16] Legan, H. L., & Burstone, C. l. (1980). Soft tissue cephalometric analysis for orthognathic surgery. 38, 744-751.

[17] Lew, K. K., Low, F. C., Yeo, J. F., & Loh, H. S. (1990). Evaluation of soft tissue profile following intraoral ramus osteotomy in Chinese adults with mandibular prognathism. *Int J Adult Orthodon Orthognath Surg*, 5, 189-197.

[18] Arnett, G. W., & Bergman, R. T. (1993). Facial keys to orthodontic diagnosis and treatment planning. Part I. *Am J Orthod Dentofacial Orthop*, 103, 299-312.

[19] Arnett, G. W., & Bergman, R. T. (1993). Facial keys to orthodontic diagnosis and treatment planning. Part II. *Am J Orthod Dentofacial Orthop*, 103, 395-411.

[20] Fernández-Riveiro, P., Smyth-Chamosa, E., Suárez-Quintanilla, A., & Suárez-Cunqueiro, A. (2003). Angular photogrammetric analysis of the soft tissue facial profile. *Eur J Orthod*, 25, 393-399.

[21] Lin, S. S., & Kerr, W. J. (1998). Soft and hard tissue changes in Class III patients treated by bimaxillary surgery. *Eur J Orthod*, 20, 25-33.

[22] Hershey, H. G., & Smith, L. H. (1974). Soft-tissue profile change associated with surgical correction of the prognathic mandible. *Am J Orthod*, 65, 483-502.

[23] Lines, P. A., & Steinhäuser, E. W. (1974). Soft tissue changes in relationship to movement of hard structures in orthognathic surgery: a preliminary report. *J Oral Surg*, 32, 891-896.

[24] Marşan, G., Cura, N., & Emekli, U. (2009). Soft and hard tissue changes after bimaxillary surgery in Turkish female Class III patients. *J Craniomaxillofac Surg*, 37, 8-17.

[25] Moss, J. P., Grindrod, S. R., Linney, A. D., Arridge, S. R., & James, D. (1988). A computer system for the interactive planning and prediction of maxillofacial surgery. *Am J Orthod Dentofac Orthop*, 94, 469-475.

[26] Nkenke, E., Vairaktaris, E., Kramer, M., Schlegel, A., Holst, A., Hirschfelder, U., Wiltfang, J., Neukam, F. W., & Stamminger, M. (2008). Three-dimensional analysis of changes of the malar-midfacial region after LeFort I osteotomy and maxillary advancement. *Oral Maxillofac Surg*, 12, 5-12.

Chapter 29

Corticotomy and Miniplate Anchorage for Treating Severe Anterior Open-Bite: Current Clinical Applications

Mehmet Cemal Akay

Additional information is available at the end of the chapter

http://dx.doi.org/10.5772/53857

1. Introduction

Anterior open bite (AOB) is a term used if there is localized absence of occlusion anteriorly when the remaining teeth are in occlusion; it is commonly one of the main symptoms of an overall dentofacial deformity. Diagnosis, treatment, and retention can be difficult because this malocclusion has numerous correlated etiologic factors. Clinically, it is grouped into 2 main categories: dental or acquired open-bites which have no distinguishing craniofacial malformations, and skeletal open bite with superimposed craniofacial dysplasia. [1]

The cause of an anterior open bite is multifactorial and can be attributed to a combination of skeletal, dental, and soft-tissue defects. Vertical malocclusion develops as a result of the interaction of many different etiologic factors including thumb and finger sucking, lip and tongue habits, airway obstruction, and true skeletal growth abnormalities. The etiologic factors play an important role in diagnosis. Heredity, unfavorable growth patterns and incorrect jaw postoure are the characteristics of skeletal AOB. Besides depending on where the thumb is placed, a number of different types of dental problems can develop. Malocclusions of the late mixed or permanent dentitions, caused by thumb sucking are not self-corrected and surely orthodontic treatment is necessary. Due to oral respiration, the mandible is postured inferiorly with the tongue protruded and resting against the oral floor. This postural alteration induces dental and skeletal modifications similar to those caused by thumb sucking. This may cause excessive eruption of the posterior teeth, leading to an increase in the vertical dimension of the face and result in development of AOB. Additionally, tongue habits cause an AOB or they develop secondarily to thumb sucking. In skeletal AOB the tongue habit acts as a secondary factor which helps to maintain or exacerbate the condition. Many

INTECH
open science | open minds

© 2013 Akay; licensee InTech. This is a paper distributed under the terms of the Creative Commons Attribution License (http://creativecommons.org/licenses/by/3.0), which permits unrestricted use, distribution, and reproduction in any medium, provided the original work is properly cited.

orthodontists have had a discouraging experience of completing dental treatment, with what appeared to be good results, only to discover that the case had relapsed because the patient had a tongue thrust swallowing pattern. AOB is frequently observed in orthodontic practice. While 17.7% of children in the early to mixed dentition period present with an open bite of 1–12 mm [2], even after an improvement in orofacial dysfunctions [3], AOB is still diagnosed in 2.9% of adult Caucasian Americans [4]; it is an increasingly recognized major orthodontic problem. Patients with AOB malocclusion can be diagnosed clinically and cephalometrically; however, diagnosis should be viewed in the context of the skeletal and dental structure. Accurate classification of this malocclusion requires experience and training. Simple AOB during the exchange of primary to permanent dentition usually resolves without treatment. However, complex skeletal AOB that extend farther into the premolar and molar regions, and those that do not resolve by the end of the mixed dentition years may require orthodontic and/or surgical intervention. Most skeletal AOB cases are characterized by excessive vertical development of the posterior maxilla and usually have excessive eruption of posterior teeth accompanying AOB. [5] Treatment for AOB ranges from observation or simple habit control to complex surgical procedures. Successful identification of the etiology improves the chances of treatment success. Vertical growth is the last dimension to be completed, therefore treatment may appear to be successful at one point and fail later. Some treatment may be prolonged, if began early. When orthodontic or surgical intrusion of the overerupted maxillary teeth is performed, the mandible rotates closed at rest and in function, resulting in open-bite closure. [6] Different treatment modalities have been used for this purpose such as orthognathic surgery, conventional orthodontic appliances and combined methods. Orthodontic treatment options include functional appliances, and orthopedic devices. Intrusion of the overerupted molar teeth by traditional orthodontic methods is hardly possible in adult patients; there is therefore no real alternative to a combined orthodontic and surgical approach because the condition tends to recur after orthodontic treatment alone. In adult patients, combined approaches of surgery and orthodontic appliances make it possible to complete orthodontic treatment in a fast and predictable manner. [7]-[11] In the present chapter, advantages and disadvantages of current treatment protocols and corticotomy-facilitated compressive force procedure using orthodontic anchor plates applications are discussed in light of the current clinical literature.

2. Current clinical applications for treating severe AOB

2.1. Traditional orthodontic treatment options for AOB

Long-term skeletal and dental stability has been a concern because of the influence that the neuromusculature has on the repositioned jaws and the stability of teeth after vertical orthodontic mechanics required for closing open bites. Traditional treatment modalities include compensating orthodontics, functional appliances, and orthopedic devices. Orthodontic treatment involves extrusion of incisors or intrusion of molars. These therapies show relatively stable results for younger patients. In young patients, the vertical maxillary growth can be controlled with a high-pull headgear or a functional appliance with bite blocks. Once

http://dx.doi.org/10.5772/53857

excessive vertical development of the posterior maxilla has occurred, only two treatment options are available for the correction of an openbite. Elongation of the anterior teeth leaves the skeletal component of the deformity unchanged. However, traditional techniques are concluded to produce only relative intrusion of the molars and have a limited effect in providing sound anchorage. [12] The ideal period to begin open bite treatment is during the mixed dentition; if the malocclusion is corrected during the deciduous dentition, it will recur because of continued growth changes. In the mixed dentition, the most important step in correcting an open bite associated with abnormal habits is to eliminate the habits with behavior-modification techniques, accompanied by speech therapy; if necessary, a removable functional appliance with a vertical crib can be used. It is important to present this treatment to the child as an aid and not as a penalty. In about half of the patients, thumb sucking ceases immediately, and the anterior open bite closes relatively quickly. After the habit is eliminated, it is important to maintain the appliance for 3 to 6 months. However, when the open bite is associated with skeletal features such as an increased mandibular plane angle, anterior face height, and extruded posterior teeth, it is necessary to redirect maxillary growth with molar intrusion, to rotate the mandible in an upward and forward direction. [13] On the other hand, if the skeletal relationship is the primary cause of the AOB and control of the sucking habit is limited, the prognosis is poor. [14] The treatment of choice for this problem is to reduce the vertical dimension by reducing the height of the posterior teeth. The difficulty of managing anterior open-bite malocclusions is not only in obtaining the correct diagnosis, but also in treating a successful facial and dental result. The orthodontist's challenge is to minimize molar extrusion during treatment to prevent downward and backward mandibular rotation. The early treatment strategy of skeletal AOB is based on inhibition of the vertical development or intrusion of the buccal dentoalveolar structures by means of bite-blocks or extraoral appliances, thus producing upward and forward rotation of the mandible into a more horizontal, rather than vertical growth direction. Early interception offers psychological benefits and the potential for condylar growth. Nonsurgical options usually require longer treatment times and greater patient compliance. Although attempts to limit the increase in vertical dimensions by at least 1 of the above approaches were done by orthodontists, posterior bite-blocks proved to be effective in producing condylar growth and forward rotation of the mandible. To actively intrude the posterior teeth, active components in the form of magnets and springs have been suggested. [13]-[23]

The design of spring-loaded bite-blocks was first described by Woodside and Linder-Aronson. These blocks are activated from time to time, and they supply additional force in the neuromuscular system, in addition to the forces of the masticatory muscles that are exerted by the passive posterior bite-blocks. Because of its peculiar design, it was thought that the same appliance could also act as a habit-breaking appliance. With this appliance, the patient must apply active force to close his mouth, and this acts as a distraction device. By intruding the posterior teeth, the mandible autorotates upward and forward. This form of treatment is advantageous because it corrects the AOB and simultaneously reduces the total anterior facial height. The increase in muscle strength because of its oral dynamic effect ensures a stable result. A modified acrylic occlusal splint along with spring-loaded bite blocks have been used to correct the skeletal AOB during the mixed dentition was shown to be efficient, but

its correct indication and control are of fundamental importance. Many approaches have been suggested to modify this early developmental pattern, but only posterior bite-blocks proved to be effective in producing condylar growth and forward rotation of the mandible. [14]-[23] To actively intrude the posterior teeth, Iscan et al., Akkaya and Haydar suggested the use of a spring-loaded bite-block. When adult patients are treated using classical orthodontic appliances, the duration of the treatments increase and risks such as root and marginal alveolar bone resorption, undesired movements of anchorage teeth, and relapse occur. Dental stability after vertical orthodontic mechanics is unpredictable and is prone to relapse. [24] Relapse is multifactorial and can involve skeletal and dentoalveolar components.

2.2. Orthognathic surgery techniques for AOB

Orthognathic surgery techniques for the treatment of AOB have been used for many years. The most frequently performed surgical procedures for AOB is correction via superior repositioning of the maxilla via LeFort I osteotomy, posterior segmental maxillary osteotomy, and vertical ramus osteotomy. Early attempts to close an AOB with mandibular procedures were mainly segmental [25], but were soon replaced by posterior impaction of the maxilla at LeFort I level as this was thought to be more stable. [26]-[28] If the mandible does not rotate into the correct position after the maxilla is impacted, 2-jaw surgery is required. The fear of surgery or general anesthesia and other factors may lead a significant proportion of patients to refuse surgery. Fewer than half of their patients who had sought orthodontic treatment for long-face problems accepted the recommended orthognathic surgery. Proffit et al., considered that a patient with a skeletal long-face problem who refused surgical correction was better left untreated. However, after initially successful correction of the vertical dimension by a combined treatment with a multibracket appliance and bimaxillary osteotomies, some of these patients with primary open bite may after treatment, experience a vertical relapse with a reduction in the overbite, or the reappearance of the anterior open bite. At post-treatment follow-up, the relapse rate ranged from 12% to roughly 30% depending on the type of treatment [29]-[34] In patients with severe AOB, secondary orthodontic therapy or repeated surgery may become necessary. The main indication for treatment of an AOB by posterior maxillary impaction is the presence of posterior maxillary vertical maxillary excess, which is common. About one third of patients who present with orthognathic concerns have vertical maxillary excess. It is also reported that about 60%of patients with it also have an openbite, or a tendency to an openbite. [35] It follows that many patients who are operated on to correct AOB may require maxillary surgery. Where the vertical and anterior–posterior position of the maxilla is within reasonable limits there is less of an indication to operate on the maxilla, except when it is thought to be the most stable technique to close an AOB. Although many studies have reported better stability with a maxillary procedure, the patients are heterogeneous and include those with appreciable vertical maxillary discrepancies. [36],[37] Few compare or report on cases where the maxilla was in a favourable position without a posterior vertical maxillary extension. The height of the mandibular ramus and the clinical state of the condyles are factors only recently emphasised as useful contributors to aiding the decision about the choice of procedure. [35]

http://dx.doi.org/10.5772/53857

Patients with a short mandibular ramus, normal condyles, no sign of ongoing resorption, and a well positioned maxilla would lend themselves to a mandibular sagittal split osteotomy (MSSO) alone as the procedure of choice. There have been few publications about mandibular surgery alone, with the few studies published including sample sizes of only 15–30. [38],[39] This may reflect the limited number of cases that are appropriate for such a procedure, or may reflect the blanket treatment selected by many, based on the heterogeneous case-mix previously analyzed, which universally suggests more stability with maxillary surgery. [40] Studies that describe or compare mandibular anticlockwise rotational movements alone do not clarify the technique of sagittal split osteotomy, and whether this was conventional or modified. In particular, with reference to the posterior extension of the cutinthe medial ramus, ensuring a split that allows part of the medial pterygoid to remain attached to the proximal segment and to stripping of the pterygomasseteric sling, medial pterygoid, and stylomandibular ligament from the distal segment. [35] These manoeuvres during a modified medial ramus osteotomy named as "short split technique" [26] reduce the risk that the medial pterygoid muscle may contribute to forces that encourage relapse when closing an AOB with the mandible. Other factors thought to contribute to relapse are the stretching of nonmuscular soft tissue and neuromuscular activity. Both factors are thought to adapt early postoperatively rather than cause relapse. Various studies have suggested that rigid fixation confers greater stability than other methods in the closure of AOB. [41] It has been suggested that rigid fixation using positional screws in the closure of an AOB may confer better surgical stability than semirigid mini-plates, and was therefore the preferred method used by the surgeons in this study. [36],[38],[41],[42]

Although maxillary osteotomy is done regularly with few complications, morbidity still exists and can be life threatening, especially if there is severe bleeding. In clinical practice, some patients who need closure of an AOB may also require an increased prominence of the chin. This would necessitate advancement genioplasty if the correction of the AOB was to be achieved by maxillary surgery only. Anticlockwise rotation of the mandible has the esthetic advantage of addressing this deficit, and avoids the risks and morbidity associated to advancement genioplasty as an additional procedure. Although there are few published reports, a growing numbers of surgeons are attempting and reporting MSSO technique to close AOB. [35],[38]-[40] Bimaxillary surgery, although advocated in the closure of AOB, may present a higher risk of morbidity than either maxillary or mandibular surgery alone. Published evidence has recognized the risks of relapse with this procedure [37],[43] and means that care must be taken in calculating the definite need for double jaw surgery to optimize the risk-to-benefit ratio for the patient.

This surgical procedure has not been well accepted because of rigid fixation, the need to use bone grafts and membranes, severe bleeding, longer duration of hospitalization, the risk of dental and periodontal problems that may occur when the bone segments are rapidly and excessively separated and increased risk of relapse. [44]

2.3. Titanium implants or bone anchors for AOB

AOB due to posterior maxillary dentoalveolar hyperplasia can be closed without orthognathic surgery. Osseointegrated implants serve as absolute anchorage for the intrusion of over-erupted teeth; and, after tooth movement, can be used as restorative abutments. Patients who do not need prosthetic rehabilitation may benefit from a removable skeletal anchoring device that can be placed outside the dentition. Absolute anchorage can only be achieved if the anchorage devices are fixed in bone. Such devices include miniplates, miniscrews, palatal implants, onplants and dental implants. Anchorage control is a prerequisite for the success of orthodontic treatment. Loss of dental anchorage during orthodontic treatment leads to uncontrolled occlusion results. Recent clinical studies regarding AOB suggesting the use of skeletal anchors with fixed Edgewise appliances, demonstrated that incorporation of skeletal anchors was an excellent alternative to traditional orthodontic treatment methods and may provide a significant amount of maxillary and/or mandibular molar intrusion for AOB. The pure titanium miniplates that are well-known in maxillofacial trauma and orthognathic surgery comply with these criteria.[11],[45]-[52] Several studies have examined the effects of miniplates as anchors for orthodontic distal and intrusive movements. [11],[12],[53]-[57] Miniplates placed outside the maxillary and mandibular dentition functioned as onplants, and the screws functioned as implants, making rigid anchorage possible. Rigid anchorage results from osseointegration of both anchor plates and screws. Although there have been some promising casereports, there are few studies on the posttreatment complications of miniplates used for orthodontic anchorage. Umemori et al., Sherwood et al. and Akay et al. reported that the miniplates in their studies were quite stable. However, some patients developed chronic infections related to the miniplates. Nowadays, for upper or lower molar intrusion, orthodontic implants, miniscrews and modified titanium miniplates are used and recommended by different investigators. In a study by Xun et al. on 12 patients with open bite malocclusions, upper and lower molars were intruded 1.8 mm and 1.2 mm, respectively, in a mean of 6.8 months with the use of micro-screws as anchors. Several reports document that screw-type implants have been successful anchoring units in general. [46],[56]-[59] Miyawaki et al. found that the 1-year success rate of screws with 1.0-mm diameter was significantly less than that of other screws with 1.5-mm or 2.3-mm diameter or than that of miniplates. When compared with mini or micro-screws, titanium anchor plates hold the advantage of functioning as sound anchorage units against increased force levels. [11],[12],[51]-[53],[55]-[61] Furthermore, a high-mandibular plane angle was found to be a potential risk factor for the failure of screw-type implant anchors and the use of miniplates in patients with high mandibular plane angles were suggested when micro-screws were risky to insert.[56] In a clinical study Akay et al. treated adults with AOB, using titanium screws of 2.3 mm diameter and 7, 9, 13 mm lengths and their results correlated with recent studies by Sherwood et al., Chung et al., De Clerck et al., Miyawaki et al., Erverdi et al., Choi et al., and Erverdi et al. concluding that miniplates placed at zygomatic butresses and buccal bone above the roots of premolars remained stable following application of intrusive forces. In this study, no signs of mobility of titanium screws placed in the palatal bone were observed.

http://dx.doi.org/10.5772/53857

Sherwood et al. and Erverdi et al. supported orthodontic forces by implanting titanium miniplates at the lower face of the zygomatic process of maxilla aiming to correct skelatal AOB. Sherwood et al.2002 demonstrated a mean upper molar intrusion of 1.99 mm with intrusive forces continued for 5.5 months in four patients whereas Erverdi et al.2004 reported a mean maxillary molar intrusion of 2.6 mm in 10 patients after a mean of 5.1 months. Yao et al.2005, used a combination of a buccal miniplate and palatal miniscrew in 18 patients and buccal and palatal miniscrews in 4 patients who had overerupted maxillary molars. They reported that the mean intrusion of maxillary first molars was 3 to 4 mm in a mean of 7.6 months.Titanium miniplates implanted in the zygomatic buttress area can serve as absolute anchorage for maxillary molar intrusion. Recent studies suggesting the use skeletal anchors with fixed Edgewise appliances demonstrated that incorporation of skeletal anchors was an excellent alternative to traditional methods and may provide a significant amount of maxillary and/or mandibular molar intrusion. [12],[47],[48],[50]-[53],[61]-[63]

Titanium miniplates are strongly recommended for temporary skeletal anchorage. Both the placement and the removal of the plates are minimally invasive procedures with only slight discomfort to the patient and with no serious side effects. The dense cortical bone of the zygomatic buttress area is an ideal miniplate anchorage site for maxillary molar intrusion. Development of miniature bone anchors have made this clinically feasible and practical. In the literature, a wide range of intrusion forces between 100 and 900 g was suggested for intrusion of maxillary molars, in nongrowing individuals. [45],[47],[50],[52],[64],[65] However, the optimal force to be applied following corticotomy is not clear.[11] Park et al. used 200-300 g of force for intrusion of maxillary posterior teeth with 3 roots, without a corticotomy procedure. After a buccal and palatal corticotomy Akay et al. applied an intrusion force of 200-300 g on each molar and two premolars, considering that with force level less than 200 g, intrusion may be delayed and alveolar bone may heal prematurely. On the other hand, a force level greater than 300 g may stimulate root resorption. It has been suggested that subapical corticotomy procedure decreases the risk of root resoption because the bone blocks are moved with the teeth. [9],[11],[52],[66],[67]

2.4. Corticotomy assisted maxillary impaction with bone anchor miniplates

Patients with skeletal AOB are considered the most difficult to manage because the condition tends to recur after treatment, particularly after single-jaw osteotomy. [32],[68] Patients would almost certainly prefer a less invasive surgical procedure with little or no risk and less discomfort. Additionally, a slow change in the facial appearance may be more acceptable for some patients than a sudden one. Besides local rather than general anesthesia, a decreased operation time, and a shorter duration of hospitalization can reduce costs.[69] A combination of subapical corticotomy and orthodontic treatment supported with bone anchors may be an alternative method for skeletal AOB correction in adult patients who would like to consider a rather rapid treatment option. Recently, surgically assisted orthodontic treatment for severe AOB has been described that has the advantages of corticotomy facilitated orthodontic treatment using orthodontic-skeletal anchorage miniplates. Combined approaches of surgery and orthodontic appliances make it possible to complete orthodontic

treatment in a rapid and predictable manner. Anchor plate or implant appliances allow reliable and expedient orthodontic treatment with minimal orthodontic anchorage loss. It has been suggested that corticotomy procedure decreases the risk of root resoption because the bone blocks are moved with the teeth; this compression osteogenesisis osteoplasty technique is based on the distraction osteogenesis phenomenon. [7]-[11],[57],[66],[71],[72]

Chung et al.used an orthodontic anchor plate system in his clinical study. According to the study, the teeth were moved in a block of bone that was connected to other teeth and anchored via low-density medullary bone and the block was repositioned on an outpatient basis using anchor plates and orthodontic elastics under local anaesthesia. Although this method is also indicated for open-bite patients without anterior–posterior dentofacial problems, the author's new surgical approach decreases the time required for treatment by allowing rapid movement of a block of teeth and bone. It is widely accepted that the utilization of corticotomy before orthodontic treatment allows positively accelerated tooth movement thereby shortening active treatment time with less risk of root resoption and more stable results as well. [9],[11],[52],[66],[67] Akay et al. recently described the efficacy of this technique in combination with a buccal and palatal corticotomy using a bone anchor miniplate system. After one-step corticotomy, the posterior teeth were moved in a block of bone that was connected to other teeth and anchored via low density medullary bone (Figs. 1a-d).

Although corticotomy has become an alternative technique for maxillofacial surgeons, there is no consensus in the literature regarding corticotomy assisted bone anchors application used in maxillary impaction, type of bone anchors used, effects of the new technique on the TMJ, teeth or skeletal structures, the cause and amount of relapse and whether or not overcorrection is necessary. Clinical results of Akay et al. showed that this operation can be performed succesfully under local anesthesia without sedation in cooperative patients.

There are some controversies regarding the type of corticotomy before bone anchor miniplates are inserted.

Subapical corticotomy technique used by Akay et al.: Under local anesthesia the corticotomies are performed prior to implantation of skeletal anchors. The vertical cuts begin 2 to 3 mm above the alveolar crest and extend 5 to 6 mm beyond the tooth apicies. The vertical cuts are made within the compact bone barely reaching the medullary bone on the mesial side of the most anterior tooth and on the distal side of the most posterior tooth to be intruded. A horizontal cut is then made 4 to 5 mm above the apices of the relevant teeth and connected to the 2 vertical cuts. The resection gap is 3 to 4 mm wide to facilitate the intrusion. These cuts are made on both the buccal and palatal sides so that the block of bone is retained only by the medullary bone.

For intrusion of molars, zygoma anchors with three holes (Surgi-Tec, Brugge, Belgium) are adjusted to fit the contour of the bone of each zygomatic process of the maxilla using a plate shaping kit and fixed by three 2.3 mm wide and 7 to 9 mm length miniscrews (Surgi-Tec, Brugge, Belgium). In order to intrude premolars, miniplates with two holes (Surgi-Tec, Brugge, Belgium) are attached 6-7 mm above the roots of relevant teeth and are stabilized by titanium screws (2.3 mm in diameter and 5-7 mm in length (Surgi-Tec, Brugge, Belgium).To

http://dx.doi.org/10.5772/53857

prevent any possible buccal tipping of posterior treeth during intrusion, two titanium screws (2.3 mm in diameter and 13 mm in length, Surgi-Tec, Brugge, Belgium) are implanted in the palatal region between the molars and between the premolars bilaterally, these aided as anchors for applying additional palatal force vectors (Figs. 2-4).

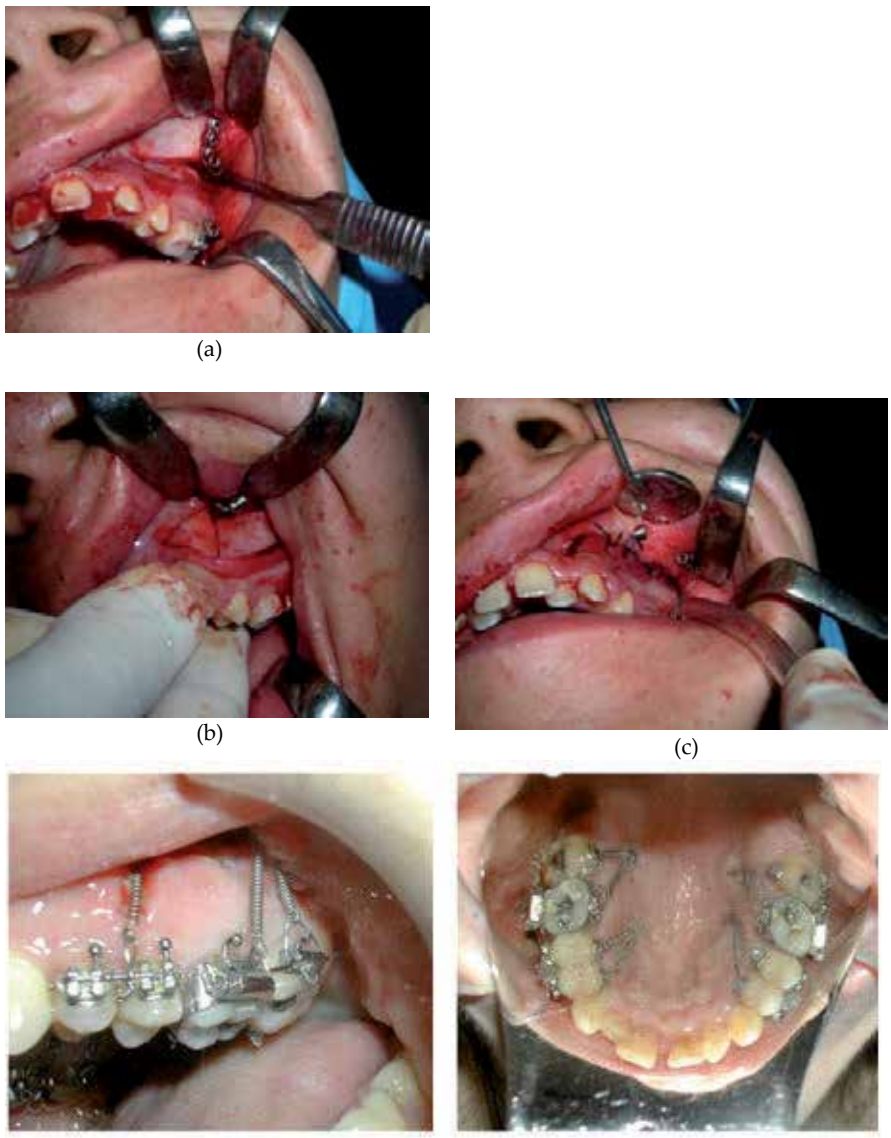

Figure 1. a) Operative photograph showing miniplate bone anchor insertion. (b) The horizontal and vertical corticotomy on the buccal surface. (c) Postoperative clinical appearance showing bone anchor position (d) Postoperative clinical photograph showing intrusive force application (buccal view left, palatal right).

Figure 2. Clinical appearence of screws implanted in the palatal region between the molars and between the premolars bilaterally.

(a)

http://dx.doi.org/10.5772/53857

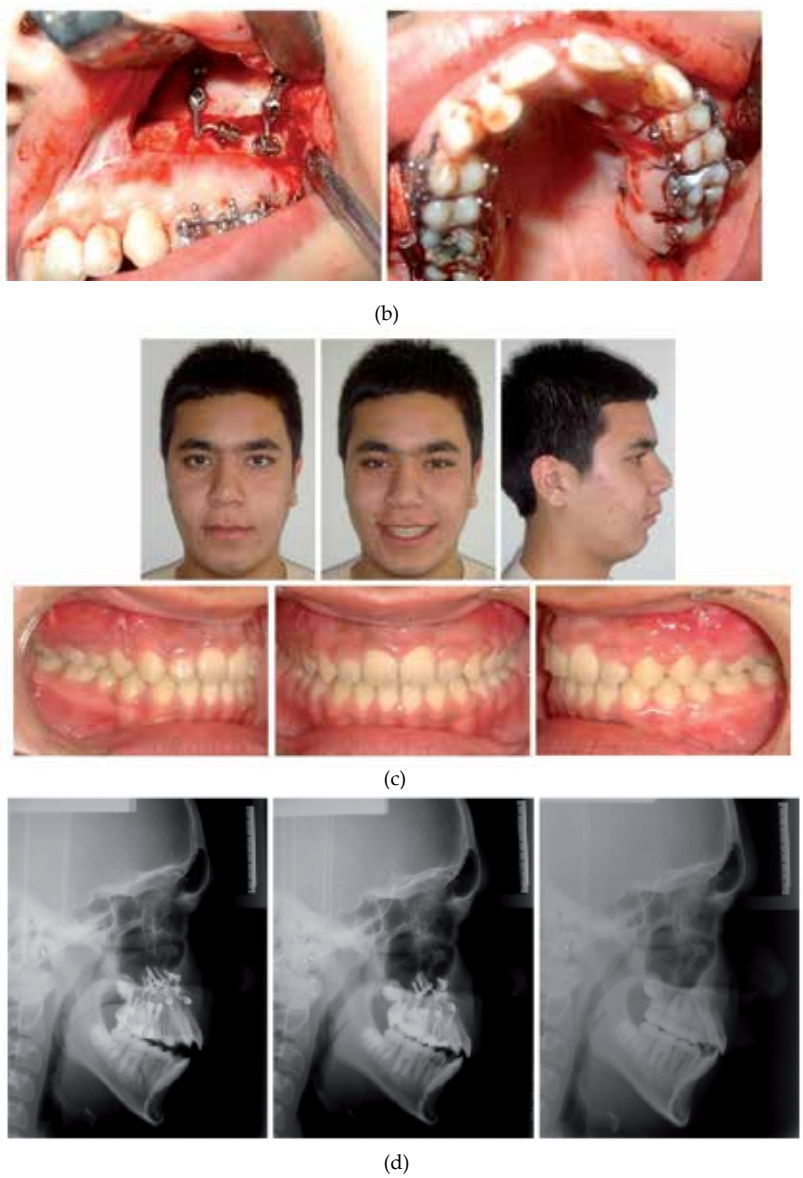

Figure 3. a. Clinical appearence of Case 1 and preoperative intraoral photographs showing severe anterior open bite. b. Intraoperative photograph showing buccal and palatal corticotomy and buccal miniplates and palatal screws insertion. c. Postoperative facial photographs and occlusion after completion of orthodontic treatment. d. Cephalometric views preoperatively, during molar intrusion and after completion of orthodontic treatment.

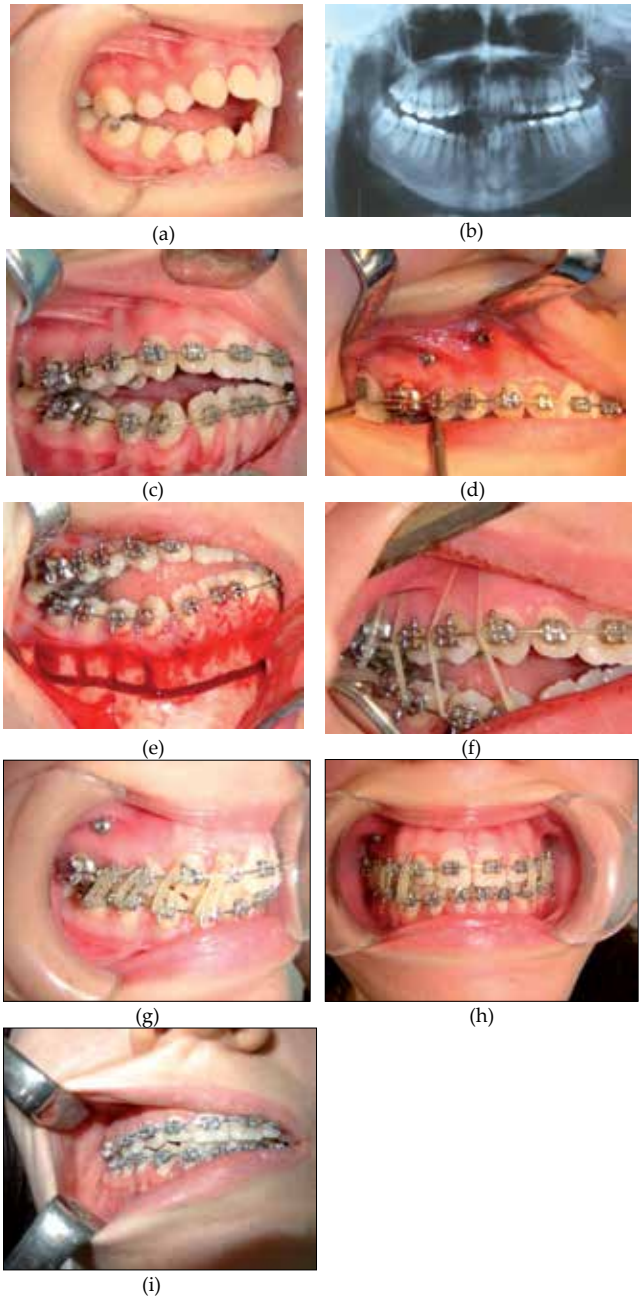

Figure 4. a. Clinical appearance of case 2 and (b) preoperative ortopantomograph showing severe open bite. c. Orthodontic preparation and (d) screw applications on the maxilllary posterior buccal cortex. e. The corticotomy on the mandibular buccal surface and (f) compression force activated using elastics. g. Lateral and (h) anterior clinical photographs during dentoalveolar osteogenesis. i. Postoperative photograph showing occlusion after completion of orthodontic treatment.

http://dx.doi.org/10.5772/53857

According to clinical study by Kanno et al., the two-stage segmental corticotomy technique may be performed under local anaesthesia with intravenous sedation and avoiding the need for conventional orthognathic surgery. Although complex double-jaw surgery is considered a relatively routine intervention for patients with severe anterior open bite, bimaxillary surgery under general anaesthesia may lead to complications necessitating intense postoperative care. [32],[68],[73] None of the postoperative complications, including root resorption, loss of tooth vitality, periodontal problems, pocket formation and segmental malunion, were observed that have been associated with less invasive surgical treatments. [10],[11],[70],[71] Although AOB may be improved by concurrent counterclockwise rotation of the mandible and molar intrusion with skeletal anchor plates, the molar intrusion is limited, the new combined technique allows postoperative adjustment of the bone/teeth segments to the ideal position using a gradual compressive force over a shortened treatment period. [10],[11],[57] An orthodontist performed post-surgical management on an out-patient basis. Reliable control of the corticotomy-facilitated teeth/bone segments has been reported in studies on bone biology and remodelling with compressive induction. [10],[11],[70],[71] According to these authors, no postoperative relapse and complications, such as infectios, dentoalveolar fractures, TMJ symptoms, dental or periodontal problems, loss of tooth vitality, segmental malunion, loss of anchorage and fracture of miniplates and screws were observed during or after corticotomy surgery.

3. Conclusion

AOB is a common problem in orthognathic practice that causes functional and esthetic handicaps on affected patients and it is frequently discussed in orthodontics. Its management varies and it is one of the most challenging disorders to treat. The orthodontic and surgical approach to the treatment of skeletal AOB is still debated, and the results are still controversial. Diagnosis, treatment, and retention can be difficult because this malocclusion has numerous correlated etiologic factors. The earlier this malocclusion is corrected, the better the prognosis will be, especially when the problem is skeletal. Treatment is usually not necessary until permanent teeth erupt (approximately at the age of 6 year). There are different treatment modalities for AOB in the literature. However, many surgeons find it difficult to decide which technique offers better results, and are also uncertain about the factors which might influence their techniques of choice. Many adult patients with AOB are significantly compromised, requiring a multidisciplinary approach to treatment. It is very important to consider surgical and dental concerns during AOB treatment planning. The relapse rate is high with all the techniques in current use. The cause of relapse is multifactorial and one of the main factors is the type of osteotomy used. Corticotomy-facilitated bone anchor applications for treating AOB has become increasingly popular as an alternative to many conventional orthognathic surgical procedures. For patients with mild to severe abnormalities of the AOB, this combined technique has increased the number of treatment alternatives. Although long-term follow-up of occlusion stability is required, the recent evidence suggest that a corticotomy-facilitated compressive force procedure using orthodontic anchor

plates is an effective means of treating patients with severe AOB, however further multicenter studies with a larger population are necessary to precisely evaluate postoperative relapse, other clinical complications and skeletal and dental changes in the long term. Further studies with different designs of titanium miniplates for orthodontic anchorage might be helpful in identifying factors for decreasing the incidence of complications. Improvement of the technique and devices used, with an adjusted protocol, could lead to a reduction in the number of complications.

Acknowledgment

I thank Professor Dr. Aynur Aras, for her orthodontic contributions to the chapter.

Author details

Mehmet Cemal Akay

Ege University, Faculty of Dentistry, Department of Oral and Maxillofacial Surgery, Izmir, Turkey

References

[1] Subtelny, J.D. & Sakuda M., (1964) Open-bite: diagnosis and treatment. *AmJ Orthod* Vol.50, pp:337-358

[2] Tausche, E., Luck O., Harzer W.,(2004) Prevalence of malocclusions in the early mixed dentition and orthodontic treatment need. Eur J Orthod Vol.26, No:3,pp: 237-244

[3] Ermel, T., Hoffmann J.& Alfter G., et al. (1999) Long-term stability of treatment results after upper jaw segmented osteotomy according to Schuchardt for correction of anterior open bite. *J Orofac Orthop Vol.*60, No:4, pp:236-245

[4] Proffit, W.R., Fields H.W. Jr.& Moray L.J., (1998) Prevalence of malocclusion and orthodontic treatment need in the United States: estimates from the NHANES III survey. *Int J Adult Orthodon Orthognath Surg*Vol.13, No:2, pp:97-106

[5] Schudy, F.F.(1965). The rotation of the mandible resulting from growth: itsimplications in orthodontic treatment. *Angle Orthod*Vol.35, pp:36-50

[6] Bell, W.H. & Proffit W.R.,(1980) Open bite. In: Bell WH, Proffit WR, White RP.eds. Surgical Correction of Dentofacial Deformities. Philadelphia, PA:Saunders, pp: 1058-1209

[7] Kole, H., (1959) Surgical operations on the alveolar ridge to correct occlusal abnormalities. *Oral Surg Oral Med Oral Pathol* Vol.12, pp: 515–529

[8] Kerdvongbundit, V., (1990) Corticotomy—facilitated orthodontics. *J Dent Assoc*Thai Vol.40, 284–291

[9] Hwang, H.S.&Lee K.H., (2001) Intrusion of overerupted molars by corticotomy and magnets. *Am J Orthod Dentofacial Orthop*Vol.120, pp:209-216

[10] Kanno, T., Mitsugi1 M.&FurukiY., et al., (2007)Corticotomy and compression osteogenesis in the posterior maxilla for treating severe anterior open bite.*Int J Oral Maxillofac Surg*Vol. 36, pp: 354–357

[11] Akay, M.C., Aras A. & Günbay T., et al., (2010) Enhanced Effect of Combined Treatment with Corticotomy and Skeletal Anchorage in Open-bite Correction. J Oral Maxillofac Surg, Vol.67.No.3, pp: 563-569

[12] Sherwood, K.H., Burch J.G., Thompson W.J.,(2002) Closing anterior open bites by intruding molars with titanium miniplate anchorage. *Am J Orthod Dentofacial Orthop* Vol.122, pp:593-600

[13] Altuna, G.&WoodsideD.G., (1985) Response of the midface to treatment with increased vertical occlusal forces. *Angle Orthod* Vol.55,pp:251-263

[14] Cozza, P., Baccetti T.& Franchi L., et al., (2005) Sucking habits and facial hyper divergency as risk factors for anterior openbite in the mixed dentition. *Am J Orthod Dentofacial Orthop*Vol.128, pp:517-519

[15] Dellinger, E.L.)1986)A clinical assessment of the active vertical corrector, a nonsurgical alternative for skeletal open bite treatment. *Am J Orthod*Vol.89, pp:428-436

[16] Woods, M.G.&Nanda R.S., (1988)Intrusion of Posterior Teeth with Magnets. *The Angle Orthodontis*, Vol. 58, No:2, pp: 136-150

[17] Kalra, V.&Burstone C.J., (1989) Effects of a fixed magnetic appliance on the dentofacial complex. *Am J Orthod Dentofacial Orthop*Vol.95, pp:467-478

[18] Kiliaridis, S., Egermark I.&Thilander B., (1990) Anterior open bite treatment with magnets. *Eur J Orthod*Vol.12, pp:447-457

[19] Barbre, R.E.&Sinclair P.M.,(1991); A cephalometric evaluation of anterior open bite correction with the magnetic active vertical corrector.*Angle Orthod*Vol.61,pp:93-102.

[20] Akkaya,S.&Haydar S., (1996) Post-retention results of spring-loaded posteriorbite-block therapy. *Aust Orthod J*,Vol.14, pp:179-183

[21] Kuster, R &Ingervall B.,(1992) The effect of treatment of skeletal open bite with two types of bite-blocks. *Eur J Orthod*Vol.14, pp:489-499

[22] Iscan, H.N., Akkaya S.&Koralp E., (1992) The effects of the spring-loaded posterior bite- block on the maxillofacial morphology. *Eur J Orthod* Vol.14, pp:54-60

[23] Iscan, H.N.& Sarisoy L.,(1997)Comparison of the effects of passive posterior bite-blocks with different construction bites on the craniofacial and dentoalveolar structures. *Am J Orthod Dentofacial Orthop* Vol.112, pp:171-178

[24] Denison, T.F.,KokichV.G.&ShapiroP.A., (1989) Stability of maxillary surgery in open bite Versus non-open bite malocclusions. *Angle Orthod* Vol.59, pp:5–10

[25] Kloosterman,J., (1985) Koele's osteotomy: A follow-up study. *J MaxillofacSurg* Vol. 13:59–63.

[26] Epker, B.N.&Fish L. (1977) Surgical-orthodontic correction of open-bite deformity. *Am JOrthod*Vol.;71, pp:278–299

[27] Swinnen, K., Politis C. & Willems G., et al.,(2001) Skeletal and dento-alveolar stability after surgical-orthodontic treatment of anterior open bite: a retrospective study. *Eur JOrthod*Vol.23, pp:547-557

[28] Schmidt L.P. & Sailer H., (1991) Long-term results of surgical-orthodontic treatment of open bite deformity by a LeFort-I osteotomy. *Swiss Dent* Vol.27, No:29,pp:31–32

[29] Epker, B.N.(1981) Superior surgical repositioning of the maxilla: long term results.*J Max-Fac Surg*Vol.9, pp: 237-246

[30] Lo, F. & Shapiro P., (1998) Effect of presurgical incisor extrusionon stability of anterior open bite malocclusion treated with orthognathic surgery. *Int JAdult Orthod Orthognath Surg*Vol.13, pp:23–34

[31] Espeland, L., Dowling P.A. & Mobarak .KA., et al., (2008) Three-year stability of open-bite correction by 1-piece maxillary osteotomy. *Am J Orthod Dentofacial Orthop* Vol.134, No:1,pp:60-66

[32] Fischer, K., Von Konow L. & Brattstrom V. (2000)Open bite: stability after bimaxillary surgery—2-year treatment outcomes in58 patients. *Eur J Orthod*Vol. 22, pp:711–718

[33] Hoppenreijs, T.J., van der Linden F.P. & Freihofer H.P., et al., (1996) Occlusal and functional conditions after surgical correction of anterior open bite deformities. *Int J Adult Orthodon Orthognath Surg*Vol.11, No:1,pp:29-39

[34] Hoppenreijs, T.J., Freihofer H.P. & Stoelinga P.J., et al., (1997) Skeletal and dento-alveolar stability of LeFort I intrusion osteotomies and bimaxillary osteotomies in anterior open bite deformities. A retrospective three-centre study. *Int J Oral Maxillofac Surg* Vol.26, pp:161-175

[35] Reyneke, J.P. & Ferretti C., (2007) Anterior openbite correction by LeFort I or bilateral sagittal split osteotomy. *Oral Maxillofac Surg Clin North Am* Vol.19, pp:321–328

[36] Hoppenreijs, T.J., Freihofer H.P. & Stoelinga P.J., et al., (2001) Stability of Orthodontic Maxillofacial surgical treatment of anterior openbite deformities. Ned Tijdschr Tandheelkd Vol.108,pp:173–178

[37] Proffit, W.R., Bailey L.J.& Phillips C, Turvey TA.(2000) Long-term stability of surgical open bite correction by LeFort I osteotomy. *Angle Orthod*Vol.70, pp:112-7

[38] Oliveira, JA & Bloomquist, D.S. (1997)The stability of the use of bilateral sagittal split Osteotomy in the closure of anterior openbite. *Int J Adult Orthodon Orthognath Surg*Vol.12, pp:101–108

[39] Reitzik, M., Barer P.G. & Wainwright W.M., et al., (1990); The surgical treatment of skeletal anterior open-bite deformities with rigid internal fixation in the mandible. *Am J Orthod Dentofacial Orthop* Vol.97, No:1, pp:52-57

[40] Bisase, B., Johnson P. & Stacey M., (2010) Closure of the anterior openbite using mandibular Sagittal split osteotomy. *British J Oral Maxillofac Surg* Vol.48, pp:352–355

[41] Blomqvist, J.E., Ahlborg G. & Isaksson S., et al., (1997)A comparison of skeletal stability after Mandibular advancement and use of two rigid internal fixation techniques. *J Oral Maxillofac Surg.*Vol.55, pp:568–575

[42] Forssell, K., Turwey T.A. & Philips C., et al., (1992)Superior repositioning ofthe maxilla combined with mandibular advancement: mandibular" RiF improves , stability. *Am J Orthod Dentofac Orthop* Vol.102, pp:-342-350

[43] Proffit, W.R., Turvey T.A. & Phillips C., (2007) The hierarchy of stability and predictability in orthognathic surgery with rigid fixation: an update and extension. *Head Face Med*Vol.30, No:3, pp:21

[44] Martin, D.L.,(1998) Transverse stability of multi-segmented Le Fort I expansion procedures (Master's thesis). Dallas: Baylor College of Dentistry

[45] Park, H.S., Kwon T.G. & Jang B.K., et al.,(2004) Treatment of open bite with microscrew implant anchorage. *Am J Orthod Dentofacial Orthop*Vol.126, pp:627-635

[46] Park, H.S., Lee S.K. & Kwon O.W., (2005) Group distal movement of teeth using microscrew implant anchorage. *Am J Orthod Dentofacial Orthop*Vol.75, pp:602-609

[47] Park, H.S., Kwon O.W. & Sung J.H. (2006) Nonextraction treatment of an open bite with micro screw implant anchorage. *Am J Orthod Dentofacial Orthop*Vol.130,pp: 391-402

[48] Yao, C.C., Wu C.B., Wu H.Y., et al., (2005) Maxillary molar intrusion with fixed appliances and mini-implant anchorage studied in three dimensions. *Angle Orthod*Vol.75, pp :754-760

[49] Kuroda, S., Sakai Y. & Tamamura N., et al.,(2007) Treatment of severe anterior open bite with skeletal anchorage in adults: Comparison with orthognathic surgery outcomes. *Am J Orthod Dentofacial Orthop*Vol.132, pp:599-605

[50] Xun, C., Zeng X., & Wang X.,(2007) Microscrew Anchorage in skeletal anterior openbite treatment. *Angle Orthod* Vol. 77,pp:47-56

[51] Erverdi, N., Keles A. & Nanda R., (2004) The use of skeletal anchorage in open bite treatment: a cephalometric evaluation. *Angle Orthod*Vol.74, pp:381-390

[52] Erverdi, N., Usumez S. & Solak A. (2006) New generation open-bite treatment with zygomatic anchorage. *Angle Orthod*Vol.76, pp:519-526

[53] Umemori, M., Sugawara J. & Mitani H, et al., (1999) Skeletal anchorage system for open-bite correction. *Am J Orthod Dentofacial Orthop*Vol.15, pp:166–174

[54] Daimaruya, T., Nagasaka H. & Umemori M., et al., (2001) The influences of molar intrusion on the inferior alveolar neurovascular bundle and root using the skeletal anchorage system in dogs. *Angle Orthod*Vol.71,pp:60-70

[55] De Clerck, H., Geerinckx V. & Siciliano S., (2002) The zygoma anchorage system. *J Clin Orthod*Vol.36,pp:455-459

[56] Miyawaki, S., Koyama I. & Inoue M., et al., (2003) Factors associated with the stability of titanium screws placed in the posterior region for orthodontic anchorage. *Am J Orthod Dentofacial Orthop*Vol.124, pp:373–378

[57] Sugawara, J., Baik U.B. & Umemori M., et al., (2002) Treatment and post-treatment Dentoalveolar changes following intrusion of mandibular molars with application of a skeletal anchorage system (SAS) for open bite correction. *Int J Adult Orthod Orthognath Surg*Vol.17, pp:243-245

[58] Liou, E.J., Pai B.C. & Lin J.C., (2004) Do miniscrews remain stationary under orthodontic forces? *Am J Orthod Dentofacial Orthop*Vol.126,pp:42-47

[59] Chen, C.H., Chang C.S. & Hsieh C.H., et al.,(2006) The use of microimplants in orthodontic anchorage. *J Oral Maxillofac Surg*Vol.64,pp:1209-1213

[60] Choi, B.H., Zhu S.J. & Kim Y.H. (2005) A clinical evaluation of titanium miniplates as anchors for orthodontic treatment. *Am J Orthod Dentofacial Orthop*Vol.128, pp:382-384

[61] Chung, K.R., Kım Y.S. & Linton J.L., et al., (2002) The miniplate with tube for skeletal anchorage. *J Clin Orthod*Vol.36, pp::407-412

[62] Costa, A., Raffini M., & Melsen B., (1998) Miniscrews as orthodontic anchorage:a preliminary report. *Int J Adult Orthod Orthognath Surg Vol.*13,pp:201-209

[63] Seres, L. & Kocsis A., (2009) Open-bite closure by intruding maxillary molars with skeletalanchorage. In: Bell W, Guerrero C. eds. Distraction Osteogenesis of the Facial Skeleton. Hamilton, Ontario, Canada: BCDecker, pp:215-220

[64] Park, Y.C., Lee S.Y & Kim D.H., et al., (2003) Intrusion of posterior teeth using miniscrew implants. *Am J Orthod Dentofacial Orthop*Vol.123, pp:690-694

[65] Carano, A., Siciliani G. & Bowman S.J. (2005) Treatment of skeletal open bite witha device forrapid molar intrusion. *Angle Orthod Vol.*75, pp:736-746

[66] Suya H. Corticotomy in orthodontics. In:Hösl E, Baldauf A, editors. Mechanical and biological basis in orthodontic therapy. Heidelberg: Hüthig, 1991, p.207-226

[67] Mostafa, Y.A., Tawfik K.M., El-Mangoury N.H., (1985) Surgical-orthodontic treatment for overerupted maxillary molars. *J Clin Orthod*Vol.19, pp:350-351

[68] Burford, D. & Noar J.H., (2003) The causes, diagnosis and treatment of anterior open bite. *Dent Update Vol.* 30, pp: 235–241

[69] Proffit, W.R., White R.P. & Sarver D.M.,(2003)Long face problems. In: Proffit WR, White RP, Sarver DM, eds. Contemporary Treatment of Dentofacial Deformity. St Louis, MO:Mosby, pp:464-506

[70] Sen, C., Kocaoglu M. & Eralp L., et al., (2004) Bifocal compression-distraction in the acute treatment of grade IIIopen tibia fractures with bone and soft tissue loss: a report of24 cases.*J Orthop Trauma*Vol. 18, pp: 150–157

[71] Kawakami, T., Nishimoto M. & Matsuda Y., et al., (1996) Histological suture changes following retraction of the maxillary anterior bone segment after corticotomy. *Endod Dent Traumatol* Vol.12, pp:38–43

[72] Chung, K.R., Oh M.Y. & Ko S.J. (2001) Corticotomy-assisted orthodontics. *J Clin Orthod* Vol.35, pp: 331–339

[73] Panula, K., Keski-Nisula L., Keski-Nisula K., et al., (2002) Costs of surgical-orthodontic treatment in community hospital care: an analysis of the different phases of treatment. *Int J Adult Orthod Orthognath Surg*Vol.17,pp:297-306

Section 13

Esthetic Oral and Maxillofacial Surgery

Chapter 30

Office – Based Facial Cosmetic Procedures

Farzin Sarkarat, Behnam Bohluli and
Roozbeh Kahali

Additional information is available at the end of the chapter

http://dx.doi.org/10.5772/53882

1. Introduction

The human face has an important role in a person's identity, communication and self-confidence. Thus, any disfigurement or deformity of the face can causes both functional and social isolation. Facial cosmetic surgery seeks to rejuvenate and restore facial volume loss, static and dynamic rhytids and facial form from the effects of aging, facial muscle movements and gravity. The sudden explosion in recent years of non-surgical rejuvenative techniques is patient-driven. Addressing facial rhytids and undesirable skin changes has required an in-patient stay and a significant period of recovery time. But today's cosmetic patients increasingly desire office-based procedures with minimal recovery time. They are looking for maximal improvement with minimal risks, and cost that will provide them some form of facial rejuvenation and at the same time allow them to get back to work or their social lives as soon as possible. Minimal recovery procedures, offer patients significant esthetic options with minimal or no recovery time and minimal risks. These procedures including the use of injectable fillers, fat transfer, botulinum toxin injection and facial resurfacing techniques are among the most popular and widely performed office procedures. In this chapter, we discuss office-based facial cosmetic procedures, their indications and contraindications, benefits and risks and procedural methods.

2. Injectable fillers

Soft tissue augmentation with the various soft tissue filler materials is particularly performed on patients with minimal to moderate signs of facial aging and because of its non-surgical procedure and minimal downtime, is very popular.

INTECH
open science | open minds

© 2013 Sarkarat et al.; licensee InTech. This is a paper distributed under the terms of the Creative Commons Attribution License (http://creativecommons.org/licenses/by/3.0), which permits unrestricted use, distribution, and reproduction in any medium, provided the original work is properly cited.

2.1. Background

Various materials for facial rejuvenation, such as wax, silicone and animal products have been used. In 1893, Neuber used autologous fat transfer for soft tissue augmentation [1]. Paraffin and vaseline were injected for soft tissue augmentation, just a few years later [2]. In 1940 liquid silicone was injected for cosmesis [3,4]. Bovine collagen injection became popular in 1980 [1].

2.2. Anatomy of the skin

Human skin has several layers. The most superficial layer which acts as a barrier is the epidermis. The deeper layer to epidermis is the dermis and it consists of the papillary dermis and the reticular dermis. The papillary dermis contains a web of primarily type 3 collagen that reaches the epidermis. The reticular dermis is primarily made of type 1 collagen fibers [5]. Elastic fibers are very low and they are responsible for skin resiliency. Ground substance is also a part of dermis and is composed of hyaluronic acids, glycosaminoglycans and proteins and it fills the spaces between other components of dermis [6]. Sub cutis which is seen under the dermis, consists of fat which is responsible for skin volume.The amount of skin collagen decreases with aging, which affects primarily type 1 collagen fibers [5]. In addition to aging, exposure to tobacco smoke and excessive sun can cause a decrease in collagen fiber contents by increasing collagenase levels responsible for wrinkle formation by loss of skin elasticity and turgor [7].

2.3. Filler types

Injectable filler products are syringes containing filler agents. Their needle size is proportional to the filler viscosity; the higher the viscosity, the larger the needle lumen. The smallest appropriate needle size is used to minimize injection pain [8].High viscous agents are generally used for deeper defects and lower viscous fillers are ideal for superficial defects [1]. The depth of the injection is also important. For superficial defects, the needle tip enters the skin very superficially, but for moderate defects, the level of entrance is mid to deep dermis, and for deeper defects, the needle tip enters at the level of dermal-sub cutis junction. After injection, gentle massage is required for evenness of the injected material.An ideal filler agent must meet criteria such as biocompatibity, and be non-antigenic, non-toxic, easy to handle, long-lasting, inexpensive and reversible [8,9].Generally filler agents are categorized into three groups, according to their duration: first, non-permanent fillers, which are short-lasting fillers and they need repeated injections after their resorption. Second, semi-permanent fillers, which last longer but they will undergo some resorption as well. Third, the permanent fillers which may be long lasting with only a single injection.

2.3.1. Non-permanent fillers

2.3.1.1. Collagen replacements

These agents are purified bovine or human collagen and before the advent of Hyaluronic acid filler, was the 'gold standard' filler agents for many years. Bovine collagen was the first

http://dx.doi.org/10.5772/53882

product approved by FDA for soft tissue augmentation [8,10].Because the possibility of allergy reaction, allergy testing was needed. It has been suggested to do the second skin test a month later before augmentation [11,12].Several collagen replacements have been introduced: Zyderm, Zyplast, Cosmoderm and Cosmoplast (INAMED Aesthetics, Irvine, CA). Zyderm and Zyplast are bovine collagen materials.Zyderm got FDA approval in 1981. Zyplast was longer lasting and got FDA approval in 1985. [7]. All of these materials are eventually degraded by inflammatory responses in 4- 5 months [8]. In 2003, Cosmoderm and Cosmoplast were introduced into the market, which are human-derived collagen products. They are derived from cultures of human fibroblast cells [8,13,14]. Because these products are human-derived, there is no need for allergy testing and they are easier to use but their longevity are less than bovine-collagen products [8].

2.3.1.2. Hyaluronic acid

Hyaluronic acid in a part of skin dermis and provides a scaffold for collagen development. Aging decreases the amount of hyaluronic acid and this leads to decreasing of skin hydration and elasticity and formation of rhytids and increased folds [15,16]. It increases the skin hydration and turgor by binding to water molecules and helps to maintain the skin volume and elasticity. It has a uniform structure among various species and this makes it a suitable filler for injection, because there is no need for allergy testing. Its natural molecule is unstable and will degrade in two days after injection [15]. Companies have cross-linked natural hyaluronic acids to increase longevity and cross-linked materials are called hylans [8,17,18]. Hylans are highly viscous materials but their viscosity decreases by applying shear forces to them, in this way their injection is easier [19,20].Hyaluronic acid fillers are injected intradermally, and if the result of injection is not desirable, hyaluronidase can be injected to degrade the filler. Hyaluronic acid products are not combined with anesthetic agents, meaning anesthetic local block injections may be necessary [19].During hyaluronic acid injections, the defect must be treated completely and no over-correction should be performed. The longevity ranges between 6 to 9 months [17].The first hyaluronic acid product introduced into the market was Restylane (Medicis Aesthetics, Inc., Scottsdale, Arizona) and received FDA approval in 2003 [9,11]. It is a partially cross-linked hyaluronic acid and binds water strongly and is derived from Streptococcus cultures [17] and is ideal for mid to deep dermal injections [9,21]. The high degree of cross-linking is responsible for maintain its bulk and its stability which makes it last up to 4 to 6 months depending on the injection site [21]. In contrast to collagen materials which are simply degraded and lose volume, when hyaluronic acids are more degraded, more water molecules are drawn into the filler and this leads to maintaining the volume much longer than collagen fillers [11,19,20].Because Restylane is a human-derived product and there is no need for allergy testing; longevity lasting up to 8 months has been reported [21,22].There are two other formulations of Restylane. Restylane Fine Line has smaller particle size and has lower viscosity which means it is ideal for more superficial dermis injections. Restylane Perlane has larger particle size than Restylane and has higher viscosity and longer-lasting results and is ideal for deep dermal injections [9,17]. Hylaform (Inamed, Santa Barbara, Calif.) and Hylaform Plus were introduced to market and

were approved by the FDA in 2004 [9].Hylaform is derived from rooster combs [20] and has smaller amount of hyaluronic acid and higher degree of cross-linking in comparison to Restylane, which makes its longevity slightly shorter [23]. It also has a small amount of avian protein that may leads to allergic reaction. It is used for mid dermis injections. Hylaform Plus has larger particle size than Hylaform, which makes it ideal for deep dermis injections [9,19].Captique (Allergan, Santa Barbara, Calif.) introduced in 2004 and received FDA approval, is a non-animal-derived hyaluronic acid produced bay bacterial fermentation. It is a cross-linked product and is used for mid to deep dermis injections [9].Juve´derm (Allergan, Inc., Irvine, Calif.) received FDA approval in 2006. It is a bacterially-derived hyaluronic acid homogenous gel rather than a particle suspension like other hyaluronic acid products, and this makes it more biocompatible. It has three different formulations. Juve'derm 24 HV and Juve'derm 30 HV are highly cross-linked and more highly cross-linked products respectively, which are used for deeper dermis injections. Juve'derm 30 is used for superficial dermal injections [9,24].

2.3.1.3. Autogenous fat

First, Neuber used autologous fat for soft-tissue augmentation in 1893. After a period of decline until 1970s, with the advent of liposuction, autologous fat augmentation again became popular [8,25]. The main advantage of autologous fat augmentation is that it is autologous, and there is no risk of allergy reactions. The most important concern about autologous fat augmentation is its unpredictable results and longevity [25,26]. In contrast to other fillers, it requires a harvesting procedure, which increases the procedure time and cost [19].

2.3.1.4. Cymetra

Cymetra (LifeCell Corporation, Branchburg, NJ) is a micronized form of acellular dermal tissue product from human donors called alloderm. It consists of collagen, proteoglycans, and all components of the dermal tissue with the exception of cells. This product forms a web for aggregation of fibroblasts to promote collagen formation. Cymetra is a packaged powder which must be mixed with saline prior to injection. It lasts approximately 3 to 6 months [12].

2.3.2. Semi-permanent fillers

2.3.2.1. Sculptra

Sculptra (Dermik Laboratories, Berwyn, PA) is a synthetic poly-L-lactic acid. It is packaged as a powder and must be mixed with saline at least 2 hours prior to injection. It is injected into subcutaneous tissues and is good for correction of deep and large defects. The filler acts as a web for fibroblast proliferation and collagen production [27].Over-correction of the defect should not be performed and because of its unpredictability, several touch-up sessions 4 to 6 weeks apart may be needed. Sculpra lasts about 18 to 24 months according to the injection site [19].

http://dx.doi.org/10.5772/53882

2.3.2.2. Hydroxyapatite fillers

Radiesse (BioForm Medical, San Mateo, CA) is an FDA approved filler product containing calcium hydroxyapatite spheres. It is a viscous product and is used for deep dermis and subdermal injections [28]. Calcium hydroxyapatite is the mineral component of bones and it promotes no allergy reactions. These spheres maintain volume augmentation by promoting collagen production. So there are two mechanisms for maintaining long-term volume. First is the carrier itself, which degrades after 6 to 8 weeks. However during its degradation, collagen ingrowth occurs at the injection site and maintains the volume [20]. It is seen that hydroxyapatite particles will become encapsulated by a localized fibroblastic reaction, which is helpful in limiting particle migrations and maintaining volume [28]. The injected filler is palpable for about 2 to 3 months until the particles degrade and collagen appears in the site [19]. Radiance FN consists of hydroxyapatite microspheres in a soluble gel vehicle [29]. It does not have FDA approval for cosmetic purposes. This product lasts long, therefore no over-correction should be done [11].

2.3.3. Permanent fillers

2.3.3.1. ArteFill

ArteFill (Artes Medical, San Diego, CA) is an FDA approved product composed of 20% polymethylmethacrylate microspheres and 80% bovine collagen as a delivery agent [30]. Because of bovine collagen, allergy testing is needed. The delivery agent degrades after about 4 months, but microspheres are permanent and become encapsulated by inflammatory reactions, which are responsible for 50 to 70 percent of permanent correction and volume maintenance. Overcorrection should not be performed and the patient may need several touch-up injections spaced 3 to 4 months apart for optimal results [8]. Three to four days following injection, the microspheres are prone to migration and the patient should avoid facial expressions [20].

2.3.3.2. Injectable silicone

Silicone refers to polymers of silicon. Small volumes of Silicone are injected in a grid-like fashion spaced at 1 to 3 mm into the deep dermis called micro-droplet technique. Several injections spaced four weeks apart are required for gaining final results. Encapsulation occurs around particles and is permanent. [31]. Silikon (Alcon Laboratories, Fort Worth, TX) is an injectable silicone for facial augmentation. AdatoSil (Bausch & Lomb, Rochester, NY) is another injectable silicone which is more viscous than Silikon.

2.4. Treatment considerations

When injecting fillers, some considerations should be kept in mind. Before injection a combination of topical, local and regional anesthesia can be administered. Topical anesthetic creams must be applied 20 minutes before the injection of local anesthesia. Usually lidocaine 1% with 1:200,000 epinephrine is used.Filler injection around thin skin of eyes and cheeks

with fine wrinkles is contraindicated; instead resurfacing or chemical peel is needed. Blindness has been reported with the peri-orbital injection of Zyplast and fat due to intravascular injection [32-34], therefore the injection should be very superficial, and without extreme pressure. Allergic reactions occur more in patients with lighter skin. Intramuscular injection of all fillers is contraindicated because the filler dislocation due to muscle movements. Implant dislocation can occur during the first three days after injection, therefore early facial muscle movement should be kept at a minimum. During filler injections the gray of the needle should never be visible through the skin, because in this case the needle is very superficial and the filler is injected intradermally. Acne or surgical/traumatic scars, which are not mobile like wrinkles are the only indications for superficial injections. It has been suggested to cover the lower face during cold weather and exposure to extreme cold. For patients with dark shadowed eyelids, it has been suggested to augment the orbital rim epiperiosteally by scratching the needle tip on the bone. Care has to be taken not to inject into the orbicularis muscle [35]. Regular follow-up is necessary after filler injection. The patient should be visited 1 to 2 weeks after injection for evaluation and touch-up corrective injections if needed in cases of underfill or asymmetry. Touch-up injections also may be needed 1 to 3 months after injection, when the permanent filler has assumed its final volume and shape [9,11,35].

2.5. Injection techniques

There are 4 commonly reported techniques for filler injection: serial puncture, threading, fanning and crosshatching.

2.5.1. Serial Puncture

Serial puncture is often used for the glabella injection, philtral column enhancement, lip augmentation, nasolabial folds and fine wrinkles. In this technique multiple injections are made serially along the area. First, the skin is held taut and pulled slightly away and out from the injection area. Then the needle is inserted up to the appropriate depth. The filler agent is then injected in a small amount. Following that, the needle is removed and reinserted along a particular defect and a new injection is made. The injection sites should be close together, so that the injected filler agents merge into each other [1, 9, 11].

2.5.2. Linear threading

Linear threading is commonly used for lip augmentation, nasolabial fold injection and vermilio-cutaneous border augmentation. In this technique, first, the skin is held taut. Then the full length of the needle is inserted into the defect to create a channel. Then the filler agent is delivered slowly and continuously while withdrawing the needle [8,9,11].

2.5.3. Fanning

Fanning injection technique is ideal for large area augmentation such as deep malar injection. In this technique several linear threading injections are done in a radial fashion by just one entrance point for the needle. After full length insertion of the needle and continuous

http://dx.doi.org/10.5772/53882

injection of the filler while needle withdrawal, just immediately before the needle is withdrawn completely, the direction of the needle is changed in a radial fashion, and new lines are injected the same way. The fanning pattern of lines should be evenly spaced so that the contour is evenly filled and shaped [9,17].

2.5.4. Cross-hatching

Cross-hatching technique is generally used to fill large defect areas, especially oral commissures and perioral area. Cross-hatching involves a series of linear threading injections in a perpendicular fashion to each other. The pattern of lines should be evenly spaced so that the contour is evenly filled and shaped [9,17].

2.6. Indications

2.6.1. Treating the lips

The lips are the most common areas requested for tissue augmentation. Younger patients who have enough lip volume usually only need vermilio-cutaneous border enhancement. In older patients and people with thin lips, volume enhancement is also indicated. Injecting the lips can provide significant discomfort and usually local anesthesia is needed. Bilateral infra-orbital blocks are used during upper lip injection and bilateral mental blocks are performed for the lower lips [36]. Generally, the white roll of Cupid's bow is injected in the intradermal or submucosal plane or both. Linear threading and/or serial puncture techniques are used starting at the oral commissures and proceeding in a lateral to medial direction. By using the non-injecting hand to pinch the lip with the thumb and forefinger, the surgeon can contain the filler to the desired space laterally along the lip. The needle is inserted at the mucocutaneous junction or slightly on the mucosal side and inserted all the way to the hub. Care should be taken to avoid superficial injection in this region, as a light blue hue may become visible. As the needle is withdrawn, the filler is evenly injected into this potential space. Finally, the descending legs of the central M configuration are injected to make sharp angles in the central upper lip. The white roll is also created in the lower lip but is more curvilinear than in the upper lip. The lower lip is injected in a similar manner but without sharp angles. The filler is injected in the potential space just beneath the mucosa across the entire lower lip. Marionette lines are a key element in overall lip enhancement; otherwise, results are destined to be disappointing to both the patient and the physician [9,11].Some patients may desire more vermilion volume and want bigger lips as opposed to simply more-defined lips. Instead of injecting at the vermilion/cutaneous junction, the needle is inserted several millimeters below the cutaneous margin and well into the vermilion. Depending on the desired area to be augmented, the needle is sometimes positioned at the wet/dry line. Again, the needle is inserted to the hub and slowly withdrawn while continuous, steady injection is performed. In this area, the goal is to spread a thin, flat layer to plump the vermilion. The needle can also be placed deeper into the lip when greater volume is required [11].To enhance the philtral columns, the needle is inserted at the vermilion/cutaneous junction in the intradermal plane and directed all the way to the base of the ala. The

skin is then pinched with the non-injecting hand to create a triangle. Less filler is injected near the alar base, with more filler injected toward the vermilion border. By pinching the skin with the non-injecting hand, the injected filler can be formed into the specific shape. Intravascular injection could cause lip necrosis. Notice that the artery lies in the posterior one third of the lip at about the level of the incisal edge of the anterior teeth. This level also corresponds with the vermilion/cutaneous junction on the facial surface of the lip [11,37].

2.6.2. Injecting oral commissures

Aging causes oral commissures to become depressed and also causes a down-turned smile. Oral commissures are where multiple tissue planes and muscles converge together and this makes it difficult to augment; usually a significant amount of filler material is necessary [11]. This area is augmented using the cross-hatching technique. In this area, filler must be injected into multiple layers. The filler must be injected deep to create a base, then the rest of the filler is injected on top of it interadermally [9].

2.6.3. Injecting perioral rhytids

Perioral rhytids which are also call lipstick lines, are usually treated by just white roll and lip augmentations. By doing this, most of the rhytids are fade because of stretching of the skin. If this does not solve the problem, rhytids are treated individually by injecting fine particle-sized filler agents intradermally using linear threading technique. The needle is inserted into the rhytide at the vermilio-cutaneous junction, and the filler is injected while withdrawing the needle [11].

2.6.4. Injecting the nasolabial folds

The nasolabial fold is a normal and natural anatomic structure present even in young people. Aging causes the nasolabial fold to deepen and the treatment goal is to improve it not to make it disappear. This area is treated by injecting filler (Figure 1-A) using serial puncture or linear threading technique or the combination of both. The patient should always be seated upright and the filler is injected into the mid to deep dermis beginning inferiorly and moving superiorly. It is important to be careful not to inject the filler material into the lateral side of the nasolabial fold, which makes the fold look deeper. Using linear threading technique, the needle is inserted into the fold and the filler is injected while withdrawing the needle. For serial puncture technique augmentation, a small amount of filler is injected along the nasolabial fold [9,11].

2.6.5. Glabellar folds

The mobility of the muscles of this area can decrease the longevity of the filler; therefore it is recommended to treat this area with a combination of filler augmentation and botulinum toxin injections; this can increase the longevity as long as nine months. This area is usually treated by injecting the filler using serial puncture technique into the mid-dermis of the wide and deep rhytids, and injecting fine-sized particle filler using linear threading techni-

http://dx.doi.org/10.5772/53882

que into the dermal-epidermal junction of the narrow and fine rhytids. Compressing the supra-trochlear vessel with the non-injecting hand is necessary to prevent intravascular injection of the filler agent [9].

2.6.6. Forehead lines

Linear threading technique is usually used for the treatment of forehead rhytids. Fine-sized particle fillers are used for injection into the dermal-epidermal junction of this area. In the glabellar region, because of the activity of the muscles of this area, combination therapy of this area with botulinum toxin injection is preferred for longevity of the results [9].

2.6.7. Tear trough/malar region

For augmentation of this area, large-sized particle fillers are used for supra-periosteal injection using linear threading or serial puncture technique (Figure 1-B,C). For deep rhytids of this area, filler augmentation alone may not be effective enough and face lift surgery may be needed [9].

Figure 1. Filler agent injection. A, B, C, The injectable filler agent is used for the augmentation of the nasolabial folds, malar region and tear trough region respectively.

2.7. Post – operative care

There are several post-treatment considerations that patients should mind following filler injection. The patients are recommended to use cold compresses for 24 to 48 hour to reduce swelling and the patient should have 30 degrees head elevation for the first 24 hours. Physical activities and facial expressions should be limited immediately after injection to prevent filler migration. They also should avoid excessive sun exposure until erythema and swelling disappears.Aspirin, NSAIDs and blood-thinning medications should be avoided for 24 to 48 hours before and after injection to minimize the bruising which may last 7 to 10 days. Acetaminophen is usually enough for pain control. Oral antihistamines can blunt the histamine release and resultant early edema and may be most useful in patients who develop more edema than usual or redness immediately after injection. Swelling occurs following injection

and usually last for 2 days but it may continue for up to 3 weeks. Oral antihistamines can help to decrease the early edema [1,8,9,17].

2.8. Complications

Pain is common following injection. Using small needles can decrease the injection pain, but viscous filler agents may require larger needles for injection. It is also recommended to use topical or regional anesthesia prior to filler injection to reduce injection discomfort [8,38]. Acetaminophen is also effective to manage post-injection pain, but aspirin or NSAIDs are contra-indicated due to their anticoagulation effects and they should be discontinued prior to injection if possible. Blood-thinning medications are also no exceptional because of their ability to increase the risk of bleeding. Post-operative infections are rare, but people with the history of herpes simplex infections should be treated with prophylactic antiviral agents [1,8]. Granuloma formation is common with alloplastic filler agents and semi-permanent and permanent materials, but it is also reported with using biologic filler agents [39-41]. Granulomas can often be treated with simple excision and incision/drainage. Hyaluronidase is also recommended for hyaluronic acid fillers [40,42]. To prevent complications such as filler palpability and lumps, care should be taken to inject more viscous and large-sized particle filler agents into the deep dermis and less viscous and small-sized particle filler agents more superficially [8].Major complications are rare but serious. Allergic reactions can occur with animal-derived products and allergy testing prior to injection of these materials is required [41,43]. Some other serious complications such as skin necrosis, blindness and death are also reported [1,8,13].

3. Autologous fat transfer

As mentioned previously, ideal fillers should be safe, efficient, easy to use and biocompatible. Autologous fat is the closest to an ideal filler. It is autologous and therefore biocompatible and non-immunogenic, it is available and inexpensive and it can be easily acquired through a minimally invasive procedure [44-47].Fat tissue transfer has become a commonly used technique because of its advantages. One of its disadvantages is its longevity and survival rate, which is very unpredictable and survival rates between 40 to 80 percent have been reported [48-51].

3.1. Background

Autologous fat grafting, first performed in 1890s, and as injectable filler in the 1920s [1,52]. In 1893, Neuber first described the free autologous fat graft transfer for soft tissue augmentation. He transferred tiny parcels of fat into the scar tissues and studied their survival and reported that smaller grafts survived longer with more predictable results. Silex, Axenfeld and Verderame have also separately studied free abdominal fat grafts for treating depressed skin scars as a result of tuberculosis [53].In 1912, Hollander described changes after fat injection in patients with facial lipo-atrophy [54]. In 1926, Miller described the methods for fat

http://dx.doi.org/10.5772/53882

injection via cannulas [52]. Neuhof performed several studies on fat graft survival and reported that with time the graft cells die and are replaced by fibrous tissue [55]. In 1956, Peer mentioned that good blood supply at the recipient site and the need for hemostasis are important factors for graft survival [56]. In 1997, Coleman introduced his modified technique for atraumatic fat harvesting, centrifugation and injection to maximize survival rate [57].

3.2. Indications

The fat transfer technique can be used for the correction of facial asymmetries. Today, it is also used for cosmetic purposes, as a filler for facial rejuvenation.

3.3. Fat harvesting

3.3.1. Donor site

The most common fat harvest sites include the abdominal wall, extremities, trochanteric area, inner knee, dorsocervical fat pad, and flank sites. There is no evidence to claim that which donor site is optimal for far harvesting [50,58]. Rohrich et al. found no difference between the viability of the fat cells harvested from abdomen, flank, thigh and medial knee [58]. According to this, the donor site is usually chosen for ease of access and availability. Lower abdomen and the thighs are the most two easily accessible sites for fat harvesting because these sites do not require patient repositioning and redraping (Figure 2).

3.3.1.1. Lower abdomen

The central part of the abdomen, in the lower and upper region usually contains low contents of fat for harvesting. The harvesting should be kept minimized in the midline to prevent contour irregularity. The cannula should be entered into the lower abdomen while feathered upward and outside into the upper-lateral abdomen. It is important harvest the upper abdomen beyond the lateral limit of the lower abdomen to prevent the occurrence of contour irregularities [59].

3.3.1.2. Inner thigh

Fat can be harvested from inner thigh by performing a stab incision along the inguinal line. Then the cannula is inserted. The shadow of the cannula should not be visible through the skin, which means that the cannula is very superficial and harvesting will lead to contour irregularities. The harvesting should be feathered out toward the anterior thigh to minimize contour changes [59].

3.3.1.3. Anterior thigh

The anterior thigh has variable amounts of fat in different patients and can be accessed through the same access point as for the inner thigh [59].

3.3.1.4. Lateral thigh

The lateral thigh is accessed via a stab incision made laterally along the inguinal line and the harvesting is performed inferio-laterally.

3.3.1.5. Inner knee

This is an easy area to harvest and usually is used only in very thin patients with low fat reserves. A stab incision is made in the medial, inferior and posterior portion of the fat pad and the cannula is inserted in an anterio-superior direction for fat harvesting [59].

3.3.1.6. Buttock

The buttock can be used in the very thin patients with low fat reserves, because everyone has some fat in the buttock. The reason that this area is not commonly used for fat harvesting, is that it needs patient repositioning and redraping. The stab incision should be made along the buttock crease to minimize the scar and pigmentation of the skin [59].

3.3.1.7. Lower back

The lower lateral back is another area for fat harvesting in thin patients. The incision should be made along the lower lateral skin fold to harvest the lower back fat [59].

3.3.1.8. Triceps region

This area is also usually used in thin patients. The stab incision is made on the back of the arm, near the elbow, along the triceps for fat harvesting. Over-harvesting this area can lead to contour irregularities [59].

3.3.2. Local anesthesia

Moor et al. studied the effect of epinephrine and lidocaine on human fat viability and they mentioned that it had no adverse effect on fat cells [60]. Fat harvested with normal saline, lidocaine and epinephrine solution has no significant effect on cell viability [61-65]. Today, most clinicians inject the donor site with local anesthetic. Some surgeons however, do not use any local anesthesia to avoid exposing the fat cells to lidocaine, which has been shown to temporarily restrain adipocyte growth in cell culture [60]. For patients who are under deeper levels of sedation or under full general anesthesia, a mixture of 5 ml 1% lidocaine and 1:100,000 epinephrine with 15 ml plain saline is enough. Half of the mixture is placed deeper to the fat plane, and the other half is distributed superficially into the subcutaneous plane [59].

3.3.3. Aspiration technique

Rohrich et al. harvested fat using traditional liposuction, internal ultrasound-assisted liposuction and external ultrasound-assisted liposuction and they found that internal ultra-

http://dx.doi.org/10.5772/53882

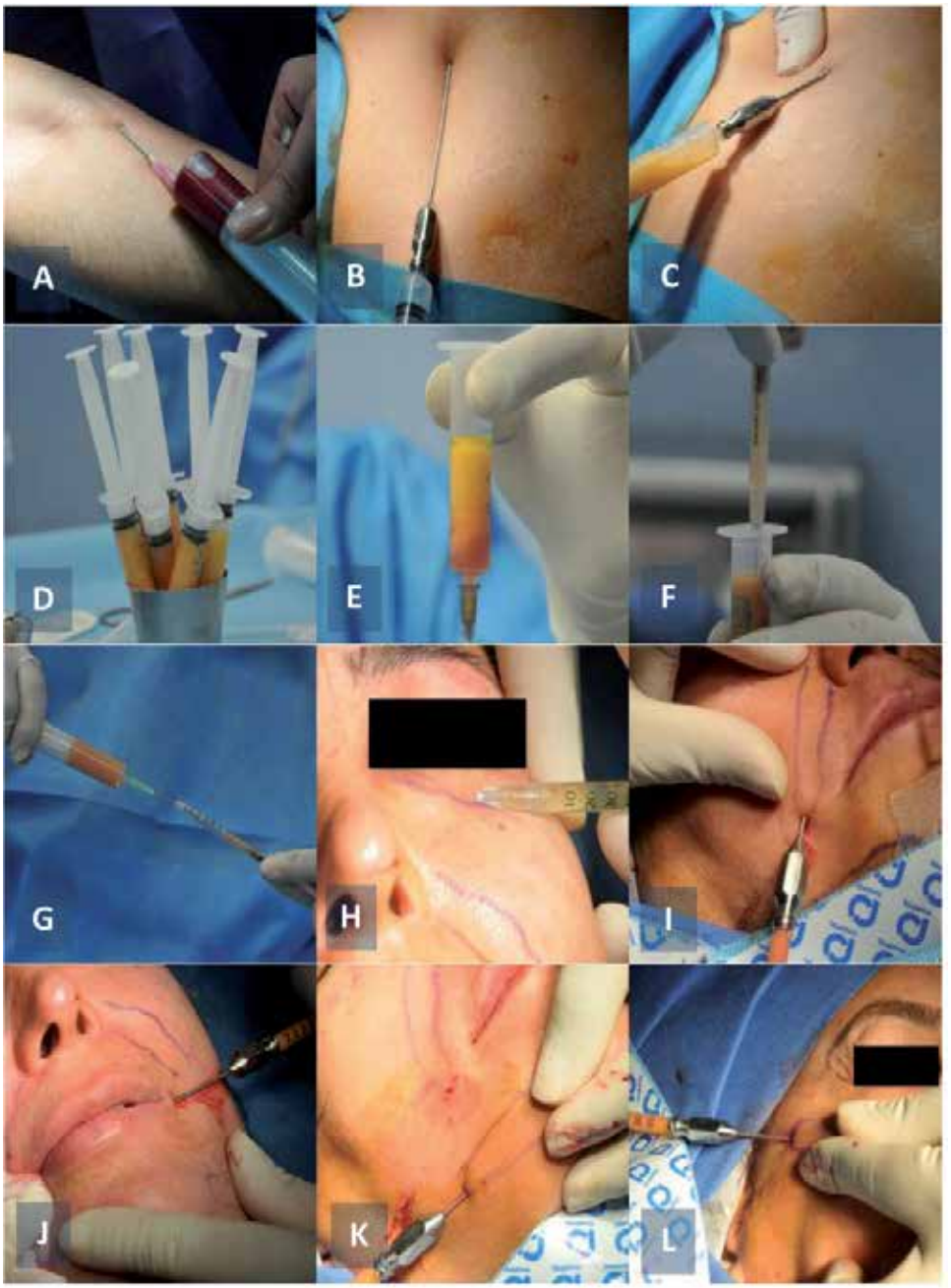

Figure 2. Autologous fat transfer. A, Blood is collected from the patient for PRP preparation. B, The donor site is injected with local anesthetic solution. C, The fat graft is aspirated with a cannla connected to syringe. D, Syringes containing aspirated fat graft. E, Harvested fat graft after washing with lactated Ringer's solution. F, PRP is added to the graft to increase its longevity. G, The fat graft is delivered into the insulin syringe for reinjection. H, The tear trough area is augmented with PRP injection. I, J, K, L, The fat graft is injected into the nasolabial groove, lips, jowl and malar areas respectively.

sound-assisted liposuction can lead to thermal liquefaction of the fat cells [67]. Shiffman and Mirrafati compared various cannulas, needles and suction pressures due their effect on cell viability and found that vacuum pressure more than 700 mmHg can lead to cell damage [68]. Leong et al. found no difference between syringe liposuction and pump-assisted liposuction in cell viability [69].Ozsoy et al. compared the effect of different cannula diameter in the cell viability and found that larger cannula leads to more viable cells [70,71]. Pu et al. compared the effect of fat harvesting using Coleman technique versus liposuction technique in the cell viability and found more viable cells in the Coleman technique group (use of a 3-mm cannula connected to a 10-cc syringe with manual suction via withdrawing the plunger) [72]. Conventional liposuction cause up to 90 percent fat cell rupture [73]. Carpaneda and Ribeiro mentioned the benefits of tiny particle fat grafts aspiration. They mentioned that the graft thickness was inversely proportional to the survival rate of the graft if its thickness exceeds 3mm [74]. As discussed above, syringe aspiration is currently the most popular fat harvesting technique. After the patient has been sedated, prepared and draped, the anesthetic material is injected into the donor site and a 3 mm stab incision is made into a discreet area. A blunt 2-hole cannula attached to a 10 cc syringe in used for harvesting the graft by applying a gentle negative pressure by retracting the syringe plunger [50,64,66,75]. The cannula should be move inside the donor site, in the curetting action fashion to let the small fat parcels enter the cannula [75]. The non-dominant hand should be used to stabilize the fat pad during cannula movement with the palm flat on the skin. After a few passes of the cannula along one straight path, the cannula should be withdrawn but not completely and then the cannula should be redirected to the adjacent linear path.

3.4. Preparation

3.4.1. Centrifugation / washing

Coleman stressed the importance of removing nonviable components of fat aspirate such as oil, blood, and lidocaine by sedimentation or centrifugation at 3000 rpm for 3 minutes [45]. Centrifugation and washing are both aspects of fat graft preparation that have been examined for greatest graft success. Butterwick and others compared centrifuged versus non-centrifuged fat, grafted in hands and found that the centrifuged fat showed more longevity [76,77]. Ferraro et al. evaluated fat grafting in patients using 1300 rpm for 5 minutes showed less resorption in patients grafted [78-80].Rohrich et al found no difference in adipose viability between non-centrifuged fat and fat that underwent the centrifugation (500 g for 2 minutes) and challenged the role of centrifugation [58]. Xie et al. found that the increased centrifugal force, especially greater than 1145 g, significantly decreased the viability of cells [81]. Ramon et al. also found no difference between centrifuged fat grafts in comparison to fat harvested after the use of a sponge to wipe away fluids, debris and oil [82]. Karacalar et al. introduced fat harvesting technique in a bloodless field by using a pneumatic tourniquet to eliminate the need for centrifugation [83]. Washing harvested fat before injection has also been described as a means of enhancing graft survival. Marques et al. used washing technique instead of centrifugation. They used lactated Ringer's solution to wash the harvested fat

http://dx.doi.org/10.5772/53882

and reported increased graft survival rate [84]. It has been stated that washing, will eliminate the inflammatory components from the graft.

3.4.2. Addition of growth factors

The addition of growth factors and nutrients to the harvested fat is not advocated by many. Coleman emphasized to prevent damage to the delicate fat grafts and opposed the addition of chemicals, hormones, drugs, or foreign substances to it [57]. Karacalar et al. [83] and Nordstrom [64] advised not to add any growth factors to the harvested graft. In contrast, some studies proposed the addition if supplements to improve the fat survival [85]. Har-Shai et al. proposed the suspension of the fat graft in a nutrient cell culture supplemented with non-steroidal anabolic hormones, insulin, thyroxin, and growth hormone [86]. Yuksel et al. delivered a relatively continuous dose of insulin, IGF-1, basic fibroblast growth factor (bFGF), or varying combinations to inguinal fat grafts and found increased fat graft weight and volume [87].

3.5. Fat reinjection

It is believed that the method of injection has great effect on the success and longevity of treatment [51,75]. The injected fat should be within 2 mm of an arterial blood supply. This will increase the fat survival and minimize graft necrosis and scar tissue formation [65]. Butterwick and Lack described a technique known as "fat autograft muscle injection" that involved using blunt-tipped cannulas for fat injection directly into the intrinsic facial muscles [88]. Nordstrom described a "spaghetti" fat grafting technique in which 3 mm grafts were laid down in tunnels that did not touch each other [64]. To maximizing the surface area of the graft in contact with blood supply, injecting small particles of fat in multiple tunnels in a fanning fashion has been proposed [53]. this technique involves the creation of multiple tunnels by inserting the cannula through a 2 mm stab incision and then injecting small fat particles during cannula withdrawal (Figure 2). Coleman uses a 17 gauge blunt cannula connected to syringe [45], but the use of a 14 gauge blunt tip or curved micro-cannula is also suggested [47,65,89]. Tzikas used a 16 gauge, bullet-tipped, one-hole cannula for injection [66]. Trepsat used a 0.3 mm cannula attached to a 1 cc syringe for upper lid injection from the deep layer near the bone to a superficial layer just under the orbicularis oculi muscle. He also used a fine 19 gauge cannula on a 1 cc syringe for the lower lid to lay down fat cells in a multi-pass, pre-tunneled areas of the sub-orbicularis oculi fat [90].

3.6. Fat graft survival

Fagrell et al. compared the longevity of the excised fat grafts, fat harvested in a cylinder shape with a 4.5 mm cannula, and fat grafts aspirated with a 2 mm cannula and found 60 percent weight loss in the aspirated group, 1 percent in the excised group and 2 percent in the cylinder group [91]. Coleman believes that stabilization of the graft volume occurs 3 to 4 months after injection and remain constant for 8 to 12 years [75].

3.7. Fat storage

Lidagoster et al. compared fresh, refrigerated (1°C), and frozen (–16° C) fat specimens injected 1 to 2 weeks after harvesting, with a group that underwent immediate injection. They found more inflammation and less viable fat in the stored group in comparison to the immediately injected group [92]. Butterwick et al. compared fat augmentation by using freshly isolated fat with frozen fat (–40°C) and found no difference in the esthetic results between them at 1, 3, and 5months [93]. It has been reported that even brief exposure of the fatty tissue to air causes up to 50 percent of it undergo cytoplasmic lysis [94]. MacRae et al. compared the differential effect of incubation temperature on the fatty tissue viability versus storage at low temperature and they found that viability was superior in the frozen group [95]. Pu et al. found that there was no difference between fat graft mixed with cryoprotective agent and fresh fat graft in terms of cell viability [96].

3.8. Complications

Fat injection has some minor common complications such as edema and bruising with are transient and can be minimized by head elevation, compression and anti-inflammatory medicines. Using blunt cannula can minimize the damage to the underlying tissues and minimize the edema. Infection is rare using sterile technique. A rarely reported esthetic complication is the overgrowth of the graft [97-99]. Liposuction deformities may occur if the donor site is not correctly chosen. The most severe complications reported include fat embolism with subsequent blindness, aphasia, motor restriction and even acute fatal stroke [32,100-103].

4. Botulinum neurotoxin injection

Hyper-dynamic contraction of the facial muscles cause overlying skin folds perpendicular to the direction of the muscles. These facial folds produced by muscle contractions cause dynamic wrinkles. Dynamic wrinkles are best treated with botulinum toxin injections.

4.1. Background

Justinus Kerner, first described a case of lethal food poisoning particular to poorly-prepared meat products. The symptoms were mydriasis, diplopia, gastrointestinal problems and muscle paralysis. He named the causative poison botulism [104,105]. In 1897, Emile van Ermengem, isolated the causative pathogen, later named clostridium botulinum [106-108].Clostridium botulinum is a gram-positive spore-forming bacillus. In 1949, neuromuscular blockade was described as the mechanism of action of the botulinum neurotoxin [109]. In 1973, Scott et al, studied the therapeutic effect of botulinum neurotoxin type-A (BoNT-A) in primates [110]. In the 1989, Alan Scott used this toxin in human to treat strabismus and blepharospasm [111,112]. Oclulinum received FDA approval in 1989 for the treatment of strabismus, blepharospasm and hemi-facial spasm in 1989, which was then

http://dx.doi.org/10.5772/53882

renamed by Allergan (Irvine, USA) company to Botox Medical. In the same period, Ipsen (Slough, UK) introduced Dysport to European markets [113]. In 1992, Carruthers and Carruthers observed the improvement in peri-orbital wrinkles in patient treated for blepharospasm using Botox and they discovered a new treatment indication for BoNT [113]. Since then, many published the cosmetic use of BoNT [113-116]. In 1999 and 2000, Niamtu introduced the cosmetic uses of BoNT in maxillofacial practice [117,118]. Botox Cosmetic, received FDA approval for the glabellar region in 2002 [108].

4.2. Bacteriology

As mentioned earlier, Clostridium Botulinum is an anaerobic, gram-positive, spore-forming bacillus which produces exotoxin. Based on their exotoxin antigenic specificity, eight serotypes of this bacterium are recognized: A, B, C1, C2, D, E, F and G [106,119,120].Neurotoxin strains A, B, E, F and G can affect humans [121,122]. Neurotoxin strains A and B are antigenicity different, but they have similar functions and are commercially available for medical treatments [108,123]. Although these toxins are antigenically different, there are some serum cross-reactivity among them and with tetanus toxin, because of some similar homological sequences [124].

4.3. Structure and toxicity

BoNT is a high-molecular weight protein complex made of 3 different proteins: First, a 150-KDa toxin which itself is composed of a 100-kDa heavy chain and a 50-kDa light chain that are binded together with disulfide non-covalent bonds. This bond disrupts during toxin activation. Second, a non-toxin hemagglutinin protein, which protects the toxin from being destroyed by acids. Third, a non-toxin non-hemagglutinin protein [125]. Clostridium botulinum spores are heat resistant and can survive in inadequately processed foods and can produce toxin, which can cause food-borne botulism [126]. Symptoms of toxin poisoning include weakness, vertigo, diplopia, difficult speaking and swallowing, difficult breathing, muscular weakness and constipation. These usually appear 18 to 36 hours after food poisoning [108].The lethal dose of BoNT in humans is not known exactly, but according to animal studies the LD50 (lethal dose for the death of 50% of population) for a 70 kg human is estimated about 0.09–0.15 mg by intravenous injection, 0.7–0.9 mg by inhalation and 70 mg by oral administration [122,127,128]. The standard vial of BoNT-A has a lethal dose 200 million times less [129].

4.4. Mechanism of action

Facial muscle contractions are responsible for the creation of dynamic facial folds. When the action potential passing along a nerve reaches the nerve ending; it causes acetylcholine vesicles to attach to the nerve ending membrane and then acetylcholine is excreted from the nerve ending membrane, into the neuro-muscular junction. Acetylcholine fuses to the muscle membrane and causes muscle contractions [130].When BoNT is injected on neuromuscular junction, its heavy chain binds to the cell membrane of the nerve ending and creates a passage for the light chain to enter the nerve ending via endocytosis and vesicle formation. These toxin-containing vesicles

inhibit the acetylcholine release from nerve endings. As mentioned earlier acetylcholine is responsible for muscle contraction. Without acetylcholine release, muscle contraction is inhibited and leads to reversible muscle atrophy [131-134]. By doing this the facial muscles which are responsible for facial dynamic folds, will become paralyzed. The paralytic effect of BoNT is dose-dependent. BoNT effects usually take 2 to 3 days to appear after injection and its maximum effects occurring 1 to 2 weeks later and then level off slowly until full nerve recovery within 3 to 6 months following administration [119,135-137]. This nerve blocking effect of BoNT is permanent but the reason for the loss of effect after 3 to 6 months is due to synaptic switching and spouting of new axon terminals and the re-establishment of neuromuscular transmission [108,133,138,139].It is seen that BoNT can diffuse across fascial planes to surrounding muscles, which can cause weakening of the surrounding muscles not injected and creates a flaccid area larger than the area of muscle denervation [140].

4.5. Preparations

There are several BoNT preparations in different countries. The most common available BoNT-A preparations are Botox, Dysport, Xeomin, Prosigne and PurTox. Myobloc is a BoNT-B preparation. The treatment dose varies for each brand of toxin and for different parts of the body.

4.5.1. BoNT-A

Botox was first produced by Allergan Inc, USA in 1968 for the treatment of strabismus which was originally called Oculinum. Then in 1991, Allergan Inc. renamed it Botox [106,110]. Each vial of Botox contains 5 ng (100 U) of air-dried BoNT-A, 500 μg of albumin and 900 μg of sodium chloride [141].

Dysport produced by Ipsen Limited, UK is a cosmetic product mostly available is Europe. Each vial of Dysport contains 12.5 ng (500 U) of air-dried BoNT-A, 125 μg of albumin and 2.5 μg of lactose. It is important to remember that because of different type and strain of bacteria used for the production of Botox and Dysport, their doses are equivalent to each other [141].

Xeomin is a freeze-dried powder of BoNT-A without any accessory proteins produced by Merz Pharmaceuticals GmBH, Germany. Because in contrast to other BoNT-A products, it does not contain additive proteins, it is less immunogenic and can be used when large amounts of BoNT are required to be injected [142,143]. Botox and Xeomin have similar dose-dependent paralytic effects and their diffusion to the surrounding muscles are low [144].

Prosigne is a BoNT-A product made by Lanzhou Biological Products Institute, China, in 1993 and is only available in China [145].

PurTox is a purified BoNT-A which is produced by Mentor Corp, Santa Barbara, CA, USA [143].

4.5.2. BoNT-B

Myobloc is a BoNT-B product made by Solstice Pharmaceuticals, South San Francisco, CA, USA [141]. Myobloc has received FDA approval of the treatment of cervical dystonia and

http://dx.doi.org/10.5772/53882

hemi-facial spasm in 2001, but it does not have cosmetic approval, and its cosmetic use is off-label [146]. It is usually used for cosmetic purposes when the patient shows resistance to BoNT-A products [141,147-150].

Each 0.5 cc vial of Myobloc contains 25 ng (2500 U) of BoNT-B, 1.0 cc vial contains 50 ng (5000 U) and 2.0 cc vial contains 100 ng (10,000 U). Each product is pre-constituted in solution with 0.05% albumin [141]. Several studies have shown that the duration of action of BoNT-B is shorter than BoNT-A, and it has a less predictable diffusion pattern [141,150-152].

4.6. Indications

BoNT is used for cosmetic purposes in the face for dynamic folds and should be injected in areas with dynamic muscle contractions, such as the glabellar region, frontal region and peri-orbital lines (Figure 3). It is also used for the treatment of gummy smile [137,153-155].

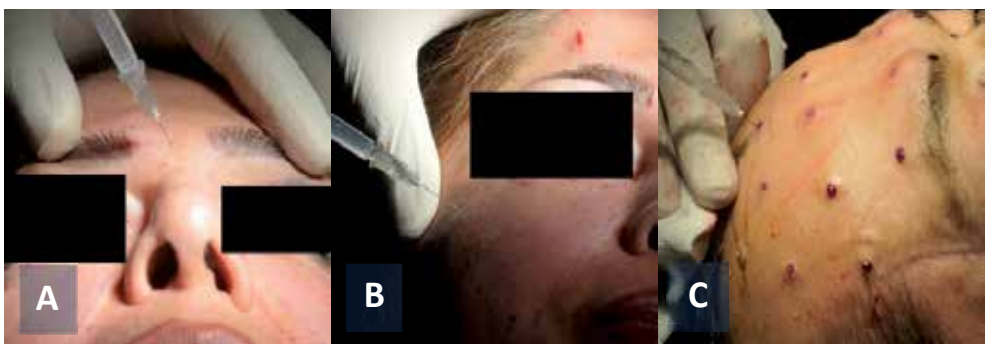

Figure 3. Botulinum neurotoxin injection. A, B, C, The BoNT is injected for the treatment of the glabellar rhytids, peri-orbital rhytids and horizontal forehead rhytids respectively.

4.7. Contra – indications

BoNT should not be injected to pregnant women and nursing mothers. Patients who are taking aminoglycoside antibiotics, quinine, calcium channel blockers, magnesium sulfate, succinylcholine, polymyxin, cyclosporine and cholinesterase inhibitors should not be given BoNT, because these may potentiate the effect of the toxin [122,136,156]. BoNT injection is also contra-indicated in patients with neuromuscular disorders such as myasthenia gravis, amyotrophic lateral sclerosis and Lambert-Eaton syndrome. BoNT administration is also contra-indicated in patients who may have hypersensitivity to BoNT or to any of the additive ingredients [157,158].

4.8. Dosage

There are several brands of BoNT-A products available, but Botox (also known as Botox Cosmetic, Vistabel, and Vistabex) is the most well-known brand. Botox should be kept frozen prior to use. The manufacturer recommends reconstitution of the vial with sterile injectable normal

saline. The reconstituted toxin should be stored at a temperature of 2 to 8 °C and should be injected within 4 to 8 hours [136]. This concern is mostly about its sterility. Although there are some reports that shows no bacterial contamination even after 15 days [159,160].The reconstitution should be done by gently injecting the diluent into the toxin vial to avoid foam formation, which can compromise the effectiveness of the toxin. The volume of the diluent to be injected into the toxin vial differs according to the injection site and desired concentration, the number of units to be injected, the clinician preferences and muscular mass. It is seen that injecting higher doses of toxin in smaller volumes prevent the toxin from diffusing around and keeps the toxin effects localized, but when there is a need to treat a large area such as the forehead injecting higher doses in smaller volumes is hard to do [131,161-163].Male patients usually have larger muscle volumes than female patients and they need more units of toxin to be injected to achieve the same effects as female patients. [162,164,165].

4.9. Injection technique

For maximal effect, the toxin should be injected into the mass of the muscle which causes skin folds, not into the skin folds and depressions. This is achieved by identifying the causative muscle when examining the patient at rest and maximal facial muscle contraction situation [136].The injection technique is simple. The injection should be performed intramuscularly and should avoid superficial intra-dermal injections. Usually there is no need for anesthesia, but if the patient insists topical anesthetics can be used at least 45 minutes before injection [136,166].

4.10. Applications

4.10.1. Glabellar rhytids

Deep vertical folds of the glabellar region which are also called frown lines are best treated by BoNT injection [136]. Corrugator supercilii muscles with contribution from the frontalis, orbicularis and procerus muscles are responsible for these dynamic folds, but with aging, these folds become static. Orbicularis oculi and corrugator supercilii muscle are responsible for adduction of the brows. Depressor supercilii and procerus muscles cause brows to move inferiorly [136,167,168].The physician asks the patient to frown to be able to palpate and identify the muscles. The corrugator supercilii muscle should be injected about 1 cm above the orbital rim in the mid-pupillary line to prevent toxin diffusion into the medial part of the brows which can cause brow ptosis [136,169]. The dermal insertion of the corrugator muscle should also be assessed, because it determines the lateral extent of the toxin injection. Injections just above the brow in the mid-pupillary line must be avoided because they will cause eyelid ptosis [156]. The toxin effects usually last for 3 to 6 months. Male patients may need more doses of toxin due to their greater muscular mass [162,165].

4.10.2. Horizontal forehead rhytids

The frontalis muscle is a large muscle which originates superiorly to the brows. Its contraction causes horizontal forehead folds. These folds can be treated by injecting BoNT into the

http://dx.doi.org/10.5772/53882

frontalis muscle (Figure 4). The injections should be made higher than half way between the hairline and brows, because lower injections can cause brow ptosis. Injections are done at 5 to 7 sites distributed horizontally, 2 to 3 cm above the eyebrows. The injections should extend laterally enough at the lateral part of the brow to prevent the lateral part of the eyebrows being pulled up excessively, but not more than 2 cm lateral to the most lateral part of the eyebrow [136,170-172]. For patients who want elevation of the lateral part of the brows, these areas should not be injected [169,173,174]. The effects of the toxin injection usually last for 4 to 6 months [175]. The side effects, such as headache, eyelid swelling, and brow ptosis, are more common with higher doses, but it has been shown that lower doses are prone to faster relapse [167,176].

Figure 4. BoNT injection into the frontalis muscle.

4.10.3. Brow lift

Contraction of the corrugator supercilii, procerus and the medial portion of the orbicularis oculi causes inferior positioning of the medial part of the brow. Contraction of the lateral portion of the orbicularis oculi is responsible for inferior positioning of the lateral part of the brow. As mentioned earlier, treating the forehead folds can also causes eyebrow elevation [175].Injecting the procerus muscles and the supero-lateral portion of the orbicularis oculi could also causes eyebrow elevation. The injection is done at the temporal fusion line, below the lateral third of the brow and superior to the orbital rim [167,173].

4.10.4. Eyebrow asymmetry

There are some conditions that could cause eyebrow asymmetry, such as unilateral facial nerve palsy, uneven brow lift surgery, hemi-facial paralysis and the patients with binocular vision combined with ipsilateral brow ptosis. In these cases, unilateral injection of the procerus and lateral portion of the orbicularis oculi with the BoNT at the inferiorly positioned eyebrow side, can improve the condition [177].

4.10.5. Peri – orbital rhytids

Contraction of the lateral portion of the orbicularis oculi muscle is responsible for the development of the peri-orbital folds at the lateral side of the orbit, which are also called crow's feet appearance. At first, they are only dynamic folds, but by aging, muscle activity and sun exposure they became static [136,137].

For treating these folds, three injections should be done in the lateral portion of the orbicularis oculi muscle. The injection sites are identified while the patient is smiling. It is important for these injections to be at least 1 cm lateral to the lateral orbital rim, to prevent the diffusion of the toxin into the orbit. The upper most injection site is just below the eyebrow and the lower most site is 1 to 2 cm lower to the first one [178,179]. The injections should be done when the patient is relaxed and not smiling to prevent the diffusion of the toxin into the zygomaticus muscles which causes upper lip ptosis [180]. The injections should be superficial to prevent injecting the toxin into the orbital septum, which could migrate into the ocular muscles and cause diplopia [181].

4.10.6. Hypertrophic pre – tarsal orbicularis

Injecting the pre-tarsal orbicularis muscle with BoNT can widen the palpebral aperture for better esthetic appearance. The injection is done 3 mm inferior to the lower pre-tarsal orbicularis oculi muscle both at rest and while smiling [167,179].

4.10.7. Nasalis muscle

Nasalis muscle has 2 parts. The upper nasalis muscle extends inferio-laterally from the boy dorsum of the nose to the skin lateral to the nose. Its contraction is responsible for the development of fanning-shaped, radial folds of the skin lateral to the nose, which are called "bunny lines". The lower nasalis muscle extends into the lateral portion of the nasal ala and its contraction causes nostrils to dilate. Some patients might be unsatisfied of these contractions, especially because these contractions are usually involuntarily. This condition can be treated easily by injecting toxin into the nasalis muscle. The injection site should be superior to the nasofacial groove and anterio-inferior to the angular vein [167].

4.10.8. Gummy smile

There are several reasons that could make a patient have a gummy smile appearance. One of its reasons is the hyper-functionality of the upper lip elevating muscles. The levator labii superior aleque nasi muscle, the levator labii superior muscle and zygomaticus minor muscles are responsible for the elevation of the upper lip. By injecting the toxin into these muscles, their tonicity can be reduced, which could treat the gummy smile. The toxin is injected lateral to each nostril, which can cause relaxation of the muscles. Weakening of these muscles decreases the amount of lip elevation and decreases the amount of gingival show [137,182].

http://dx.doi.org/10.5772/53882

4.10.9. Perioral rhytides

Contraction of the orbicularis oris muscle is responsible for the creation of the vertical perioral folds. This muscle encircles the mouth and acts as a sphincter which causes the lip to close. For treating these folds, several micro-dose injections into the orbicularis oris are required to weaken this muscle. Usually 6 to 8 injections are required to accomplish this [167].

4.10.10. Mid – facial asymmetry

There are two functional reasons for producing mid-facial asymmetry: the hyper-function of the muscles of one side, or the hypo-function of the muscles of the other side. These patients can be treated by injecting toxin into the zygomaticus muscle, risorius muscle, orbicularis oris and masseter. In patients with hemi-facial spasm, the facial midline moves toward the hyper-functional side, and the muscles of the hyper-functional side should be injected for the correction of the facial midline. In contrast, in patients with facial nerve paresis, the midline moves toward the normal side, the normo-functional side muscles should be injected [167].

4.10.11. Depressor anguli oris

The depressor anguli oris muscle originates from modiolus and extends inferiorly into the inferior border of the mandible. Its contraction is responsible for the inferior movement of the mouth corners. Its hyper-functionality leads to a constant downward turn of the mouth corners and constant bitter appearance. Because of its origin, which is in close proximity to other muscles, it should not be injected directly. It is proposed to inject this muscle at the level of the mandible, at its posterior margin and close to the anterior margin of the masseter muscle [167]. Because the upward motion of the mentalis muscle is also responsible for this bitter appearance, the injection of this muscle is also advisable.

4.10.12. Mental crease

Hyper-functionality of the mentalis muscle can cause a deep mental crease and unesthetic appearance. Weakening this muscle can softens this crease. To accomplish this, toxin should be injected into this muscle, at each side of the midline and below the mental crease. Injections above the mental crease can cause perioral muscle weakness [167].

4.10.13. Lower facial asymmetry

Lower facial asymmetry is usually seen in patients with hypo-functionality of one side of the face. This hypo-functionality can be due to a surgical procedure, traumatic cutting of the orbicularis oris or risorius muscles, congenital or acquired weakness of the depressor anguli oris muscle, or due to innervation problem. To treat this condition, the risorius muscle at the normo-functional side should be injected with BoNT [167].

4.10.14. Masseteric hypertrophy

Para-functional habits such as bruxism and clenching can lead to hypertrophic masseter muscles, which can cause an unesthetic appearance. This condition can be treated by injecting BoNT into the masseter muscle to reduce its tonicity and its mass, but the para-functional habits should be first treated prior to BoNT injection. Each masseter is injected in 3 to 6 sites in the thickest part of the muscle at the inferior mandibular border, with low dose toxin. The muscle can be palpated by asking the patient to clench the teeth together [137,167,183].

4.11. Complications

Side effects of cosmetic BoNT are usually mild and transient. The most common side effects are pain, swelling, bruising and ecchymosis. Some transient rare systemic side effects such as weakness, fatigue, nausea, pruritus and flu-like syndromes have also been reported [184]. These symptoms are usually transient and there is no need for any treatment. It is important to use the smallest needle possible to minimize the bruising. Injection into the superficial vessels, should also be avoided and the toxin should be injected into the subcutaneous layer. Bruising usually resolves in 10 days [136]. The headache usually occurs on the first day after injection, and it is not due to BoNT. The studies have shown that it is related to the injection procedure itself [185]. Injecting the lower half of the frontalis muscle can cause brow ptosis. This also can occur by diffusion of the BoNT into the lower half of the frontalis muscle. For the patients with pre-existing brow ptosis, the frontalis injections should be avoided. It has been suggested that the higher the volume, the greater the diffusion [186]. Transient upper eyelid ptosis may occur in the first two days after glabellar BoNT injections. This is due to toxin diffusion through the orbital septum, to the upper eyelid levator muscle. This condition usually resolves itself over the first week [184]. This can be prevented by using high dose, low volume BoNT no closer than 1 cm above the orbital rim. It has been seen that Dysport diffuses more than Botox. It is also important to apply digital pressure on the orbital rim during injection to prevent the toxin diffusion. Ectropion has seen in patients with pre-existing lower eyelid laxity, due to weakening the orbicularis oculi muscle with BoNT [187].

When treating crow's feet, the inferior limit for injection should be superior to the zygomatic arch and the injections should not be deep, because this can cause zygomaticus major palsy, which is responsible for the lip drop after BoNT injection [181]. It has been suggested that the patient could exhibit an allergic reaction to the albumin that is used in the preparation of some BoNT products. The estimated lethal dose of BoNT-A for humans has been estimated about 2500 to 3000 U, which shows that it has a large margin of safety [106].

5. Facial resurfacing

Facial resurfacing refers to procedures that change the texture and appearance of skin. Photoaging and acne scarring are the most common reasons for which patients seek resurfacing procedures. Facial resurfacing includes mechanical derm-abrasion in 1905 by Kromayer, the Baker-

http://dx.doi.org/10.5772/53882

Gordon phenol peel in the 1960s, the laser principle of selective photo-thermolysis by Anderson and Parrish in 1983, and medium-depth chemical peeling by Brody in 1986 [188-191].

5.1. Anatomy of the skin

The skin consists of two layers: the epidermis and the dermis. The epidermis is composed of epithelium which is subdivided into 5 layers: the stratum corneum, stratum lucidum, stratum granulosum, stratum spinosum, and the stratum basale. The stratum corneum is the most superficial layer and composed of layers of keratinocyte. The stratum lucidum contains a dense layer of keratin filaments that provides additional structural support. The stratum granulosum contains lipid granules which makes the skin waterproof. The stratum spinosum is characterized by the presence of multiple spiny cells containing cytokeratin. The stratum basale generates the cells composing all other layers of the epidermis. The dermis consists of two layers: the papillary layer and the reticular layer. The papillary layer contains the capillary network and nerve endings. The reticular layer contains densely packed collagen, hair follicles and sweat and sebaceous glands [192].

5.2. Patient selection

The ideal patient for a resurfacing procedure is one who has signs of photo-aging or acne scarring. Acne scarring is classified as ice pick, rolling, or boxcar type. Ablative resurfacing is most effective for boxcar and rolling types [193].The first step is to review the patient's medical history and lifestyle. Patients with a history of keloids, smoking, extensive undermining of skin and facelift surgery in the last 6 months, history of skin radiation, HSV infections and diabetes are relative contra-indications to ablative procedures [194]. Chronic smoking causes micro-vascular damage and leads to poor tissue healing. Smoking should be stopped as least a month prior to peeling and 6 months after that [195].Excessive sun exposure could also lead to poor healing and the patient should be advised to avoid sun exposure after peeling [195]. Birth control pills, exogenous estrogens and photosensitizing drugs are to be avoided because of risks of hyperpigmentation. The patients who are planning to become pregnant within the first 6 months after treatment are not good candidates for peeling due to the elevation of the estrogen level. [196]. Isotretinoin use is an absolute contraindication to resurfacing procedures, because it prevents re-epithelialization and should be stopped 12 to 24 months prior to the treatment [195].

5.3. Pretreatment skin preparation

Skin preparation and protection is essential prior to resurfacing treatments. These pretreatment considerations contain preconditioning the skin with topical retinoids, alpha-hydroxy acids, and hydroquinones and photo-protection after ablative procedures [197]. Sunscreens should be started to prevent pre-peel burns or tanning to decrease melanocyte activity 3 months prior to the peel in combination with minimal sun exposure [195]. Tretinoin aids in re-epithelialization and leads to increased melanin distribution [198]. It also has synergistic qualities with trichloroacetic acid [199,200]. It is recommended to use topical tretinoin (0.05% to 0.1%) 6 to 12 weeks prior to the treatment.

Hydroquinone is used prior to treatment in patients with melisma, dyschromia, lentigines, hyper-pigmentation and Fitzpatrick skin types 3 to 6 [201]. Hydroquinone decreases melanin production by blocking tyrosinase and preventing the conversion of tyrosine to L-Dopa. Hydroquinone (4 to 8%) should be started 4 to 6 weeks prior to treatment. Antiviral prophylaxis should be started prior to the procedure. Acyclovir should be used 400 mg 3 times a day, or 500 mg twice a day, 3 days prior to the treatment and should be continued for at least 7 days after. For those patients with a positive history of active HSV infections, Valacyclovir 1 g should be used [202,203]. A study by Manuskiatti et al. showed a bacterial infection rate of 4% in patients pretreated with prophylactic antibiotic undergoing laser resurfacing and 8% in the untreated group [204,205]. The use of appropriate prophylactic antibiotic especially against staphylococcal and streptococcal species is recommended, but it is controversial.

It is necessary for the patient to avoid waxing, derm-abrasion, and electrolysis for 3 to 4 weeks prior to peeling. These procedures could affect the uniform depth penetration of the peeling agents [195].

5.4. Resurfacing procedures

Resurfacing procedures are classified into ablative or non-ablative procedures. Ablative procedures are those which wound the skin to the level of the dermis. These procedures include chemical peels, derm-abrasion, laser ablation and plasma resurfacing techniques. They can cause a wound to the level of superficial, medium or deep. The disadvantages of these techniques are increased risk of infection, erythema, post-inflammatory hyperpigmentation, cicatrical scarring and hypopigmentation.The non-ablative procedures include lasers and radiofrequency techniques. Their advantages are minimal recovery time and low risk of scarring.

5.4.1. Chemical peel resurfacing

5.4.1.1. Introduction

Chemical resurfacing is the application of chemical agents to produce a controlled partial thickness wound of the skin. Chemical peeling agents are categorized as superficial, medium, and deep based on the depth of ablation. Superficial peels cause exfoliation of the epidermis, medium peels cause epidermal to papillary dermal peel and deep peels penetrate to the reticular dermis [202,206].

5.4.1.2. Indications

Chemical peel indications are rhytides, irregular pigmentation, scars, actinic keratosis, and acne [207]. Superficial peels are effective for treating the mild actinic damage, superficial lentigines, mild rhytids, post-inflammatory erythema and mild photo-aging. The superficial peels result in epidermal sloughing and mild inflammatory response in the superficial papillary dermis. They are safely used in all Fitzpatrick skin types. Medium depth peels are used

http://dx.doi.org/10.5772/53882

for dyschromia from dermal melasma moderate photo-aging and mild to moderate acne scars. They result in sloughing of the epidermis, variable necrosis of the papillary dermis and some inflammation within the reticular dermis. These peels should not be used for Fitzpatrick skin type 5 and 6, due to the risk of dyschromia [208]. Deep peels are used for advanced photo-aging and deep rhytids of the perioral and peri-orbital. They create sloughing of the epidermis and papillary dermis and cause inflammation within the reticular dermis. They should be used for patients with Fitzpatrick skin type 1 and 2 [195].

5.4.1.3. Superficial chemical peels

Alpha-hydroxy acids (AHAs) are usually used for superficial peeling. They include glycolic acid and lactic acid. They are time-dependent and after achieving appropriate peeling depth, they should be neutralized by using ammonium salts, sodium bicarbonate or sodium hydroxide to prevent excessive peeling and healing problems [201,206]. These agents affect epidermis and the superficial dermis by creating the loss of cohesion of keratinocytes.Salicylic acid is a beta-hydroxy acid agent which exfoliates the dead skin cells. This agent is usually used in combination with other agents [209]. Jessner's solution consists of 14 g salicylic acid, 14 g lactic acid, 14 g resorcinol in 100 ml of 95% ethanol [202,203]. Its penetration depth is coat-dependent. By applying one to three coats the penetrations depth is limited to the stratum corneum. However, by applying 5 to 10 coats, the penetration depth extends to the basal cell layer.The desired end point of superficial agents can be determined by erythema and light peeling of the epidermis. A clear frost indicates penetration into the dermis and should be avoided [210,211]. Mild stinging occurs during the procedure which resolves within a few minutes. Mild erythema subsides within a few hours. Desquamation begins 2 to 3 days later and can last 1 to 4 days. Usually 3 to 5 treatment sessions spaced 2 to 4 weeks apart are necessary for desirable results.

5.4.1.4. Medium-depth peels

Trichloroacetic acid (TCA) is the gold standard agent used for medium-depth peeling. At concentrations up to 35%, it acts as a medium depth peel, but at concentrations of 45% to 50%, acts as a deep peel [212]. The risk of scarring increases at concentrations more than 50% [213]. It does not require neutralization. To lessen the risk of scarring, and to achieve the appropriate peeling depth, Coleman combined glycolic acid with 35% TCA [214].When combining Jessner's or 70% glycolic acid with 35% TCA, Jessner's solution or glycolic acid is applied first within 60 seconds until a faint frosting with mild erythema appears. The glycolic acid needs to be neutralized [215]. Jessner's solution is allowed to dry. Then the 35% TCA is applied [216]. Jessner's solution destroys the epidermis and allows for even application of the TCA solution to achieve a deeper penetration [217].The endpoint is a white frost that usually appears within 30 to 120 seconds of application. If it does not appear, additional passes are done. It is important to wait at least 120 seconds between passes for the frost to appear. The face develops erythema for the first 12 hours, followed by moderate edema. Full re-epithelialization usually occurs 7 to 10 days after the treatment. The treatment can be repeated as necessary on a yearly basis.

5.4.1.5. Deep phenol peels

The Baker-Gordon solution is usually used for deep peels. It consists of 3ml of 88% phenol, 3 drops of 2.1% Croton oil, 8 drops of Septisol and 2ml of water [218,219]. This mixture should be freshly prepared for each treatment. It was thought that, phenol was responsible for deep peeling, but Hetter showed that in fact, croton oil was responsible for peeling [220]. Because the potential toxic effects of phenol to the cardiac system, and its ability for causing cardiac arrhythmias, the blood pressure, pulse oximetry and ECG monitoring should be used during treatment. This complication is more common when more than half of the face is treated in less than 30 minutes [207,221]. It also can cause renal toxicity and irreversible hypopigmentation and should be used only in patients with Fitzpatrick skin type 1 and 2 [195]. The deep phenol peel is applied within 15 minutes interval between each esthetic unit. The endpoint of the application is a white frost followed by a deep brawny erythema. The skin should be protected and moistened during the first 4 days after the treatment [218]. Full re-epithelialization occurs in 10 to 14 days. The erythema typically resolves within 2 months [194].

5.4.1.6. Technique

Prior to application of peeling agent, preparing the skin is needed. A soap free cleanser is used to remove makeups. Then the skin is vigorously cleaned by rubbing alcohol or acetone for about 3 minutes to degrease the skin and reach a brisk erythema [195]. 10 to 15 mg oral diazepam is usually administered preoperatively to reduce the patient's anxiety. The intravenous catheter is placed and fluid therapy is administered for the patient to regain intravascular volume. Usually a sedative dose of propofol is administered. Then the supra-orbital, infra-orbital and mental nerves are blocked by lidocaine 2% without epinephrine, to prevent the accumulation of the phenol agent. The peeling agent is uniformly applied to each esthetic unit (forehead, left cheek, right cheek, nose, chin, and peri-orbital area) with a cotton gauze. The cotton tipped applicator is used for the application of phenol peels. The upper eyelids should be left untreated. The peel should be performed to within 3 mm of the cilliary line of the lower eyelids [194,195]. If phenol is used, 10 to 15 minutes must be allowed between each unit peeled for the phenol clearance. The peel should be carried into the hairline and over the vermillion border to prevent lines of demarcation. The adjacent esthetic units should also be peeled adequately by overlapping the adjacent application areas for the same reason.

5.4.1.7. Post-operative care

The burning sense may last up to 8 hours after the treatment. An oral narcotic analgesic is usually prescribed to minimize the burning sensation. When the frost subsides and only erythema persists, a bland emollient should be applied to the skin to ease the skin monitoring on a daily basis. A day after treatment, the patient is advised to apply cream, 3 times a day.In the first 12 weeks after the treatment, sun exposure can result in hyperpigmentation and the patient should be advised to avoid excessive sun exposure. The sunscreens should also be avoided for the first 6 weeks because of their para-amino-benzoic acid formulation

http://dx.doi.org/10.5772/53882

which could lead to irritation and erythema [195].The healing process occurs in five stages. The first stage is inflammation which increases during the first 12 hours. At the second stage, the epidermis becomes leathery and separates from the dermis and sloughs. The third stage is desquamation and will occur over 4 to 7 days. At the fourth stage, re-epithelialization begins within 48 to 72 hours and lasts about 7 to 10 days. Finally, fibroplasia begins within the first week and continues for 3 to 4 months after the treatment [222].

5.4.1.8. Complications

As mentioned earlier, cardiac arrhythmias is one of the complications of the phenol peels. When it happens, the patient will develop a supraventricular tachycardia within 30 minutes, which if continues can lead to ventricular tachycardia and atrial fibrillations. Once arrhythmia is noted, the treatment should be stopped and adequate fluid therapy should be administered until the patient's rhythm is back to normal [195]. If re-epithelialization does not occur within 10 days after the treatment, those areas should be checked for the presence of infection [223]. Bacterial infection can delay wound healing and lead to scarring. In this case antibacterial therapy should be initiated. HSV infection can also occur and must be treated with 1g Valacyclovir, 3 times a day for 10 days [195].The erythema may last longer than expected in patients with sensitive skin. The administration of topical 2.5% hydrocortisone lotions are recommended in these patients [195]. Post-inflammatory hyperpigmentation might occur in patients with Fitzpatrick skin type 3 to 6. For eliminating this, the use of glycolic acid lotion or the combination of 0.05% retinoic acid, 8% hydroquinone and hydrocortisone cream is recommended [224]. Hypopigmentation may occur by using phenol peels and this complication is irreversible.

5.4.2. Dermabrasion

5.4.2.1. Introduction

Derm-abrasion is a skin-resurfacing technique that has been around since the 1930s. It has been used for treating wrinkles, scars, and the precancerous lesions [195,225]. By performing the derm-abrasion, the epidermis and partial of the underlying dermis is mechanically removed. Usually two passes are performed, in directions perpendicular to each other. Kromeyer was the first performed derm-abrasion using a rotating burr or rasp after freezing the skin with carbon dioxide snow or ether spray [189]. Derm-abrasion is ideally performed in the face because of its high density of skin appendages. The neck has thinner dermis and less skin appendages and should be avoided because of the risk of hypertrophic scarring and depigmentation occurrence [195].

5.4.2.2. Indications and contra-indications

Its indications are similar to superficial chemical peels including boxcar and rolling acne scars, rhinophyma, scarring, tattoos, lentigines, facial rhytides, fine perioral rhytids, seborrheic or actinic keratosis and removal of benign and premalignant epidermal growths. Indications for full thickness derm-abrasion include deep peri-orbital or perioral rhytids [226]. It

is also used to revise scars from trauma, skin grafts, and surgical incisions [225].Treating hypertrophic scars and keloids with derm-abrasion is contra-indicated due to the lack of adnexal structures for epidermal regeneration. Use of isotretinoin within the recent year is also contra-indicated, due to their healing impairment which leads to keloid formation [195]. Derm-abrasion during active acne is a relative contra-indication due to its increased risk of postoperative infection [225].

5.4.2.3. Dermabraders and devices

Many dermabraders are available for skin resurfacing, which are connected to a pneumatic or electric motor rotating handpiece. The desired speed for derm-abrasion is approximately 12,000 to 15,000 revolutions per minute. The most common dermabraders include diamond burs, serrated wheels, or wire brushes [194]. During the procedure, they must be kept in contact with the skin with a gentle pressure [225]. One of the alternative equipments that is useful for derm-abrasion of the scars is sterile, medium grade (220 grit) silicone carbide sandpaper that is wrapped around gauze [227].

5.4.2.4. Pre-operative considerations

Any patient with the history of isotretinoin use during the past year is prone to hypertrophic scarring or keloid formation due to their delayed wound healing and should not undergo the procedure. Those patients who use blood-thinners and having bleeding disorders are prone to post-operative hyperpigmentation and if medically possible, their medication should be discontinued. Patients with the history of HSV may require prophylactic antiviral medications [225]. Patients with darker skin shades are more prone to irreversible hypopigmentation and are not good candidates for derm-abrasion [225]. Administration of tretinoin, a few weeks before the procedure is recommended due to its promotion of the wound healing process.

5.4.2.5. Pre-operative considerations

Derm-abrasion is usually performed under local anesthesia, but sedation or general anesthesia could also be used due to the patient's pain tolerance and patient's overall health [225]. The patient's ECG, blood pressure and pulse oximetry should be monitored if sedation or general anesthesia is used. Regional nerve blocks are administered adequately before the procedure [194]. The appropriate diamond bur or wire brush is chosen and attached to the handpiece. Diamond burs abrade the skin slowly and are more conservative than wire brushes and serrated wheels [195]. The affected area is stabilized with the non-dominant hand, and the handpiece is held at a right angle to the skin with the dominant hand and by applying slow and even pressure to the skin, the dermabrader is moved across the skin in a back and forth motion for diamond burs and in one-direction motion for wire brushes [228].When performing the derm-abrasion, the epidermal layer is removed first. Then by entering the papillary dermis, pinpoint bleedings from small capillary loops occur. By the disappearance of the pinpoint bleedings, the upper reticular dermis has been reached and small parallel strands of whitish-yellow colored collagen

http://dx.doi.org/10.5772/53882

are visualized. The papillary-reticular junction is the ideal endpoint of derm-abrasion and is identified by increased, confluent bleeding. No more penetration into the reticular dermis should be performed, due to the risk of scar formation [194,195,225]. The periphery of the area should be slightly feathered to blend treated and untreated areas. Protection from blood exposure and aerosolized particles must be considered during the treatment, especially for patients with a history of HIV or hepatitis.

5.4.2.6. Post-operative care

Immediately following the procedure, saline-soaked gauze moistened with dilute epinephrine is placed on the wounds to achieve hemostasis [225]. Post-operatively, the wound is cleansed daily with a wet gauze and petroleum-based products are applied several times a day to moistens the wound and keep it from crusting. Re-epithelialization time is approximately 5 to 7 days and is fully completed by day 10 to 14 [225]. Erythema is common and can persist for 2 to 3 months [195]. Patients should avoid excessive sun exposure for 6 to 12 months following the procedure to avoid hyperpigmentation. Hydroquinone can be used to treat post-inflammatory hyperpigmentation following the procedure.

5.4.2.7. Complications

Common complications include dyspigmentation, hypertrophic scarring, acne eruptions, and postoperative infections [195]. If the derm-abrasion is performed beyond the reticular dermal layer, it can lead to abnormal scarring, hypertrophic scars and keloids. It is also seen in patients with collagen disorders. Excessive sun exposure can lead to post-inflammatory hyperpigmentation and hydroquinone is administered to treat this condition [225]. Patients with Fitzpatrick skin types 3 to 6 are prone to irreversible hypopigmentation. Patients with active acne are more prone to infection. Infections should be treated with antibiotic and antiviral therapy. Patients with a history of HSV should be treated with prophylactic antivirals. The formation of Milia is a small white keratin-filled cyst, which might occur following derm-abrasion. Its treatment is incision and drainage, if it does not resolve spontaneously [225].

5.4.3. Microdermabrasion

Microdermabrasion is a less invasive and less painful skin resurfacing technique that uses an inert substance such as aluminum oxide or sodium chloride crystals to remove the superficial layers of the skin. It is used for the treatment of photo-damaged skin, hyperpigmentation, superficial rhytides, stretch marks, scars, acne scarring, and enlarged pores [225,229]. It can be performed on all Fitzpatrick skin types. The operator uses a device that mobilizes a fine stream of ablative substances on the skin with the intent of disrupting the stratum corneum. The cells at the most superficial layer are dislodged and simultaneously removed by vacuum suction [225].Side effects include mild erythema and tenderness. These complications are treated with non-steroidal anti-inflammatory drugs.

5.4.4. Laser resurfacing

5.4.4.1. Introduction

Lasers are generally categorized into 2 groups: ablative and non-ablative lasers. Ablative lasers are mostly used for the treatment of photo-damaged skins, deep rhytides, solar elastoses, uncontrollable acne, acne scars, telangectasias and actinic keratosis. These lasers ablate the outer layers of the skin to the level of the dermis and cause thermal damage to the dermis resulting in collagen remodeling and new collagen formation which leads to smoother and firmer skin [195,230,231]. Patients with Fitzpatrick skin type 1 to 4 are good candidates for ablative laser resurfacing [232]. Non-ablative laser are less aggressive and cause minimal injury to the epidermis and their side effects are less than ablative lasers. They are effective in the treatment of mild to severe rhytides [195,230]. Fractional photo-thermolysis (FP) is a laser technology with decreased side effects and improved recovery time. FP therapy is done by delivering an ablative or non-ablative laser to the skin to create micro-thermal zones of injury. By this method the normal skin is preserved and treated area is decreased which leads to improved recovery time [195,233]. The surrounding unaffected follicular units and fibroblasts are responsible for rapid collagen remodeling and faster recovery time. FP is effective in the treatment of moderate to severe acne scarring and moderate to severe photo-aging [234].

5.4.4.2. Ablative lasers

Ablative lasers include the CO_2 and Er:YAG devices. They cause homogenous tissue vaporization with surrounding residual thermal damage after selective absorption by intracellular water in the epidermis. Er:YAG lasers have 10 times more absorption by water than CO_2 lasers and are able to ablate the tissue more precisely with less residual thermal damage [235,236].The CO_2 laser was first introduced in the 1980s and initially it created excessive thermal damage and lead to excessive scar formation [195]. CO_2 laser works by delivering energy at 10,600 nm wavelength. For decreasing the residual thermal damage, the CO_2 in delivered at 5 J/cm2 in less than 1 millisecond, which creates 20 to 30 μm of tissue ablation and 40 to 120 μm of residual thermal damage [194]. CO_2 lasers are able to ablate tissue of the reticular dermis, because of their hemostatic effects.The Er:YAG laser is an alternative for CO_2 with minimized risks. The laser beam is delivered at 2940 nm wavelength, which is close to the peak absorption of water at 3000 nm. This would limit the penetration depth and residual thermal damage and leads to less side effects and decreased healing time [195]. The energy is delivered at 0.6 to 5 J/cm2 which causes 4 μm of tissue ablation and 10 to 40 μm of residual thermal damage. The ablation depth of Er:YAG lasers are limited to the papillary dermis due to their inability to coagulate blood vessels. Bleeding absorbs the laser light and prevents further penetration. Usually these two lasers are combined to minimize the side effects and maximize the benefits. After the treatment with CO_2 laser, Er:YAG is used to remove the coagulated tissues produced by the CO_2 laser, which leads to shorter healing time [195].

5.4.4.3. Non-ablative lasers

Non-ablative lasers are introduced to minimize the tissue damage and healing time. These lasers are divided into three groups: infrared lasers, intense pulsed light (IPL) and visible lasers. Infrared lasers which are mostly used include the 1320 nm Nd:YAG laser, 1450 nm

http://dx.doi.org/10.5772/53882

diode and 1540 nm erbium-doped phosphate glass laser. These lasers only target the dermis to promote new collagen formation and rhytides improvement, and are not effective on patients with epidermal changes and severe photo-damaged skin [195].IPL devices are not real lasers, but they have a wide spectrum range 550 to 1200 nm. They are able to target the hemoglobin, melanin and blood vessels, so they are used for the treatment of dyschromias, telangiectasias, increased vascularity and pigment changes from photo-damaged skin [195].

Visible lasers include pulsed dye laser (PDL) and pulsed 532 nm potassium titanyl phosphate laser (KTP). These lasers target the blood vessels and superficial pigmentations and are used to treat telangiectasias in photo-damaged skins [195].Lasers have been combined with radiofrequency (RF) devices to increase the depth of the lasers penetration without increasing the ablative effects. This increased penetration depth leads to increased skin tightening and increased new collagen formation [230,237].

5.4.4.4. Indications

The indications for CO_2 and Er:YAG lasers include acne scarring and moderate to severe photo-aging. CO_2 laser is also used for the treatment of the skin laxity and deep rhytides [238,239].

5.4.4.5. Technique

Each esthetic unit is treated individually. The borders of the units should be feathered to prevent demarcation lines. Overlapping of the pulses is not recommended with CO_2 resurfacing [240]. Lasers could cause damage to the hair follicles, therefore protecting the hair is mandatory.The endpoint of the treatment is a visible smoothing of the rhytids. This is achieved by 1 to 4 passes with CO_2 laser. Between the passes, the epidermal debris should be wiped away. When using Er:YAG laser, because of its minimal residual thermal damage, the overlapping of the pulses is possible and wiping the debris between the passes is not necessary [241].

5.4.4.6. Post-operative care

The postoperative care is similar to that described for deep phenol peels. The full re-epithelialization time with laser resurfacing is approximately 7 to 10 days which is faster than with deep phenol peeling. Usually the erythema, edema and crusting occur during the first 3 to 4 days.

5.4.4.7. Complications

The erythema usually lasts from 1 to 4 months and may even last up to a year. The post-inflammatory hyperpigmentation is common in patients with Fitzpatrick skin type 3 to 6. Hydroquinone and retinoic acid may be used to treat this hyperpigmentation and the patients should be advised to avoid excessive sun exposure. Hypopigmentation may occur 6 to 12 months after the treatment which is irreversible. In the case of infection, antimicrobial agents should be used for treatment. Acne eruptions are common in patients with a history of acne and should be treated with standard acne treatments. The risk for scarring is higher with CO_2 resurfacing compared with erbium resurfacing because of the higher residual thermal damage.

5.4.5. Fractional photo-thermolysis (FP)

The traditional ablative and non-ablative lasers create a homogenous zone of thermal damage, but FP creates multiple microsomal thermal zones surrounded by normal skin with intact stratum corneum, which results in a shorter healing time [242]. Each microsomal thermal zone consists of an area within 70 to 100 μm wide and 250 to 800 μm deep containing necrotic debris of epidermal and dermal tissues [243]. Ablative FP devices include CO_2, Er:YAG and yttrium scandium gallium garnet and they have high affinity for water molecules. Non-ablative FP devices include 1550 nm erbium doped laser, 1540 nm pulsed device, 1440 nm neodymium yttrium aluminum garnet and 1410 nm erbium fiber devices. These devices have moderate affinity for water.

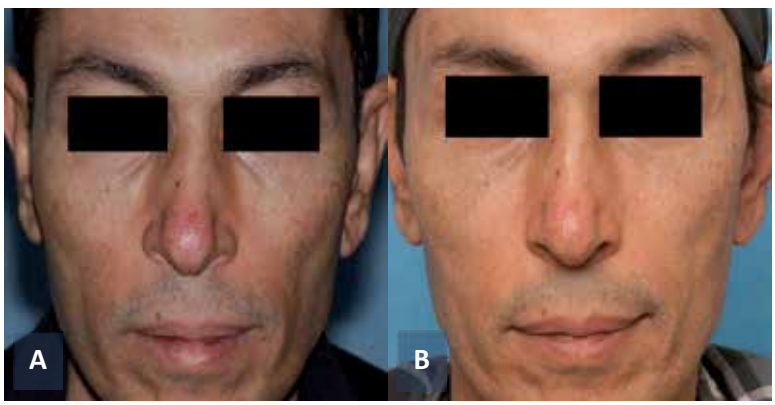

Figure 5. A patient treated with fat and PRP injection. A, Before treatment. B, After treatment.

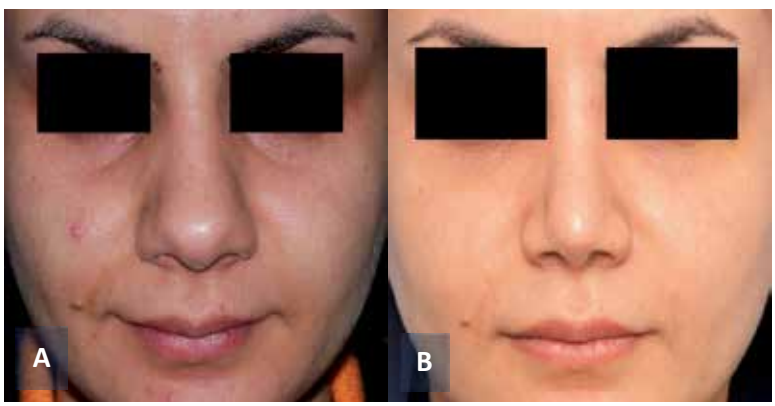

Figure 6. A patient treated with fat and PRP injection. A, Before treatment. B, After treatment.

http://dx.doi.org/10.5772/53882

6. Conclusion

The field of cosmetic surgery continues to be a rapidly changing and expanding one. Use of minimally invasive facial rejuvenation continues to increase. With the understanding of the changes that take place in aging and contribute to photo-damaged skin, technologic advances have become more science-based. Patients are aware of these changes and it has become more important than ever for surgeons to be knowledgeable about available procedures, limitations, techniques, risks and complications. Figures 5 and 6 show two patients before and after treatment.

Author details

Farzin Sarkarat, Behnam Bohluli and Roozbeh Kahali

Department of Oral and Maxillofacial Surgery, Bouali Hospital, Islamic Azad University of Medical Sciences, Tehran, Iran

References

[1] Donald W. Buck II, Murad Alam, John YS Kim: Injectable fillers for facial rejuvenation: a review. Journal of Plastic, Reconstructive & Aesthetic Surgery (2009) 62, 11-18.

[2] Glicenstein J. The First ''Fillers'', vaseline and paraffin. From miracle to disaster. Ann Chir Plast Esthet 2007;52: 157-61.

[3] Narins RS, Beer K. Liquid injectable silicone: a review of its history, immunology, technical considerations, complications, and potential. Plast Reconstr Surg 2006;118:77S-84S.

[4] Rapaport MJ, Vinnik C, Zarem H. Injectable silicone: cause of facial nodules, cellulites, ulceration and migration. Aesthetic Plast Surg 1996;20:267-76.

[5] Arndt KA, LeBoit PE, Robinson JK, et al: What is normal skin? In White CR Jr, Bigby M, Sangueza OP (eds): Cutaneous Medicine and Surgery: An Integrated Program in Dermatology, vol. 1. Philadelphia, W.B. Saunders Company, 1996 pp 3-45

[6] Uitto J, Bernstein EF, McGrath JA. The dermis, in White CR Jr, Bigby M, Sangueza OP (eds): Cutaneous Medicine and Surgery: An Integrated Program in Dermatology, vol. 1. Philadelphia, W.B. Saunders Company, 1996 pp 857-881

[7] Bauman L: CosmoDerm/CosmoPlast (human bioengineered collagen) for the aging face. Facial Plast Surg 20:125-128, 2004

[8] Murray CA, Zloty D, Warshawski L. The Evolution of soft tissue fillers in clinical practice. Dermatol Clin 2005;23:343-63.

[9] Rod J. Rohrich, Ashkan Ghavami, Melissa A. Crosby: The Role of Hyaluronic Acid Fillers (Restylane) in Facial Cosmetic Surgery: Review and Technical Considerations. Plast. Reconstr. Surg. 120 (Suppl.): 41S-54S, 2007.

[10] Keefe J, Wauk L, Chu S, et al. Clinical use of injectable bovine collagen: a decade of experience. Clin Mater 1992;9(3-4):155-62.

[11] Joseph Niamtu III: New Lip and Wrinkle Fillers. Oral Maxillofacial Surg Clin N Am 17 (2005) 17 – 28.

[12] Owens JM: Soft tissue implants and fillers. Otolaryngol Clin N Am 38:361-369, 2005

[13] Eppley BL, Dadvand B. Injectable soft-tissue fillers: clinical overview. Plast Reconstr Surg 2006;118:98e-106e.

[14] Baumann L, Kaufman J, Saghari S. Collagen fillers. Dermatol Ther 2006;19:134-40.

[15] Devore, D. P., Hughes, E., and Scott, J. B. Effectiveness of injectable filler materials for smoothing wrinkle lines and depressed scars. Med. Prog. Technol. 20: 243, 1994.

[16] Longas, M. O., Russell, C. S., and He, X. Y. Evidence for structural changes in dermatan sulfate and hyaluronic acid with aging. Carbohydr. Res. 159: 127, 1987.

[17] Matarasso SL, Carruthers JD, Jewell ML, et al. Consensus recommendations for soft-tissue augmentation with nonanimal stabilized hyaluronic acid (Restylane). Plast Reconstr Surg 2006;117:3S-33S.

[18] Monheit GD, Coleman KM. Hyaluronic acid fillers. Dermatol Ther 2006;19:141-50.

[19] Raghu S. Athre: Facial filler agents. Operative Techniques in Otolaryngology (2007) 18, 243-247

[20] Narins RS, Bowman PH: Injectable skin fillers. Clin Plast Surg 32: 151-162, 2005

[21] Narins, R. S. A randomized, double-blind, multicenter comparison of the efficacy and tolerability of Restylane versus Zyplast for the correction of nasolabial folds. Dermatol. Surg. 29: 588, 2003.

[22] Lemperle G, Morhenn VV, Charrier U. Human histology and persistence of various injectable filler substances for soft tissue augmentation. Aesthetic Plast Surg 2003;27(5):354 –66.

[23] Rao J, Chi GC, Goldman MP: Clinical comparison between two hyaluronic acid-derived fillers in the treatment of nasolabial folds: Hylaform versus restylane. Dermatol Surg 31:1587-1590, 2005

[24] Baumann L: Replacing dermal constituents lost through aging with dermal fillers. Semin Cutan Med Surg 23:160-166, 2004

[25] Kaufman MR, Miller TA, Huang C, et al. Autologous fat transfer for facial recontouring: is there science behind the art? Plast Reconstr Surg 2007;119:2287-96.

[26] Kanchwala SK, Holloway L, Bucky LP. Reliable soft tissue augmentation.Aclinical comparisonof injectable soft-tissue fillers for facial-volume augmentation. Ann Plast Surg 2005;55:30-5.

[27] Vleggaar D: Facial volumetric correction with injectable poly-L-lactic acid. Dermatol Surg 2005;31:1511-1518

[28] Flaharty P: Radiance. Facial Plast Surg 20:165-169, 2004

[29] Sklar JA, Soren M, White MD. Radiance FN: a new soft tissue filler. Derm Surg 2004;30(5):764– 8.

[30] Thaler MP, Ubogy ZI: Artecoll: The Arizona experience and lessons learned. Dermatol Surg 31:1566-1576, 2005

[31] Duffy DM: Liquid silicone for soft tissue augmentation. Dermatol Surg 31:1530-1541, 2005

[32] Teimourian B. Blindness following fat injections. Plast Reconstr Surg 1988;82(2):361.

[33] Castillo GD. Management of blindness in the practice of cosmetic surgery. Otolaryngol Head Neck Surg 1989;100(6):559–62.

[34] Egido JA, Arroyo R, Marcos A, et al. Middle cerebral artery embolism and unilateral visual loss after autologous fat injection into the glabellar area. Stroke 1993; 24:615–6.

[35] Gottfried Lemperle, Peter P. Rullan, Nelly Gauthier-Hazan: Avoiding and Treating Dermal Filler Complications. Plast. Reconstr. Surg. 118 (Suppl.): 92S-107S, 2006.

[36] Niamtu J. Local anesthetic blocks of the head and neck for cosmetic facial surgery. Part I. A review of basic sensory neuroanatomy. Cosmet Dermatol 2004;17: 515–22.

[37] Larrabee WF, Makielski KH, editors. Surgical anatomy of the face. New York, NY: Raven Press; 1993.

[38] Lam SM, Azizzadeh B, Graivier M. Injectable poly-L-Lactic acid (Sculptra): technical considerations in soft-tissue contouring. Plast Reconstr Surg 2006;118:55S-e63S.

[39] Brody HJ: Use of hyaluronidase in the treatment of granulomatous acid reactions or unwanted hyaluronic acid placement. Dermatol Surg 31:893-897, 2005

[40] Hönig JF, Brink U, Korabiowski M: Severe granulomatous allergic tissue reaction after hyaluronic acid injection in the treatment of facial lines and its surgical correction. J Craniofac Surg 14:197-200, 2003

[41] Johl SS, Burgett RA. Dermal filler agents: a practical review. Curr Opin Ophthalmol 2006;17:471-9.

[42] Honig JF, Brink U, Korabiowski M. Severe granulomatous allergic tissue reaction after hyaluronic acid injection in the treatment of facial lines and its surgical correction. J Craniofac Surg 2003;14:197-200.

[43] Zimmerman U, Clerici TJ. The Histologic aspects of fillers complications. Semin Cutan Med Surg 2004;23:241-50.

[44] Bucky LP, Kanchwala SK. The role of autologous fat and alternative fillers in the aging face. Plast Reconstr Surg. 2007; 120(Suppl):89S–97S.

[45] Coleman SR. Structural fat grafts: The ideal filler? Clin Plast Surg. 2001;28:111–119.

[46] Kanchwala SK, Holloway L, Bucky LP. Reliable soft tissue augmentation: A clinical comparison of injectable soft-tissue fillers for facial-volume augmentation. Ann Plast Surg. 2005; 55:30–35; discussion 35.

[47] Guerrerosantos J: Long-term outcome of autologous fat transplantation in aesthetic facial recontouring: sixteen years of experience with 1936 cases. Clin Plast Surg 27: 515e543, 2000

[48] Zocchi ML, Zuliani F. Bicompartmental breast lipostructuring. Aesthetic Plast Surg. 2008;32:313–328.

[49] Wolf GA, Gallego S, Patro´n AS, et al. Magnetic resonance imaging assessment of gluteal fat grafts. Aesthetic Plast Surg. 2006;30:460–468.

[50] Kaufman MR, Miller TA, Huang C, Roostaien J, Wasson KL, Ashley RK, et al: Autologous fat transfer for facial recontouring: is there science behind the art? Plast Reconstr Surg 119: 2287-2296, 2007

[51] Calabria R: Fat grafting: fact or fiction? Aesthet Surg J 25: 55, 2005

[52] Miller, C. G. Cannula Implants and Review of Implantation Techniques in Esthetic Surgery. Chicago: Oak Press, 1926.

[53] Matthew R. Kaufman, Timothy A. Miller, Catherine Huang, Jason Roostaien, Kristy L. Wasson, Rebekah K. Ashley, James P. Bradley: Autologous Fat Transfer for Facial Recontouring: Is There Science behind the Art? Plast. Reconstr. Surg. 119: 2287-2296, 2007.

[54] R. Guijarro-Martínez, L. Miragall Alba, M. Marqués Mateo, M. Puche Torres, J. Vicente Pascual Gil: Autologous fat transfer to the cranio-maxillofacial region: Updates and controversies. Journal of Cranio-Maxillo-Facial Surgery 39 (2011) 359-363.

[55] Neuhof, H. The Transplantation of Tissues. New York: D. Appleton & Co., 1923.

[56] Peer, L. A. The neglected free fat graft. Plast. Reconstr. Surg. 18: 233, 1956.

[57] Coleman, S. R. Facial recontouring with lipostructure. Clin. Plast. Surg. 24: 347, 1997.

[58] Rohrich RJ, Sorokin ES, Brown SA: In search of improved fat transfer viability: a quantitative analysis of the role of centrifugation and harvest site. Plast Reconstr Surg 113: 391-395, 2004

[59] Samuel M. Lam, Robert A. Glasgold, Mark J. Glasgold: Fat Harvesting Techniques for Facial Fat Transfer. Facial Plast Surg 2010;26:356–361.

[60] Moore JH Jr, Kolaczynski JW, Morales LM, et al. Viability of fat obtained by syringe suction lipectomy: Effects of local anesthesia with lidocaine. Aesthetic Plast Surg. 1995;19:335–339.

[61] Shoshani O, Berger J, Fodor L, et al. The effect of lidocaine and adrenaline on the viability of injected adipose tissue: An experimental study in nude mice. J Drugs Dermatol. 2005;4: 311–316.

[62] Kim IH, Yang JD, Lee DG, Chung HY, Cho BC. Evaluation of centrifugation technique and effect of epinephrine on fat cell viability in autologous fat injection. Aesthet Surg J. 2009; 29:35–39.

[63] Keck M, Janke J, Ueberreiter K. Viability of preadipocytes in vitro: The influence of local anesthetics and pH. Dermatol Surg. 2009;35:1251–1257.

[64] Nordstrom, R. E. A. "Spaghetti" fat grafting: A new technique. Plast. Reconstr. Surg. 99: 917, 1997.

[65] Cook, T., Nakra, T., Shorr, N., et al. Facial recontouring with autogenous fat. Facial Plast. Surg. 20: 145, 2004.

[66] Tzikas, T. L. Lipografting: Autologous fat grafting for total facial rejuvenation. Facial Plast. Surg. 20: 135, 2004.

[67] Rohrich RJ, Morales DE, Krueger JE, et al. Comparative lipoplasty analysis of in vivo-treated adipose tissue. Plast Reconstr Surg. 2000;105:2152–2158; discussion 2159–2160.

[68] Shiffman MA, Mirrafati S. Fat transfer techniques: The effect of harvest and transfer methods on adipocyte viability and review of the literature. Dermatol Surg. 2001;27:819–826.

[69] Leong DT, Hutmacher DW, Chew FT, Lim TC. Viability and adipogenic potential of human adipose tissue processed cell population obtained from pump-assisted and syringe-assisted liposuction. J Dermatol Sci. 2005;37:169–176.

[70] Ozsoy Z, Kul Z, Bilir A. The role of cannula diameter in improved adipocyte viability: A quantitative analysis. Aesthet Surg J. 2006;26:287–289.

[71] Erdim M, Tezel E, Numanoglu A, Sav A. The effects of the size of liposuction cannula on adipocyte survival and the optimum temperature for fat graft storage: An experimental study. J Plast Reconstr Aesthet Surg. 2009;62:1210–1214.

[72] Pu LL, Coleman SR, Cui X, Ferguson RE Jr, Vasconez HC. Autologous fat grafts harvested and refined by the Coleman technique: A comparative study. Plast Reconstr Surg. 2008; 122:932–937.

[73] Nguyen A, Pasyk KA, Bouvier TN, Hassett CA, Argenta LC: Comparative study of survival of autologous adipose tissue taken and transplanted by different techniques. Plast Reconstr Surg 85: 378-386, 1990

[74] Pu LL, Cui X, Fink BF, Cibull ML, Gao D. The viability of fatty tissues within adipose aspirates after conventional liposuction: A comprehensive study. Ann Plast Surg. 2008;54:288-292; discussion 292.

[75] Coleman SR: Structural fat grafting: more than a permanent filler. Plast Reconstr Surg 118: 108-120, 2006

[76] Butterwick KJ. Lipoaugmentation for aging hands: A comparison of the longevity and aesthetic results of centrifuged versus noncentrifuged fat. Dermatol Surg. 2002;28:987–991.

[77] Khater R, Atanassova P, Anastassov Y, Pellerin P, Martinot-Duquennoy V. Clinical and experimental study of autologous fat grafting after processing by centrifugation and serum lavage. Aesthetic Plast Surg. 2009;33:37–43.

[78] Ferraro GA, De Francesco F, Tirino V, et al. Effects of a new centrifugation method on adipose cell viability for autologous fat grafting. Aesthetic Plast Surg. 2011;35:341–348.

[79] Botti G, Pascali M, Botti C, Bodog F, Cervelli V. A clinical trial in facial fat grafting: Filtered and washed versus centrifuged fat. Plast Reconstr Surg. 2011;127:2464–2473.

[80] Boschert MT, Beckert BW, Puckett CL, Concannon MJ. Analysis of lipocyte viability after liposuction. Plast Reconstr Surg. 2002;109:761–765; discussion 766–767.

[81] Xie Y, Zheng D, Li Q, Chen H, Lei H, Pu LL. The effect of centrifugation on viability of fat grafts: An evaluation with the glucose transport test. J Plast Reconstr Aesthet Surg. 2010;63: 482–487.

[82] Ramon, Y., Shoshani, O., Peled, I. J., et al. Enhancing the take of injected adipose tissue by a simple method for concentrating fat cells. Plast. Reconstr. Surg. 115: 197, 2005.

[83] Karacalar, A., Orak, I., Kaplan, S., et al. No touch technique for autologous fat harvesting. Aesthetic Plast. Surg. 28: 158, 2004.

[84] Marques, A., Brenda, E., Saldiva, P. H., et al. Autologous fat grafts: A quantitative and morphometric study in rabbits. Scand. J. Plast. Reconstr. Surg. Hand Surg. 28: 241, 1994.

[85] Huss, F. R., and Kratz, G. Adipose tissue processed for lipoinjection shows increased cellular survival in vitro when tissue engineering principles are applied. Scand. J. Plast. Reconstr. Surg. Hand Surg. 36: 166, 2002.

[86] Har-Shai, Y., Lindenbaum, E. S., Gamliel-Lazarovich, A., et al. An integrated approach for increasing the survival of autologous fat grafts in the treatment of contour defects. Plast. Reconstr. Surg. 104: 945, 1999.

[87] Yuksel, E., Weinfeld, A., Cleek, R., et al. Increased free fat-graft survival with the long-term, local delivery of insulin, insulin-like growth factor-I, and basic fibroblast growth factor by PLGA/PEG microspheres. Plast. Reconstr. Surg. 105: 1712, 2000.

[88] Butterwick, K. J., and Lack, E. A. Facial volume restoration with the fat autograft muscle injection technique. Dermatol. Surg. 29: 1019, 2003.

[89] Guerrerosantos, J. Long-term outcome of autologous fat transplantation in aesthetic facial recontouring. Clin. Plast. Surg. 27: 515, 2000.

[90] Trepsat, F. Periorbital rejuvenation combining fat grafting and blepharoplasties. Aesthetic Plast. Surg. 27: 243, 2003.

[91] Fagrell, D., Enestrom, S., Berggren, A., et al. Fat cylinder transplantation: An experimental comparative study of three different kinds of fat transplants. Plast. Reconstr. Surg. 98: 90, 1996.

[92] Lidagoster, M. I., Cinelli, P. B., and Levee, E. M. Comparison of autologous fat transfer in fresh, refrigerated, and frozen specimens: An animal model. Ann. Plast. Surg. 44: 512, 2000.

[93] Butterwick KJ, Bevin AA, Iyer S. Fat transplantation using fresh versus frozen fat: A side-by-side two-hand comparison pilot study. Dermatol Surg. 2006;32:640–644.

[94] Aboudib, J. H. C., Cardoso de Castro, C., and Gradel, J. Hand rejuvenescence by fat filling. Ann. Plast. Surg. 28: 559, 1992.

[95] Aygit, A. C., Sarikaya, A., Doganay, L., et al. The fate of intramuscularly injected fat grafts: An experimental study in rabbits. Aesthetic Plast. Surg. 28: 334, 2004.

[96] Feinendegen, D. L., Baumgartner, R. W., Vuadens, P., et al. Autologous fat injection for soft tissue augmentation in the face: A safe procedure? Aesthetic Plast. Surg. 22: 163, 1998.

[97] Latoni JD, Marshall DM, Wolfe SA: Overgrowth of fat autotransplanted for correction of localized steroid-induced atrophy. Plast Reconstr Surg 106: 1566-1569, 2000

[98] Miller JJ, Popp JC: Fat hypertrophy after autologous fat transfer. Ophthal Plast Reconstr Surg 18: 228-231, 2002

[99] Guaraldi G, De Fazio D, Orlando G, Murri R, Wu A, Guaraldi P, et al: Facial lipohypertrophy in HIV-infected subjects who underwent autologous fat tissue transplantation. Clin Infect Dis 40: 13-15, 2005

[100] Dreizen NG, Framm L: Sudden unilateral visual loss after autologous fat injection into the glabellar area. Am J Ophthalmol 107: 85-87, 1989

[101] Egido JA, Arroyo R, Marcos A, Jiménez-Alfaro I: Middle cerebral artery embolism and unilateral visual loss after autologous fat injection into the glabellar area. Stroke 1993: 615-616, 1993

[102] Feinendegen DL, Baumgartner RW, Vuadens P, Schroth G, Mattle HP, Regli F, et al: Autologous fat injection for soft tissue augmentation in the face: a safe procedure? Aesthetic Plast Surg 22: 163-167, 1998

[103] Yoon SS, Chang DI, Chung KC: Acute fatal stroke immediately following autologous fat injection into the face. Neurology 61: 1151-1152, 2003

[104] Erbguth FJ. Historical notes on botulism, Clostridium botulinum, botulinum toxin and the idea of the therapeutic use of the toxin. Mov Disord 2004;19:S2-S6.

[105] Erbguth FJ. From poison to remedy: the chequered history of botulinum toxin. J Neural Transm 2008: 115: 559–565.

[106] Ting PT, Freiman A. The story of Clostridium botulinum: from food poisoning to Botox. Clin Med 2004: 4: 258–261.

[107] Cherington M. Botulism: update and review. Semin Neurol 2004: 24: 155–163.

[108] MG Berry, Jan J. Stanek: Botulinum neurotoxin A: A review. Journal of Plastic, Reconstructive & Aesthetic Surgery (2012) xx, 1-9

[109] Burgen ASV, Dickens F, Zatman LJ. The action of botulinum toxin on the neuro-muscular junction. J Physiol 1949;109: 10-24.

[110] Scott AB, Rosenbaum A, Collins CC. Pharmacologic weakening of extraocular muscles. Invest Ophthalmol 1973: 12: 924–927.

[111] Scott AB. Botulinum toxin injection of eye muscles to correct strabismus. Trans Am Ophthalmol Soc 1981: 79: 734–770.

[112] Scott AB, Kennedy RA, Stubbs HA. Botulinum toxin A injection as a treatment for blepharospasm. Arch Opththalmol 1985; 103:347-50.

[113] Carruthers J, Carruthers A. Treatment of glabellar frown lines with C. botulinum-A exotoxin. J Dermatol Surg Oncol 1992: 18: 17–21.

[114] Benedetto AV. The cosmetic uses of Botulinum toxin type A. Int J Dermatol 1999: 38: 641–655.

[115] Blitzer A, Brin MF, Keen MS, Aviv JE. Botulinum toxin for the treatment of hyperfunctional lines of the face. Arch Otolaryngol Head Neck Surg 1993: 119: 1018–1022.

[116] Carruthers A, Carruthers J. History of the cosmetic use of Botulinum A exotoxin. Dermatol Surg 1998: 24: 1168–1170.

[117] Niamtu J. Aesthetic uses of botulinum toxin A. J Oral Maxillofac Surg 1999: 57: 1228–1233.

[118] Niamtu J. Cosmetic facial surgery. Oral Maxillofac Surg Clin North Am 2000: 12: 595.

[119] Osako M, Keltner JL. Botulinum A toxin (Oculinum) in ophthalmology. Surv Ophthalmol 1991;36:28-46.

[120] Smith LDS. The occurrence of Clostridium botulinum and Clostridium tetani in the soil of the United States. Health Lab Sci 1978: 15: 74–80.

[121] Flynn TC. Update on botulinum toxin. Semin Cutan Med Surg 2006: 25: 115–121.

[122] O. W. Majid: Clinical use of botulinum toxins in oral and maxillofacial surgery. Int. J. Oral Maxillofac. Surg. 2010; 39: 197–207.

[123] Hatheway CL. Clostridium botulinum and other clostridia that produce botulinum neurotoxins. In: Hauschild AHW, Dodds KL, eds: Clostridium botulinum Ecology and Control in Foods. New York, NY: Marcel Dekker, Inc 1992: 3–10.

[124] Halpern JL, Smith LA, Seamon KB, Groover KA, Habig WH. Sequence homology between tetanus and botulinum toxins detected by an antipeptide antibody. Infect Immun 1989: 57: 18–22.

[125] Huang W, Foster JA, Rogachefsky AS. Pharmacology of botulinum toxin. J Am Acad Dermatol 2000: 43(2 Pt 1):249–259.

[126] Setlow P. I will survive: DNA protection in bacterial spores. Trends Microbiol 2007;15:172-80.

[127] Franz DR, Pitt LM, Clayton MA, Hanes MA, Rose KJ. Efficacy of prophylactic and therapeutic administration of antitoxin for inhalation botulism. In: DasGupta BR, ed: Botulinum and Tetanus Neurotoxins: Neurotransmission and Biomedical Aspects. New York, NY: Plenum Press 1993: 473–476.

[128] Herrero BA, Ecklung AE, Streett CS, Ford DF, King JK. Experimental botulism in monkeys Aclinical pathological study. Exp Mol Pathol 1967: 6: 84–95.

[129] Cartee TV, Monheit GD. An overview of botulinum toxins: past, present, and future. Clin Plast Surg 2011;38:409-26.

[130] Brin MF. Botulinum toxin therapy: basic science and overview of other therapeutic applications. In: Blitzer A, ed: Management of facial lines and wrinkles. Philadelphia: Lippincott, Williams and Wilkins 2000 p : 279–302.

[131] Klein AW. Dilution and storage of botulinum toxin. Dermatol Surg 1998: 24: 1179–1180.

[132] Koriazova LK, Montal M. Translocation of botulinum neurotoxin light chain protease through the heavy chain channel. Nat Struct Biol 2003;10:13-8.

[133] Angaut-Petit D, Molgo´ J, Comella JX, Faille L, Tabti N. Terminal sprouting in mouse neuromuscular junctions poisoned with botulinum type A toxin: morphological and electrophysiological features. Neuroscience 1990;37:799-808.

[134] Schiavo G, Matteoli M, Montecucco C. Neurotoxins affecting neuroexocytosis. Physiol Rev 2000;80:717-66.

[135] Sanders DB, Massey EW, Buckley EG. Botulinum toxin for blepharospasm: single-fibre EMG studies. Neurology 1986;36: 545-7.

[136] Benjamin A. Bassichis: Cosmetic use of botulinum toxin in the upper face. Operative Techniques in Otolaryngology (2007) 18, 248-253.

[137] G. W. C. Jaspers, J. Pijpe, J. Jansma: The use of botulinum toxin type A in cosmetic facial procedures. Int. J. Oral Maxillofac. Surg. 2011; 40: 127–133.

[138] de Paiva A, Meunier FA, Molgo J, Aoki KR, Dolly JO. Functional repair of motor endplates after botulinum neurotoxin type A poisoning: biphasic switch of synaptic activity between nerve sprouts and their parent terminals. Proc Natl Acad Sci USA 1999;96:3200-5.

[139] Blitzer A, Sulica L. Botulinum toxin: basic science and clinical uses in otolaryngology. Laryngoscope 2001: 111: 218–226.

[140] Shaari CM. Quantifying the spread of botulinum toxin through muscle fascia. Laryngoscope 1991: 101: 960–963.

[141] Matarasso SL. Comparison of botulinum toxin types A and B: A bilateral and double-blind randomized evaluation in the treatment of canthal rhytides. Dermatol Surg 2003: 29: 7–13.

[142] Jost Wh. Blumel J, Grafe S. Botulinum neurotoxin type A free of complexing proteins (XEOMIN) in focal dystonia. Drugs 2007: 67: 669–683.

[143] Freeman SR, Cohen JL. New Neurotoxins on the Horizon. Aesthetic Surg J 2008: 28: 325–330.

[144] DRESSLER D, MANDER GJ, FINK K. Equivalent potency of Xeomin and BOTOX. Abstracts Toxins 2008/Toxicon 51: 10.

[145] Tang X, Wan X. Comparison of Botox with a Chinese type A botulinum toxin. Chin Med J (Engl) 2000: 113: 794–798.

[146] Ramirez AL, Reeck J, Maas CS. Botulinum toxin type B (MyoBloc) in the management of hyperkinetic facial lines. Otolaryngol Head Neck Surg 2002: 126: 459–467.

[147] Alster T, Lupton J. Botulinum toxin type B for dynamic glabellar rhytides refractory to botulinum toxin type A. Dermatol Surg 2003: 29: 516–518.

[148] Baumann L, Stezinger A, Vujevich J, Halem M, Bryde J, Black L. A double-blinded, randomized, placebocontrolled pilot study of the safety and efficacy of Myobloc (botulinum toxin type B)-purified neurotoxin complex for the treatment of crow's feet: A double-blinded, placebo- controlled trial. Dermatol Surg 2003: 29: 508–515.

[149] Lew MF, Brashear A, Factor S. The safety and efficacy of botulinum toxin type B in the treatment of patients with cervical dystonia: Summary of three controlled clinical trials. Neurology 2000: 55(12 Suppl 5):S29–S35.

[150] Lowe NJ, Yamauchi PS, Lask GP, Patnaik R, Moore D. Botulinum toxins types A and B for brow furrows: Preliminary experiences with type B toxin dosing. J Cosmet Laser Ther 2002: 4: 15–18.

[151] Flynn TC. Myobloc. Dermatol Clin 2004: 22: 207–211.

[152] Flynn TC, Clark RE. Botulinum toxin type B (MYOBLOC) versus botulinum toxin type A (BOTOX) frontalis study: rate of onset and radius of diffusion. Dermatol Surg 2003: 29: 519–522.

[153] Guerrissi J, Sarkissian P: Local injection into mimetic muscles of botulinum toxin A for the treatment of facial lines. Ann Plast Surg 39:447-453, 1997

[154] Blitzer A, Binder WJ, Aviv JE, et al: The management of hyperfunctional facial lines with botulinum toxin. A collaborative study of 210 injection sites in 162 patients. Arch Otolaryngol Head Neck Surg 123:389-392, 1997

[155] Fagien S: Botox for the treatment of dynamic and hyperkinetic facial lines and furrows: Adjunctive use in facial aesthetic surgery. Plast Reconstr Surg 103:701-713, 1999

[156] Carruthers JA, Lowe NJ, Menter MA, et al: A multicentre, doubleblind, randomized, placebo-controlled study of efficacy and safety of botulinum toxin type A in the treatment of glabellar lines. J Am Acad Dermatol 46:840-849, 2002

[157] Borodic G. Immunologic resistance after repeated botulinum toxin type a injections for facial rhytides. Ophthal Plast Reconstr Surg 2006: 22: 239–240.

[158] Pribitkin EA, Greco TM, Goode RL, et al: Patient selection in the treatment of glabellar wrinkles with botulinum toxin type A injection. Arch Otolaryngol Head Neck Surg 123:321-326, 1997

[159] Hexsel D, Rutowitsch MS, de Castro LC, do Prado DZ, Lima MM. Blind multicenter study of the efficacy and safety of injections of a commercial preparation of botulinum toxin type A reconstituted up to 15 days before injection. Dermatol Surg 2009: 35: 933–939.

[160] Hexsal DM, de Almeida AT, Rutowitsch M, et al: Multicenter, doubleblind study of the efficacy of injections with botulinum toxin type A reconstituted up to six consecutive weeks before application. Dermatol Surg 29:523-529, 2003

[161] Carruthers A, Carruthers J, Cohen J. Dilution volume of botulinum toxin type A for the treatment of glabellar rhytides: Does it matter? Dermatol Surg Volume 33:S97, 2007

[162] Carruthers A, Carruthers J: Prospective, double-blind, randomized, parallel-group, dose-ranging study of botulinum toxin type A in men with glabellar rhytids. Dermatol Surg 31:1297-1303, 2005

[163] Carruthers J, Fagien S, Matarasso SL, et al: Consensus recommendations on the use of botulinum toxin type A in facial aesthetics. Plast Reconstr Surg 114:1S-22S, 2004

[164] Carruthers A, Carruthers J, Flynn TC, Leong MS. Dose-finding, safety, and tolerability study of botulinum toxin type B for the treatment of hyperfunctional glabellar lines. Dermatol Surg 2007: 33: S60–S68.

[165] Carruthers A, Carruthers J, Said S. Dose-ranging study of botulinum toxin type A in the treatment of glabellar rhytids in females. Dermatol Surg 2005: 31: 414–422.

[166] Niamtu J, Campbell RL. The anesthetic skin patch for topical cutaneous anesthesia. J Oral Maxillofac Surg 1984: 42: 839–840.

[167] Carruthers J, Carruthers A: The use of botulinum toxin type A in the upper face. Facial Plast Surg Clin North Am. 2006 Aug;14(3):253-60.

[168] Hegedus F, Diecidue R, Taub D, Nyirady J. Non-surgical treatment modalities of facial photodamage: practical knowledge for the oral and maxillofacial professional. Int J Oral Maxillofac Surg 2006: 35: 389–398.

[169] Carruthers A, Carruthers J. Eyebrow height after botulinum toxin type A to the glabella. Dermatol Surg 2007: 3: S26–S31.

[170] Fagien S, Carruthers JD. A comprehensive review of patient-reported satisfaction with botulinum toxin type a for aesthetic procedures. Plast Reconstr Surg 2008: 122: 1915–1925.

[171] Dayan SH, Bassichis BA: Evaluation of the patient for cosmetic Botox injections. Facial Plast Surg Clin North Am 11:349-358, 2003 (review)

[172] Spencer JM, Gordon M, Goldberg DJ: Botulinum B treatment of the glabellar and frontalis regions: A dose response analysis. J Cosmet Laser Ther 4:19-23, 2002

[173] Ahn MS, Catten M, Maas CS. Temporal brow lift using botulinum toxin A. Plast Reconstr Surg 105:1129-1135; discussion 1136-1139, 2000

[174] Huilgo SC, Carruthers A, Carruthers JD: Raising eyebrows with botulinum toxin. Dermatol Surg 25:373-375, 1999

[175] Carruthers A, Carruthers J: Botulinum toxin type A: History and current cosmetic use in the upper face. Semin Cutan Med Surg 20:71-84, 2001

[176] Carruthers A, Carruthers J, Cohen J. A prospective, double-blind, randomized, parallel-group, dose-ranging study of botulinum toxin type a in female subjects with horizontal forehead rhytides. Dermatol Surg 2003: 29: 461–467.

[177] Fagien S, Brandt FS: Primary and adjunctive use of botulinum toxin type A (Botox) in facial aesthetic surgery: Beyond the glabella. Clin Plast Surg 28:127-148, 2001

[178] Coroneo MT, Rosenberg ML, Cheung LM. Ocular effects of cosmetic products and procedures. Ocul Surf 2006: 4: 94–102.

[179] Carruthers J, Carruthers A: BOTOX use in the mid and lower face and neck. Semin Cutan Med Surg 20:85-92, 2001

[180] Matarasso SL, Matarasso A: Treatment guidelines for botulinum toxin type A for the periocular region and a report on partial upper lip ptosis following injections to the lateral canthal rhytids. Plast Reconstr Surg 108:208-214; discussion 215-217, 2001

[181] Balikian RV, Zimbler MS: Primary and adjunctive uses of Botulinum Toxin Type A in the periorbital region. Facial Plast Surg Clin North Am 13:583-590, 2005 (review)

[182] CARRUTHERS A: Facial aesthetic enhancement educational initiative. Chicago, IL, Faculty Training, July 2001; 13-15.

[183] Bentsianov B, Francis A, Blitzer A. Botulinum toxin treatment of temporomandibular disorders, masseteric hypertrophy, and cosmetic masseter reduction. Oper Tech Otolaryngol Head Neck Surg 2004: 15: 110–113.

[184] Vartanian AJ, Dayan SH: Complications of botulinum toxin A use in facial rejuvenation Facial Plast Surg Clin North Am 13:1-10, 2005 (review)

[185] Brin MF, Tl Boodhoo, Pogoda JM, et al. Safety and tolerability of onabotulinumtoxinA in the treatment of facial lines: a metaanalysis of individual patient data from global clinical registration studies in 1678 participants. J Am Acad Dermatol 2009; 61:961-70.

[186] Hsu TSJ, Dover JS, Arndt KA: Effect of volume and concentration on the diffusion of botulinum exotoxin A. Arch Dermatol 140:1351-1354, 2004

[187] Wollina U, Konrad H. Managing adverse events associated with botulinum toxin type A: a focus on cosmetic procedures. Am J Clin Dermatol 2005: 6: 141–150.

[188] McKee GM, Karp FL: The treatment of postacne scars with phenol. Br J Dermatol 64:456, 1952

[189] Kromayer E: The Cosmetic Treatment of Skin Complaints. New York, Oxford University Press, 1930 (English Translation of 2nd German Edition, 1929)

[190] Baker TJ: The ablation of rhytides by chemical means. J Fla Med Assoc 47:451-454, 1961

[191] Anderson RR, Parrish RR: Selective photothermolysis: Precise microsurgery by selective absorption of pulsed radiation. Science 220:524-527, 1983

[192] Gartner LP, Hiatt JL. Color textbook of histology. 2nd edition. Baltimore (MD): Saunders; 2001.

[193] Jacob CI, Dover JS, Kaminer MS: Acne scarring: A classification system and review of treatment options. J Am Acad Dermatol 45:109-117, 2001

[194] Naga B. Meduri: Facial resurfacing: An overview. Operative Techniques in Otolaryngology (2007) 18, 172-180

[195] Mangat DS, Tansavatdi K, Garlich P: Current chemical peels and other resurfacing techniques. Facial Plast Surg. 2011 Feb;27(1):35-49. Epub 2011 Jan 18.

[196] Brody HJ. Complications of chemical peeling. J Dermatol Surg Oncol 1989;15:1010–1019

[197] Sadick NS: Overview of complications of nonsurgical facial rejuvenation procedures. Clin Plast Surg 28:163-176, 2001

[198] Popp C, Kligman AM, Stoudemayer TJ. Pretreatment of photoaged forearm skin with topical tretinoin accelerates healing of full-thickness wounds. Br J Dermatol 1995;132: 46–53

[199] Vagotis FL, Brundage SR. Histologic study of dermabrasion and chemical peel in an animal model after pretreatment with Retin-A. Aesthetic Plast Surg 1995;19:243–246

[200] Kim IH, Kim HK, Kye YC. Effects of tretinoin pretreatment on TCA chemical peel in guinea pig skin. J Korean Med Sci 1996;11:335–341

[201] Tung RC, Bergfeld WF, Vidimos AT, Remzi BK. alpha-Hydroxy acid-based cosmetic procedures: Guidelines for patient management. Am J Clin Dermatol. 2000;1:81–88.

[202] Herbig K, Trussler AP, Khosla RK, Rohrich RJ. Combination Jessner's solution and trichloroacetic acid chemical peel: Technique and outcomes. Plast Reconstr Surg. 2009; 124:955–964.

[203] Rohrich RJ, Herbig KS. The role of modified Jessner's solution with 35% trichloroacetic acid peel. Plast Reconstr Surg. 2009;124:965–966.

[204] Manuskiatti W, Fitzpatrick RE, Goldman MP: Prophylactic antibiotics in patients undergoing laser resurfacing of the skin. J Am Acad Dermatol 40:77-84, 1999

[205] Sabini P: Classifying, diagnosing, and treating the complications of resurfacing the facial skin. Facial Plast Surg Clin N Am 12:357-361, 2004

[206] Fischer TC, Perosino E, Poli F, Viero MS, Dreno B; Cosmetic Dermatology European Expert Group. Chemical peels in aesthetic dermatology: An update 2009. J Eur Acad Dermatol Venereol. 2010;24:281–292.

[207] Rohrich RJ, Hollier LH. Chemical peels in plastic surgery. West J Med. 1995;162:538–539.

[208] Brody HJ, Hailey CW: Medium depth chemical peeling. J Dermatol Surg Oncol 12:1268-75, 1989

[209] Kligman D, Kligman AM. Salicylic acid peels for the treatment of photoaging. Dermatol Surg. 1998;24:325–328.

[210] Van Scott EJ, Yu RJ. Alpha hydroxy acids: procedures for use in clinical practice. Cutis 1989;43:222–228

[211] Perkins SW, Castellano R: Use of combined modality for maximal resurfacing. Facial Plast Surg Clin N Am 12:323-337, 2004

[212] Nguyen AT, Ahmad J, Fagien S, Rohrich RJ: Cosmetic medicine: facial resurfacing and injectables. Plast Reconstr Surg. 2012 Jan;129(1):142e-153e.

[213] Brody HJ. Variations and comparisons in medium-depth chemical peeling. J Dermatol Surg Oncol 1989;15:953–963

[214] Coleman WP III, Futrell JM. The glycolic acid trichloroacetic acid peel. J Dermatol Surg Oncol 1994;20:76–80

[215] Tse Y, Ostad A, Lee HS, et al: A clinical and histologic evaluation of two medium-depth peels: Glycolic acid versus Jessner's trichloroacetic acid. Dermatol Surg 22:781-786, 1996

[216] Asken S: Unoccluded Baker-Gordon phenol peels—Review and update. J Dermatol Surg Oncol 15:9, 1989

[217] Monheit GD. Advances in chemical peeling. Facial Plast Surg Clin North Am 1994;2:5–9

[218] Stuzin JM, Baker TJ, Gordon HL. Chemical peel: A change in the routine. Ann Plast Surg. 1989;23:166–169.

[219] Roy D: Ablative Facial Resurfacing. Dermatol Clin 23:549-559, 2005

[220] Hetter GP. An examination of the phenol-croton oil peel: Part II. The lay peelers and their croton oil formulas. Plast Reconstr Surg. 2000;105:240–248; discussion 249–251.

[221] Vermeer BJ, Gilchrest BA. Cosmeceuticals: A proposal for rational definition, evaluation, and regulation. Arch Dermatol. 1996;132:337–340.

[222] Monheit GD. Medium-depth chemical peels. Dermatol Clin 2001;19:413–425, vii

[223] Szachowicz EH, Wright WK. Delayed healing after full-face chemical peels. Facial Plast Surg 1989;6:8–13

[224] Brody HJ. Complications of chemical resurfacing. Dermatol Clin 2001;19:427–438, vii–viii

[225] Kim EK, Hovsepian RV, Mathew P, Paul MD: Dermabrasion. Clin Plast Surg. 2011 Jul;38(3):391-5, v-vi.

[226] Holmkvist KA, Rogers GS: Treatment of perioral rhytides: A comparison of dermabrasion and superpulsed carbon dioxide laser. Arch Dermatol 136:725-731, 2000

[227] Fezza JP: Laserbrasion: The combination of carbon dioxide laser and dermasanding. Plast Reconstr Surg 118:1217-1221, 2006

[228] Gold M. Dermabrasion in dermatology. Am J Clin Dermatol 2003;4(7):467–71.

[229] Freedman BM, Rueda-Pedraza E, Waddell SP: The epidermal and dermal changes associated with microdermabrasion. Dermatol Surg 27:1031-1033, 2001

[230] Alexiades-Armenakas MR, Dover JS, Arndt KA. The spectrum of laser skin resurfacing: Nonablative, fractional, and ablative laser resurfacing. J Am Acad Dermatol. 2008;58:719–737; quiz 738–740.

[231] Roy D. Ablative facial resurfacing. Dermatol Clin. 2005;23: 549–559, viii.

[232] Fitzpatrick TB. Soleil et peau. J Med Esthet. 1975;2:33–34.

[233] Narurkar VA. Nonablative fractional laser resurfacing. Dermatol Clin. 2009;27:473–478, vi.

[234] Hunzeker CM, Weiss ET, Geronemus RG. Fractionated CO2 laser resurfacing: Our experience with more than 2000 treatments. Aesthet Surg J. 2009;29:317–322.

[235] Airan LE, Hruza G: Current lasers in skin resurfacing. Facial Plast Surg Clin N Am 13:127-139, 2005

[236] Yang CC, Chai CY: Animal study of skin resurfacing using the ultrapulse carbon dioxide laser. Ann Plast Surg 35:154-158, 1995

[237] Tierney EP, Hanke CW. Recent advances in combination treatments for photoaging: review of the literature. Dermatol Surg 2010;36:829–840

[238] Khatri KA, Ross V, Grevelink JM, et al: Comparison of Erbium:YAG and carbon dioxide lasers in resurfacing of facial rhytides. Arch Dermatol 135:391-397, 1999

[239] Ross EV, Naseef GS, McKinlay JR, et al: Comparison of carbon dioxide laser, Erbium:YAG laser, dermabrasion, and dermatome: a study of thermal damage, wound contraction, and wound healing in a live pig model: implications for skin resurfacing. J Am Acad Dermatol 42:92-105, 2000

[240] Fitzpatrick RE, Smith SR, Sriprachya-Anunt S: Depth of vaporization and the effect of pulse stacking with a high energy, pulsed carbon dioxide laser. J Am Acad Dermatol 40:615-622, 1999

[241] Goldman MP, Manuskiatti W: Combined laser resurfacing with the 950-microsec pulsed CO2 Er:YAG lasers. Dermatol Surg 25:160-163, 1999

[242] Manstein D, Herron GS, Sink RK, et al: Fractional photothermolysis: A new concept for cutaneous remodeling using microscopic patterns of thermal injury. Lasers Surg Med 34:426-438, 2004

[243] Rahman Z, Alam M, Dover JS: Fractional laser treatment for pigmentation and texture improvement. Skin Therapy Lett 11:7-11, 2006

Chapter 31

Facial Sculpturing by Fat Grafting

Behnam Bohluli, Mehran Aghagoli, Farzin Sarkarat,
Mansour Malekzadeh and Nima Moharamnejad

Additional information is available at the end of the chapter

http://dx.doi.org/10.5772/54874

1. Introduction

Autologous fat grafting is one of the most demanded facial cosmetic procedures. Fat reservoirs are usually available in large amounts in most patients. The procedure of fat grafting may be repeated several times without any considerable complications. Facial tissues readily accept autologous fat without any fear of immune reaction or carcinogenicity. It is a popular technique that may be used in maxillofacial esthetic surgery. This procedure may be done as an isolated procedure or as an adjunct to any facial esthetic operation such as face lifting to enhance the final esthetic outcome. The main drawback of this procedure is possibility of resorption and unpredictable results of the augmentation; however it is generally believed that prognosis of fat grafting is directly related to proper case selection and meticulous surgical technique. This chapter provides an overview of current concepts and key points in fat harvesting, refinement and injection that may potentially lead to long-lasting, predictable results. Common complications are discussed, and effort is made to explain ways to avoid these events and to solve the problems when they happen.

2. History of fat grafting

The story of fat grafting started in 1893 when a German surgeon (Adolf Neuber) reported his new technique in operating a depressed scar in the infraorbital region of a young man. He harvested a small piece of subdermal fat from the patients upper arm and inserted it to elevate a depressed scar; surprisingly he also explained his frequent failures in treating larger defects and suggested to reserve fat grafting for defects the size of a bean. This effort was occasionally repeated by some other surgeons. The graft results were extremely controversial till 1983 when suction lipectomy was introduced. This technique provided a safe and conservative method

INTECH
open science | open minds

© 2013 Bohluli et al.; licensee InTech. This is a paper distributed under the terms of the Creative Commons Attribution License (http://creativecommons.org/licenses/by/3.0), which permits unrestricted use, distribution, and reproduction in any medium, provided the original work is properly cited.

for fat harvesting and transfer. At this time a new drawback of fat grafting appeared which was resorption and unpredictable results. Coleman explained structural fat grafting with long lasting results. His concept was mainly a refinement of known technique with a great attention to atraumatic handling of fat cells during harvesting, processing and grafting. [1-6] This concept opened a new era in the field of facial esthetic surgery and found its popularity in a really short time; nowadays fat grafting is well-known technique and studies are underway to turn structural fat grafting to a regenerative procedure using stem cells, platelet derivatives and other additives to fat grafts.

3. Surgical technique

Fat grafting may be divided into three dominant steps; firstly fat is extracted from a secondary donor site then it is processed and purified by one of the known techniques to separate vital fat cells from other redundant ingredients and finally it is injected or transferred to the recipient site; each step needs crucial attention and plays a role in success of the surgery.

3.1. Selection of donor site

Fat harvesting may be done from the lateral thigh, medial thigh, abdomen, suprapubic area and any other part of the body that shows a considerable amount of fat tissue. Some authors believe that medial knee has the least amount of elastic fibers and will lead to a better quality fat, though this finding is not supported by other clinical studies. It is assumed that all donor sites may provide an acceptable amount of vital fatty tissue and patient compliance, surgeon's preference and donor site contours are the main concerns when selecting a donor site. It is sometimes recommended in massive fat harvestings or in lean patients that bilateral donor sites be used to prevent contour deformities [Fig. 1].

3.2. Donor site preparation and local anesthesia infiltration

A small 2-3mm stab incision is made, a small cannula is inserted and 20 to 30cc of local anesthetic(lidocaine with 1/200 000 epinephrine) is dispersed in donor site, after 10 to 15 minutes fat harvesting may be started through the same stab incision [Fig. 2].

3.3. Fat harvesting

Historically fat harvesting was performed by an open approach and direct resection of fatty tissues; use of microcannulae in 1981 changed fat harvesting techniques to a simple conservative procedure. Cannulae may be connected to a suction machine, negative pressure of the machine takes fat parcels from donor sites toward a sterile reservoir; some authors use a 10mm syringe to induce negative pressure in this technique and the cannula is connected to syringe. By withdrawing the plunger, negative pressure is provided, back and forth hand movement will gather fat into the syringe; it is believed that vigorous negative pressure will endanger vital fatty cells and it is proposed that the process of fat harvesting should be based on curettage

http://dx.doi.org/10.5772/54874

Figure 1. In thin patients bilateral multiple donor sites should be considered; in this patient bilateral medial, lateral thighs and medial knees are prepared.

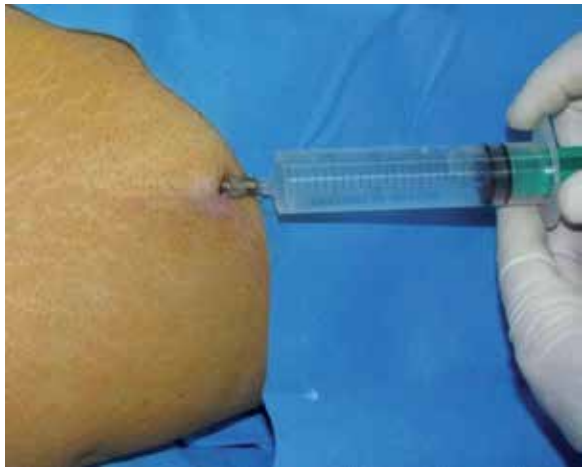

Figure 2. Local anesthetic solution is dispersed into the donor site; it may be done using a 1.5 to 2mm cannula.

of several openings located on the lateral sides of a cannula. Slight negative pressure on the plunger of a syringe (1mm to 3mm negative pressure in a 10cc syringe) which is connected to a cannula plus gentle back and forth hand movements in a relatively longer period of suctioning will gather considerable fat in the syringe (Fig. 3).[7-10]

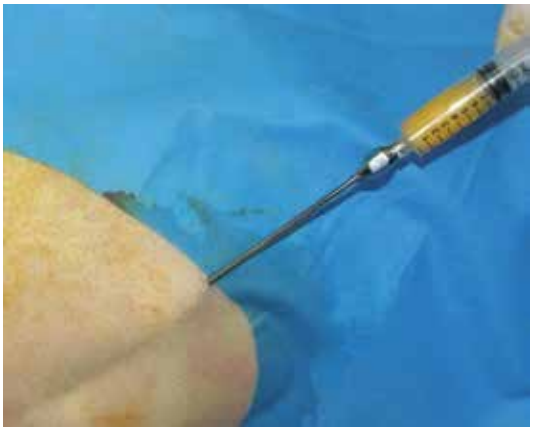

Figure 3. The plunger of a 10cc syringe is withdrawn up to the 3cc mark to induce a light negative pressure.

After 10 to 15 minutes a blunt tip cannula is inserted again and with gentle back and forth movements of the dominant hand fat is extracted from donor adipose tissue while the non-dominant hand holds and stabilizes the donor tissue (Fig. 4).

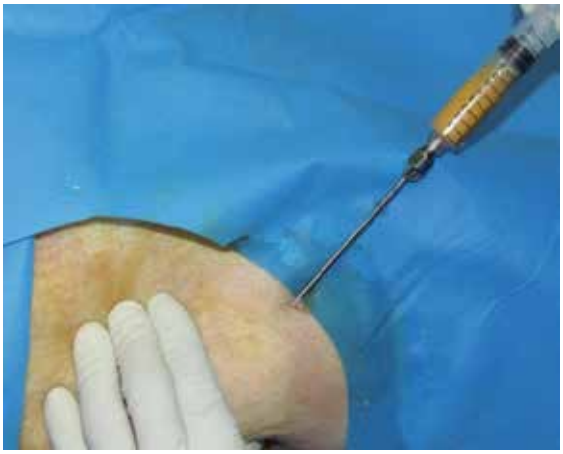

Figure 4. Non-dominat hand holds and stabilizes donor site while dominant hand starts the harvesting procedure.

3.4. Perils and pitfalls

1. **Vital fat cells** are very sensitive, so strict attention to sterility and infection control principles is mandatory; any contamination may lead to infection or destroy the vital cells and result in early resorption.
2. **Small diameter cannulae** (2-3mm) will easily transfer the fat particles and will impose minimal trauma to cells; larger cannulae will accelerate the procedure but take larger

http://dx.doi.org/10.5772/54874

particles which is not desirable for facial tissues and may potentially deform the donor sites.

3. **Low negative pressure** (1-3mm negative pressure by withdrawing the plunger up to 3mm mark) will take longer but is less traumatic to vital fat cells.
4. **Fluid injection**. It is usually recommended to infiltrate 1cc of local anesthetics for each cc of harvested fat ; larger quantities of local anesthetics may be added to ringer's solutions. Super wet environment (injection of tumescent solution) which is routinely used in liposuction operations will cause the fat cells to float and may potentially rupture the cells and should be avoided.
5. **Blood in harvested fat.** It is believed that blood leads to easier and faster degradation of viable fat cells so it is recommended to stop the harvesting process when blood is seen in the harvesting syringe and to proceed to some other donor site to obtain fat.

3.5. Fat processing

A usual harvest is a mixture of three main components; the first part is local anesthetics and ringers solution; this part is the solution which is usually injected preoperatively; this liquid is partly transferred to harvested fat and must be separated to eliminate devastating effects of epinephrine on fat cells; the second part is an oily liquid which lacks vital fat cells this liquid has no adverse effect on donor site when injected but it disturbs intraoperative judgments as it increases postoperative swelling and lengthens recovery time so it is best separated from the third and main part which is vital fatty cells. Fat processing includes any procedure that may help to separate fat cells from two other redundant components. Many methods have been introduced for fat processing but the main two are: 1-Centrifuge, 2-filtering and washing.

Centrifuge: harvested fat is poured in 10cc syringes (Fig. 5 a,b).



Figure 5. a. Harvested fat is poured in 10cc syringes. b. Then the syringes are placed in their special slots in the centrifuge machine.

The syringes are inserted in their special slots in a centrifuge and spun at 3000 rpm for 3 minutes to separate different components (Fig. 6 a,b).

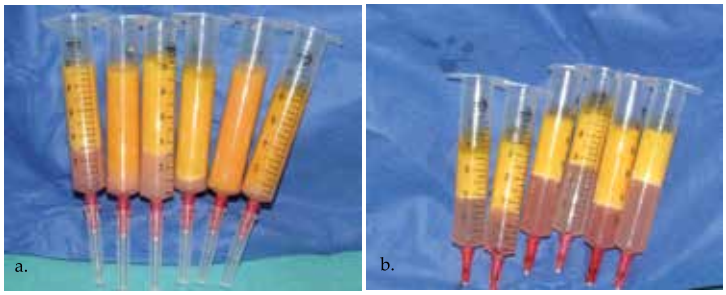

Figure 6. a-Harvested fat is a mixture of lysed fat, local anesthetics and vital fat cells. b-The same view after centrifuge shows the lower part which is local anesthetics and preoperatively injected solutions, middle part is viable fatty tissue and the third upper part is lysed fat cells and triglyceride.

The first part is a liquid that is easily discarded by gentle pressure over the plunger; the second part includes fat cells that are transferred to several 1 cc syringes and are made ready for injection (Fig. 7 a,b,c,d).

Figure 7. a. In all centrifuged syringes the middle part which is viable fat should be separated by slight pressure over plunger until the first part (local anesthetic) is depleted. b.By gradual turning of syringes the upper part which is lysed fat is easily separated and discarded. c. The middle part which is the main part is transferred to 1cc syringes. d. 1cc syringes are set and ready for injection to recipient sites.

http://dx.doi.org/10.5772/54874

3.5.1. Washing and filtering

Harvested fat is poured in a strainer and washed several times with normal saline; some surgeons close both sides of a strainer and stir it for few minutes to provide a more concentrated fatty compartment. Then one side of the strainer is opened and fat is transferred to 1 cc syringes by a sterile surgical spoon or spatula to get it ready for lipoinjection (Fig 8 a,b, c).

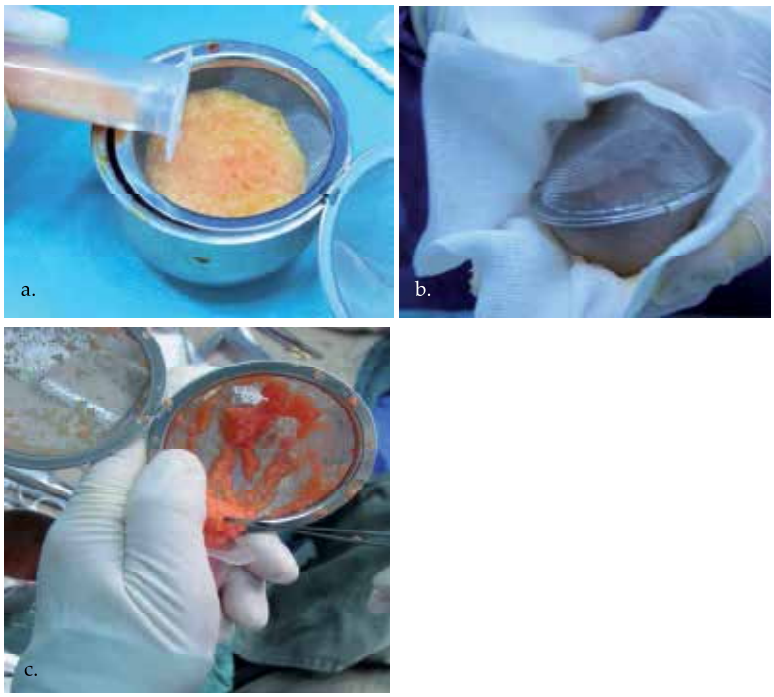

Figure 8. a. Harvested fat is gently poured in a strainer; b. it is washed several times to separate redundant materials.c. Sterile instrument is used to transfer the purified fat to 1cc syringes.

Selecting processing techniques: Many studies have tried to compare known techniques, up to now none of these trials have convinced the surgeons to leave one technique and unanimously accept the other; but it is clear that skills and expertise, gentle handling of fat and sterility may directly affect the success rate of each technique.

4. Fat transfer or injection

Injection sites are carefully designed and marked preoperatively; possible pathways of injection cannulae are drawn with a marker then the usual preparation and draping is performed(Fig. 9 a,b).

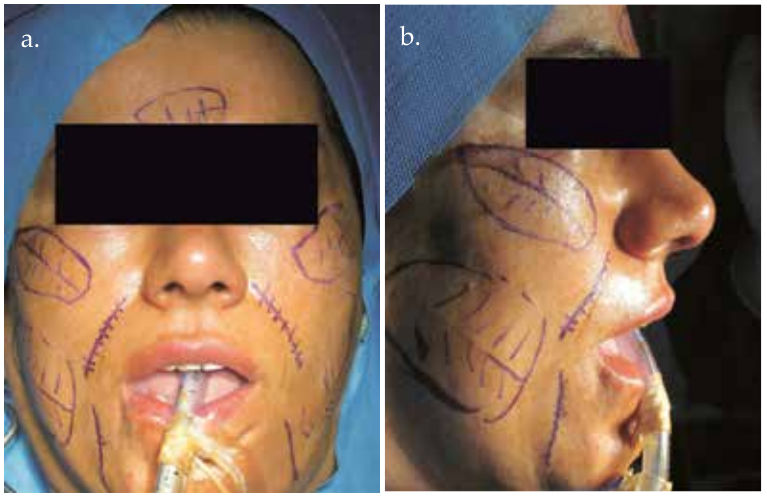

Figure 9. Careful pre-operative drawing and mapping will prevent many post-operative complications.

Proper diameter of injection cannula, amount of graft in each recipient site and injection technique may directly affect the graft viability; these determinant factors will be discussed in detail.

4.1. Injection technique

A stab incision is made in pre-planned site cannula is gently inserted.By gentle movement of cannula a tunnel is formed; a small amount of fat (0.3 to 0.5cc) is injected while withdrawing the cannula; the process is repeated several times till the total amount of pre-planned fat is delivered to recipient site. A 40 to 60 percent overcorrection may be done to overcome any possible delayed resorption and relapse.

4.2. Key-points

Size or diameter of cannula

The size of the cannula will definitely determine the size of transferred fat particles; these sizes are usually from delicate 0.7mm cannulae which are used to fill tear troughs to larger ones (up to 1.5 mm) may be used in cheek and chin augmentations.

Regional approaches

The lips: Lips are mobile and extremely sensitive elements that are challenging sites for augmentation; some authors believe mobility will lead to early resorption while others show long-term stability in their cases. To augment the lips a stab incision is made in center of the lip; left and right sides are separately penetrated by a delicate cannula and 0.5cc of fat is placed in each side then 0.5cc is separately inserted in the middle portion.

Tear troughs: Thin skin with very delicate underling tissue makes this region a critical area in fat grafting; use of a delicate cannula, incremental fat placements in small drops or parcels and meticulous technique of injection may guarantee an acceptable result in periorbital rejuvenation.

The cheek and chin: Malar pads sag with aging; this may lead to flattening of malar contours. This unpleasant deformity may easily be camouflaged by fat grafting; 4cc of fat may be enough to recontour the cheeks. These sites are the most common sites treated. A relatively large (1.2-1.5mm) cannula is usually used to augment chin and cheeks. Chin and cheek augmentation will moderately improve soft tissue contours and should not be accounted as an alternative to hard tissue augmentations (genioplasty, chin implants, malar prosthesis).

Paranasal creases: Elimination of a deep paranasal crease is a big challenge in facial rejuvenation. Filling of nasolabial folds by fat grafting may be added to any face lift procedure or may be performed as a sole procedure; 2-3cc of fat in each site will improve deep nasolabial grooves.

Jaw lines: Gradual appearance of jaw lines and deepening of marionettes line are frustrating sequels of aging; these sites may be easily accessed by small stab incisions that are made for paranasal crease or a separate small incision may made in mandibular border to approach these areas.

Sharp needle injections: Sharp needle injection is a controversial modification of original fat grafting. In this procedure fat is injected transdermally; the main indication of this procedure is to fill deep skin creases or scars.

Amount of injection: The amount of graft may be determined by specific case characteristics though it is generally recommended to use known guidelines and do small modifications from case to case.

5. Indications for fat grafting

Fat grafting has been used for many different purposes but it can be generally mentioned that fat graft rehydrates facial skin and improves the patients skin quality; it is also a good filler which may be used to fill a defect, to correct a contour and finally to augment facial volume. Thus, the main indications of fat graft are based on these two dominant properties of fat grafts.

5.1. Rejuvenation and soft tissue augmentation

Aging is a complex phenomena it is recently proved that volume loss is one of the main factors that manifests characteristics of an aging face; so fat grafts may potentially restore volume deficits. This procedure may be done solely or added to other rejuvenation procedures such as face or brow lifting [Fig. 10].

Figure 10. This 41 year-old woman severe characteristics of early aging such as volume loss, deepening of facial creases and loss of skin quality is seen; esthetic nasal surgery and conservative rejuvenation by fat graft was performed. The 1-year follow-up shows acceptable rejuvenation and improvement of skin quality.

As an adjunct to other major maxillofacial procedure such as rhinoplasty and orthognathic surgery: the role of soft tissue in overall esthetic appearance of the face cannot be underesti-

http://dx.doi.org/10.5772/54874

mated; fat injection may improve soft tissue conditions and will help the patient to obtain a more pleasant appearance (Fig.11).

Figure 11. This 53 year-old woman has undergone a minimal-scar face lifting, and the nasolabial folds, malar eminences, nose deformities and marionette lines were simultaneously augmented by fat grafting; the 2-year follow up shows stable results.

Recontouring facial borders in facial atrophies and hypertrophies

Fat contouring may be used in camouflaging facial contours which is extremely difficult to correct by other reconstructive modalities. Progressive hemifacial atrophy (Pary-Romberg syndrome),hemifacial hyperplasia, traumatic and developmental facial asymmetries are frequently treated by fat grafting techniques [Fig.12].

Figure 12. In this 44 year-old woman a masculine face with exaggerated border and contours was planned for feminization; simultaneous forehead lifting, mandibular angle reduction and total facial fat graft was performed. The 10-year follow up shows acceptable long term results.

To augment and fill lips, paranasal tissues and cheeks, there is a common trend toward the use of fillers to shape and augment facial tissues; infection, foreign body reactions and carcinogenicity of some fillers has made the fat graft an ideal material. As a filler it may be easily provided in larger amounts, it is cheaper when used in larger amounts and easily accepted by most patients(Fig13).

Fat injection to the nose

Fat grafting in rhinoplasty is rapidly finding great popularity. Dorsal irregularities after rhinoplasty are extremely challenging in revision rhinoplasty; use of crushed or morselized cartilages or use of a delicate rasping is not usually efficient and sometimes exaggerate the

http://dx.doi.org/10.5772/54874

Figure 13. This young class III woman underwent mandibular setback to correct the skeletal deformity. Lack of vermilion show was a frustrating complaint. A 3-year follow up shows long term effects of fat grafts of the upper lip.

problem. Fat injection was recently reported to be effective in these cases; some recent studies advocate the use of fat graft in some primary cases, fat may be used in radix augmentation, dorsal refinements and alar pinch deformities though this field is open to future studies. This harmless but extremely unpredictable technique may be best used in patients with other clear indications of fat grafting as an ancillary procedure in hope to obtain the desired results. [10,11]

6. Complications

Fat grafting is a relatively safe procedure it is usually followed by some swelling, bruising and ecchymosis both at donor site and facial recipient site; these sequelae are self limiting and will subside spontaneously in maximum two or three weeks.

1. **Accumulation of fat particles** and visible lumps under the skin: Sometimes small irregularities and lumps are easily seen and palpated under thin skins this will lead to an unesthetic appearance. This complication like most other complications may be best prevented by preoperative planning and delicate surgical technique use of small cannulae in harvesting fat to obtain smaller fat parcels; fat injection and transfer should be done by smaller canulas to help the surgeon delicately place the fat graft in recipient tissues in thin skin areas like lower eyelids and tear troughs; injection may be done in deeper layers.

2. **Resorption and relapse**: resorption of grafted fat is commonly reported; some authors believe in these cases the procedure should be repeated several times though some studies report long lasting results after one stage surgery; it is unanimously accepted that surgeons skills and expertise directly affects the predictability of results. Sometimes it is suggested to do 40 to 50 percent over-contouring to see the best results after usual estimated resorption.

3. **Facial asymmetry**: Asymmetries may be due to uneven injections; this complication may be best prevented by proper planning and preoperative mapping over the face; in case

this asymmetry remains after six months a secondary revision fat grafting may be scheduled.

Immediate postoperative asymmetries in case of precise surgical procedures may be due to asymmetric edema common in facial surgeries and is usually expected to be corrected after subsiding edema.

4. **Fat emboli:** Fat may be placed in medium to large vessels; these particles may be transferred to vital organs and lead to severe life-threatening problems. Blindness and respiratory dysfunctions are amongst the reported cases. Use of blunt cannulae instead of sharp needles that were previously used for fat injection has considerably reduced this possibility. [12-18]

Donor site complications:

Surface depressions and contour irregularities: Careless fat resection from a limited area and massive harvesting from a single site may disturb surface integrity of the donor site and may also lead to body asymmetries; it is recommended to harvest the fat in a radial fashion from insertion site to include a wider donor surface. Massive fat resection may be done from two bilateral sites; in case the problems remain after several months it may be restored by a separate fat transfer to damaged donor tissue asymmetric limbs. The total amount of fat which is usually needed in facial fat augmentation will not cause limb asymmetries in normal patients; in thin patients or those who have undergone extensive liposuction procedures both sides should be prepared and a bilateral symmetrical harvest be considered to prevent this unwanted effect. Any possible congenital or developmental preoperative asymmetry should be determined preoperatively and use of the larger limb in asymmetric limbs may help prevent exaggerated limb asymmetries. [19-23]

Author details

Behnam Bohluli[1], Mehran Aghagoli[2], Farzin Sarkarat[3], Mansour Malekzadeh[4] and Nima Moharamnejad[5]

1 Craniomaxillofacial Research Center and Department of Oral and Maxillofacial Surgery, Buali Hospital, Islamic Azad University of Medical Sciences, Tehran, Iran

2 Oral and Maxillofacial Surgeon, Private Practice, Tehran, Iran

3 Department of Oral and Maxillofacial Surgery, Buali Hospital, Islamic Azad University of Medical Sciences, Tehran, Iran

4 Craniomaxillofacial Research Center, Islamic Azad University of Medical Sciences,Tehran, Iran

5 Department of Oral and Maxillofacial Surgery, Gazi University, Ankara, Turkey

References

[1] Coleman, S. R. Facial augmentation with structural fat grafting.Clin Plast Surg. (2006). Oct;33

[2] Coleman, S. R. Long-term survival of fat transplants: controlled demonstrations.Aesthetic Plast Surg. (1995). Sep-Oct

[3] Coleman, S. R. Facial recontouring with lipostructure.Clin Plast Surg. (1997). Apr

[4] Coleman, S. R. Structural fat grafting.Aesthet Surg J. (1998). Sep-Oct;

[5] Coleman, S. R. Structural fat grafting: more than a permanent filler. Plast Reconstr Surg. (2006). Sep;118

[6] Coleman, S. R. Facial augmentation with structural fat grafting.Clin Plast Surg. (2006). Oct

[7] Grimaldi, M, Gentile, P, Labardi, L, Silvi, E, Trimarco, A, & Cervelli, V. Lipostructure technique in Romberg syndrome. J Craniofac Surg. (2008). Jul;19(4):

[8] Foyatier, J. L, Mojallal, A, Voulliaume, D, & Comparin, J. P. Clinical evaluation of structural fat tissue graft (Lipostructure) in volumetric facial restoration with face-lift. About 100 cases.Ann Chir Plast Esthet. (2004). Oct;49

[9] Defatta, R. J, & Williams, E. F. rd.Fat transfer in conjunction with facial rejuvenation procedures.Facial Plast Surg Clin North Am. (2008). Nov

[10] Alencar, J. C, Andrade, S. H, Pessoa, S. G, & Dias, I. S. Autologous fat transplantation for the treatment of progressive hemifacial atrophy (Parry-Romberg syndrome: case report and review of medical literatute). An Bras Dermatol. (2011). Jul-Aug;86(

[11] Hunstad, J. P, Shifrin, D. A, & Kortesis, B. G. Successful treatment of Parry-Romberg syndrome with autologous fat grafting: year follow-up and review. Ann Plast Surg. (2011). Oct, 14.

[12] Teimourian, B. Blindness following fat injections. Plast Reconstr Surg. (1988). Aug

[13] Dreizen, N. G, & Framm, L. Sudden unilateral visual loss after autologous fat injection into the glabellar area.Am J Ophthalmol. (1989). Jan

[14] Egido, J. A, Arroyo, R, Marcos, A, & Jiménez-alfaro, I. Middle cerebral artery embolism and unilateral visual loss after autologous fat injection into the glabellar area. Stroke. (1993). Apr

[15] Danesh-meyer, H. V, Savino, P. J, & Sergott, R. C. Case reports and small case series: ocular and cerebral ischemia following facial injection of autologous fat.Arch Ophthalmol. (2001). May

[16] Coleman, S. R. Avoidance of arterial occlusion from injection of soft tissue fillers. Aesthet Surg J. (2002). Nov;, 22(6), 555-7.

[17] Smith, P. Adams WP Jr, Lipschitz AH, Chau B, Sorokin E, Rohrich RJ, Brown SA. Autologous human fat grafting: effect of harvesting and preparation techniques on adipocyte graft survival.Plast Reconstr Surg. (2006). May;, 117(6), 1836-44.

[18] Khater, R, Atanassova, P, Anastassov, Y, Pellerin, P, & Martinot-duquennoy, V. Clinical and experimental study of autologous fat grafting after processing by centrifugation and serum lavage.Aesthetic Plast Surg. 2009 Jan;Epub (2008). Nov 20., 33(1), 37-43.

[19] Monreal, J. Fat grafting to the nose: personal experience with 36 patients. Aesthetic Plast Surg. (2011). Oct;, 35(5), 916-22.

[20] Cárdenas, J. C, & Carvajal, J. Refinement of rhinoplasty with lipoinjection. Aesthetic Plast Surg. (2007). Sep-Oct;, 31(5), 501-5.

[21] Teimourian, B, & Fisher, J. B. Suction curettage to remove excess fat for body contouring. Plast Reconstr Surg. (1981). Jul;, 68(1), 50-8.

[22] Teimourian, B. Repair of soft-tissue contour deficit by means of semiliquid fat graft. Plast Reconstr Surg. (1986). Jul;, 78(1), 123-4.

[23] Illouz, Y. G. The fat cell "graft": a new technique to fill depressions.Plast Reconstr Surg. (1986). Jul;, 78(1), 122-3.

Section 14

Temporomandibular Joint Disorders and Facial Pain

Chapter 32

Diagnosis and Management of Temporomandibular Disorders

Fina Navi, Mohammad Hosein Kalantar Motamedi, Koroush Taheri Talesh, Esshagh Lasemi and Zahra Nematollahi

Additional information is available at the end of the chapter

http://dx.doi.org/10.5772/55018

1. Introduction

Temporomandibular disorder (TMD) is one of the most common disorders in the maxillofacial region which usually presents with pain, unusual sounds, discomfort in chewing and locking of the jaw. TMD patients comprise a considerable proportion of patients seeking treatment; early diagnosis is important because it is proven that acute TMD responds well to treatment in contrast to chronic TMD. True diagnosis and treatment of TMD can be difficult, as these patients often suffer from some other disorder at the same time. In these cases, a successful treatment is due to true diagnosis of all initiating factors, predisposing and perpetuating factors and treatment of other established disorders. An important point is the close relation of intrajoint disorders to disorders of masticatory muscles. Today, it has been proven that disorder of masticatory muscles can lead to TMD. The opposite of this, is also true. Correct diagnosis is essential. The diagnostic steps and differential diagnosis of TMD and the treatment protocols from supportive treatment, splint therapy and physiotherapy to temporomandibular joint (TMJ) surgeries are explained herein. We hope this chapter can help better understand TMJ disorders, diagnosis and recognition of the signs and symptoms of disorders of the temporomandibular and masticatory system.

2. Temporomandibular disorder (TMD)

TMD is a general term including clinical problems which affect masticatory muscles, TMJ and adjacent structures. TMD is the most common non-dental pain in the maxillofacial region. The

INTECH
open science | open minds

© 2013 Navi et al.; licensee InTech. This is a paper distributed under the terms of the Creative Commons Attribution License (http://creativecommons.org/licenses/by/3.0), which permits unrestricted use, distribution, and reproduction in any medium, provided the original work is properly cited.

most common sign of TMD is pain in masticatory muscles, or preauricular region and on the TMJ which becomes severe when chewing or upon other mandibular movements. TMD patients have limitation and asymmetry in mandibular movements. They often have clicking, popping, grating and crepitus. Patients may complain from headache, earache and pain in the mandibulofacial region. Masticatory muscle hypertrophy and an unusual facet of occlusal surfaces of the dentition due to excessive mandibular movements such as bruxism or grinding may be present. Management of TMJ disorders usually includes finding the cause or etiology. Parafunction and trauma are common causes of TMD. Stress and mental problems are secondary aggravating factors. [1,2]

2.1. History

After initial studies in 1934, Costen proposed that patients suffering from auricular pain, pressure and fullness in the ear and swallowing problems (Costen syndrome) improve by occlusion correction. In the 1960s, the quality of clinical examinations and scientific studies improved; the importance of occlusion in TMD etiology in 1970 was studied. Methods including tomography, arthrography, computed tomography (CT) scan and magnetic resonance imaging (MRI) lead to improvements in examination of intracapsular structures. Today the information in this field show that patients with orofacial pains may suffer from disorders such as systemic, neuromuscular, vascular, and mental or a combination of disorders associated with TMD; some headway in pain mechanism, neurology, physiology and neuoropharmacology have been made. Different studies demonstrated that TMD treatment has changed based on the diagnosis of the etiology and stage of the disorder. [1,2]

2.2. TMJ anatomy

Temporomandibular joint is the junction site of the mandibular condyle to skull base or glenoid fossa of the temporal bone. A disc separates the two bones. The part of the disc which is in contact with mandibular condyle bone consists of fibrous connective tissue without any nerve or vessel. This joint is a compound one. The disc is divided into three parts, in sagittal view: anterior, posterior and middle. The middle zone is the thinnest part. The disc becomes thicker in the anterior and posterior parts. In coronal view, the medial part of the disc is thicker than the lateral part (Fig. 1). [1]

Disc shape is determined by condyle morphology and mandibular fossa. The disc may become displaced or destroyed via degenerative forces. In the posterior part, the disc is attached to a loose connective tissue of nerve and vessels named retrodiscal tissue. In the superior posterior part, it is attached to a connective tissue full of elastic bands named superior retrodiscal layer or bilaminary zone. This tissue connects the disc to the tympanic bone posteriorly. Below this, there is the inferior retrodiscal layer which connects the inferior border of the posterior edge of the disc to the posterior part of condyle joint surface. Inferior disc layer and superior retrodiscal tissue are made of collagen and elastic fibers, respectively. Anteriorly to the disc, superior and inferior adhesions of it connect to the capsular ligament. Both of these adhesions are made of collagen fibers. Between the capsular ligaments, the disc is adherent to fibers of the superior lateral pterygoid muscle. The disc adheres to the capsular ligament, not only anteroposterior-

http://dx.doi.org/10.5772/55018

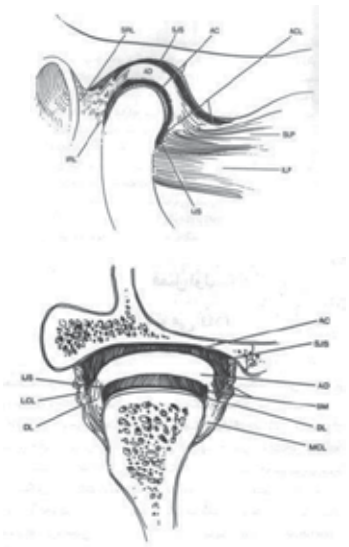

Figure 1. TMJ in sagittal and coronal views.

ly, but also mediolaterally. The joint is divided into two separate and distinct spaces. The superior space is located between the glenoid fossa and superior part of the disc; the inferior disc space lies between the disc and condyle. Internal surfaces of superior and inferior spaces are lined with special endothelial cells which secrete synovial fluid. This fluid has two functions: 1-Molecular transport and metabolism and 2-Lubrication of joint surfaces; the fluid is secreted on the joint surfaces under pressure and results in friction reduction. During function, forces entering to the joint surfaces lead to movement of this fluid into intrajoint tissues. In coronal view, the condyle has a medial and lateral pole; the medial pole is thicker than the lateral one. The TMJ is supported by three major and two minor ligaments. [1,2]

Major ligaments are:

1. Collateral ligaments
2. Capsular ligament
3. Temporomandibular ligament

Minor ligaments are:

1. Sphenomandibular ligament
2. Stylomandibular ligament

2.3. TMD etiology

TMD is considered as a multifactorial disorder and there is no special or individual cause for it. There are factors which can damage the balance in TMJ and the masticatory system. Bone deformations, soft tissue metaplasia of TMJ and muscle activity reduction are often adaptive

responses to changes. Hyperactivity of masticatory muscles resulting from parafunctional habits can lead to adaptive responses in dynamic balance because of hyperactivity and high load in the long term. Excessive changes in any of the above functions can lead to disability to adapt leading to TMJ disorders. For example, external trauma to any part results in injuries and disorders in normal joint function. Moreover, anatomic, systemic, pathophysiological and emotional causes can make the disorder more severe. [1,2]

2.3.1. Trauma

Nowadays, trauma is believed to be the initial cause of TMD. In fact, excessive trauma because of parafunctional forces can damage the masticatory system. These damages may result in joint injuries and pain in eating, smiling, yawing or excessive opening of the mouth. External trauma such as a punch, sport activities and injuries because of dental practice can lead to TMD. An important type of trauma is parafunctional trauma. Postural habits such as head forwarding or holding the phone handset place pressure on joints and muscles which result in musculoskeletal pains such as headaches in TMD patients. Additional habits and movements such as clenching, bruxism, attrition, lip biting and abnormal posture of the jaws common in society may lead to TMD. Although in some patients, it is known as an initial factor, parafunctional habits can be aggravated by stress, anxiety, sleeping and eating disorder. [1,2]

2.3.2. Anatomical factors

Anatomical factors affecting the TMJ can be hereditary, developmental or acquired. Some skeletal disorders such as small mandibular arch, class II occlusion etc. can affect the TMJ. However, millimetric changes in face vertical dimension, overbite, over jet or cross bite alone, are not the only cause of TMD. Today it is believed that dental occlusion disorders are second in importance.

2.3.3. Pathophysiological factors

These include: degenerative disorders, endocrine disorders, infections and blood disorders. It is revealed that viscosity of synovial liquid and its lack of lubricant property may be the initial cause of internal derangement and clicking.

2.3.4. Mental factors

Stress and mental stresses, can result in excessive load on masticatory system and parafunctional habits. Mental and emotional disorders can be predisposing TMD causes. So, it is highly important to consider the socio-mental factors upon examination of patients with TMD.

3. Temporomandibular disorders classification

Classifying TMDs, makes diagnosis easier. As there are numerous similar disorders and pains in the head and neck region, differential diagnosis is paramount (Table 1).

http://dx.doi.org/10.5772/55018

1. Deviation in form
2. Disc displacement with reduction
3. Disc displacement without reduction
4. Dislocation
5. **Inflammatory conditions:** Synovitis Capsulitis
6. **Arthritides**: Osteoarthrosis Osteoarthritides Polyarthritides
7. **Ankylosis**: Fibrosis Bony

Table 1. Classifying temporomandibular disorders

In differential diagnosis of TMJ disorders and pains, problems such as neoplasms, migraine, neuralgia and mental disorders should be considered. Moreover, it is noticeable that, growth-developmental disorders include aplasia, hypoplasia, hyperplasia and dysplasia can lead to TMJ problems.

Aplasia is defective growth of skull or mandible bones. These belong to one group of mandibular anomalies named hemifacial microsomia or first and second brachial arch syndrome. These are the most common developmental defects which have no articular fossa or eminence and the patient suffers from hearing problems.

Hypoplasia is low or incomplete growth of bones which is congenital or acquired. This is milder than aplasia. Many craniofacial anomalies include incomplete growth of cranial and mandibular bones, for example Treacher-Collins syndrome.

Hyperplasia is extensive growth of bones in congenital or acquired form which is unilateral in mandibular body, coronoid or condyle and leads to asymmetry. [1-3]

Dysplasia or fibrosis dysplasia is a benign disorder with defective mandible or maxilla growth which demonstrates itself as fibrotic connective growth. On radiography, it varies from lucent to ground glass.

Neoplasia may be benign or malignant. From the benign ones, osteoma, chondroma, osteoblastoma, chondroblastoma, ameloblastoma and synovial chondromatosis (which is common in TMJ) can be named. Malignant tumors such as osteosarcoma, Ewing sarcoma, chondrosarcoma, fibrosarcoma and adenocarcinoma are usually rare. About 1% of malignant tumors metastasize to jaws.

Fractures can result in displacement, damage of joint surfaces, ligaments and disc in combination with bleeding, then adhesion, or joint derangement can be expected.

In general, intrajoint disorders are divided into 6 classes:

1. Joint deformation (deviation in form)
2. Disc displacement which itself divided into: reducing and nonreducing
3. Joint dislocation
4. Inflammation
5. Articular bone inflammation (arthritides)
6. Ankylosis

Joint deformation is a mechanical painless disorder or deviation in the form of internal hard and soft tissues which may be developmental or acquired. Deviation in form is due to destructive forces resulting in physiologic deformation. Any growth or acquired remodeling and anatomic deformation that destroy joint surfaces results in mechanical interference that clinically results in joint noises or clicking during opening and closing.

Diagnostic criteria:

1. One of the most important signs of this disorder is deviation of the jaw on mouth opening and closing.
2. Complaint of mandibular movements. (i.e. locking or dislocation)
3. Repeatable joint noises during mandibular opening and closing.
4. Radiographic findings may demonstrate bony changes or deviation in joint form (i.e. flattening of condyle head or fossa)

Disc displacement: Disc displacement is the most common TMD in which the disc is displaced anteriorly. It may be with or without reduction.

Disc displacement or dislocation with reduction: Normal relationship between disc and condyle is altered on mouth opening. The disc is anterior to the condyle corrected upon translating (opening) and a click may be heard. Upon closing the condyle slips posteriorly and reaches the retrodiscal tissue and reduces. Usually, a second noise is also heard just before mouth closing but with less sound. These two noises or clicks are named reciprocal which are the results of disc displacement. As disc dislocation with reduction is common, some consider it as physiological. So, there may be no need to treat in a painless disorder. If any pain exists, it will be seen upon joint movements usually upon reduction. Severe trauma plays an important role especially in cases resulting in distraction or ruptured ligaments or capsule (Fig. 2, 3). [1,2]

Diagnostic criteria:

1. If pain exists, it becomes severe upon joint movements.
2. Repeatable noise usually upon opening and closing.

http://dx.doi.org/10.5772/55018

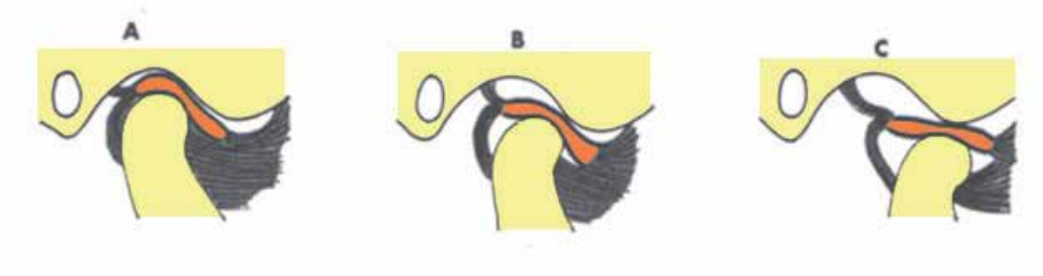

Figure 2. Normal relationship between condyle and disc; they move together.

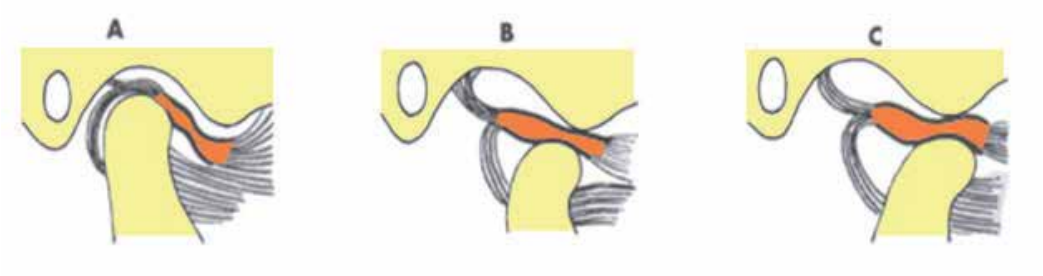

Figure 3. Disc displacement with reduction.

3. MRI images demonstrate disc dislocation which is greater upon opening.

Disc displacement or dislocation without reduction: In this state there is alteration in translating movements and an abnormal relationship remains in opening and closing. Thus, the disc does not return to its correct position and remains dislocated anteriorly without any correction during translating movement. The term "closed lock" is used to describe this disorder (the jaw is locked and will not open). The disc is stuck anterior to the condyle and maximum opening is only 10 to 15 mm. The type of condyle and disc movement is only rotational (hinge movement). During opening, the mandible deviates to the affected side. In lateral movements, inflammation and derangement is present in posterior disc tissues. Joint noises are absent here. In acute cases, pain becomes severe by forced mandibular movements. In chronic cases, pain is distinctively less and in many patients, there is no pain. In chronic cases, a history of joint noises and then limitation in mandibular opening is usually present (Fig.4). [1,2]

Diagnostic criteria: (acute type)

1. Pain accelerates during forced mandibular movements.

2. Mouth opening movements are limited (hinge movement only).

3. Deviation to the affected site exists upon mandibular opening.

4. Limitation exists in lateral movements.

Figure 4. Anterior disc displacement without reduction-there is no translational movement.

5. Soft tissue MRI reveals nonreducing disc displacement.

Acute disc displacement must be treated urgently by pulling the mandible downward and forward to allow the disc to "pop" in place posteriorly.

Diagnostic criteria: (chronic type)

1. Pain if exists, is less than acute type.
2. History of joint noises then mouth opening limitation
3. There is mandibular opening limitation
4. There is lateral movement limitation
5. MRI images demonstrate nonreducing disc displacement

Mandibular dislocation is a situation in which the condyle is displaced anteriorly in front of the articular eminence and is unable to return to its normal position. To describe it, the term "open lock" is used as the mouth locks in open position (Fig. 5) .

Figure 5. Mandibular dislocation - the position of the condyle head is in front of the articular eminence.

It is caused by:

1. Disc-condyle mandibular hypermobility.
2. Excessive translating movement of the condyle.

http://dx.doi.org/10.5772/55018

3. Atrophied articular eminence.

Acute mandibular dislocation must be treated urgently by pulling the mandible downward and backward to allow the condyle to "pop" in place posteriorly.

Diagnostic criteria

1. Closing Disability
2. Pain, if acute

Inflammation: Initial inflammation is rare and usually presents as rheumatologic disorders. Inflammation including synovitis, capsulitis and retrodiscitis often occur following trauma, damage, infection or other joint disorders. Pain in these disorders is acute and occurs with other joint movements.

Synovitis: Wearing of synovial tissue of TMJ can occur after trauma, intracapsular irritation and even unusual function. Clinical features of synovitis are local pain which becomes severe during mandibular movements. In many cases, fluctuant swelling in synovitis and pain inhibits posterior teeth from occluding.

Capsulitis: Capsular inflammation may occur because of distraction of capsular ligaments. Differential diagnosis of capsulitis from synovitis is difficult. It is painful. There is tenderness to palpation. The most important cause of capsulitis is macro- trauma. It is impossible to differentiate between capsulitis from synovitis clinically.

Retrodiscitis: Inflammation and degeneration is possible following excessive forces on retrodiscal tissues replete with nerves and vessels. As with other inflammations, it appears as dull pain upon clenching. Both of mild and severe traumas are causative factors. Sudden trauma to the chin results in condyle pressure on retrodiscal tissues and thus, inflammation and degeneration may occur in the long-term.

Diagnostic criteria

1. Local concentrated pain at rest which becomes severe in function and clenching
2. There is limitation in mandibular movement because of pain. Sometimes, swallowing leads to no contact of posterior teeth on that side. MRI may demonstrate inflammation.
3. If there is inflammation in the joint and teeth cannot occlude on the affected side.

Joint inflammations: They may be local, diffuse or generalized.

- Osteoarthrosis
- Osteoarthritis

Diffuse type includes: Polyarthritis which itself has 6 groups:

- Traumatic arthritis
- Infectious arthritis
- Rheumatoid arthritis

- Hyperuricemia arthritis
- Psoriatic arthritis
- Ankylosing arthritis

Osteoarthrosis: This is known as a degenerative noninflammatory condition of the joint. As we know, functional forces entering joint surfaces result in remodeling stimulation to adaptation of the condyle during life. It is a natural reaction of subjoint bone. However, if forces are more than adaptive capacity and condyle remodeling, degeneration or osteoarthritis will appear. In milder forces to joint surfaces and bone remodeling with no symptoms, it is named osteoarthrosis as conditions are stable but the shape of bone changes.

Clinical observations

It is painless. Limitation in mandibular movements and deviation to the affected side occurs on opening.

Radiographic findings

Bone remodeling, changes in shape and size which are signs of physiologic adaptive mechanical stress are seen. However, initial degeneration of joint can be demonstrated with arthroscopy.

Diagnostic criteria

1. Crepitus, (grating sound)
2. Limitation in mandibular movements resulting in deviation to the affected side on opening.
3. If radiography shows bony changes, they include: subchondral sclerosis, osteophyte, density loss, subjoint cysts.

Osteoarthritis: This is a degenerative condition sometimes associated with a secondary inflammation of the TMJ (i.e. synovitis). Osteoarthritis is a degenerative process of condyle and fossa surfaces resulting in their changes. It has slow progression then cartilage remodels and reshapes. Osteoarthritis may be a component of a systemic disorder.

Etiology

When articular surfaces are unable to bear the forces, the capacity of functional adaptation cannot respond and thus, degeneration ensues. If bony changes are active, it is named osteoarthritis.

Clinical features

Limitation of opening is present because of articular pain. Crepitus is obviously common. Condyle palpation leads to pain.

Radiographic findings

Include: bony changes in subarticular bone of condyle and fossa, sclerosis, subarticular cysts, osteophyte, low density and roughness. In progressive conditions, extensive condyle degen-

http://dx.doi.org/10.5772/55018

eration is present. It is considerable that patient may have signs before demineralization in radiography. Individuals suffering from osteoarthritis usually have unilateral pain which becomes worsened in mandibular movements and also in late afternoon and night. Articular changes may be due to trauma, destructive forces, infection or an idiopathic process (Fig. 6).

Figure 6. Degenerative lesions in the TMJ with disc perforation.

Diagnostic criteria:

1. Pain upon function due to inflammation.
2. Trigger points to palpation are present.
3. Crepitus
4. Limitation in mandibular movements with deviation to the affected side on opening
5. Radiographic changes include : subchondral sclerosis, osteophyte, narrowing of articular space

Polyarthritides: This includes a variety of articular disorders which are less common. Their signs and symptoms are like in osteoarthritis but with completely different etiology. Different types include: Traumatic arthritis, infectious arthritis, rheumatoid arthritis, hyperuricemia arthritis, psoriatic arthritis and ankylosing arthritis.

Traumatic arthritis: Major trauma to the jaw leads to articular surface changes and inflammation. Clinically, patients have consistent pain becoming severe with movements and opening limitation.

Infection Arthritis: It occurs because of bacterial infection from adjacent structures.

Rheumatoid arthritis: It is an autoimmune chronic systemic disorder which leads to synovitis. Clinical features are continuous pain, pain on swallowing and limitation in mandibular movements. It involves joints of the legs, at first. In 5%, there are signs in the TMJ. In about 80% of patients, rheumatoid factor is positive. In initial stages, there is no distinctive radiographic sign because changes are in soft tissues. But after progressing, erosive changes, subchondral cysts, decrease in articular space, bone degeneration and osteoporosis can be seen. In acute cases, inflammation and tenderness to palpation is present. Limitation in mandibular movement leads to ankylosis progress. Condyle degeneration may result in VD reduction and anterior open bite. Crepitus or joint noises may be present, also. Histologically, in progressive stages, there is severe secretion of lymphocytes, plasma cells and lysosomic enzymes with exudates in the joint. It usually affects the TMJs bilaterally and is more common in women (Fig. 7).

Figure 7. Degenerative changes in rheumatoid arthritis-attenuation of the condyle.

Hyperuricemia: In this disorder, crystals of sodium urate in periarticular tissues increase which lead to, warmness, tenderness to palpation and pain in mandibular movement. Gout is a common hereditary disease in men. In laboratory tests, uric acid and erythrocyte sedimentation rate in blood is high. In radiography, punch-out bone erosions can be seen.

Psoriatic arthritis: This is an autoimmune disease accompanied by psoriasis dermatic lesions. Psoriatic arthritis affects men more than women and Rh factor is negative. Radiographic findings reveal osteoarthritis changes with erosion, osteoporosis and narrowing of articular space. This polyarthritis is asymmetric. Joint signs are pain, warmness, pain on swallowing and limitation in mandibular movements.

http://dx.doi.org/10.5772/55018

Ankylosing spondylitis: Ankylosing spondylitis or Marie-Strumpel disease is a chronic inflammatory disease with unknown cause.There is HLA-B27 marker. It involves joints of the vertebrae. There is calcification in ligaments tending toward bony ankylosis here. It is more common in men. There are signs such as arthritis and iridocyclitis present. The possibility of involving TMJ is low but in cases of TMJ involvement, signs are mild and the most important one of them is limitation in mandibular movements, pain, and diffuse stiffness in muscles. These patients have severe signs in other joints. On radiography, bone margins of subchondral bone are absent and sclerosis, bony erosions, narrowing of joint space and extensive ankylosis are visible.

Ankylosis: In general, ankylosis means abnormal immobility of the jaw and mandibular movements because of adhesion. It is divided into 2 major groups: bony and fibrotic. In fibrotic ankylosis fibrous adhesion or fibrotic changes in capsular ligaments occurs. It is the most common form which occurs between condyle and disc or between disc and fossa. Bony ankylosis occurs between condyle and glenoid fossa, and leads to fusion. In another classification, low mobility disorders are divided into three groups:

Trismus because of stiffness of masticatory muscles.

1. Psudoankylosis which results from extracapsular causes and leads to reduced mandibular movements.

2. True ankylosis: It results from fibrosis adhesion or bony fusion. The most severe form of it is low mobility because of bony adhesion of condyle to glenoid fossa.

The most common form of low mobility is trismus from infection, trauma, malocclusion, tumors and mental problems.

The most common cause of pseudoankylosis is due to zygomatic arch and condyle fracture. This fracture leads to transgression of a part of these structures to articular space and finally, inhibition of condyle movements. Adhesion of the coronoid process and hypertrophy around it, or fibrosis of the temporalis muscle, can be considered as other causes of pseudo ankylosis. In true ankylosis, trauma is the most common cause of bony ankylosis. Following trauma, in children, after 3 to 6 months, mandibular movements become progressively reduced; the most important mechanism after trauma, is bone formation following intracapsular hematoma or intracapsular fracture. The most important cause of ankylosis after trauma is intracapsular infection. With a lower percentage, ankylosis occurs after intracapsular inflammations such as rheumatoid arthritis, Still's disease, Marie-Strumpel disease etc. Fibrosis or bony ankylosis is also common after arthroplasty. Bony type occurs after diskectomy as well. In initial diagnosis, panoramic radiography can be used. More complete information is gained from CT scans. If fibrotic ankylosis is present, articular space decreases. Articular space loss is a sign of disc destruction; the space may fill with bone. [1,4]

Etiology: The most common cause of is macrotrauma which leads to tissue damage, inflammation and hemarthrosis. These increase the formation of fibrous matrix. The other cause of ankylosis is surgery that often results in fibrotic changes and reduced mandibular movements. Fibrosis ankylosis of mandible is the continuous progression of joint adhesion.

Clinical features: Patients have history of damage or capsulitis with reduced mandibular movements (which is painless). Mandibular movements in all directions (opening, lateral and protrusive) are limited. If ankylosis is unilateral, the jaw deviates to the affected site on opening. In most cases of ankylosis, the condyle can rotate to some degree thus the patient is able to open his/her mouth 20 to 25 mm. Bilateral ankylosis in children results in severe retrognathia and bird face with open bite.

Diagnostic criteria (fibrosis type):

1. Reduced opening limit
2. Distinctive deviation to the affected site
3. There is no translational movement of condyle

Diagnostic criteria (bony type):

1. Severe mandibular movements limitation
2. Deviation to the affected site in unilateral cases
3. When it is unilateral, lateral movements to the unaffected site is clearly limited.
4. Bony proliferation and immobility of the condyle on radiography (Fig. 8).

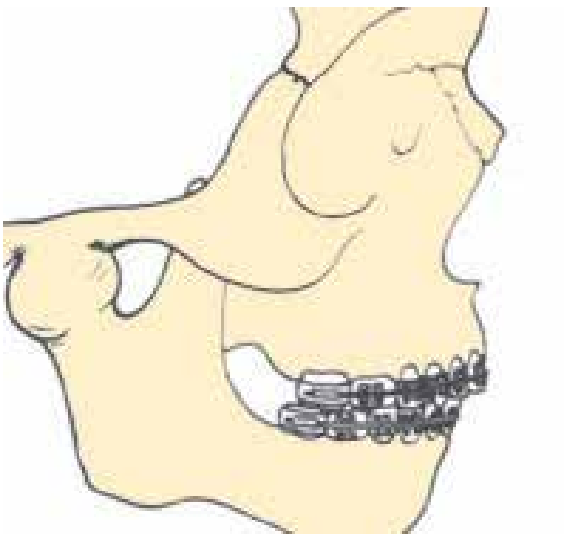

Figure 8. Complete bony ankylosis

Adhesion: Sticking of joint surfaces to each other may occur between condyle and disc (inferior articular space) or between disc and glenoid fossa (superior articular space). This may follow long-term forces (for example clenching during sleep), hemarthrosis, macro trauma and or surgery.

http://dx.doi.org/10.5772/55018

Clinical features:

In adhesion between disc and fossa, normal translational movement is limited, so the condyle just has rotational movement. In this case, opening range is about 25 to 30 mm.

If this kind of adhesion occurs permanently in the superior joint space, the disc remains posterior to the condyle which in fact is posterior dislocation of the disc.

In adhesions of the inferior joint space, translational movements may be normal. But the condyle is unable to do rotational movement with the disc. The result is a jolt during mouth opening.

Masticatory muscles disorders

Masticatory muscles disorders in the head and neck region, include: myofacial pains, myositis, spasm, protective splinting, contracture and neoplasia. In most patients with TMD, the muscles are tender to palpation and 40% of them have pain chewing food. Fibromyalgia is a chronic muscle pain.

Myofacial pain

Myofacial pain can be misleading by tension type headache resulting from tiredness.

Etiology :

The most important causes are : Systemic factors such as vitamin deficiency, viral infection, mental stress and sleep disorders. The chief compliant of the patient is various pains, recurrent pains, temporal headache etc. Here, the patients show the site of pain not the source of it.

Clinical features:

The most important sign of myofacial pains is trigger point.Other signs are pain at rest and upon activity.

Diagnostic criteria:

1. Poorly localized pain
2. Localized trigger point in muscles or fascia
3. Pain decrease in localized anesthetic injection

Myositis or inflammatory myalgia

This is a muscular tissue inflammation resulting from localized causes such as trauma or infection. Myositis is divided in two types of inflammatory reactions:.

Diagnostic criteria: (type 1)

1. Pain increase in mandibular movements
2. Pain following long and abnormal use of muscles

Diagnostic criteria: (type 2 : diffuse)

1. Pain is usually acute in localized areas
2. Localized tenderness to palpation in all parts of the muscles
3. Pain increase in mandibular movements
4. Moderate to severe limited movements due to inflammation

Myospasm or tonic contraction myalgia:

Myospasm is a toxic muscular contraction created by CNS

Myospasm or acute trismus is an acute disorder and sudden and involuntary contraction.

Diagnostic criteria:

1. Acute pain
2. Persistent contraction of muscle
3. Hyperactivity of EMG
4. Pain decrease in activity
5. Pain at rest and tenderness to palpation

Evaluation and diagnosis of temporomandibular disorders

The patient history should include chief complaint, history of the present illness, medical and dental history and individual history (Table 2).

1. Do you have difficulty, pain or both when opening your mouth, for instance when yawing?
2. Does your jaw stick, locked, or go out?
3. Do you have difficulty, pain or both when chewing, talking or using your jaws?
4. Are you aware of noises on the jaw joint?
5. Do your jaws regularly feel stiff, tight or tired?
6. Do you have pain in or about the ears, temples or cheeks?
7. Do you have frequent headaches and or neck aches?
8. Have you had a recent injury to your head, neck or jaw?
9. Have you been aware of any recent changes in your bite?
10. Have you previously been treated for a jaw joint problem? If so when?
Masticatory muscle disorders
1. Myofacial pain
2. Myositis
3. Spasm

4. Protective splinting
5. Contracture
6. Neoplasia
Usual examinations in TMD
1. Measure range of motion of the mandible or opening and right and left lateral excursions (note any uncoordination in the movement)
2. Palpate for pre- auricular or interameatal TMJ tenderness
3. Auscultate and or palpate for TMJ sounds (clicking or crepitus)
4. Palpate for tenderness in the masseter and temporalis muscle
5. Note excessive occlusal wear , excessive tooth mobility , buccal mucosal lateral tongue scalloping
6. Inspect symmetry and arrangement of the face, jaw and dental arches
Differential diagnosis of oral and maxillofacial pains:
1. Intracranial structures
2. Extracranial structures
3. Neuromuscular disorders
4. Neuropathic pain disorders
5. Continuous pain disorders
6. Sympathetic maintained pain
7. Psychogenic pain disorders
8. Somatoform disorders
Pseudoankylosis :
1. Depressed zygomatic arch fracture
2. Fracture dislocation of the condyle
3. Adhesions of the coronoid process
4. Hyper trophy of the coronoid process
5. Fibrosis of the temporalis muscle
6. Myositis ossificans
7. Scar contracture following thermal injury
8. Tumor of the condyle or coronoid process
True ankylosis:
1. Inter capsular fracture (child)
2. Medial displaced condylar fracture (adult)
3. Obstetric trauma
4. Intracapsular fibrosis

5. Infection : otitis media		
6. Suppurative arthritis		
7. Inflammation:,	Rheumatoid arthritis	Stills disease
8. Ankylosing spondylitis		
9. Mari Strumpel disease		
Surgical : Post operative complications of TMJ surgery Orthognathic surgery		
Hypomobility of the mandible		
1. Odontogenic :myofacial pain , malocclusion , erupting teeth		
2. Infection: pterygomandibular , lateropharyngeal , temporal		
3. Trauma: fracture of the mandible , muscle contusion		
4. Tumors: nasopharyngeal tumors, tumors that invade jaw muscle		
5. Psychological: hysterical trismus		
6. Pharmacologic: phenothiazines		
7. Neurologic: tetanus		
Sign and symptoms of mental disorders		
1. Inconsistent , inappropriate and or vague of pain		
2. Over-dramatization of symptoms		
3. Symptoms that vary with life events		
4. Significant pain of greater than 6 month duration		
5. Repeated failures with conventional therapies		
6. Inconsistent response to medications		
7. History of other stress – related disorders		
8. Major life events e.g. new job , marriage , divorce , death		
9. Evidence of drug abuse		
10. Clinically significant anxiety or depression		
11. Evidence of secondary gain		

Table 2. Questionnaire about TMD

Recommended Imaging for TMD:

Panoramic view:

It is a valuable method in diagnosis of TMD. Advantages are low price and the possibility of comparing both sides of mandible and fossae.

Generally, information from panoramic view include: whole evaluation of maxilla and mandible bilaterally (coronoid process and condyle).

Magnetic Resonance Imaging (MRI):

Today, MRI often is used to diagnose of TMD. This method evaluates both joints at the same time. Video film is achieved from mandibular movements during imaging, also. On the other hand, the danger of high radiation is obviated.

Computed tomography (CT Scan):

This technique is used in recognizing bony abnormal cases or anomalies of TMJ (such as developmental anomalies, trauma and neoplasia). CT does not play an important role in diagnosing disc displacement because it is problematic in showing the disc. CT scan with direct sagittal plane provides high quality images. It is the best method in evaluating bone structures (ankylosis) in combination with TMJ.

Disadvantages:

1. High price
2. No suitable images of soft tissue within the joint
3. No possibility of imaging during motion of disc and condyle

Arthrography:

It refers to the injection of a radiopaque contrast medium into the inferior, superior or both spaces and evaluating intracapsular soft tissues. Dynamic and functional movement of the disc and condyle can be assessed via fluoroscopy and video in this method. This technique is very precise in observing intracapsular derangement. Arthrography is the method choice to recognize disc perforations.

Disadvantages:

It is a minimally invasive method, may result in infection, hematoma, disc injury, or hypersensitivity to the medium.

Diagnoses achieved by arthrography:

1. Disc dislocation with reduction
2. Disc dislocation without reduction
3. Perforation
4. Adhesion

Mental and socio-behavioral evaluation:

In patients with TMD especially who suffer from chronic pain sometimes stress due to muscle hyperactivity may be recognized as a major factor. So there should be some questions in order to evaluate behavioral, social and emotional factors because they may result in initiation, or

exacerbation of the disorder. On the other hand, long-term chronic pains with function disorder can lead to mental changes. Anxiety and depression are recognized by simple questions.

Additional clinical tests:

Biopsy:

This is helpful in diagnosis of benign and malignant tumors of the TMJ; the most important of them are chondroma, chondrosarcoma and osteochondromatosis.

Diagnostic anesthesia injection:

These injections include:

1. Nerve block (auriculotemporal nerve)
2. Trigger points injection
3. TMJ injections

4. Conservative therapy

Treatment goals in patients with TMD are : Pain relief and return of function. These goals will be achieved only if diagnosed properly and the treatment plan takes mental and physical problems into consideration. Predisposing factors must be eliminated. In many cases, signs and symptoms of TMD are transient and self-limited without any serious sequelae and no invasive treatment is needed. [1,2]

Conservative treatments such as behavioral modifications, physiotherapy, medication therapy and splint therapy decreases signs and symptoms in most patients suffering from TMD. There are many studies that emphasize this point; 86% or more of these patients with disc displacement become pain-free and regain acceptable function. [1,2]

In general, TMD treatments are divided into two separate phases :

Phase 1: Includes education, anxiety control, behavioral modifications, medication therapy and splint therapy.

Phase 2: Dental rehabilitation, occlusion correction, fixed prosthesis, restorative treatments, orthodontic treatments and orthognathic surgery. The concept of treatment phase 2 is that it will be done automatically after completion of phase 1. In spite of successful conservative treatment in TMD, some patients do not improve. These patients are divided in two groups:

1. Pain and dysfunction is as a result of changes in joint structures. Joint surgery may be needed in this case.
2. 2- Patients with chronic syndromes or combination of factors. In this case, a treatment plan for chronic pain and a group of specialists may be needed. Selective treatments include:

http://dx.doi.org/10.5772/55018

3. Patient education and stress control
4. Mental therapy
5. Pharmacotherapy
6. Physiotherapy
7. Splint therapy
8. Occlusal correction
9. Surgery

Patient education and stress control: Successful treatment lies in awareness, patient motivation and cooperation. Dentist should explain clinical findings, diagnostic information, treatment choices and prognosis in simple terms. Necessary instructions should include;

1. Muscle relaxant by voluntary limitation in mandibular function
2. Parafunctional habits modification
3. Physiotherapy at home

The program should emphasize avoiding chewing hard food or gum, yawning, singing, excessive talking, bruxism and clenching and bad sleeping habits. Home physiotherapy plan includes moist warm towels on sensitive areas can decrease sensitivity and pain and also increase the range of mandibular movements. Heat relaxes muscles in the form of warm and moist compress. Patient's stress and habits can be treated by a combination of different methods such as behavioral modifications, medication therapy and physiotherapy. Patient cooperation and motivation play an important role here.

Pharmacotherapy:

It is effective in treatment of TMD. Clinical experiences show that pharmacotherapy and supportive treatment will accelerate patient improvement. It is noticeable that no drug has a complete range of effectiveness in TMD. The most effective drugs to treat all kinds of TMD include analgesics and nonsteroidal anti-inflammatory drugs (NSAIDs), corticosteroids, muscle relaxants, anti-depressants and antianxiety drugs. Analgesics and corticosteroids in acute TMD pain, nonsteroidal anti-inflammatory drugs and muscle relaxants in both acute and chronic disorders and tricyclic anti- depressants in chronic problems are recommended. It is advised that tranquillizing drugs three times a day for two weeks be given.

Analgesic drugs:

These drugs are used to decrease pain in TMD. Non-narcotics are effective on mild to moderate pains. The primary form aspirin inhibits prostaglandin synthesis. Ibuprofen is effective in skeletomuscular pains (dosage: 600 – 800 mg three times daily). These drugs may have gastrointestinal side-effects.

Corticosteroids:

These drugs have effective anti-inflammatory properties but rarely used in TMD.

Muscle relaxant drugs:

These drugs are advised for muscle hyperactivity inhibition in TMD; mainly benzodiazapines.

Anti depressant drugs:

Recently, antidepressant drugs are used in different kinds of chronic pains. For example, pain decrease is expected in low dose of Amitriptyline (Elavil) 10 mg before sleep for some weeks. This 1/10 to 1/20 dosage is because of its antidepressant property.This drug can be used in individuals who have depression and sleep disorder due to their chronic pain and is effective in treatment of headache resulting from muscle contraction and musculoskeletal pains. It increases the stage 4 (delta) of sleep and reduces rapid eye movement (REM) in sleep. They may be effective in treatment of nightly bruxism, also. In dosage between 10 to 75 mg, they are effective in treatment of orofacial chronic pains. Antidepressant drugs should be advised by specialists. Recommendations of these drugs are for individuals who have depression not only TMD.

Antianxiety drugs:

They are effective when TMD is associated with anxiety. They reduce the patient's reaction to stress. The most common drugs in this group is diazepam which should not be given for more than 10 days. Dosage of 2.5 to 5 mg before sleeping results in muscle relaxation and probable decrease in parafunctional habits.

Local anesthetic drugs:

As it was said before, local anesthetic drugs are used for two aims of treating and diagnosing. When we are suspecting neuralgia, or treating disc or mandibular dislocations. [5,6]

Physical therapy:

A group of supportive treatments used as an important part of successful treatment of TMD includes physiotherapy.

Physical therapy modalities: This treatment includes: Thermal therapy, ultrasound, electro-galvanic stimulation therapy, low voltage electric stimulation, acupuncture and low-level laser. [7]

Thermal therapy:

Heat leads to blood flow increase at that site. A moist warm towel can be used in the site for 10-15 minutes, on and off.

Ultra sound:

This method results in increasing temperature of internal tissue surfaces, so deep surfaces become warmer. Its mechanism is translating high frequency to heat during passing through tissues. This heat is able to penetrate.

Splint therapy: 1 – Interocclusal splint, 2 – Anterior repositioning splint

Splints solves muscle tension and TMJ pain decreases. In anterior displacement of disc and degenerative joint disorder, splint decreases direct pressure in TMJ area so joint and muscles

http://dx.doi.org/10.5772/55018

have a passive state. Occlusal splints use in TMD treatments as temporary and conservative treatment decrease occlusal direct load in TMJ region. It allows the patient to seek the most comfortable muscle and joint position without excessive influence of the occlusion. It is advised to use the splint at night for several months because results appear then. Theoretically, the position of disc and condyle head is corrected and condyle is placed in a proper relation with the disc. So, posterior disc ligaments shorten maintaining the disc in proper relationship to the condyle. However, splints may be required for a year or more to stabilize treatment, provide relief pain and discomfort of TMJ (Figs. 9, 10).

Figure 9. Maxillary hard acrylic splint.

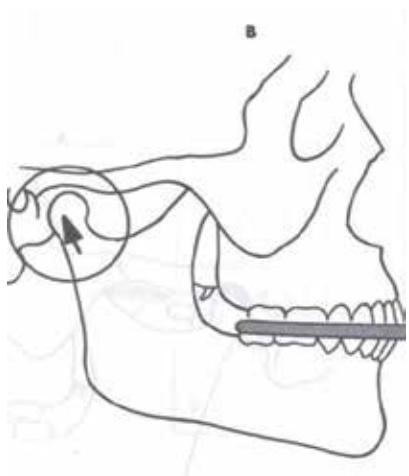

Figure 10. Maxillary hard acrylic splint increases joint space when used; it allows for disc reduction, relieves spasms, redistributes occlusal forces and prevents attrition.

5. TMJ surgery

Although most patients with TMJ disorders can be treated by nonsurgical and conservative treatment, in some, surgery is necessary. The common TMJ surgeries are:

1. Arthrocentesis
2. Arthroscopy
3. Disc – repositioning surgery
4. Condylotomy
5. Arthroplasty
6. Total joint displacement

Arthrocentesis:

Arthrocentesis involves placing a suitable needle into the superior joint space and aspiration for histopathology examinations, and then a large amount of lactated Ringer's solution is injected into the superior joint space to debride the superior joint space. This is done by a maxillofacial surgeon who has enough skill and experience in TMJ surgery to prevent adverse effects. Most patients undergoing arthrocentesis prefer local anesthesia and sedation.

Arthroscopy

Use of arthroscopy in diagnosing, treating and surgery of TMJ disorders is very popular. In comparison with open surgery and direct cutting of local tissues, arthroscopy is more comfortable with less adverse effects. In Arthroscopy, at first, a small cannula is placed into the superior joint space, followed by insertion of an arthroscope with a light source.The end of arthroscope is connected to a TV and a video monitor which allows perfect visualization of all aspects of the joint including glenoid fossa and joint disc. Intrajoint space just can be visualized and joint space can be washed and pathologic adhesions can be lysed. One cannula is used for visualization, where as instruments are placed through the other one are instruments such as forceps, scissors, sutures, cautery, medication needles, laser instrumentation and shavers. So, Arthroscopy is possible for disc displacement, disc attachment release, posterior band cautery, and suture techniques.Laser fibers can also be used to eliminate adhesions and inflamed tissue and cutting adhesions. A variety of TMJ disorders, including internal disorders, hypomobility as a result of fibrotic adhesions, DJD, hypermobility or excessive movements of joint can be treated by arthroscopy.

It is noteworthy that before and after arthroscopy, conservative treatments such as splint therapy and physiotherapy are used (Fig. 11).

Disc repair:

In advanced disorders, the joint disc may be severely damaged. Sometimes it can be repaired but in other cases there is no alternative except to remove it. Disc repair or replacement is done with autogenous grafts include dermis, temporalis fascia, auricular cartilage or inferior nasal

http://dx.doi.org/10.5772/55018

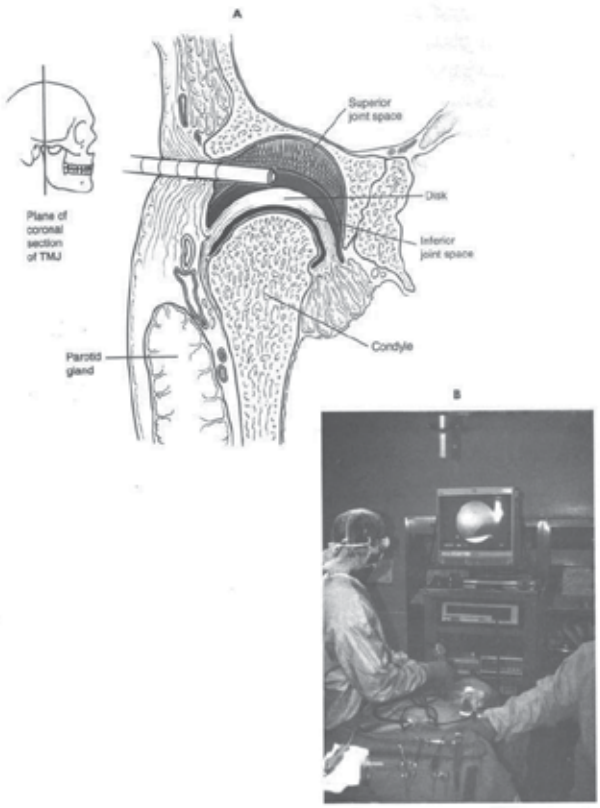

Figure 11. Arthroscopy of the superior joint space.

concha. Although, long-term results of these methods are not desirable in all cases, but most patients are satisfied from local function improvement and pain decrease.

Condylotomy of TMJ:

In this method, a subcondylar osteotomy in the ramus is used which starts from the sigmoid notch and ends inferiorly to the condylar neck. The lateral pterygoid muscle pulls the head of the condyle in a new passive relationship with disc and joint socket. It is suggested in some disorders such as recurrent anterior disc displacement and in degenerative joint disease.

Arthroplasty:

It is a treatment choice in bony ankylosis and fibrosis of TMJ. In this method, a part of the condyle head is removed. A gap is created between the head of the condyle and glenoid fossa so the patient can open his/her mouth.[4]

Total joint replacement:

Sometimes, advanced degenerative lesions lead to condyle process destruction, so it is necessary to repair that part by autogenous graft or other implants. In advanced rheumatoid

arthritis, neoplastic lesions, trauma and damage to local structures, there are destructions in many parts of the condyle and glenoid fossa. Costochondral graft often is used to replace condyle head and neck. In total joint replacement, titanium is used which has the same shape as the glenoid fossa and condyle head. This avoids severe pains, limitation or ankylosis, complete closed lock, deformation and severe malocclusion. (Fig.12)

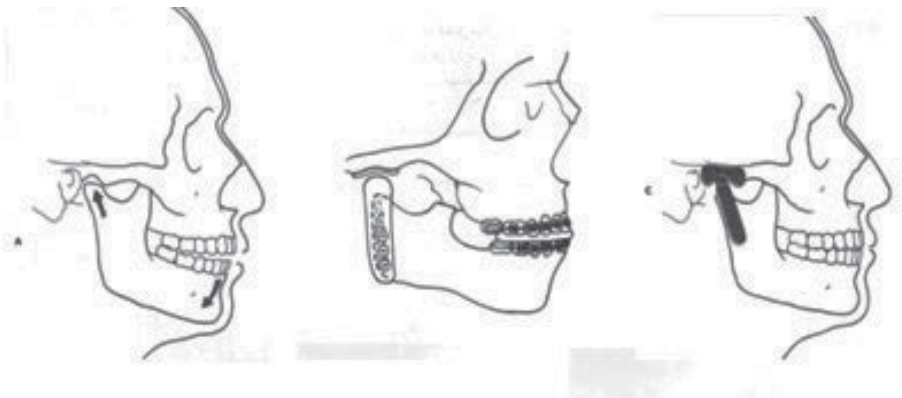

Figure 12. Total joint replacement – condyle removal and replacement via prosthesis.

Myofacial pain dysfunction syndrome (MPDS)

Causes pain, discomfort and inflammation in muscles and joints affecting function and activity of the masticatory system. This is a maxillofacial muscle disorder due to parafunctional habits or muscular hyperactivity and because of stress and anxiety.

Methods of stress control include: Exercise, avoiding stressful factors, psychological consultant, behavioral modification, soft diet for 4 weeks, trying to maximum opening the mouth without pressure, pain, slowly and with stretching exercises.

Medication:

1. Analgesic and anti inflammatory drugs

Ibuprofen – piroxicam, or acetaminophen codeine 3 – 4 times daily for 10 – 14 days

2. Muscle relaxant :

In individuals with muscles hyperactivity and severe pain give (3 -4 times daily for 10 – 14 days) diazepam (2- 5 mg 3 – 4 times in a day).

2. Tricyclic anti – depressant such as Amitriptyline (Elavil) lead to sleep improvement, nightly bruxism decreases and muscle pain improvement.

Triptizol Tab 10 – 25 mg, nightly before sleep

Physical therapy: Includes: Relaxation therapy, Ultrasound heating, stretching, pressure massage

Permanent occlusion modification:

After a reversible and conservative treatment, some people need permanent treatment and occlusal adjustment. It includes: prosthetic restoration, orthodontic treatment, orthognathic surgery and occlusal equilibration if it is necessary. These treatments in indicated patients may provide long-term treatment effects.

Surgical treatments include:

Arthrocentesis, Arthroscopy, Disc repair or removal, Disc repositioning, Condylotomy, Total joint replacement.

Author details

Fina Navi[1], Mohammad Hosein Kalantar Motamedi[3], Koroush Taheri Talesh[2], Esshagh Lasemi[2] and Zahra Nematollahi[4]

1 Scientific Faculty, Department of Oral and Maxillofacial Surgery, Azad University of Medical Sciences, Tehran, Iran

2 Department of Oral and Maxillofacial Surgery, Azad University of Medical Sciences, Tehran, Iran

3 Department of Oral and Maxillofacial Surgery, Trauma Research Center, Baqiyatallah University of Medical Sciences, Tehran, Iran

4 Private Practice Dentistry, Tehran, Iran

References

[1] Dowlat Abadi MMotamedi MHK, Taheri KT. Textbook of Temporomandibular Disorders. Shayan Nemodar Publications, Tehran, (2009). , 2009, 5-100.

[2] Mortazavi, S. H. Motamedi MHK, Navi F, Pourshahab M, Bayanzadeh SM, Hajmiragha H, Isapour M: Outcomes of management of early temporomandibular joint disorders: How effective is nonsurgical therapy in the long-term? National J Maxillofac Surg, (2010).

[3] Motamedi, M. H. Treatment of condylar hyperplasia of the mandible using unilateral ramus osteotomies. J Oral Maxillofac Surg. (1996). Oct;discussion 1169-70, 54(10), 1161-9.

[4] Behnia, H, Motamedi, M. H, & Tehranchi, A. Use of activator appliances in pediatric patients treated with costochondral grafts for temporomandibular joint ankylosis: analysis of 13 cases. J Oral Maxillofac Surg. (1997). discussion 1414-6., 55, 1408-14.

[5] Motamedi, M. H, Rahmat, H, Bahrami, E, Sadidi, A, Navi, F, Asadollahi, M, & Eshkevari, P. S. Trigeminal neuralgia and radiofrequency. Todays FDA. (2010). Sep-Oct; 22(5):54-5, 57-9.

[6] Bohluli, B, Motamedi, M. H, Bagheri, S. C, Bayat, M, Lassemi, E, Navi, F, & Moharamnejad, N. Use of botulinum toxin A for drug-refractory trigeminal neuralgia: preliminary report.Oral Surg Oral Med Oral Pathol Oral Radiol Endod. (2011). Jan;Epub 2010 Jul 31, 111(1), 47-50.

[7] Lassemi, E, & Jafari, S. M. Motamedi MHK, Navi F, Lasemi R: Low-level Laser Therapie in the Management of Temporomandibular Joint Disorder. JOLA, (2008).

Edited by Mohammad Hosein Kalantar Motamedi

The discipline of oral and maxillofacial surgery covers a wide range of diseases, conditions, injuries and defects of the head, neck, face and jaws as well as the hard and soft tissues of the oral cavity. It is an internationally recognized surgical specialty rapidly changing with evolving advancements in technology. Specialists of this field care for patients with problems such as impacted teeth, facial pain, misaligned jaws, facial injuries, oral cancer, cysts, tumors, and patients requiring facial cosmetic surgery and dental implants. New texts are needed to keep practitioners up-to-date because advancements are being made world-wide on a daily basis. This book seeks to present advanced concepts on complex topics within the scope of this dynamic discipline.

ISBN 978-953-51-7166-9

Photo by creativenv / iStock

IntechOpen